

Four-handed Technique for Total Laparoscopic Hysterectomy: An Italian Experience

Pierpaolo Nicoli¹, Anna Biffi², Gregorio Del Boca², Amerigo Vitagliano¹, Erica Silvestris³, Vera Loizzi³, Edoardo Di Naro¹, Ettore Cicinelli¹, Gianluca Raffaello Damiani^{1*}

¹Department of Obstetrics and Gynecology, University of Bari, ²Gynecologic Oncology Unit, IRCCS Istituto Tumori "Giovanni Paolo II", Bari, ³Department of Obstetrics and Gynecology, Unit of Gynecology and Obstetrics, Leopoldo Mandic Hospital, Merate, ASTT, Lecco, Italy

Abstract

Objectives: In our previous article, we proposed the novel four-handed technique (FHT) for total laparoscopic hysterectomy (TLH), which, according to us, is more helpful compared to the traditional TLH route. The objectives of the study were to analyze the FHT-TLH feasibility and efficiency by comparing some surgical outcomes recorded from 750 FHT-TLH performed in our hospital to literature data about the traditional TLH route and to underline the great opportunity this novel technique offers to the young specialists and residents to be more confident with gynecological laparoscopy.

Materials and Methods: This was a retrospective analysis carried out by collecting data regarding patient characteristics and surgical outcomes (operative time, blood loss, surgical complications, use of analgesics, and length of hospitalization) from 750 hospital records of women who underwent FHT-TLH (with or without adnexectomy) due to benign or malignant pathology from January 2015 to December 2021 at our hospital.

Results: We performed a total of 750 FHT-TLH, with or without adnexectomy. The mean skin-to-skin operative time for a FHT-TLH was 50 min, and the mean blood loss was 150 mL. No visceral damage was caused during surgeries. Only two patients underwent exploratory laparotomy with total abdominal hysterectomy due to the inability to proceed laparoscopically. Nonsteroidal anti-inflammatory drugs were administered only twice a day as analgesics, with advantage. The mean length of stay in the hospital after the procedure was 1.5 days, with discharge on the evening of the 1st day after surgery. No major postoperative complications occurred. The only minor postoperative complication described, in just three patients, was cellulitis of the vaginal vault.

Conclusion: Our FHT-TLH experience represents an alternative to the traditional TLH route, which allows to apply a minimally invasive approach with some advantages for patients compared to the traditional TLH route, such as early recovery and reduced operating time, blood loss, use of analgesics, and hospital stay. Moreover, it allows young specialists and residents to be more confident with gynecological laparoscopy, particularly when operating as the first assistant, to improve their laparoscopic surgical skills faster than the traditional TLH route allows them.

Keywords: Four-handed technique, hysterectomy, time reduction, total laparoscopic hysterectomy

INTRODUCTION

Although in the beginning, gynecology has been slow to adopt minimally invasive procedures, the laparoscopic approach to hysterectomy has increasingly replaced the abdominal one, and nowadays, total laparoscopic hysterectomy (TLH) represents the standard of care for a multitude of pelvic

complaints. Indeed, benefits of TLH have been widely demonstrated in literature, particularly magnification of anatomy and pathology, access to the uterine vessels, vagina, and rectum, the ability to achieve complete hemostasis and clot evacuation, and all patient advantages related to

Article History:

Submitted: 02-Apr-2023

Revised: 23-Sep-2023

Accepted: 09-Nov-2023

Published: 18-Jul-2024

Access this article online

Quick Response Code:



Website:
<https://journals.lww.com/gmit>

DOI:
10.4103/gmit.gmit_50_23

Address for correspondence: Dr. Gianluca Raffaello Damiani, Department of Obstetrics and Gynecology, University of Bari, I Clinic, Bari, Italy.
E-mail: damiani14@alice.it

This is an open access journal, and articles are distributed under the terms of the Creative Commons Attribution-NonCommercial-ShareAlike 4.0 License, which allows others to remix, tweak, and build upon the work non-commercially, as long as appropriate credit is given and the new creations are licensed under the identical terms.

For reprints contact: WKHLRPMedknow_reprints@wolterskluwer.com

How to cite this article: Nicoli P, Biffi A, Boca GD, Vitagliano A, Silvestris E, Loizzi V, *et al.* Four-handed technique for total laparoscopic hysterectomy: An Italian experience. *Gynecol Minim Invasive Ther* 2024;13:161-7.

avoidance of a painful abdominal incision, which include faster recovery, reduced duration of hospitalization, and an extremely low rate of infection and ileus.^[1-4]

Mettler *et al.* clearly describe and illustrate the different types of laparoscopic hysterectomy (LH) (laparoscopic-assisted vaginal hysterectomy [LAVH], TLH, classic intrafascial supracervical hysterectomy, laparoscopic supracervical hysterectomy, and radical laparoscopic vaginal hysterectomy [VH]), which are advantageous to patients if performed by experts for the appropriate indication.^[5]

In our previous article, we proposed the four-handed technique (FHT) for TLH,^[6] which according to us is a more ergonomic, efficient, and effective technique compared to the traditional one. The aim of the present article was to analyze FHT-TLH feasibility and efficiency in terms of operative time, blood loss, use of analgesics, and length of hospitalization. Furthermore, we want to underline how young specialists and residents can improve their TLH learning curve by means of this new procedure.

MATERIALS AND METHODS

From January 2015 to December 2021, 750 women underwent FHT-TLH, with or without adnexectomy, due to benign or malignant pathology in the Unit of Gynecology and Obstetrics, Hospital of Merate, ASST Lecco, Merate, Lecco, Italy.

Inclusion criteria were: benign disorders requiring simple hysterectomy with or without adnexectomy; malignant disorders requiring Type A radical hysterectomy (Querleu–Morrow Classification) with bilateral adnexectomy; and patient consent. The upper limit of uterine size was set to 17 weeks (13 cm in length). Benign disorders included: menorrhagia, metrorrhagia; uterine leiomyoma; dysmenorrhea, pelvic pain; endometrial hyperplasia; endometriosis; postinflammatory disorders; and cervical intraepithelial neoplasia (CIN) (when indicated). Malignant disorders included: Stage IA Grade 1/2 endometrioid type endometrial cancer (International Federation of Gynecology and Obstetrics 2009).

Exclusion criteria were: myoma located on the uterine isthmus or intraligamentary myoma with a main diameter >10 cm; total uterine prolapse; body mass index >45; and anesthetic contraindications for laparoscopic surgery. Patients who needed additional surgical procedures were excluded too.

All women underwent preoperative pelvic ultrasonography and, when indicated, endometrial sampling. Patients gave consent to surgery and possible transfusion of blood or blood products after receiving a detailed explanation, including

risks associated with anesthesia, laparoscopy, and all possible surgery complications.

Approval was exempted from the institute's Human Investigation Review Board since the study was not an experimental protocol, but a summary of outcomes of routine management. Indeed, a retrospective analysis was carried out, collecting data regarding patient characteristics (demographics, surgical history, physical examination findings, and indication for surgery), type of the procedure, total operating time, and other information related to surgery (like immediate intraoperative complications), pathology reports, duration of hospital stay, and immediate and long-term postoperative outcomes from hospital and outpatient records.

Intraoperative complications included: bleeding requiring transfusion; bladder, bowel, and ureteral injury; and unintended conversion to abdominal hysterectomy (AH).

Postoperative complications were classified as (A) major: hemorrhage requiring treatment, thrombosis, embolism, fistula formation, and reoperation within 8 weeks; or (B) minor: fever, infiltration of the vaginal vault (clinically palpable and painful mass or sonographically detected mass more than 4 cm without complaints), wound complications, and others (urinary tract infections).

Operative procedure

Surgical team

The FHT-TLH procedure requires two gynecologic surgeons with the same surgical experience, one on every side of the surgical field, with two couples of laparoscopic instruments active simultaneously. This means that we need four port insertions (beyond the classic umbilical one used for the camera), which must be placed to ensure an ergonomic position for surgeons during the procedure. In this way, the surgeons can interact with each other with automatic synergy in movements, making the procedure faster.

The camera assistant is an obstetrics/gynecology resident, who has the possibility to learn all the steps of the procedure and its anatomic logic in that way. After this training, novice laparoscopists get used to handle instruments and practice with the two-dimensional visual system and eye–hand coordination on the surgical monitor.

Finally, even the role of the scrub nurse is not canonical since, beyond having the technical skills for using instruments and equipment, he is entrusted with the movements of the manipulator, which is a task performed by a medical doctor in a classic TLH procedure.

Surgical technique

Operating room equipment and laparoscopic instruments are the same as all TLHs described in literature.

After administration of antibiotic prophylaxis with cefazolin 2 g, the patient is conducted in the operating room and positioned on the operating table appropriately to nonobstruct the surgeon's movements and to avoid neurological injuries. During this procedure, the pronated arms should be positioned along the body or form an angle $<90^\circ$ with the operating table to avoid injuries to the brachial plexus. On the other hand, the lithotomy position of the lower limbs guarantees to avoid damage to the femoral cutaneous, femoral, sciatic, obturator, and peroneal superficial nerves.

After administering general anesthesia through endotracheal intubation, disinfection of the surgical field is performed as usual. Then, a 14/18 G Foley catheter is inserted into the bladder and a RUMI manipulator (Medical Equipment Export LLC, Seneca, SC, USA) is stabilized into the uterus [Figure 1]. We do not use other manipulator types while performing FHT-TLH.

Umbilical entry is the first surgical step and it is performed with the direct entry technique "open laparoscopy." It happens before putting the operating table in Trendelenburg position, to avoid major vessel injuries. A 2-cm skin incision is usually made in the deepest part of the umbilicus, from its lower margin toward the pubis. When the uterus is large, we use to incise the umbilicus from its upper margin toward the patient's head to allow better visualization of the operating field. Placed the primary 10-mm Hasson trocar, which will host the camera, we insufflate CO_2 into the intraperitoneal cavity, so creating an immediate pneumoperitoneum.

The second step is to insert a number of secondary ports adequate to the surgical procedure we choose to adopt.^[7] In our FHT-TLH, both the first and the second surgeons use two laparoscopic instruments; hence, they need four secondary port insertions. Two of them, one on each side, are made on an imaginary line that connects the anterior superior iliac spine to the umbilicus, at 3 cm from the spine, along cutaneous Langer's lines. Two other ports, one on each side, are placed 8 cm from the umbilical entry, just above the transverse umbilical line. The inferior left access is about 1 cm, to allow

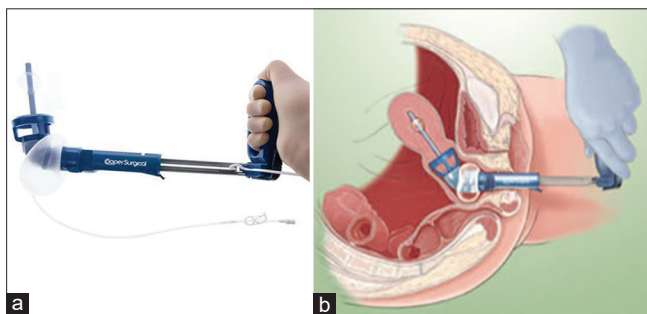


Figure 1: (a) RUMI manipulator; (b) RUMI manipulator insertion into the uterus

a trocar insertion suited both for anatomic pieces extraction and suture-needles insertion; the others are about 0.5 cm. Trocars are placed under endoscopic vision modulating the direction in accordance with the distance between the abdominal wall and organs and remaining as perpendicular to the abdominal wall as possible. The exact location of the inferior epigastric vessel must be checked before trocar insertion to avoid injuries and bothersome bleeding. This arrangement of the trocars ensures an ergonomic position for surgeons during the procedure, and interference among instruments is avoided [Figure 2].

From this point on, the TLH procedure is carried out according to classic surgical times, with the advantage that, thanks to this novel arrangement of the trocars, the two surgeons are alternately, mutually, and symmetrically the first operator and assistant. They can interact with each other bringing automatic synergy in movements, with the consequent faster procedure execution. As we already described the subsequent surgical steps in our previous article,^[6] they will not be discussed in detail here.

At the end of surgery, we perform a routine chromocystoscopy. The specimens are sent for pathological investigation. After extubation, the patient is moved to the recovery room. According to ERAS Society indications, it is very important to minimize nausea and vomiting after the surgery, with an early and appropriate control of postoperative pain.^[8] Patient hemoglobin levels are checked preoperatively and at 6 h and on the 2nd day after surgery. If the patient recovers properly in the early hours, a fast-track protocol is applied: it allows an early mobilization with spontaneous diuresis after bladder catheter removal and lastly a discharge 2 days after surgery with strict postoperative recommendations. All patients are evaluated clinically and by ultrasonography on the day of discharge.

RESULTS

Out of the initial 865 patients assessed for eligibility, a total of 750 patients were ultimately included in the study and underwent TLH (with or without adnexectomy) performed with FHT. The flowchart illustrating the patient selection process is presented in Figure 3.

The mean skin-to-skin operative time for a FHT-TLH was 50 min (excluding chromocystoscopic time), and the mean blood loss was 150 mL. No visceral damage was caused during operations. Only two patients underwent exploratory laparotomy with total AH due to the inability to proceed laparoscopically. Nonsteroidal anti-inflammatory drugs (NSAIDs) were administered only twice a day as analgesics, with benefit. Patients recovered correctly in the first 3 h after surgery with early mobilization; hence, the mean length of

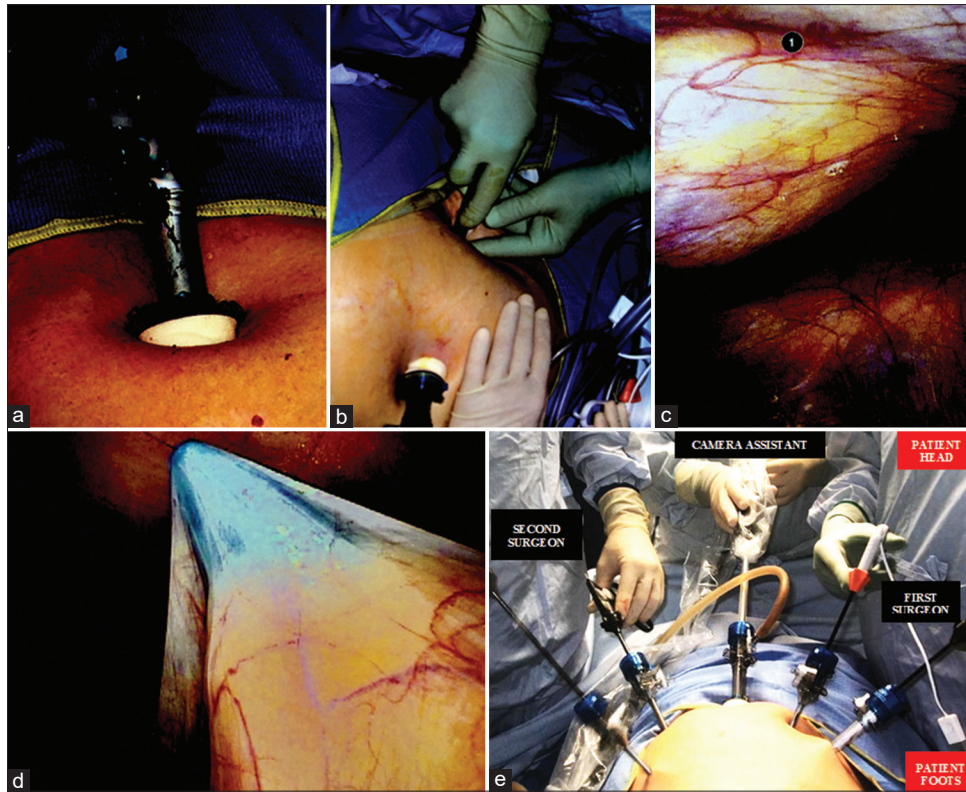


Figure 2: (a-d) Port insertion in the four-handed technique – total laparoscopic hysterectomy; (e) Final result and disposition of the operators

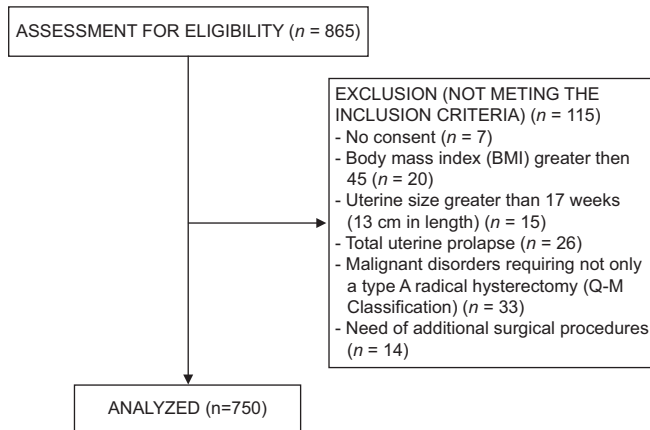


Figure 3: The flowchart displays the patient selection process

stay in the hospital after the procedure was 1.5 days, with discharge on the evening of the 1st day after surgery. No major postoperative complications occurred. Pyrexia was not described in any case after TLH, and the only minor postoperative complication described, in just three patients, was cellulitis of the vaginal vault, treated with antibiotic therapy and regressed.

DISCUSSION

Hysterectomy is the most common gynecological surgical procedure performed on women. There are three popular approaches to hysterectomy for benign disease: AH, VH, and

LH. Recently, robotic hysterectomy has also been introduced in this wide field, but it is not widely practiced yet. LH has three further subdivisions: (1) LAVH, where a VH is assisted by laparoscopic procedures that do not include uterine artery ligation; (2) LH where the laparoscopic procedures include uterine artery ligation; and (3) TLH where there is no vaginal component and the vaginal vault is sutured laparoscopically.^[9,10] Over time, TLH has become more and more practiced, thanks to many surgical advantages related to laparoscopy, particularly magnification of anatomy and pathology, access to the uterine vessels, vagina, and rectum, the ability to achieve complete hemostasis and clot evacuation, and all patient advantages related to avoidance of a painful abdominal incision, which include faster recovery, reduced duration of hospitalization, and an extremely low rate of infection and ileus.^[1-4]

Total duration of surgery

In TLH, operating time is usually assessed from initial skin incision for primary trocar to final skin closure. We have recorded a mean operating time of about 50 min (±9). This seems to be a better result than those we found in most literature when the TLH traditional procedure was performed.^[11-16]

Mean blood loss

Intraoperative blood during TLH is usually quantified by measuring the amount of fluid in the suction machine and then subtracting the amount of irrigation solution used. Our

patients who underwent FHT-TLH had a mean blood loss of 150 mL (± 70). Several studies about classic TLH procedure reported worse results compared to ours.^[11,14]

Intraoperative complications

The complication rate of 1%–2% is acceptable in the hands of laparoscopically trained surgeons^[17-19] and is usually due to adhesions in patients with previous cesarean and abdominal surgery. Urinary tract injury (bladder and ureter) is the most common visceral injury encountered in laparoscopic hysterectomies. In particular, the ureteric injury is usually a consequence of a badly done uterine artery ligation, especially if the surgeon is unskilled. Bowel injury is rare and is usually a thermal injury. In the present study, no visceral damage was caused and no major intraoperative complications occurred. We have to report only two cases of conversion to laparotomy with subsequent total or radical AH due to the inability to proceed laparoscopically. As far as we know, several studies documented higher rates of conversion, such as Park's retrospective study^[20] in which 288 patients underwent traditional TLH with a rate of conversion to laparotomy was 8%.

Postoperative complications

The most common complications after LH have been categorized by Clarke-Pearson and Geller^[21] as infectious, venous thromboembolic, hemorrhagic, nerve injury, genitourinary, gastrointestinal, and vaginal cuff dehiscence. According to their study, infectious complications after hysterectomy are the most common, ranging 9.0% for traditional TLH. The most common infections include vaginal cuff cellulitis, infected hematoma or abscess, wound infection, urinary tract infection, respiratory infection, and febrile morbidity. In particular, vaginal cuff cellulitis, a unique complication to this procedure, occurs late in the hospital course or soon after discharge and its incidence ranges from 0% to 8.3% after hysterectomy. Some of the main factors that may increase the risk for postoperative infection include hospitalization, operator experience, increased blood loss, operative time of more than 3 h,^[21] and some types of surgical sutures.^[22] Venous thromboembolism is less common, with a diagnosis rate ranging from 1% to 12%.^[21] Kallol Kumar Koy in his study^[14] described two UTIs, four vaginal bleedings, and two cases of fever after traditional TLH procedures. Instead, pyrexia was not described in any case after our FHT-TLH, and the only postoperative complication we reported, in just three patients, was cellulitis of the vaginal vault, treated with antibiotic therapy and regressed. The low complication rate in our cohort could also be due to the high surgical skills of all first surgeons.^[23]

Pain

Literature reports that the postoperative pain and analgesic requirement in laparoscopic surgeries may be lesser

compared to other hysterectomy routes,^[24,25] especially when ERAS protocol is applied.^[26] Opioids have a notorious side effect profile with acute postoperative side effects in the form of constipation, decreased bowel motility, ileus, nausea and vomiting, sedation, and delirium.^[27] Moreover, their exceeding use could create first tolerance and later dependence. These are the reasons why opioid-free analgesia is an important component of ERAS protocol: it enables early feeding and early discharge from the hospital in addition to a possible long-term role in dealing with the opioid dependence epidemic.^[28] As we already said, in this study, we applied the ERAS protocol, reporting a significantly reduced use of analgesics, with the only administration of NSAIDs twice a day. None of our patients required opioid analgesia, but it could be also related to our shorter surgical times.

Total hospital stay

Our FHT-TLH patients recovered correctly in the first 3 h after surgery with early mobilization; hence the mean length of stay in the hospital after the procedure was 1.5 days (± 1) with discharge on the evening of the 1st day after surgery. This represents a time shorter than those reported in literature in most cases (for example, the mean hospital stay for Kallol Kumar Roy's patients after TLH was 64 h^[14]).

We have to report that although traditionally TLH patients are discharged 1–2 days after surgery, recent literature supports the introduction of “day case TLH protocols,” but the process has not been adopted evenly throughout the world as far as we are aware. Same-day discharge rates vary considerably between studies: it is 40.3% in a systematic review including over 140,000 patients,^[29] whereas it reaches 99.8% in some American units performing TLH in outpatient clinics.^[30] Nensi *et al.*,^[31] who work in a health-care setting more similar to ours, demonstrated an 18.3% same-day discharge before the introduction of a “same-day discharge protocol following TLH,” which improved to 79.1% same-day discharge after the addition of the protocol, without recording significant differences in peri-operative complications, readmission rates, or patient satisfaction. Byford *et al.*^[32] also reported that the implementation of day case TLH protocol is feasible, safe, and well received by patients in their tertiary Australian hospital. These results are very interesting because of multiple possible effects in health care: the decrease in hospital costs, by reducing length of stay and overnight admission, and improved theater efficiency and patient flow while maintaining patient safety and satisfaction. This is much more fundamental in the COVID-19 era since the lack of inpatient beds in hospitals hinders elective surgery. Despite this, in our nation, inpatient admission following TLH is still considered standard care and those undergoing a TLH at our tertiary hospitals have to stay 1–2 days inpatient after surgery.

The learning curve of total laparoscopic hysterectomy

Virtual reality laparoscopy simulators and laparoscopy boxes are only some of the numerous methods introduced for teaching residents or inexperienced surgeons.^[33,34] Despite this, the operating room remains the best environment to acquire certain surgical tactile skills. Hence, virtual reality and other surgery teaching methods should only be considered as supplementary to or as preparation for operating in the surgery room.^[35] Since TLH became a well-standardized surgery used throughout the world and performed increasingly frequently in the last decades, it represents a great context for studying learning curves among surgeons.^[36-39] A recent retrospective analysis^[40] examined the development of surgical skills among surgeons learning TLH, using differences in complication rates between surgeons with different levels of experience and analyzing the development of individual operating times. All TLHs were performed by six inexperienced surgeons, accompanied by one skilled surgeon. The authors clearly showed that if an inexperienced surgeon is accompanied by an experienced one during a procedure, the complication rate does not differ between inexperienced and experienced surgeons. It represents an important safety message for patients. Furthermore, with growing numbers of procedures, most surgeons quickly became faster, leading to reduced operating times.^[40] In light of this, our experience with FHT-TLH seems to be a really good chance to learn surgery for young specialists and residents, who can be the first assistant in double with the first surgeon. Indeed, teacher and learner have both an active role in the surgical field and they are alternately, mutually, and symmetrically the first operator and assistant. Even being the second assistant involved with the camera is a great opportunity for young specialists and residents, since they can learn real intraoperative stereotaxis and the sequence of all surgical steps, familiarizing with the pelvic anatomy of the retroperitoneum. In our clinical practice, we noticed a marked reduction in learning times for the majority of residents who attend our operating room when executing FHT-TLH compared to the traditional laparoscopic route, especially when they were first assistants. This is intuitive, as while performing TLH with the novel FHT, the first assistant becomes alternately, mutually, and symmetrically the first operator, rather than be a more passive helper as it happens during the classical TLH route. All of these, extraordinarily, do not prolong the operating times, which are even shorter than the traditional way, as we showed.

It should also be considered that since making experience means reducing operating times, it also allows to reduce surgical costs; moreover, experience in laparoscopic surgery is of advantage to help overcome entry to robotic surgery, which will be more and more widespread.^[41-45]

CONCLUSIONS

The numerous benefits of an LH are widely proven in scientific literature. Our FHT-TLH experience represents an alternative to the traditional TLH route, with some advantages for patients compared to the traditional TLH route, such as early recovery and reduced operating time, blood loss, use of analgesics, and hospital stay. Moreover, it allows young specialists and residents to be more confident with gynecological laparoscopy and with pelvic anatomy of retroperitoneum, particularly when operating as the first assistant, to improve their laparoscopic surgical skills faster than the traditional TLH route allows them.

Author contributions

Pierpaolo Nicoli: Wrote the paper; Anna Biffi, Gregorio Del Boca: Surgeon and ideators of the surgical procedures; Amerigo Vitagliano, Erica Silvestris: Data review and control of references; Edoardo Di Naro, Ettore Cicinelli: Supervisors and review the paper; Vera Ioizzi: Imaging; Gianluca Raffaello Damiani: Principal investigator.

Data availability statement

The datasets generated during and/or analyzed during the current study are available from the corresponding author on reasonable request.

Financial support and sponsorship

Nil.

Conflicts of interest

There are no conflicts of interest.

REFERENCES

- Garry R. Laparoscopic hysterectomy-definitions and indications. *Gynaecol Endosc* 1994;3:1-3.
- Reich H, Roberts L. Laparoscopic hysterectomy in current gynecological practice. *Rev Gynaecol Pract* 2003;3:32-40.
- AAGL Advancing Minimally Invasive Gynecology Worldwide. AAGL position statement: Route of hysterectomy to treat benign uterine disease. *J Minim Invasive Gynecol* 2011;18:1-3.
- Aarts JW, Nieboer TE, Johnson N, Tavender E, Garry R, Mol BW, *et al.* Surgical approach to hysterectomy for benign gynaecological disease. *Cochrane Database Syst Rev* 2015;2015:CD003677.
- Mettler L, Ahmed-Ebbiary N, Schollmeyer T. Laparoscopic hysterectomy: Challenges and limitations. *Minim Invasive Ther Allied Technol* 2005;14:145-59.
- Del Boca G, Damiani GR, Zagni R, Guglielmi D, Malvasi A, Vimercati A, *et al.* Total laparoscopic hysterectomy four-handed ergonomic technique: Description of an original surgical procedure for the reduction of learning curve. *Minerva Obstet Gynecol* 2023;75:298-306.
- Grigoriadis G, Mumdzjans A. Trocar configuration in laparoscopic hysterectomy for benign indications. *Gynecol Minim Invasive Ther* 2021;10:137-42.
- Bajsova S, Klát J. ERAS protocol in gynecologic oncology. *Ceska Gynecol* 2019;84:376-85.
- Nieboer TE, Johnson N, Lethaby A, Tavender E, Curr E, Garry R, *et al.* Surgical approach to hysterectomy for benign gynaecological disease. *Cochrane Database Syst Rev* 2009;(3):CD003677. doi: 10.1002/14651858.CD003677.pub4. Update in: *Cochrane Database Syst Rev* 2015;8:CD003677. PMID: 19588344.

10. Kanti V, Verma V, Singh M, Vishwakarma S, Mittal N, Singh NP. A comparative analysis of nondescent vaginal hysterectomy, laparoscopy-assisted vaginal hysterectomy, and total laparoscopic hysterectomy for benign uterine diseases at a rural tertiary care center. *Gynecol Minim Invasive Ther* 2022;11:164-70.
11. Long CY, Fang JH, Chen WC, Su JH, Hsu SC. Comparison of total laparoscopic hysterectomy and laparoscopically assisted vaginal hysterectomy. *Gynecol Obstet Invest* 2002;53:214-9.
12. Schindlbeck C, Klauser K, Dian D, Janni W, Friese K. Comparison of total laparoscopic, vaginal and abdominal hysterectomy. *Arch Gynecol Obstet* 2008;277:331-7.
13. Matteson KA, Phipps MG, Raker C, Sacco LJ, Jackson AL. Discussion: 'Laparoscopic versus vaginal hysterectomy for benign pathology' by Candiani *et al.* *Am J Obstet Gynecol* 2009;200:e1-6.
14. Roy KK, Goyal M, Singla S, Sharma JB, Malhotra N, Kumar S. A prospective randomised study of total laparoscopic hysterectomy, laparoscopically assisted vaginal hysterectomy and non-descent vaginal hysterectomy for the of benign diseases of the uterus. *Arch Gynecol Obstet* 2011;284:907-12.
15. Allam IS, Makled AK, Gomaa IA, El-Bishry GM, Bayoumy HA, Ali DF. Total laparoscopic hysterectomy, vaginal hysterectomy and total abdominal hysterectomy using electrosurgical bipolar vessel sealing technique: A randomized controlled trial. *Arch Gynecol Obstet* 2015;291:1341-5.
16. Bettaiah R, Reddy CA. Laparoscopic hysterectomies: Our 10 years experience in a single laparoscopic center. *J Obstet Gynaecol India* 2016;66:274-81.
17. Canis MJ, Wattiez A, Mage G, Bruhat MA. Results of evaluate study of hysterectomy techniques: Laparoscopic hysterectomy may yet have a bright future. *BMJ* 2004;328:642-3.
18. Thiel F, Renner S, Oppelt P, Ackermann S, Binder H, Beckmann MW, *et al.* Establishment of total laparoscopic hysterectomy (TLH) in a university gynecology department: Results of the first 100 operations. *Geburtshilfe Frauenheilkd* 2006;66:665-9.
19. Takahashi A, Uemura M, Kitazawa J, Nakata M, Hayashi Y. Laparoscopic hysterectomy for benign pathology does not yield more perioperative complications than abdominal or vaginal hysterectomies: Our experience in introducing laparoscopic hysterectomy. *Gynecol Minim Invasive Ther* 2020;9:215-9.
20. Park SH, Cho HY, Kim HB. Factors determining conversion to laparotomy in patients undergoing total laparoscopic hysterectomy. *Gynecol Obstet Invest* 2011;71:193-7.
21. Clarke-Pearson DL, Geller EJ. Complications of hysterectomy. *Obstet Gynecol* 2013;121:654-73.
22. Talwar P, Velayudam L, Hemapriya L, Patil S. Barbed suture in total laparoscopic hysterectomy: A comparative study of the safety in vaginal cuff closure with that of polyglactin 910 suture. *Gynecol Minim Invasive Ther* 2021;10:154-8.
23. Balasubramaniam D, Ravi S, Yogini K. Giant nabothian cyst mimicking a huge cervical fibroid: Challenging aspects in laparoscopic hysterectomy. *Gynecol Minim Invasive Ther* 2022;11:64-6.
24. Soriano D, Goldstein A, Lecuru F, Daraí E. Recovery from vaginal hysterectomy compared with laparoscopy-assisted vaginal hysterectomy: A prospective, randomized, multicenter study. *Acta Obstet Gynecol Scand* 2001;80:337-41.
25. Nascimento MC, Kelley A, Martitsch C, Weidner I, Obermair A. Postoperative analgesic requirements – Total laparoscopic hysterectomy versus vaginal hysterectomy. *Aust N Z J Obstet Gynaecol* 2005;45:140-3.
26. Inania M, Sharma P, Parikh M. Role of enhanced recovery after surgery in total laparoscopic hysterectomy. *J Minim Access Surg* 2022;18:186-90.
27. American Society of Anesthesiologists Task Force on Acute Pain Management. Practice guidelines for acute pain management in the perioperative setting: An updated report by the American Society of Anesthesiologists Task Force on Acute Pain Management. *Anesthesiology* 2012;116:248-73.
28. Kamdar NV, Hoffman N, Rahman S, Cannesson M. Opioid-free analgesia in the era of enhanced recovery after surgery and the surgical home: Implications for postoperative outcomes and population health. *Anesth Analg* 2017;125:1089-91.
29. Dedden SJ, Geomini PM, Huirne JA, Bongers MY. Vaginal and laparoscopic hysterectomy as an outpatient procedure: A systematic review. *Eur J Obstet Gynecol Reprod Biol* 2017;216:212-23.
30. Ribot HD. Outpatient total hysterectomy in the freestanding ASC setting and #x2013; experience with 819 consecutive cases. *J Minim Invasive Gynecol* 2017;24:S94-5.
31. Nensi A, Coll-Black M, Leyland N, Sobel ML. Implementation of a same-day discharge protocol following total laparoscopic hysterectomy. *J Obstet Gynaecol Can* 2018;40:29-35.
32. Byford S, Madhok D, Baldan P, Amey G, Barber J, Harris R, *et al.* Introduction of the day case total laparoscopic hysterectomy (TLH) protocol. *Aust N Z J Obstet Gynaecol* 2022;62:881-6.
33. Clevin L, Grantcharov TP. Does box model training improve surgical dexterity and economy of movement during virtual reality laparoscopy? A randomised trial. *Acta Obstet Gynecol Scand* 2008;87:99-103.
34. Mohammadi Y, Lerner MA, Sethi AS, Sundaram CP. Comparison of laparoscopy training using the box trainer versus the virtual trainer. *JLS* 2010;14:205-12.
35. Papandria D, Rhee D, Ortega G, Zhang Y, Gorgy A, Makary MA, *et al.* Assessing trainee impact on operative time for common general surgical procedures in ACS-NSQIP. *J Surg Educ* 2012;69:149-55.
36. Müller A, Thiel FC, Renner SP, Winkler M, Häberle L, Beckmann MW. Hysterectomy – A comparison of approaches. *Dtsch Arztebl Int* 2010;107:353-9.
37. Jokinen E, Brummer T, Jalkanen J, Fraser J, Heikkinen AM, Mäkinen J, *et al.* Hysterectomies in Finland in 1990-2012: Comparison of outcomes between trainees and specialists. *Acta Obstet Gynecol Scand* 2015;94:701-7.
38. Terzi H, Biler A, Demirtas O, Guler OT, Peker N, Kale A. Total laparoscopic hysterectomy: Analysis of the surgical learning curve in benign conditions. *Int J Surg* 2016;35:51-7.
39. Biyik I, Albayrak M, Keskin F, Mut ANU. The learning curve of total laparoscopic hysterectomy in a rural hospital. *Gynecol Obstet Reprod Med* 2020;26:134-9.
40. Schützendübel M, Boosz A, Baev E, Häberle L, Müller A. Learning laparoscopic hysterectomy: Analysis of different surgeons' individual learning curves. *Arch Gynecol Obstet* 2023;307:1065-72.
41. Wright JD, Lewin SN, Deutsch I, Burke WM, Sun X, Herzog TJ. Effect of surgical volume on morbidity and mortality of abdominal hysterectomy for endometrial cancer. *Obstet Gynecol* 2011;117:1051-9.
42. Reynolds RK, Advincula AP. Robot-assisted laparoscopic hysterectomy: Technique and initial experience. *Am J Surg* 2006;191:555-60.
43. Pellegrino A, Damiani GR, Fachechi G, Pirovano C, Gaetani M, Youssef A. Cost analysis of minimally invasive radical hysterectomy for cervical cancer performed by a single surgeon in an Italian center: An update in gynecologic oncological field. *Updates Surg* 2017;69:517-22.
44. Pellegrino A, Damiani GR, Fachechi G, Corso S, Pirovano C, Trio C, *et al.* Cost analysis of minimally invasive hysterectomy versus open approach performed by a single surgeon in an Italian center. *J Robot Surg* 2017;11:115-21.
45. Pellegrino A, Damiani GR, Loverro M, Pirovano C, Fachechi G, Corso S, *et al.* Comparison of robotic and laparoscopic radical type-B and C hysterectomy for cervical cancer: Long term-outcomes. *Acta Biomed* 2017;88:289-96.