

Erythema multiforme in a young adult following COVID-19 infection and vaccination in Tanzania

Karim Premji Manji ¹, George Mwaniki,² Alma Abu Simba,³ Julie Makani⁴

¹Pediatrics and Child Health, Muhimbili University of Health and Allied Sciences, Dar es Salaam, Tanzania

²Family Medicine, Premier Care Clinic and Pharmacy, Dar es Salaam, Tanzania

³History, University of Dar es Salaam, Dar es Salaam, Tanzania

⁴Haematology, Muhimbili University of Health and Allied Sciences, Dar es Salaam, Tanzania

Correspondence to

Professor Karim Premji Manji; kpremanji@gmail.com

Accepted 12 May 2022

SUMMARY

We report the case of a young female adult in her early 20s, who had COVID-19 infection for 8 weeks and COVID-19 vaccination 4 weeks prior to presentation with an extensive rash associated with erythema multiforme, resembling varicella zoster on initial presentation. After initial acyclovir therapy with no improvement, systemic corticosteroid treatment dramatically resolved the patient's skin rash.

BACKGROUND

COVID-19 has protean manifestations. Knowledge of cutaneous COVID-19 manifestations is still evolving, especially in a country like ours that has a low disease burden and minimal public health measures to mitigate the COVID-19 pandemic. This report is important for highlighting and raising awareness regarding the heterogeneity of the clinical presentation of COVID-19, and the heterogeneity of responses to COVID-19 vaccination.

CASE PRESENTATION

We report the case of a healthy, young female adult in her early 20s with no comorbidities.

The patient tested positive for COVID-19 and 2 weeks later she tested negative by reverse transcriptase (RT)-PCR, despite still having some symptoms. During the interim period, she experienced post-COVID-19 symptoms, such as fatigue, breathlessness, headaches, body soreness and low mood.

Eight weeks after the initial COVID-19 positive test, she received the Janssen COVID-19 vaccine (also known as Johnson & Johnson) at a designated health facility in Dar es Salaam. This vaccine has been advocated in Tanzania since 3 August 2021. Within 24 hours following vaccination, she started experiencing symptoms of severe nausea, body soreness and fatigue.

Two weeks later, she developed a skin rash ([figure 1A](#)), which was initially diagnosed as a fungal infection. The patient had travelled very briefly to a natural rainforest 3 days prior to the onset of these rashes.

On the third week post-vaccination, she developed face and neck rashes, and rashes in the abdomen and genital area. These were vesicular, at places bullous, and increasingly itchy ([figure 1B](#)). For the subsequent 2–3 days, the rashes increased in number and were associated with significant itch, pain and discomfort ([figure 2](#)). The patient had not been exposed to any common medicine associated with such rashes, such as carbamazepine, hydroxychloroquine, isoniazid or sulfonamides.

On the fourth week post-vaccination and second week from the onset of rashes, the patient experienced excruciating pain on touch all over the body rashes, including in her palms and soles, and major discomfort on contact with water, clothing, etc. The rashes were intensely pruritic. The maculo-papular rashes were erythematous, some scaly, with central dark areas and irregular margins ([figures 3 and 4](#)). Moreover, the rashes on her hands and soles were sore.

Laboratory tests were suggestive of a viral infection, because the patient's lymphocyte count was elevated. Following a second review, a differential diagnosis of possible varicella infection was made, and blood was taken to test for varicella infection. This test was sent to India with a turnaround time of 2 weeks. In the meantime and while awaiting for the results, the patient was treated with acyclovir 800 mg every 8 hours, an antihistamine and topical calamine lotion.

On the fifth and sixth week post-vaccination, the patient's symptoms worsened. Yellowish serous discharge was observed coming out from some rashes. Bleeding was observed from her gums, and extensive sores were present on her palms and soles. Some sores had blistered open and were sensitive. The cutaneous lesions were associated with generalised body pain, dry mouth and significant insomnia.

A clinical diagnosis of erythema multiforme was made, and the patient was treated with prednisolone for 5 days. A significant relief was observed following prednisolone treatment, with cessation of new lesions. The patient's skin became dry and started peeling ([figure 5A,B](#)), although the itchiness persisted for a while longer. The fever, extreme exhaustion and body pain started to resolve around the 10th week post-vaccination.

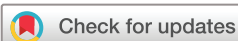INVESTIGATIONS

Laboratory tests:

- ▶ Complete blood count: increased lymphocytes at presentation, normal neutrophil counts.
- ▶ C reactive protein was raised to 42 IU (normal: 0–10 IU) on the fifth week.
- ▶ Varicella antibodies were raised: IgG levels of 1757.00 mIU/mL (normal: <150 mIU/mL).
- ▶ IgE levels were normal.
- ▶ Additional tests such as D-dimer, ferritin and lactate dehydrogenase were not performed.

DIFFERENTIAL DIAGNOSIS

Mucocutaneous drug eruption or Stevens-Johnson syndrome was unlikely because there were no



© BMJ Publishing Group Limited 2022. No commercial re-use. See rights and permissions. Published by BMJ.

To cite: Manji KP, Mwaniki G, Simba AA, et al. *BMJ Case Rep* 2022;**15**:e247168. doi:10.1136/bcr-2021-247168

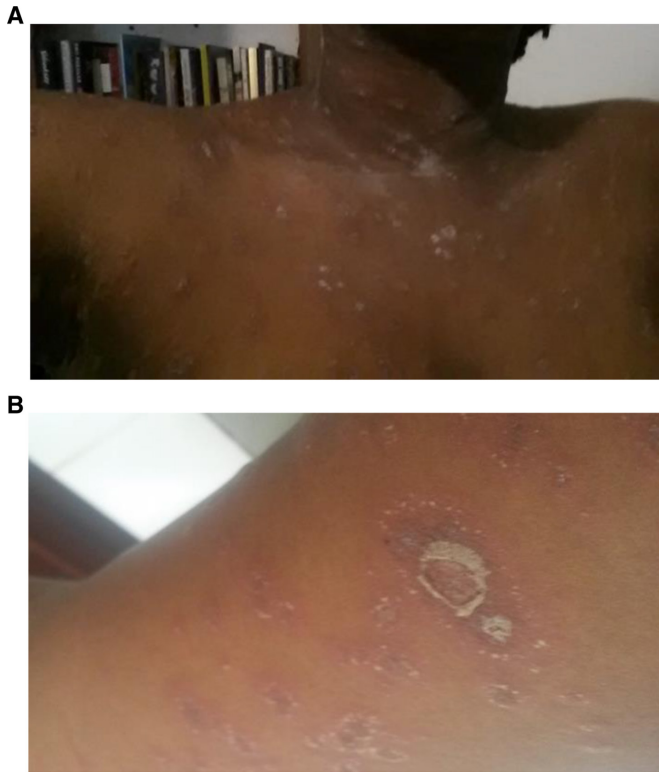

Figure 1 (A) Rashes initially misdiagnosed as a fungal infection. (B) Worsening at some areas, forming vesicles and appear bullous.

obvious mucocutaneous lesions and the urine output remained normal.

Likewise, the visit to the natural rainforest was brief, and the onset of rashes of this type is not related to any acute exposure.

TREATMENT

The treating physician prescribed acyclovir for viral exanthem, followed by treatment with prednisolone for 5 days, and with Celestamine (betamethasone 0.25 mg and dexchlorpheniramine maleate 2 mg, an anti-inflammatory and anti-allergic combination) for 10 days.

OUTCOME AND FOLLOW-UP

The patient experienced a full recovery. The lesions resolved with desquamation and mild itchiness.

DISCUSSION

To the best of our knowledge, this is the first case of erythema multiforme reported in a young, healthy African woman in Tanzania, following COVID-19 infection and vaccination. On inquiry though, several physicians treating patients with COVID-19 have mentioned that they anecdotally see increased cutaneous manifestations in patients with COVID-19, and scientists from other countries have also reported such manifestations.¹⁻⁶

These cutaneous features may be the result of exaggerated cytokine responses (cytokine storms), resulting in erythema multiforme. This has previously been reported.¹⁻⁵ The varicella infection (which was confirmed by the attending physician due to a raised IgG antibody titre) in our view was coincidental and unrelated to the erythema multiforme, since only IgG antibodies were observed but not IgM. In our view,

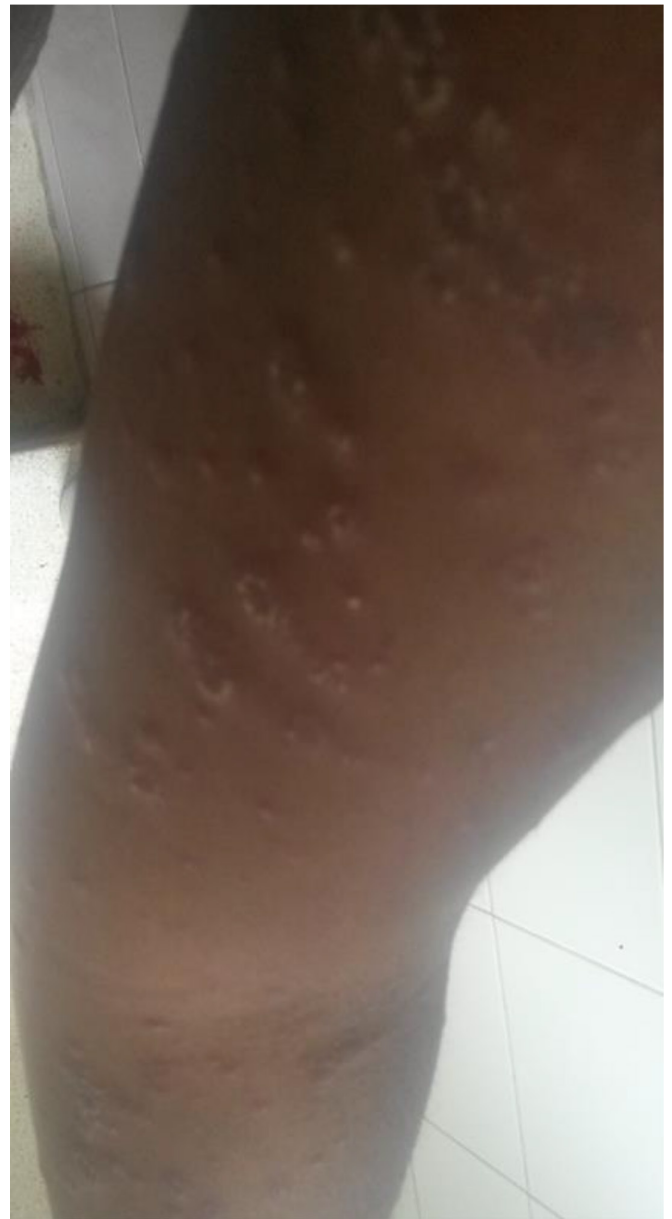

Figure 2 Worsening of the rash and spreading to other areas in the back and thighs.

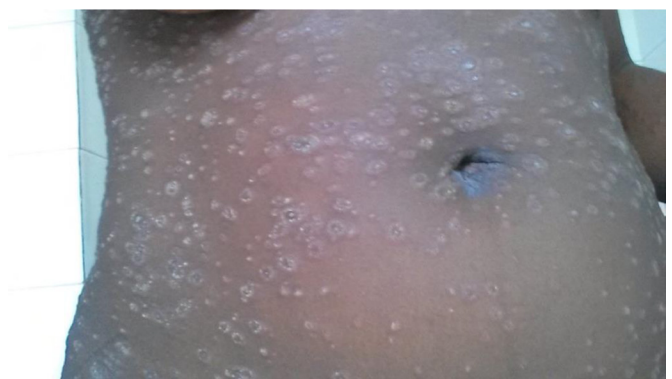

Figure 3 Widespread, central darkening, maculo-papular (and painful) rashes.

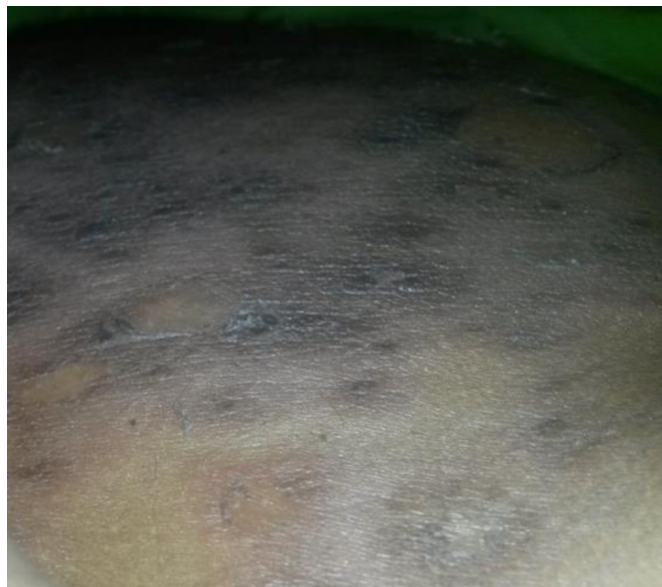

Figure 4 At some areas, the lesions were necrotic dark patches.

the erythema multiforme was caused by the COVID-19 infection and vaccination.

We are presenting this case in order to highlight the importance of potential skin manifestations related to COVID-19 infection/vaccination. The protean manifestations of COVID-19 and its associated vaccine should raise a high index of suspicion. Tanzania has had a low burden of COVID-19 infections. Furthermore, although active public

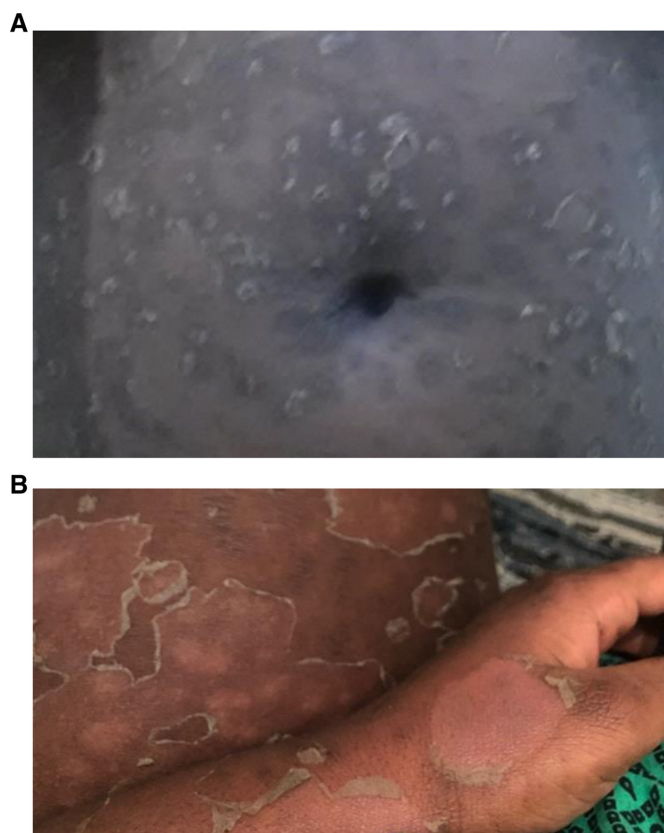


Figure 5 (A,B) Healing with extensive exfoliation of skin in the abdomen, thigh and hand. The authors created all figures.

health measures such as wearing face masks and hand washing were put in place, there has been suboptimal testing, and the political decision was not to impose lockdown measures that may have led to deleterious socioeconomic consequences.

The COVID-19 testing is still an arduous task for patients, although measures for travel-related testing are well outlined. Furthermore, COVID-19 vaccination in Tanzania only started in August 2021. The clear guidance for recent symptomatic individuals with COVID-19 to refrain from COVID-19 vaccination for at least 12 weeks after symptoms so that they reduce the potential of developing vaccine-related eruption of papules and plaques needs to be kept in mind.^{6–8} The Janssen COVID-19 vaccine, also known as the Johnson & Johnson vaccine, can be given to any person who have had prior COVID-19 infection, if they have recovered and they are free of symptoms. Research has consistently shown that previously infected and recovered individuals mount sufficient immune response to vaccination. Therefore, the Centre for Disease control recommends waiting until the individual is asymptomatic beyond the period of isolation.^{7,8}

Several cases of erythema multiforme following SARS-CoV-2 vaccine have been described in the literature, but none of these cases have been linked to a recent COVID-19 infection and

Patient's perspective

At first, I thought this could be measles or allergies. When the rash spread, it started causing painful lesions on my palms and soles, and raised bumps which were not only painful but itchy. At that time I panicked and I visited three doctors, before meeting my long-time paediatrician who finally diagnosed my condition from my history and clinical findings. The diagnoses of all the three doctors I visited differed, and this was stressful for me. I was also scared of being contagious and passing my condition to my grandparents and family members. I also wished the pain had resolved faster.

Learning points

- ▶ The findings of pernio and chilblain-like macular, pruritic, erythematous lesions, with central darkening and scaling, and with some pustular satellites, are typical of erythema multiforme. These occurred 8 weeks post-COVID-19 infection and 4 weeks post-vaccination with the COVID-19 Johnson & Johnson vaccine. There was raised C reactive protein, a biomarker commonly seen elevated in COVID-19-infected individuals.
- ▶ The appearance of these rashes was seen 2–4 weeks post-COVID-19 infection, and there was no history of use of any known drug which can be associated with such eruptions (such as hydroxychloroquine, carbamazepine, sulfonamides).
- ▶ The patient experienced persistent systemic symptoms such as nausea, weakness, body pain, numbness and exhaustion for more than 6 weeks. These resolved after a short course of prednisolone.
- ▶ The onset after COVID-19 infection may also indicate multisystem inflammatory syndrome (post-COVID-19), although not all biomarkers were tested. Moreover, this is more frequently reported in children.
- ▶ COVID-19 vaccination should be postponed for at least 12 weeks post-infection.

to the Janssen vaccine. Most of published and peer-reviewed cases were about the Pfizer BioNTech (BNT162b2) COVID-19 vaccine, and only two reports described CoronaVac or mRNA-1273 SARS-CoV-2 vaccine.^{9–15} This makes our report important for the purpose of increased surveillance among those who have access to the Janssen vaccine.

Although the initial suspicion for this patient was a varicella-like eruption, we saw that the clinical course and healing was that of erythema multiforme. There is scarce literature on potential reactivation of varicella zoster infection following COVID-19 vaccination, and this possibility can be coexisting in our patient.¹⁶

Six major recognised forms of skin manifestations in COVID-19 have been described by Genovese *et al*,¹⁷ but erythema multiforme has been rarely described.^{2–5}

Finally, the patient had travelled to a natural forest reserve, and it might be the reason that she developed a rare tropical condition. However, from a clinical point of view, she had no signs and symptoms of any dermatological condition, and all the patient's symptoms started soon after receiving the Janssen vaccine.

Contributors KPM diagnosed the patient, researched literature, prepared the initial manuscript, revised and incorporated all suggestions by coauthors. He submitted the final manuscript. GM provided relevant information on progress, reviewed the initial and final manuscript and made edits as appropriate. AAS is the patient advocate who provided inputs on progress, reviewed and accepted the final manuscript. JM provided support in revising the manuscript and its scientific content, and revised the final manuscript.

Funding The authors have not declared a specific grant for this research from any funding agency in the public, commercial or not-for-profit sectors.

Competing interests None declared.

Patient consent for publication Obtained.

Provenance and peer review Not commissioned; externally peer reviewed.

Case reports provide a valuable learning resource for the scientific community and can indicate areas of interest for future research. They should not be used in isolation to guide treatment choices or public health policy.

ORCID iD

Karim Premji Manji <http://orcid.org/0000-0002-7069-6408>

REFERENCES

- Bennardo L, Nisticò SP, Dastoli S, *et al*. Erythema multiforme and COVID-19: what do we know? *Medicina* 2021;57. doi:10.3390/medicina57080828. [Epub ahead of print: 16 Aug 2021].
- Jimenez-Cauhe J, Ortega-Quijano D, Carretero-Barrio I, *et al*. Erythema multiforme-like eruption in patients with COVID-19 infection: clinical and histological findings. *Clin Exp Dermatol* 2020;45:892–5.
- Rahimi H, Tehranchinia Z. A comprehensive review of cutaneous manifestations associated with COVID-19. *Biomed Res Int* 2020;2020:1236520
- Conforti C, Dianzani C, Agozzino M, *et al*. Cutaneous manifestations in confirmed COVID-19 patients: a systematic review. *Biology* 2020;9. doi:10.3390/biology9120449. [Epub ahead of print: 05 Dec 2020].
- Henderson LA, Canna SW, Friedman KG, *et al*. American College of rheumatology clinical guidance for multisystem inflammatory syndrome in children associated with SARS-CoV-2 and Hyperinflammation in pediatric COVID-19: version 1. *Arthritis Rheumatol* 2020;72:1791–805.
- McMahon DE, Kovarik CL, Damsky W, *et al*. Clinical and pathologic correlation of cutaneous COVID-19 vaccine reactions including V-REPP: a registry-based study. *J Am Acad Dermatol* 2022;86:113–21.
- Sadoff J, Gray G, Vandebosch A, *et al*. Safety and efficacy of single-dose Ad26.COV2.S vaccine against Covid-19. *N Engl J Med* 2021;384:2187–201. doi:10.1056/NEJMoa2101544
- Centers for disease control and prevention (CDC): summary document for interim clinical considerations for use of COVID-19 vaccines currently authorized in the United States. Available: <https://www.cdc.gov/vaccines/covid-19/clinical-considerations/covid-19-vaccines-us.html#CoV-19-vaccination> [Accessed 21 Dec 2021].
- Lavery MJ, Nawimana S, Parslew R, *et al*. A flare of pre-existing erythema multiforme following BNT162b2 (Pfizer-BioNTech) COVID-19 vaccine. *Clin Exp Dermatol* 2021;46:1325–7.
- Buján Bonino C, Moreiras Arias N, López-Pardo Rico M, Pita da Veiga Seijo G, Rosón López E, Suárez Peñaranda JM, *et al*. atypical erythema multiforme related to BNT162b2 (Pfizer-BioNTech) COVID-19 vaccine. *Int J Dermatol* 2021;60:e466–7.
- Kim MJ, Kim JW, Kim MS, *et al*. Generalized erythema multiforme-like skin rash following the first dose of COVID-19 vaccine (Pfizer-BioNTech). *J Eur Acad Dermatol Venereol* 2022;36:e98–100.
- Lopes NT, Pinilla CEO, Gerbase AC. Erythema multiforme after CoronaVac vaccination. *J Eur Acad Dermatol Venereol* 2021;35:e717–9.
- Gambichler T, Scholl L, Ocker L. Prompt onset of erythema multiforme following the first BNT162b2 SARS-CoV-2 vaccination. *J Eur Acad of Dermatol Venereol* 2021;35:e415.
- Saibene AM, Alliata A, Cozzi AT, *et al*. Erythema multiforme major following SARS-CoV-2 vaccine. *Clin Case Rep* 2021;9:e04947.
- Wunderlich K, Dirschka T. [Erythema multiforme following COVID-19 vaccination (BNT162b2)]. *Hautarzt* 2022;73:68–70.
- Nanova K, Zlotogorski A, Ramot Y. Recurrent varicella following SARS-CoV-2 vaccination with BNT162b2. *Int J Dermatol* 2021;60:1148–9.
- Genovese G, Moltrasio C, Berti E, *et al*. Skin manifestations associated with COVID-19: current knowledge and future perspectives. *Dermatology* 2021;237:1–12.

Copyright 2022 BMJ Publishing Group. All rights reserved. For permission to reuse any of this content visit <https://www.bmj.com/company/products-services/rights-and-licensing/permissions/>
BMJ Case Report Fellows may re-use this article for personal use and teaching without any further permission.

Become a Fellow of BMJ Case Reports today and you can:

- ▶ Submit as many cases as you like
- ▶ Enjoy fast sympathetic peer review and rapid publication of accepted articles
- ▶ Access all the published articles
- ▶ Re-use any of the published material for personal use and teaching without further permission

Customer Service

If you have any further queries about your subscription, please contact our customer services team on +44 (0) 207111 1105 or via email at support@bmj.com.

Visit casereports.bmj.com for more articles like this and to become a Fellow