



# Correlation between adenoidal nasopharyngeal ratio and symptoms of enlarged adenoids in children with adenoidal hypertrophy

Taiwo Olugbemiga Adedeji, Yemisi B. Amusa<sup>1</sup>, Ademola A. Aremu<sup>2</sup>

## ABSTRACT

**Background:** Adenoid hypertrophy is one of the most common health problems affecting the paediatric population. This study aims to correlate adenoidal nasopharyngeal ratio (ANR) with symptoms of enlarged adenoids in children with enlarged adenoids. **Materials and Methods:** It was a year, cross-sectional, hospital-based study conducted at Lautech Teaching Hospital, Osogbo. ANR was determined by dividing adenoidal depth with nasopharyngeal depth on the plain lateral radiographs. **Results:** A total of 90 consecutive children consisting of 61 males and 29 females were included in the study with M:F ratio of 2.1:1. Their ages ranged from 8 months to 11 years. All the patients presented with nasal obstruction, mouth breathing and noisy breathing. Majority (64.5%) had severe obstructions with preponderance among children of 3-5 years (39.9%). Linear regression analysis showed significant association between age and ANR ( $t = 10.447$ ,  $P < 0.001$ ). There was high significant association ( $P < 0.05$ ) between presenting symptoms and degree of nasopharyngeal airway obstruction; for snoring ( $r = 0.251$ ,  $P = 0.000$ ), sleep apnoea ( $r = 0.594$ ,  $P = 0.000$ ), nasal discharge ( $r = 0.314$ ,  $P = 0.001$ ), excessive daytime sleepiness ( $r = 0.219$ ,  $P = 0.019$ ) and failure to thrive ( $r = 0.240$ ,  $P = 0.011$ ). **Conclusion:** Lateral X-ray of the nasopharynx is an effective tool to evaluate children with suspected adenoid hypertrophy. It correlates well with patients' symptoms and provides objective measures of adenoid hypertrophy.

**Key words:** Adenoidal hypertrophy, adenoidal nasopharyngeal ratio, plain radiography, resource-limited environment

Department of Otorhinolaryngology Head and Neck Surgery, Lautech Teaching Hospital, Osogbo, <sup>1</sup>Department of Surgery, ENT Unit, Obafemi Awolowo University Teaching Hospital, Ile-Ife, Osun State, <sup>2</sup>Department of Radiology, Lautech Teaching Hospital, Ogbomosho, Oyo State, Nigeria

### Address for correspondence:

Dr. Ademola A. Aremu,  
Department of Radiology, Lautech Teaching Hospital, Ogbomosho,  
Oyo State, Nigeria.  
E-mail: lamode70@yahoo.com

## INTRODUCTION

Adenoids constitute the upper portion of the Waldeyer's ring at the portal of the upper respiratory tract.<sup>[1,2]</sup> It is an important site of contact of inhaled microorganisms and antigens with immunoactive cells.<sup>[1]</sup> Adenoids grow more rapidly than the bony structure of the nasopharynx in children predisposing them to obstructive symptoms.<sup>[3]</sup> The clinical symptoms of obstructive adenoids are more common in the younger age due to the relatively small volume of the nasopharynx and the increased frequency of upper respiratory infections.<sup>[4]</sup> Adenoid hypertrophy plays an important role in various pathological manifestations, which include otitis media with effusion/recurrent otitis, rhinosinusitis, adenoiditis and obstructive sleep apnoea.<sup>[1]</sup> Other problems reported to have resulted from enlarged adenoids that include failure to thrive, excessive daytime sleepiness, impairment of cognitive functions, poor school performance and psychosocial problems.<sup>[5]</sup>

Adenoidectomy, a surgical procedure frequently adopted in otolaryngology, has been found to play a major role in the treatment of problems associated with adenoid hypertrophy in children.<sup>[2,5]</sup> Although adenoidectomy is a useful procedure, there has been an emphasis on the careful selection of subjects for these procedures due to a consensus on the

This is an open access article distributed under the terms of the Creative Commons Attribution-NonCommercial-ShareAlike 3.0 License, which allows others to remix, tweak, and build upon the work non-commercially, as long as the author is credited and the new creations are licensed under the identical terms.

**For reprints contact:** reprints@medknow.com

**Cite this article as:** Adedeji TO, Amusa YB, Aremu AA. Correlation between adenoidal nasopharyngeal ratio and symptoms of enlarged adenoids in children with adenoidal hypertrophy. Afr J Paediatr Surg 2016;13:14-9.

immunological role played by adenoids as well as the potential complications of the surgery.<sup>[2,4-6]</sup> Therefore, adequate preoperative evaluation which includes physical examination, nasopharyngolaryngoscopy, plain radiograph, rhinomanometry, computerised tomography scan and magnetic resonance imaging are necessary for careful and accurate selection of patients for surgeries.<sup>[3,7]</sup> In Nigeria and other less developed countries, advanced imaging modalities are not readily available and are expensive. Lateral radiograph of neck soft tissue is cheap, readily available and comfortable for the child with a simple way of determining adenoids' size, shape, and position.<sup>[2,8]</sup>

This study aims at correlating the symptoms of enlarged adenoids and adenoidal nasopharyngeal ratio (ANR) in a resource-challenged environment.

## MATERIALS AND METHODS

This was a cross-sectional, hospital-based study conducted between July 2010 and June 2011. One hundred consecutive, mouth breathing children, aged 8 months to 12 years were selected after obtaining ethical clearance from the Research Ethics Committee of Ladoke Akintola University of Technology Teaching Hospital, Osogbo. Written, informed consent was obtained from caregivers/parents of all eligible participants following which structured questionnaire were administered for patients' demographic and clinical information about symptoms, such as the presence of snoring, nocturnal drooling, noisy sleep, mouth breathing, daytime sleepiness and nasal obstruction. General physical examination including thorough ear, nose and throat of the participants were done. The plain lateral radiographs of the nasopharynx of the affected children were obtained. The X-ray film was taken by the standard technique of lateral soft tissue radiograph of the nasopharynx. The beam was centred to the external auditory meatus with the head in true lateral position and the patient breathing through the nose with the mouth closed. The dimension of the adenoids and nasopharynx were measured with a transparent rule using the standard landmarks designed by Fujioka [Figure 1]. Adenoid depth was determined by drawing a perpendicular line from a line drawn along the straight part of the anterior margin of basiocciput to a point of maximal convexity of adenoid. Nasopharyngeal depth was determined by drawing a line from the anterior inferior edge of sphenobasioccipital synchondrosis to the posterior superior margin of the hard palate. ANR was then determined by dividing adenoidal depth with nasopharyngeal depth. The validated

'Symptomatology score' (SS) parameters were used to grade the severity of the most typical symptoms of adenotonsillar hypertrophy.<sup>[7]</sup> The following numeric values were assigned to snoring/and mouth breathing: 0 - absent, 1 - occasionally during sleep, 2 - regularly during sleep and 3 - regularly during sleep and daytime. Obstructive breathing during sleep was assigned the following values: 0 - absent, 1 - occasionally, 2 - up to 5 episodes and 3 - >5 episodes. Nasal discharge and daytime hypersomnolence were assigned the following values: 0 - never, 1 - occasionally and 2 - regularly. The SS represents the sum of the individual domain scores. The maximum score any child had was thus 13. The SS of <6 suggested 'mild' airway obstruction, scores between 6 and 9 were considered suggestive of 'moderate' obstruction, whereas scores of more than 9 suggested 'severe' obstruction. Excluded from the study were patients with upper airway obstruction from tonsillar or inferior turbinate hypertrophy, allergic rhinitis, cleft palate, previous history of adenoidectomy and those whose parent(s) refused to give consent for participation in the study. Data obtained were entered into a spreadsheet and analysis was done using Statistical Package for Social Sciences version 14 (SPSS Inc. Chicago, IL, USA) with means and frequencies calculated. The data were presented in simple descriptive forms as proportions using tables and graphic charts. Linear regression analysis was used to determine the degree of association between age and ANR and between various adenoids symptoms and ANR. Chi-square was used to determine the differences between ANR and the time of presentation. The level of significant was set at 0.05.

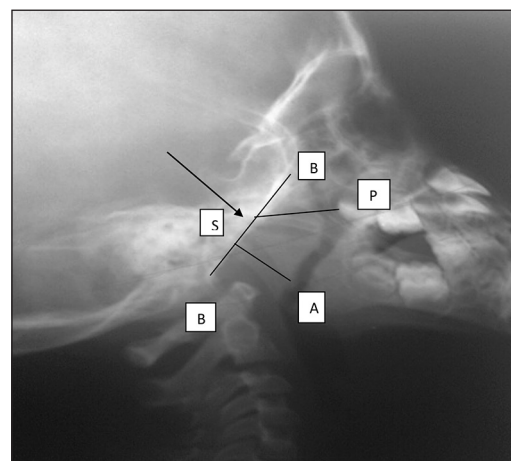


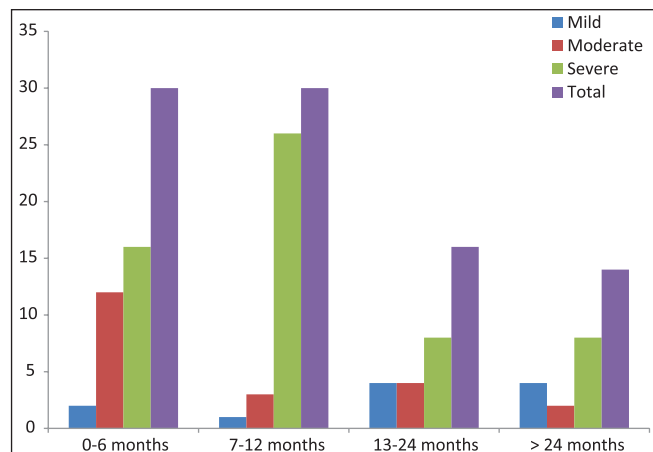
Figure 1: Plain radiograph of the postnasal space that shows how adenoidal – nasopharyngeal ratio was determined. B: Line drawn along straight part of anterior margin of basiocciput; S: Sphenobasioccipital synchondrosis; PS: Nasopharyngeal depth (line from anterior inferior edge of S to posterior superior margin of hard palate); AB: Adenoid depth (perpendicular line from B to point of maximal convexity of Adenoid); ANR: Adenoidal nasopharyngeal ratio; AB/AP: Adenoid depth/Nasopharyngeal depth

## RESULTS

A total of 90 consecutive children with chronic nasal obstructions whose parents/guardian gave informed consent were recruited for the study. There were 61 (67.8%) males and 29 (32.2%) females with M:F ratio of 2.1:1. The age of the patients ranged from 8 months to 11 years (mean =  $3.0 \pm 2.3$  years) and age group 3-5 years was the most affected group (36.7%). Table 1 shows the age and sex distribution among the study population.

All the patients presented with nasal obstruction, mouth breathing and noisy breathing. Other symptoms seen among the patients were shown in Table 1. Figure 1 shows how ANR was determined from plain lateral radiograph of the post nasal space. ANR ranges from 0.60 to 0.89 (mean  $\pm$  standard deviation =  $0.78 \pm 0.74$ ). The degree of nasopharyngeal obstruction was graded into mild obstruction (0.60-0.69), moderate obstruction (0.70-0.79) and severe obstruction (0.80-0.89) from ANR obtained. Majority (64.5%) had severe obstructions, 23.3% had moderate obstructions, while 12.2% had mild obstructions. Preponderance of severe obstruction (39.9%) was found among children 3-5 years, followed by age group 1-2 years (29.3%). Linear regression analysis showed significant association between age and ANR ( $t = 10.45$ ,  $P < 0.001$ ). Figure 2 shows the association between the duration of illness before presentation and ANR. Severity of nasopharyngeal obstruction was associated with the time of presentation ( $\chi^2 = 17.77$ ,  $P < 0.005$ ). Majority (66%) presented within the 1<sup>st</sup> year of onset of symptoms.

There was a high significant correlation between symptoms of adenoid enlargement and nasopharyngeal airway obstruction as determined from ANR [Table 2].



**Figure 2: Association between duration of illness and adenoidal nasopharyngeal ratio.  $\chi^2$ : 17.77;  $P < 0.005$**

Separate analysis of the relationship between individual symptoms and ANR shows correlation to be; snoring/noisy breathing ( $r = 0.251$ ,  $P < 0.001$ ), sleep apnoea/obstructive breathing during sleep ( $r = 0.594$ ,  $P < 0.001$ ), nasal discharge ( $r = 0.314$ ,  $P = 0.001$ ), excessive daytime sleepiness ( $r = 0.219$ ,  $P = 0.019$ ) and failure to thrive ( $r = 0.240$ ,  $P = 0.011$ ). There was, however, no significant correlation between ANR and mouth breathing ( $r = -0.102$ ,  $P = 0.336$ ).

## DISCUSSION

Adenoid hypertrophy is one of the most common health problems affecting the paediatric population. The consequence of this nasopharyngeal obstruction from adenoidal hypertrophy has been implicated in various morbidities among the affected children.<sup>[9,10]</sup> The mean age of  $2.95 \pm 2.28$  years with preponderance of the disease among age group 3-5 years was similar to the reports of previous researchers. This is due to the fact that adenoid has relatively higher growth rate than the nasopharynx between the ages of 2 and 5 years.<sup>[4,7]</sup> The factor for male predominance seen in this study, which was in agreement with previous report that was, however, not clear.<sup>[7]</sup>

**Table 1: Age and gender distribution**

Age range (years)	Male (%)	Female (%)	Total (%)
<1	15 (16.7)	6 (6.6)	21 (23.3)
1-2	17 (18.9)	7 (7.8)	24 (26.7)
3-5	19 (21.1)	14 (15.6)	33 (36.7)
>5	10 (11.1)	2 (2.2)	12 (13.3)
Total	61 (67.8)	29 (32.2)	90 (100)
Mean $\pm$ SD (years)	2.95 $\pm$ 2.27587		
Symptoms	n (%)		
Nasal obstruction	90 (100)		
Noisy breathing	90 (100)		
Mouth breathing	90 (100)		
Snoring	88 (97.8)		
Nasal discharge	87 (96.7)		
Sleep apnoea	74 (82.2)		
Excessive daytime sleepiness	15 (16.7)		
Failure to thrive	10 (11.1)		

SD: Standard deviation

**Table 2: Degree of association between symptoms of adenoid enlargement and nasopharyngeal airway obstruction using correlation coefficient**

Variables	r	P
Snoring/noisy breathing	0.251	0.000
Sleep apnoea/obstructive breathing during sleep	0.594	0.001
Nasal discharge	0.314	0.001
Excessive daytime sleepiness	0.219	0.019
Failure to thrive	0.240	0.011
Mouth breathing	-0.102	0.336

Although adenoidectomy continues to be one of the most common surgical procedures performed in the paediatric population, there had been no universal guidelines for assessing adenoidal enlargement and no clear cut accepted indications for adenoidectomy.<sup>[9,11]</sup> Diagnosis and documentation of adenoidal hypertrophy, however, become an important issue when adenoidectomy is been considered.<sup>[7,11]</sup>

Clinical symptoms, lateral neck radiography and endoscopy had been employed as preoperative methods for evaluating adenoidal size. Some of the limitations of the clinical assessment as a preoperative evaluating methods were due to problems emanating from difficulty in standardising such grading system.<sup>[7,9]</sup> This has made the reliability of clinical assessment to predict the severity of nasopharyngeal obstruction a subject of controversy.<sup>[7]</sup> It is also difficult to compare subjective data, such as clinical symptoms, with objective data found in plain radiograph or endoscopy.

Although flexible nasopharyngoscopic examination appears to be more accurate and correlates better with the severity of the disease as regards the estimation of adenoidal enlargement and the tool is also emerging as a useful method for evaluating patients with pathological adenoid hypertrophy,<sup>[9,12,13]</sup> in many health facilities in developing countries such as Nigeria where resources are limited, flexible nasopharyngoscopy is not readily available. Flexible nasopharyngoscopy is also an invasive procedure and many children may not readily co-operate for nasopharyngeal examination during preoperative adenoid assessment. These factors have limited the use of flexible nasopharyngoscope in many developing countries and have made plain nasopharyngeal radiographs a common and relevant objective investigating tool for patients with enlarged adenoid in such an environment.

Different methods have been described in literature as regards the evaluation of adenoids on lateral nasopharyngeal radiographs.<sup>[9,12-15]</sup> The method employed in this study was the same with the method used by most of the previous studies.<sup>[7-9,12]</sup> ANR had been found to reflect both the adenoidal size and nasopharyngeal capacity.<sup>[7,8]</sup> The degree of nasopharyngeal airway obstruction as obtained from ANR has been shown to be a more reliable parameter than the actual size or volume of resected adenoids in the evaluation of adenoidal obstruction severity.<sup>[7,16-18]</sup> Kolo *et al.*<sup>[15]</sup> in Nigeria reported a high level of agreement among trained raters (Otolaryngologists and Radiologists), in subjectively interpreting plain

nasopharyngeal radiographs in children with suspected adenoidal obstruction. Kurien *et al.*<sup>[13]</sup> in India opined that lateral X-rays of the neck, besides being a non-invasive procedure, still remains a very reliable and valid diagnostic test in the evaluation of hypertrophied adenoids.

Our findings of gross obstruction in larger proportion of our patients with preponderance of this severe obstruction among children 3-5 years were similar to the findings of other researchers.<sup>[7,12]</sup> This may be due to the fact that parents of most of these affected children would have been consulting primary care physicians (Paediatricians/Family physicians), and only the patients who are none responsive to medical management or with gross obstruction are seen by the Otolaryngologists. Ages 3-5 years also coincides with the ages when the rate of growth of adenoid tissues is at its peak. Increased frequency of upper respiratory tracts infection at this age and relatively small volume of the nasopharynx at this younger age make clinical symptoms to be more common during this period.<sup>[1]</sup>

Previous researchers have shown that pathologic adenoid hypertrophy has negative effects on children in whom an early diagnosis is not made.<sup>[16,17]</sup> The disease causes a major loss of quality of life for the patients and it is a source of concerns for their parents/caretakers.<sup>[16]</sup> Objective assessment of the affected children becomes imperative for early intervention. Plain radiographs of the nasopharynx are generally available, accessible and non-invasive. This has made it an invaluable tool in many developing countries such as Nigeria. Primary caregivers such as paediatricians and family physician should, therefore, have adequate knowledge about nasopharyngeal plain radiographs for early diagnosis and provide appropriate referral to otorhinolaryngologist for prompt and appropriate intervention before sequelae develop.

The significant correlation obtained between ANR and more common and specific symptoms encountered in patients with adenoid hypertrophy in our study makes plain radiography in the evaluation of adenoid enlargement a relevant and reliable tool. Previous researchers had reported lateral plain radiograph of post nasal space to have relevance in establishing diagnosis and planning treatment in adenoidal enlargement.<sup>[9,19]</sup> Kurien *et al.*<sup>[13]</sup> in their study, 'X-rays in the evaluation of adenoid hypertrophy: It's role in the endoscopic era' reported statistically significant correlation in 65% of the patients between the X-ray and endoscopy findings and concluded that lateral X-rays of the

neck, besides being a non-invasive procedure, still remains a very reliable and valid diagnostic test in the evaluation of hypertrophied adenoids. Orji and Ezeanolue<sup>[7]</sup> found a strong correlation between the SSs of adenoidal obstruction and roentgenographic of nasopharyngeal airway obstruction. They concluded that graded assessment of adenoidal obstruction symptomatology is comparable to roentgenographic assessment in evaluating the severity, especially at the level of extreme of gross obstruction and minimal obstruction.<sup>[7]</sup> Some researchers, however, reported a weak correlation between the clinical symptoms and plain lateral radiographs of the nasopharynx<sup>[9,20,21]</sup> and some published studies also reported a poor correlation between the measurements taken by lateral soft tissue neck radiography and the clinical symptoms.<sup>[22,23]</sup> The unfavourable result might be due to the difficulty in the standardisation of the clinical symptoms.<sup>[7]</sup> Clinical evaluation of adenoid size (based on the history and technical difficulty in rhinoscopic examination) in young children limits the reliability of clinical assessment, especially as a pre-operative method in the affected children. Therefore, objective measures of adenoidal hypertrophy are useful to provide information that may help deciding the need of surgery as well as for outcomes' evaluation.

In an environment like ours where other objective tools such as flexible nasopharyngoscopy or video rhinoscopy, which appears to be more accurate at evaluating the pathological adenoid hypertrophy<sup>[2,9,24]</sup> that are not readily available, plain X-ray of the nasopharynx comes into play as an objective measure of adenoidal hypertrophy. The cheap cost of plain lateral radiograph is also an advantage in our setting where the majority of the populace are poor. The cost saving advantage of plain radiograph will, therefore, improve access to care and potentially will shorten the time to diagnosis and treatment of the affected children. Therefore, the relevance of such diagnostic tool such as plain radiography in resource-challenged environment cannot be overemphasised.

The limitations and some disadvantages associated with X-ray were noted. Risk associated with the irradiation of the child as well as two-dimensional image of nasopharynx rather than a three-dimensional structure is agreed a limitation. Two-dimensional radiographs may not be completely accurate in the assessment of adenoid enlargement and may allow for some weak inter-observer agreement.<sup>[9]</sup> Apart from this little drawback, high level of agreement in interpretation of nasopharyngeal plain radiography among trained

raters in the evaluation of patients with hypertrophied adenoid is a well-recognised fact.<sup>[15]</sup> This factor coupled with scarce, and limited resources in most developing countries has made plain radiography of the nasopharynx in the airway management of patients with adenoidal hypertrophy a relevant and indispensable tool in such an environment.

## CONCLUSION

Lateral X-ray of the nasopharynx is a useful objective tool to evaluate children with suspected adenoid hypertrophy, especially in a resource-limited environment. It correlates well with patients' symptoms and provides objective measures of adenoid hypertrophy as well as useful information that may help to decide the need for surgery.

## Financial support and sponsorship

Nil.

## Conflicts of interest

There are no conflicts of interest.

## REFERENCES

1. Peter JR. The adenoid and adenoidectomy. In: Michael G, George GB, Martin JB, Ray C, John H, Nicholas SJ. *et al.*, editors. *Scott-Brown's Otolaryngology*. 7<sup>th</sup> ed., Vol. 1. London: Hodder Arnold; 2008. p. 1095-101.
2. Ourenço EA, Lopes KC, Pontes A, Oliveira MH, Umemura A, Vargas A. Comparison between radiological and nasopharyngolaryngoscopic assessment of adenoid tissue volume in mouth breathing children. *Rev Bras Otorrinolaringol* 2005;71:23-8.
3. Jaw TS, Sheu RS, Liu GC, Lin WC. Development of adenoids: A study by measurement with MR images. *Kaohsiung J Med Sci* 1999; 15:12-8.
4. Görür K, Döven O, Unal M, Akkus N, Ozcan C. Preoperative and postoperative cardiac and clinical findings of patients with adenotonsillar hypertrophy. *Int J Pediatr Otorhinolaryngol* 2001;59:41-6.
5. Muzumdar H, Arens R. Diagnostic issues in pediatric obstructive sleep apnea. *Proc Am Thorac Soc* 2008;5:263-73.
6. Paulussen C, Claes J, Claes G, Jorissen M. Adenoids and tonsils, indications for surgery and immunological consequences of surgery. *Acta Otorhinolaryngol Belg* 2000;54:403-8.
7. Orji FT, Ezeanolue BC. Evaluation of adenoidal obstruction in children: Clinical symptoms compared with roentgenographic assessment. *J Laryngol Otol* 2008;122:1201-5.
8. Cohen LM, Koltai PJ, Scott JR. Lateral cervical radiographs and adenoid size: Do they correlate? *Ear Nose Throat J* 1992;71:638-42.
9. Mlynarek A, Tewfik MA, Hagr A, Manoukian JJ, Schloss MD, Tewfik TL, *et al.* Lateral neck radiography versus direct video rhinoscopy in assessing adenoid size. *J Otolaryngol* 2004;33:360-5.
10. Brooks LJ, Stephens BM, Bacevice AM. Adenoid size is related to severity but not the number of episodes of obstructive apnea in children. *J Pediatr* 1998;132:682-6.
11. Oluwole M, Mills RP. Methods of selection for adenoidectomy in childhood otitis media with effusion. *Int J Pediatr Otorhinolaryngol* 1995;32:129-35.

12. Kolo ES, Ahmed AO, Kazeem MJ, Nwaorgu OG. Plain radiographic evaluation of children with obstructive adenoids. *Eur J Radiol* 2011;79:e38-41.
13. Kurien M, Lepcha A, Mathew J, Ali A, Jeyaseelan L. X-rays in the evaluation of adenoid hypertrophy: It's role in the endoscopic era. *Indian J Otolaryngol Head Neck Surg* 2005;57:45-7.
14. Feres MF, Hermann JS, Sallum AC, Pignatari SS. Radiographic adenoid evaluation — Suggestion of referral parameters. *J Pediatr (Rio J)* 2014;90:279-85.
15. Kolo ES, Salisu AD, Tabari AM, Dahilo EA, Aluko AA. Plain radiographic evaluation of the nasopharynx: Do raters agree? *Int J Pediatr Otorhinolaryngol* 2010;74:532-4.
16. de Lima JM, da Silva VC, de Freitas MR. Long term results in the life quality of children with obstructive sleep disorders. *Rev Bras Otorrinolaringol* 2008;74:718-24.
17. Gozal D. Sleep-disordered breathing and school performance in children. *Pediatrics* 1998;102(3 Pt 1):616-20.
18. Crepeau J, Patriquin HB, Poliquin JF, Tetreault L. Radiographic evaluation of the symptom-producing adenoid. *Otolaryngol Head Neck Surg* 1982;90:548-54.
19. Kemaloglu YK, Goksu N, Inal E, Akyildiz N. Radiographic evaluation of children with nasopharyngeal obstruction due to the adenoid. *Ann Otol Rhinol Laryngol* 1999;108:67-72.
20. Paradise JL, Bernard BS, Colborn DK, Janosky JE. Assessment of adenoidal obstruction in children: Clinical signs versus roentgenographic findings. *Pediatrics* 1998;101:979-86.
21. Laurikainen E, Erkinjuntti M, Alihanka J, Rikalainen H, Suonpää J. Radiological parameters of the bony nasopharynx and the adenotonsillar size compared with sleep apnea episodes in children. *Int J Pediatr Otorhinolaryngol* 1987;12:303-10.
22. Mahboubi S, Marsh RR, Potsic WP, Pasquariello PS. The lateral neck radiograph in adenotonsillar hyperplasia. *Int J Pediatr Otorhinolaryngol* 1985;10:67-73.
23. Maw AR, Jeans WD, Fernando DC. Inter-observer variability in the clinical radiological assessment of adenoid size, and the correlation with adenoid volume. *Clin Otolaryngol* 1981;6:317-22.
24. Wormald PJ, Prescott CA. Adenoids: Comparison of radiological assessment methods with clinical and endoscopic findings. *J Laryngol Otol* 1992;106:342-4.