

Leptospirosis Followed by Kawasaki-Like Disease: Case Report From an Adult Swiss Patient and Review of the Literature

Severin Baerlocher,^{1,a} Seth Helfenstein,^{2,a} Alfred Mahr,³ Selina Crippa,⁴ Regine Garcia Boy,⁵ Christian R. Kahlert,^{2,b} Timur Yurttas,⁷ Christoph Hatz,^{2,7,8} and Philipp Kohler^{2,c}

¹Department of Internal Medicine, Cantonal Hospital of St. Gallen, St. Gallen, Switzerland, ²Division of Infectious Diseases and Hospital Epidemiology, Cantonal Hospital of St. Gallen, St. Gallen, Switzerland, ³Department of Rheumatology, Cantonal Hospital of St. Gallen, St. Gallen, Switzerland, ⁴Department of Internal Medicine, Regional Hospital of Grabs, St. Gallen, Switzerland, ⁵Zentrum für Labormedizin, St. Gallen, Switzerland, ⁶Children's Hospital of Eastern Switzerland, Infectious Diseases and Hospital Epidemiology, St. Gallen, Switzerland, ⁷University of Basel, Basel, Switzerland, ⁸Department of Medicine, Swiss TPH, Basel, Switzerland

Kawasaki disease (KD) is a vasculitis that mostly occurs in children, but rare cases in adults have been reported. We describe the case of a 43-year-old Swiss male who developed symptoms compatible with KD 7 weeks after leptospirosis, which was presumably acquired after swimming in a creek in the Swiss Alps. We performed a literature review and identified 10 other cases (all in children), in which Kawasaki-like disease was diagnosed in the context of leptospirosis. Outcome was favourable in most cases, including our patient. This exceptional case demonstrates both the possibility of autochthonous cases of leptospirosis in Switzerland as well as a possible association of leptospirosis with Kawasaki-like disease.

Keywords. adult; Kawasaki disease; leptospirosis; Switzerland; vasculitis.

CASE REPORT

A 43-year-old, otherwise healthy male presented to an external hospital with fever and cough in the beginning of November 2019 (episode 1, hospital A) (Figure 1). The patient also had acute kidney injury and thrombocytopenia. He recovered after treatment with amoxicillin-clavulanic acid and clarithromycin

for suspected pneumonia. For the next 5 weeks, he remained completely free of symptoms. On December 30, 2019, he had an acute onset of fever up to 39.3°C, a mild cough, dry eyes, arthralgia, and a generalized rash. He sought medical care as an outpatient and was again started on amoxicillin/clavulanic acid and clarithromycin for suspected relapse of pneumonia. The fever continued and the patient developed yellow discoloration of his eyes, redness and swelling of the genital region, chapped lips, and extensive scaling of his skin, whereupon he presented to our tertiary hospital (episode 2, hospital B) on January 2, 2020 (Figure 1).

The patient reported frequent outdoor activities before the onset of episode 1, including hunting, skinning of animals, and swimming in mountain lakes and creeks near the Swiss-Austrian border. He denied any other animal contacts. He was in a stable relationship with a woman for approximately 1 year and did not report any other sexual contacts. He also denied any illicit drug use. Upon admission to hospital B, the patient's blood pressure was 125/80mmHg, pulse was 88/minute, oxygen saturation on room air was 98%, and tympanic temperature was 39.3°C. Clinical examination revealed generalized jaundice, a swollen nuchal lymph node, and tenderness in the upper right abdomen. The rash had disappeared, but his skin appeared dry and showed extensive desquamation, mainly involving the lips, palms, and soles. There was diffuse swelling of the genital region (Figure 2). The papillae of the tongue were enlarged. The right knee was slightly swollen. The C-reactive protein was increased at 209 mg/L. Liver enzymes were slightly and bilirubin (119 µmol/L) was markedly increased (Table 1). Abdominal ultrasound showed no liver pathology; intrahepatic bile ducts were not dilated. The spleen (13.5 cm) was slightly enlarged. Chest x-ray was inconspicuous.

Upon hospital admission, the patient was started on ceftriaxone for 7 days to cover possible bacterial disease. Results of the extensive laboratory diagnostic work-up, which included search for infectious (eg, sexually transmitted and zoonotic diseases) and immune-mediated causes, are shown in Table 1. In the course of the hospitalization in hospital B, serology for *Leptospira interrogans* immunoglobulin (Ig)M was positive, but it was repeatedly negative for IgG. Urine polymerase chain reaction (PCR) for *L. interrogans* was also negative. Therefore, we performed a microscopic agglutination test (MAT) that identified Igs against *L. interrogans* spp Bratislava (titer 1:1280). Because of the suggestive clinical presentation in hospital A, we retrospectively performed PCR on the patients' serum from episode 1 (hospitals A and B are being served by the same microbiology laboratory), which was indeed positive for *L. interrogans*, confirming the suspected diagnosis of leptospirosis (Figure 1).

Received 8 January 2021; editorial decision 12 February 2021; accepted 18 February 2021.

^aS. B. and S. H. contributed equally to this work.

Correspondence: Philipp Kohler, MD, MSc (philipp.kohler@kssg.ch).

Open Forum Infectious Diseases® 2021

© The Author(s) 2021. Published by Oxford University Press on behalf of Infectious Diseases Society of America. This is an Open Access article distributed under the terms of the Creative Commons Attribution-NonCommercial-NoDerivs licence (<http://creativecommons.org/licenses/by-nc-nd/4.0/>), which permits non-commercial reproduction and distribution of the work, in any medium, provided the original work is not altered or transformed in any way, and that the work is properly cited. For commercial re-use, please contact journals.permissions@oup.com
DOI: 10.1093/ofid/ofab088

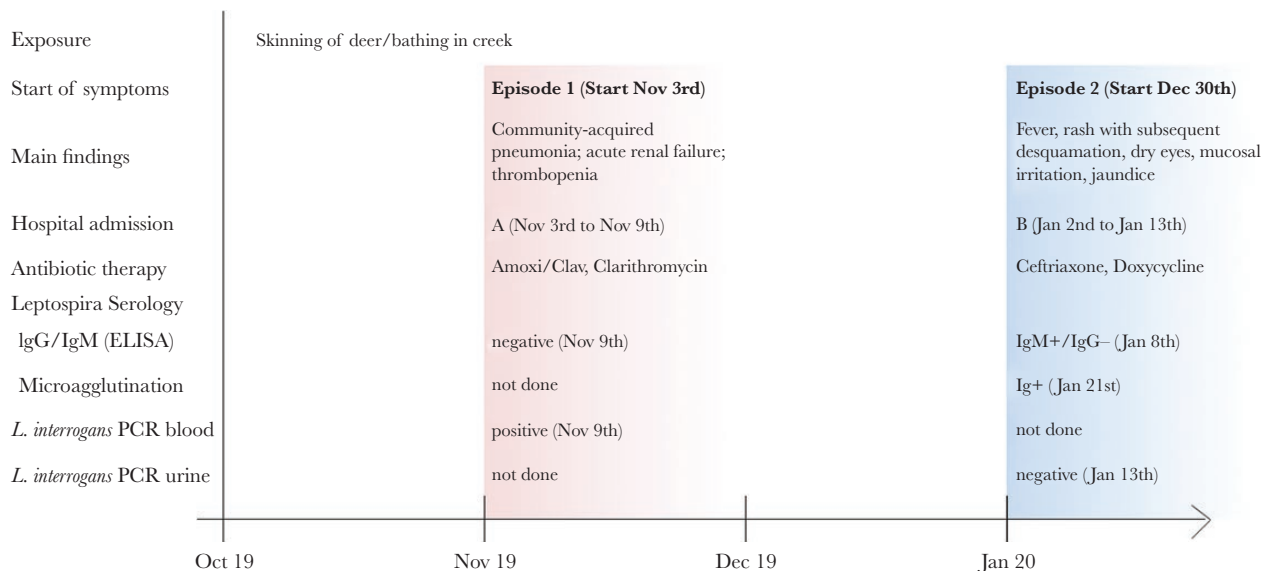


Figure 1. Timeline of patient with leptospirosis in November 2019 (episode 1 in hospital A) followed by a Kawasaki disease-like syndrome in January 2020 (episode 2 in hospital B).

However, the symptoms and laboratory findings of episode 2 were not consistent with a diagnosis of leptospirosis. With the persisting fever, the peripheral extremity changes, the irritation of the enoral mucosa and the eyes, the extensive scaling of his skin, and the nuchal lymphadenopathy, the diagnosis of adult Kawasaki disease (KD) was made [1]. Transthoracic echocardiography did not reveal any signs for a coronary aneurysm or other pathological findings. On day 6 of the hospital admission (ie, 10 days after symptom onset), the fever started to subside. Therefore, we refrained from a therapy with intravenous Igs (IVIG) [2]. Although the patient was afebrile, we initiated a 1-week course of doxycycline on January 9, 2020 because of

a positive urine PCR for *Mycoplasma hominis*. By January 13, 2020 (ie, day 12 after hospital admission), C-reactive protein and bilirubin had almost returned to normal range values and the patient was discharged.

Patient Consent Statement

We obtained written informed consent from the patient.

LITERATURE REVIEW

We performed a systematic literature review searching for records reporting cases of Kawasaki-like disease associated with leptospirosis. A professional librarian ran a literature search in

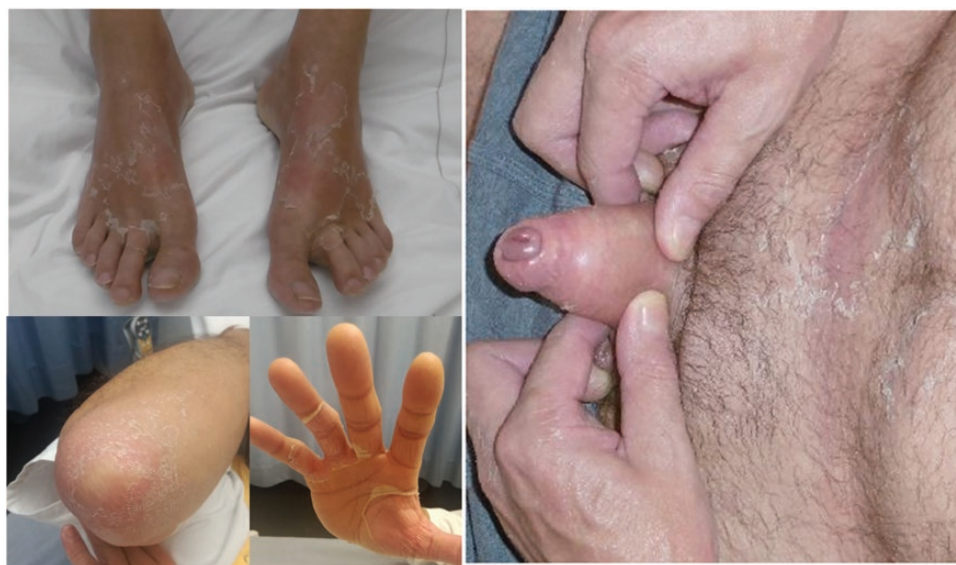

Figure 2. Clinical picture during episode 2 in hospital B: desquamating skin on feet, hands, and elbows. Swelling, redness, and scaling of genital area.

Table 1. Results of Laboratory, Microbiologic, and Serologic Work-up of Patient During Episode 1 (Leptospirosis) and Episode 2 (Kawasaki Disease)

Parameter (unit)	Episode 1 (November 2019)		Episode 2 (January 2020)	
	Date	Result	Date	Result
Hematology and Chemistry				
Hemoglobin (140–180 g/L)	Nov 11th	113	Jan 2nd	110
Thrombocytes (150–300 G/L)	Nov 11th	109	Jan 2nd	189
Leucocytes (4.0–10.0 G/L)	Nov 11th	3.4	Jan 2nd	8.1
Sodium (136–144 mmol/L)	Nov 9th	126	Jan 2nd	130
Potassium (3.5–5.1 mmol/L)	Nov 9th	3.2	Jan 2nd	2.9
Creatinine (<115 µmol/L)	Nov 9th	200	Jan 2nd	88
Bilirubin (<20 µmol/L)	Nov 9th	10	Jan 2nd	119
Aspartate aminotransferase (<40 U/L)	Nov 9th	46	Jan 2nd	32
Alanine aminotransferase (<55 U/L)	Nov 9th	43	Jan 2nd	124
Alkaline phosphatase (40–130 U/L)	Nov 9th	67	Jan 2nd	139
Gamma-glutamyltransferase (<65 U/L)	Nov 9th	57	Jan 2nd	113
C-reactive protein (<5 mg/L)	Nov 9th	179	Jan 2nd	209
Procalcitonin (<0.5 µg/L)	Nov 9th	0.5		
Haptoglobin (0.3–2 g/L)			Jan 3rd	3.68
Ferritin (30–330 µg/L)			Jan 3rd	444
International normalized ratio (0.9–1.1)	Nov 9th	1.1	Jan 6th	1.3
Urine-Chemistry				
Leucocytes	Nov 9th	+	Jan 2nd	+++
Erythrocytes/hemoglobin	Nov 9th	++	Jan 2nd	++
Bilirubin	Nov 9th	+	Jan 2nd	+++
Microbiology				
Blood cultures	Nov 9th	no growth	Jan 3rd	no growth
Urine cultures	Nov 9th	no growth	Jan 3rd	no growth
Legionella antigen urine	Nov 9th	neg.		
<i>Leptospira interrogans</i> PCR urine			Jan 9th	neg.
<i>L. interrogans</i> PCR blood	Nov 9th	pos.		
Stool PCR			Jan 8th	
<i>Salmonella</i> spp				neg.
<i>Campylobacter jejuni</i> / <i>Campylobacter coli</i>				neg.
<i>Shigella</i> spp/enteroinvasive <i>Escherichia coli</i>				neg.
Urethral PCR			Jan 4th	
<i>Ureaplasma urealyticum</i>				neg.
<i>Neisseria gonorrhoea</i>				neg.
<i>Mycoplasma hominis</i>				pos.
<i>Mycoplasma genitalium</i>				neg.
<i>Chlamydia trachomatis</i>				neg.
<i>Ureaplasma parvum</i>				neg.
<i>Haemophilus ducreyi</i>				neg.
<i>Treponema pallidum</i>				neg.
Herpes simplex I/II				neg.
Nasopharyngeal PCR	Nov 9th		Jan 3rd	
<i>Mycoplasma pneumoniae</i>				neg
Respiratory syncytial virus		neg.		
Influenza A/B virus		neg.		neg.
Serologies				
<i>L. interrogans</i> IgG (<10 U/mL)	Nov 9th	<2	Jan 8th	3
<i>L. interrogans</i> IgM (<10 U/mL)	Nov 9th	<3	Jan 8th	46
<i>Chlamydia pneumoniae</i> IgG (<10 U/mL)	Nov 9th	14		NA
<i>C pneumoniae</i> IgM (<10 U/mL)	Nov 9th	<3		NA
Hepatitis E IgG (<0.9 index)			Jan 21st	0
Hepatitis E IgM (<0.9 index)			Jan 21st	0
HIV-1/2 screening test			Jan 3rd	neg.
Cytomegalovirus IgG (<6 AE/mL)			Jan 3rd	165
Cytomegalovirus IgM			Jan 3rd	neg.

Table 1. Continued

Parameter (unit)	Episode 1 (November 2019)		Episode 2 (January 2020)	
	Date	Result	Date	Result
<i>Treponema pallidum</i> Ig			Jan 3rd	neg.
Brucella IgG (<20 U/mL)			Jan 8th	<5
Brucella IgM (<15 U/mL)			Jan 8th	<5
Brucella IgA (<10 U/mL)			Jan 8th	<5
Hepatitis A virus IgM			Jan 3rd	neg.
Hepatitis B virus anti-HBc-IgM			Jan 3rd	neg.
Hepatitis B virus HBs-antigen (<0.05 IU/mL)			Jan 3rd	<0.03
Hepatitis C virus antibody screen			Jan 3rd	neg.
Hantavirus IgG/IgM			Jan 9th	neg.
<i>Coxiella burnetii</i> phase I IgG (<0.9)			Jan 8th	0.2
<i>C burnetii</i> phase II IgM (<0.9)			Jan 8th	0.4
<i>C burnetii</i> phase II IgG (<20 U/mL)			Jan 8th	9.0
<i>Francisella tularensis</i> IgG (<10 U/mL)			Jan 8th	3.6
<i>F tularensis</i> IgM (<10 U/mL)			Jan 8th	<4
<i>Borrelia burgdorferi</i> IgG			Jan 3rd	neg.
<i>B burgdorferi</i> IgM			Jan 3rd	neg.
Malaria rapid test			Jan 8th	neg.
Rheumatoid factor IgM (<3.5 IU/mL)			Jan 3rd	0.8
Rheumatoid factor IgA (<3.5 IU/mL)			Jan 3rd	3.0
Antinuclear antibodies IgG immunofluorescence (<1:80); AC-04			Jan 3rd	1:160
Antineutrophil cytoplasmic antibodies IgG (<3.5 U/mL)			Jan 3rd	<0.2
Microscopic agglutination test (<i>Leptospira</i>)			Jan 21st	
<i>Leptospira Grippityphosa</i>				<1:20
<i>Leptospira Australis</i>				1:640
<i>Leptospira Pomona</i>				<1:20
<i>Leptospira Tarassovi</i>				<1:20
<i>Leptospira Canicola</i>				<1:20
<i>Leptospira Icterohaemorrhagiae</i>				<1:20
<i>Leptospira Hardjo</i>				<1:20
<i>Leptospira Bataviae</i>				<1:20
<i>Leptospira Bratislava</i>				1:1280
<i>Leptospira Autumnalis</i>				<1:20
<i>Leptospira Sejroe</i>				<1:20
<i>Leptospira Pyrogenes</i>				<1:20
<i>Leptospira Ballum</i>				<1:20
<i>Leptospira Copenhageni</i>				<1:40
<i>Leptospira Celledoni</i>				<1:20
<i>Leptospira Cynopteri</i>				<1:20
<i>Leptospira Javanica</i>				<1:20
<i>Leptospira Panama</i>				<1:20
<i>Leptospira Shermani</i>				<1:20
<i>Leptospira Patoc</i>				<1:20

Leucocytes + = 10-25 cells/ μ l; Leucocytes +++ = approx. 500 cells/ μ l; Hemoglobin ++ = approx. 25 erythrocytes/ μ l; Bilirubin + = low concentration in urine (semiquantitative on a scale from negativ to +++); Bilirubin +++ = high concentration in urine (see above).

Abbreviations: HIV, human immunodeficiency virus; Ig, immunoglobulin; Jan, January; NA, not applicable; neg., negative; Nov, November; PCR, polymerase chain reaction; pos., positive.

Medline (Ovid), EMBASE, Cochrane, Scopus, Web of Science, and Google Scholar (through Publish OR Perish from harzing.com). A combination of subject headings (MeSH-terms for Medline, Emtree-terms for Embase) and free text search terms for the concepts of leptospirosis and KD was applied. The detailed search strategy for Medline (Ovid) is shown in [Supplementary Table S1](#). Title and abstract screening were performed on 878 hits. Among 27 studies undergoing full-text

screening, 7 cases of Kawasaki-like disease associated with leptospirosis were identified; 3 additional cases were identified through reference screening. No language restrictions were applied. Key patient features were extracted ([Table 2](#)).

The 10 cases (2 cases are from the same report) were published between 1977 and 2018 [3-11]. All were pediatric patients, with an age range between 2 and 14 years and a male to female ratio of 1.5:1. All patients had fever, 9 had conjunctivitis, 9 had a skin

Table 2. Results of Literature Review Regarding 10 Pediatric Cases (Plus the Present Adult Case) of Kawasaki-Like Disease Associated With Leptospirosis

Author	Year	Country	Age	Sex	Symptoms ^a	Diagnosis Leptospirosis	Treatment Leptospirosis	Diagnosis of KD	Latency Until KD	Treatment KD	Outcome
Humphry	1977	USA	2.5	F	Fever, pharyngitis, anorexia, conjunctivitis, abdominal pain, vomiting, rash, cervical lymph nodes, strawberry tongue, swollen lips, acral swelling, erythema, arthralgia, 3 weeks after onset of symptoms: skin desquamation	Serology	Unknown	Complete	Concurrent	Unknown	Unknown
Wong	1977	USA	2.5	F	Fever, anorexia, submandibular lymphadenopathy, rash, hematemesis, hematochezia, acral desquamation and necrosis	Unknown	Antibiotics, details unknown	Incomplete	Unknown	Symptomatic	Amputation
Wang	1999	Taiwan	8	M	Fever, drowsiness, headache, nausea, vomiting, abdominal pain, myalgia of calves, diarrhea, nuchal rigidity, lymphadenopathy, subconjunctival hemorrhage	MAT	Penicillin, gentamicin	Incomplete	Concurrent	Unknown	Recovered
Ergüven	2005	Turkey	2	M	Fever, abdominal pain, myalgia, vomiting, erythema, oral aphthosis, cervical lymphadenopathy, tonsillar swelling, conjunctivitis, distal edema	Serology and MAT: <i>Leptospira Hepdomandis</i> and <i>Leptospira Canicola</i>	Penicillin	Complete	Unknown	ASS, IVIG	Recovered
Nateghian	2012	Iran	13	F	Fever, headache, dizziness, pharyngeal erythema, odynophagia, abdominal and body pain, exanthema, conjunctivitis, skin desquamation	MAT	Doxycycline	Complete	Unknown	Symptomatic	Recovered
Foo	2017	Singapore	7	F	Fever, exanthema, diarrhea, headache, nausea, red eyes, coryza, cervical lymph node, strawberry tongue, skin desquamation	Serology: <i>Leptospira</i> IgM	Amoxicillin/clavulanic acid	Complete	Concurrent	IVIG	Recovered
Macko	2017	Belarus	2	M	Fever, rhinitis, otitis, dry cough, rash, palmar desquamation, cervical lymphadenopathy, conjunctivitis	MAT: <i>Leptospira interrogans</i> spp Grippotyphosa (day 17 after onset of symptoms)	Ceftriaxone, cefepime, meropenem	Complete	Unknown	ASS, IVIG	Recovered
Macko	2017	Belarus	3	M	Fever, nausea, emesis, exanthema, enanthema, palmar and plantar desquamation, conjunctivitis	MAT: <i>L. interrogans</i> spp Grippotyphosa (3 months after onset of symptoms)	Cefuroxim, ceftriaxone, cefepime	Complete	Unknown	IVIG	Recovered
Yesilbas	2017	Turkey	6	M	Persistent fever, respiratory distress, vomiting, diarrhea, desquamation of groin and genital area, erythema of oral mucosa, maculopapular rash, desquamation of fingers and toes, conjunctivitis	Positive dark field microscopy and serology: <i>Leptospira</i> IgM and IgG	Ceftriaxone, clindamycin, vancomycin, clarithromycin, fresh frozen plasma, plasmapheresis, cytokine filter	Complete	25 days	IVIG, steroids	Recovered
Takashi	2018	Japan	14	M	Persistent fever, headache, bilateral calf muscle pain, general malaise, conjunctival injection, rash	MAT: <i>L. interrogans</i> spp Copenhagensis (on day 63)	Doxycycline	Incomplete	8 days	IVIG	Recovered
Baerlocher	2021	Switzerland	43	M	Fever, cough, dry eyes, arthralgia, jaundice, erythema and swelling of the genital region, nuchal lymph node, chapped lips, desquamation of palms and soles	Blood PCR positive for <i>L. interrogans</i> ; Serology and MAT: <i>L. interrogans</i> spp Bratislava	Amoxicillin/clavulanic acid, clarithromycin	Complete	7 weeks	Symptomatic	Recovered

Abbreviations: ASS, acetylsalicylic acid; Ig, immunoglobulin; IVIG, intravenous immunoglobulin; KD, Kawasaki disease; MAT, microscopic agglutination test; PCR, polymerase chain reaction.

^aSymptoms in italic represent diagnostic criteria for KD according to Newburger et al [1]: fever lasting at least 5 days PLUS 4 of the following: conjunctival injection; oral mucous membrane changes; peripheral extremity changes; rash; cervical lymphadenopathy.

rash (6 of these with desquamation), and 8 had gastrointestinal symptoms (predominantly nausea, diarrhoea, and abdominal pain). Leptospirosis was mostly diagnosed by serology or MAT; the leptospiral serovar was reported in 3 cases: 1 *L interrogans* spp Hepdomandis and Canicola [3], 1 *L interrogans* serovar Copenhageni [11], and 2 *L interrogans* serovar Grippothyposa [10]. Diagnostic criteria for KD were fully met in 7 of the 10 cases (ie, complete KD), whereas 3 had incomplete KD. Latency between leptospirosis and Kawasaki-like disease was not reported in most cases because both diagnoses were made at the same time. In 1 case, latency was 25 days [9]. Treatment consisted of IVIG in 6 cases, acetylsalicylic acid (ASS) in 3, and steroids in 1 case. Outcome was favorable in 9 cases, except for one 2.5-year-old child where amputation had to be performed due to extensive acral desquamation and necrosis [8].

DISCUSSION

We present the unusual case of an adult patient developing Kawasaki-like disease after infection with *Leptospira interrogans* spp Bratislava. The thorough literature review identified 10 similar cases, all of which were reported in children.

Kawasaki disease, also termed mucocutaneous lymph node syndrome, is a medium-sized vessel vasculitis that was first described in 1967 [12]. Hallmarks of KD, which usually occurs in children, include persistent fever, desquamating skin rash, strawberry tongue, and cervical lymph nodes [1, 13]. Adult onset KD is still rare to date and might thus often be missed by clinicians [13]. Compared with children, adult KD more often manifests with hepatitis, arthralgia, and cervical adenopathy [14], which were all present in our patient. A potentially fatal complication—which can be found in up to 23% of children with KD—is the involvement of the coronary arteries, which can lead to the development and subsequent rupture of aneurysms [14, 15]. A single dose of IVIG 2 g/kg in combination with ASS is usually given to treat the disease. The etiology of KD remains unclear. One hypothesis is that a variety of bacterial and viral infections can trigger the disease [1, 16–18]. This includes severe acute respiratory syndrome coronavirus 2 (SARS-CoV-2), which is being suspected of causing a KD-like syndrome called multisystem inflammatory syndrome in children and adolescents (MIS-C) [19].

In 1977, the first report suggesting leptospirosis as cause of KD was published [5]. Leptospirosis is one of the most common zoonotic infections globally [20]. Approximately two thirds of patients with leptospirosis diagnosed in Switzerland between 1970 and 2015 were autochthonous cases, most of them with exposure to natural waters, as in our case [21]. Other published cases include a fisherman from the lake of Geneva as well as a cluster of cases among river surfers from Central Switzerland [22, 23]. Incidentally, our patient is the first published case from North-Eastern Switzerland. The annual incidence in the country was estimated at 0.08 cases/100 000

population before 1998, which is comparable to data from Germany [21, 24]. However, more recent data from Austria, another country neighboring Switzerland, showed a much higher incidence of 1.26/100 000 population [25]; in addition, a seroprevalence study from Southern Germany (bordering Switzerland) reported that leptospiral antibodies can be detected in 4.2% of the general population. Although some of the study participants with detectable antibodies reported having had symptoms compatible with leptospirosis in the past, none of them was ever diagnosed with the disease [26]. These data suggest that leptospirosis is vastly underreported in the region, which is most probably also the case for Switzerland.

In symptomatic patients, leptospirosis presents in a biphasic course. The first phase features flu-like symptoms including fever, headache, and myalgia [27]. A second immunological phase begins within days after resolution of the first phase and may present itself with pulmonary symptoms, kidney failure, electrolyte disorders, jaundice, or pancytopenia [28]. Leptospirosis is usually diagnosed through PCR from blood (first phase) or urine (late phase). After resolution of the first phase (ie, after 5 to 7 days of illness), specific antibodies can usually be detected; approximately 10% of cases do not show any seroconversion to IgG in the further course [29].

There is a certain overlap in the clinical presentation of leptospirosis and KD. Symptoms that have been described in both diseases—and in almost all cases in our review—include fever, conjunctivitis, gastrointestinal symptoms, and rash. These symptoms might be attributable to the vasculitic changes observed in KD but also to the late phase of leptospirosis. From a pathophysiological perspective, the overproduction of interleukin (IL)-6 has been associated with more severe disease manifestation in both KD and leptospirosis (together with IL-10 overproduction) [30, 31]. Symptoms that are more specific for KD include peripheral extremity changes, skin desquamation, a strawberry tongue, dry or cracked lips, and cervical lymph nodes [1]. It is noteworthy that in several cases identified in our review, the diagnosis of leptospirosis and Kawasaki-like disease were made concurrently. However, leptospirosis was mostly diagnosed by serology, which suggests that many patients may have had a previous asymptomatic or only mildly symptomatic episode of leptospirosis, which is perfectly in line with our current understanding of the clinical presentation of leptospirosis [28]. In general, data on the time lag between onset of KD and the potential previous triggering infection are scarce. However, in a French MIS-C cohort, the median duration between symptoms of SARS-CoV-2 infection and onset of KD was 45 days, which is very similar to our patient [32].

In our case, it seems unlikely that the symptoms observed during the second hospital admission were in fact directly related to leptospirosis. First, the latency between the early phase of leptospirosis and the occurrence of Kawasaki-like disease was 7 weeks, a time span far too long to be coherently attributed to the immunological phase of acute leptospirosis.

Second, a leptospiral PCR in the urine was negative at that time, which is usually not the case during the second phase of leptospiral infection. Third, the patient showed typical features of KD, meeting the diagnostic criteria suggested by Newburger et al [1]. It is interesting to note that, as seen in our patient, thrombocyte counts tend to be decreased in leptospirosis, whereas they are mostly normal or increased in KD [13]. The relevance of *M hominis*, which can be found in up to 10% of urethral samples of asymptomatic men [33], remains unclear. However, we did not find any cases of *M hominis* related with KD in the literature. In addition, the patient showed defervescence before we started treatment with doxycycline.

CONCLUSIONS

Our case is remarkable for several reasons. First, leptospirosis is very uncommon in Switzerland. Because of the protean manifestation of leptospirosis and a nonnegligible seroprevalence in the general population from neighboring countries, we hypothesize that leptospirosis is underreported in Switzerland. Second, the patient did not show seroconversion in the course despite PCR-confirmed leptospirosis, an unusual finding that has been reported to occur in approximately 10% of cases. Third, this case highlights the possible association of leptospirosis and subsequent Kawasaki-like disease, which has previously not been described in adults. The potentially unfavorable outcome associated with KD requires not only pediatricians, but also physicians involved in care of adult patients to be aware of this disease entity.

Supplementary Data

Supplementary materials are available at Open Forum Infectious Diseases online. Consisting of data provided by the authors to benefit the reader, the posted materials are not copyedited and are the sole responsibility of the authors, so questions or comments should be addressed to the corresponding author.

Acknowledgments

We thank the librarian Martina Gosteli (University of Zurich) for performing the literature search, Hiroki Danura for his help in the screening of the Japanese literature, and Regina Zihlmann for screening of the Russian literature.

Author contributions. S. B., S. H., A. M., S. C., and P. K. were involved in patient care. S. B., S. H., T. Y., C. R. K., C. H., and P. K. performed the literature review. R. G. B. performed the microbiological analyses. S. B., S. H., and P. K. drafted a first version of the manuscript, which was critically appraised by all authors.

Financial support. P. K. is funded by the Swiss National Science Foundation (Personal Grant No. PZ00P3_179919).

Potential conflicts of interest. All authors: no reported conflicts of interest. All authors have submitted the ICMJE Form for Disclosure of Potential Conflicts of Interest.

References

- Newburger JW, Takahashi M, Gerber MA, et al.; Committee on Rheumatic Fever, Endocarditis and Kawasaki Disease; Council on Cardiovascular Disease in the

- Young; American Heart Association; American Academy of Pediatrics. Diagnosis, treatment, and long-term management of Kawasaki disease: a statement for health professionals from the Committee on Rheumatic Fever, Endocarditis and Kawasaki Disease, Council on Cardiovascular Disease in the Young, American Heart Association. *Circulation* **2004**; 110:2747–71.
- McCordle Brian W, Rowley Anne H, Newburger Jane W, et al. Diagnosis, treatment, and long-term management of Kawasaki disease: a scientific statement for health professionals from the American Heart Association. *Circulation* **2017**; 135:e927–e999.
- Ergüven O. Leptospirosis komplikasyonuna bağli Kawasaki, Göztepe Tıp Dergisi **20**: 248–9, **2005**. Available at: https://www.journalagent.com/z4/download_fulltext.asp?pdid=medeniyet&plng=tur&un=MEDJ-83436.
- Foo CCY, Leow EHM, Phua KB, Chong CY, Tan NWH. A case of Kawasaki disease with concomitant leptospirosis. *Glob Pediatr Health* **2017**; 4:2333794X1772136.
- Humphry T, Sanders S, Stadius M. Leptospirosis mimicking MLNS. *J Pediatr* **1977**; 91:853–4.
- Nateghian A, Hoseini S, Lavasani A. Leptospirosis mimicking collagen vascular disease in a thirteen-year-old Iranian girl. *researchgate.net*, **2012**; 7:69–71. Available at: https://www.researchgate.net/profile/Alireza_Nateghian/publication/284176295_Leptospirosis_Mimicking_Collagen_Vascular_Disease_in_a_Thirteen-Year-Old_Iranian_Girl/links/592c1be2458515e3d4703412/Leptospirosis-Mimicking-Collagen-Vascular-Disease-in-a-Thirteen-Year-Old-Iranian-Girl.pdf.
- Wang S, Wang Y. Leptospirosis: report of one case. *J Microbiol Immunol Infect* **1999**; 32:129–32.
- Wong M, Kaplan S, Dunkle L, Stechenberg B, Feigin RD. Leptospirosis: a childhood disease. *J Pediatr* **1977**; 32:129–32.
- Yeşilbaş O, Şevketoğlu E, Kılıç H, Hatipoğlu N. Leptospirosis in a child with acute respiratory distress syndrome. *researchgate.net*, **2017**; 59:688–92. Available at: https://www.researchgate.net/profile/Osman_Yesilbas/publication/326326035_Leptospirosis_in_a_child_with_acute_respiratory_distress_syndrome/links/5b45fd1fa6fdcc6619181df8/Leptospirosis-in-a-child-with-acute-respiratory-distress-syndrome.pdf.
- Мацко И, Шеремет А, Батын Г. Kawasaki syndrome as complication of leptospirosis in children. *elibrary.ru*, **2017**; 5:582–91. Available at: <https://elibrary.ru/item.asp?id=30318111>.
- Ogasawara T, Oka T, Narita M, Oshima M, Murata R. A case of leptospirosis encountered in a non-endemic region (Hokkaido Prefecture). *J-STAGE home / Kansenshogaku Zasshi* **2018**. Available at: https://www.jstage.jst.go.jp/article/kansenshogakuzasshi/92/2/92_144/_article-char/ja/.
- Kawasaki T. [Acute febrile mucocutaneous syndrome with lymphoid involvement with specific desquamation of the fingers and toes in children]. *Arerugi* **1967**; 16:178–222.
- Fraison JB, Sève P, Dauphin C, et al.; CRI and the French Vasculitis Study Group. Kawasaki disease in adults: observations in France and literature review. *Autoimmun Rev* **2016**; 15:242–9.
- Sève P, Stankovic K, Smail A, et al. Adult Kawasaki disease: report of two cases and literature review. *Semin Arthritis Rheum* **2005**; 34:785–92.
- Newburger JW, Takahashi M, Burns JC, et al. The treatment of Kawasaki syndrome with intravenous gamma globulin. *N Engl J Med* **1986**; 315:341–7.
- Benseler SM, McCordle BW, Silverman ED, et al. Infections and Kawasaki disease: implications for coronary artery outcome. *Pediatrics* **2005**; 116:e760–6.
- Barbour A, Krueger G, Feorino P, Smith C. Kawasaki-like disease in a young adult: association with primary Epstein-Barr virus infection. *JAMA* **1979**; 241:397–8. doi:10.1001/jama.1979.03290300039028.
- Bergeson P, Schoenike S. Mucocutaneous lymph node syndrome: a case masquerading as Rocky Mountain spotted fever. *JAMA* **1977**; 237:2299–302. doi:10.1001/jama.237.21.2299.
- Castagnoli R, Votto M, Licari A, et al. Severe acute respiratory syndrome coronavirus 2 (SARS-CoV-2) infection in children and adolescents: a systematic review. *JAMA Pediatr* **2020**; 174:882–9.
- Karpagam KB, Ganesh B. Leptospirosis: a neglected tropical zoonotic infection of public health importance—an updated review. *Eur J Clin Microbiol Infect Dis* **2020**; 39:835–46. doi:10.1007/s10096-019-03797-4.
- Fiechter GI. Leptospirosis in Switzerland: an emerging disease or emerging awareness? Available at: <https://archive-ouverte.unige.ch/unige:134857>. Accessed 21 December 2020.
- Bourquin V, Ponte B, Hirschel B, et al. Severe leptospirosis with multiple organ failure successfully treated by plasma exchange and high-volume hemofiltration. *Case Rep Nephrol* **2011**; 2011:817414.
- Schreiber PW, Aceto L, Korach R, Marreros N, Ryser-Degiorgis M-P, Günthard HF. Cluster of leptospirosis acquired through river surfing in Switzerland. *Open Forum Infect Dis* **2015**; 2:ofv102.
- Jansen A, Schöneberg I, Frank C, Alpers K, Schneider T, Stark K. Leptospirosis in Germany, 1962–2003. *Emerg Infect Dis* **2005**; 11:1048–54.

25. Hoenigl M, Wallner C, Allerberger F, et al. Autochthonous leptospirosis in South-East Austria, 2004–2012. *PLoS One* **2014**; 9:e85974.
26. Brockmann SO, Ulrich L, Piechotowski I, et al. Risk factors for human *Leptospira* seropositivity in South Germany. *SpringerPlus* **2016**; 5:1796.
27. Katz AR, Ansdell VE, Effler PV, Middleton CR, Sasaki DM. Assessment of the clinical presentation and treatment of 353 cases of laboratory-confirmed leptospirosis in Hawaii, 1974–1998. *Clin Infect Dis* **2001**; 33:1834–41.
28. Levett PN. Leptospirosis. *Clin Microbiol Rev* **2001**; 14:296–326.
29. Silva MV, Camargo ED, Batista L, et al. Behaviour of specific IgM, IgG and IgA class antibodies in human leptospirosis during the acute phase of the disease and during convalescence. *J Trop Med Hyg* **1995**; 98:268–72.
30. Wu Y, Liu FF, Xu Y, et al. Interleukin-6 is prone to be a candidate biomarker for predicting incomplete and IVIG nonresponsive Kawasaki disease rather than coronary artery aneurysm. *Clin Exp Med* **2019**; 19:173–81.
31. Reis EA, Hagan JE, Ribeiro GS, et al. Cytokine response signatures in disease progression and development of severe clinical outcomes for leptospirosis. *PLoS Negl Trop Dis* **2013**; 7:e2457.
32. Toubiana J, Poirault C, Corsia A, et al. Kawasaki-like multisystem inflammatory syndrome in children during the covid-19 pandemic in Paris, France: prospective observational study. *BMJ* **2020**; 369:m2094.
33. Gdoura R, Kchaou W, Chaari C, et al. *Ureaplasma urealyticum*, *Ureaplasma parvum*, *Mycoplasma hominis* and *Mycoplasma genitalium* infections and semen quality of infertile men. *BMC Infect Dis* **2007**; 7:129.