



## Original Article

# Radiological evaluation of the femoral tunnel positioning in anterior cruciate ligament reconstruction<sup>☆</sup>



Luciano Rodrigo Peres, Matheus Silva Teixeira\*, Caetano Scalizi Júnior, Wolf Akl Filho

Grupo do Joelho, Serviço de Ortopedia e Traumatologia, Hospital do Servidor Público Estadual de São Paulo, São Paulo, SP, Brazil

## ARTICLE INFO

## Article history:

Received 9 December 2015

Accepted 28 January 2016

Available online 8 June 2018

## Keywords:

Knee joint

Anterior cruciate ligament

Anterior cruciate ligament reconstruction

Radiography

Computed tomography by X-rays

## ABSTRACT

**Objective:** To evaluate the inclination and the length of the femoral tunnel in patients submitted to anterior cruciate ligament reconstruction (ACL) surgery by transtibial and anatomical techniques.

**Methods:** This is an analytical observational study in patients with ACL injury that underwent arthroscopic reconstruction through transtibial and anatomical surgical techniques. In the immediate postoperative period, computed tomography (CT) and anteroposterior (AP) view digital radiographs (X-rays) were performed to evaluate the inclination and length of the femoral tunnel.

**Results:** Forty-two patients were analyzed: 27 underwent anatomical reconstruction and 15, transtibial reconstruction. The inclination angle and tunnel length by the transtibial technique are always greater than by the anatomical technique. The mean inclination angles were 59.75° (53.9–66.1°) in the X-rays and 54.17° (43.5–62.3°) in CT for the transtibial technique, and 42.91° (29.3–57.4°) in the X-rays and 39.10° (23.8–50.6°) in CT for the anatomical technique. Regarding the length of the femoral tunnel, the transtibial technique promotes longer tunnels: mean 55.7 mm (40.0–70.2 mm) in the transtibial and 35.5 mm (24.5–47 mm) in the anatomical technique. No statistically significant correlation was observed between the length and the inclination of the tunnel, regardless of the technique used. Thus, these variables can be considered as independent.

**Conclusion:** The anatomical reconstruction technique presented shorter femoral tunnels and lower angle of inclination than the transtibial technique. The CT showed smaller inclination angle than the X-rays, regardless of the surgical technique.

© 2018 Sociedade Brasileira de Ortopedia e Traumatologia. Published by Elsevier Editora Ltda. This is an open access article under the CC BY-NC-ND license (<http://creativecommons.org/licenses/by-nc-nd/4.0/>).

<sup>☆</sup> Study conducted at Grupo do Joelho, Serviço de Ortopedia e Traumatologia, Hospital do Servidor Público Estadual de São Paulo, São Paulo, SP, Brazil.

\* Corresponding author.

E-mail: [matheus.st@hotmail.com](mailto:matheus.st@hotmail.com) (M.S. Teixeira).

<https://doi.org/10.1016/j.rboe.2018.05.001>

2255-4971/© 2018 Sociedade Brasileira de Ortopedia e Traumatologia. Published by Elsevier Editora Ltda. This is an open access article under the CC BY-NC-ND license (<http://creativecommons.org/licenses/by-nc-nd/4.0/>).

## Avaliação radiológica do posicionamento do túnel femoral na reconstrução do ligamento cruzado anterior

### R E S U M O

#### Palavras-chave:

Articulação do joelho  
Ligamento cruzado anterior  
Reconstrução do ligamento cruzado anterior  
Radiografia  
Tomografia computadorizada por raios X

**Objetivo:** Avaliar a inclinação e o comprimento dos túneis femorais em pacientes submetidos a reconstrução do ligamento cruzado anterior (LCA) pelas técnicas transtibial e anatômica. **Métodos:** Estudo observacional analítico em pacientes com lesão do LCA submetidos à reconstrução artroscópica pelas técnicas cirúrgicas transtibial e anatômica. No pós-operatório imediato foram feitos os exames de tomografia computadorizada (TC) e radiografia digital simples (RX) na incidência anteroposterior para avaliação da inclinação e do comprimento do túnel femoral.

**Resultados:** Dos 42 pacientes analisados, 27 foram submetidos à reconstrução anatômica e 15 à reconstrução pela técnica transtibial. O ângulo de inclinação e o comprimento do túnel na técnica transtibial são sempre maiores do que na reconstrução anatômica. Os ângulos de inclinação na técnica transtibial foram 59,75° (53,9°-66,1°) no RX e 54,17° (43,5°-62,3°) na TC; na técnica anatômica, 42,91° (29,3°-57,4°) no RX e 39,10° (23,8°-50,6°) na TC. Em relação ao comprimento do túnel femoral, a técnica transtibial gera túneis mais longos. Em média 55,7 mm (40-70,2 mm) na técnica transtibial e 35,5 mm (24,5-47 mm) na anatômica. Não encontramos correlação estatisticamente significativa nos valores do comprimento *versus* inclinação do túnel, independentemente da técnica usada. Portanto, são variáveis independentes.

**Conclusão:** A técnica de reconstrução anatômica apresentou túneis femorais mais curtos e com ângulo de inclinação menor do que a técnica transtibial. A TC apresentou valores de inclinação do túnel menores do que o RX, independentemente da técnica cirúrgica.

© 2018 Sociedade Brasileira de Ortopedia e Traumatologia. Publicado por Elsevier Editora Ltda. Este é um artigo Open Access sob uma licença CC BY-NC-ND (<http://creativecommons.org/licenses/by-nc-nd/4.0/>).

## Introduction

The anterior cruciate ligament (ACL) is one of the most frequently injured ligaments in the human body. The incidence of ACL injuries is estimated to range from 0.24 to 0.34 injuries per thousand inhabitants per year.<sup>1</sup> Currently, due to the increase in the practice of sports activities, an increase in the incidence of injuries of this ligament has been observed mainly among young patients.<sup>2,3</sup>

Although ACL reconstruction is one of the most commonly performed surgeries worldwide (estimates indicate that between 75,000 and 100,000 procedures are performed annually in the United States),<sup>4</sup> there are still discussions regarding reconstruction techniques. With the development of arthroscopic techniques, the initial aim of isometric or transtibial surgeries did not re-establish the original ACL anatomy in most cases, failing to achieve rotational stability of the knee. Currently, there is a growing interest in ACL anatomical reconstruction techniques, which may promote better clinical results by being closer to the original anatomy.<sup>5</sup>

In ACL reconstruction surgery, the femoral and tibial tunnels that are made, determine the graft functional axis. The correct positioning of these tunnels is decisive for the success of the procedure. Several authors believe that inadequate positioning of these tunnels is the main cause of ACL reconstruction failure.<sup>6,7</sup> Some errors, such as creating femoral tunnels far from the native site of the ACL, result in excessive strain on the graft and can lead to failure.<sup>7,8</sup> Moreover, the vertical orientation of the graft fails to reproduce the natural

obliqueness of the ACL, which may limit the restoration of normal knee kinematics and the control of rotational stability.<sup>6,9</sup>

In addition to positioning, tunnel length is another important factor for the success of ligament reconstruction. It is a consensus in the literature that a proper contact of the tendon with the bone surface of the tunnel is essential for bone-tendon integration. However, there is no consensus regarding the ideal tunnel length for an adequate biological fixation.<sup>10,11</sup>

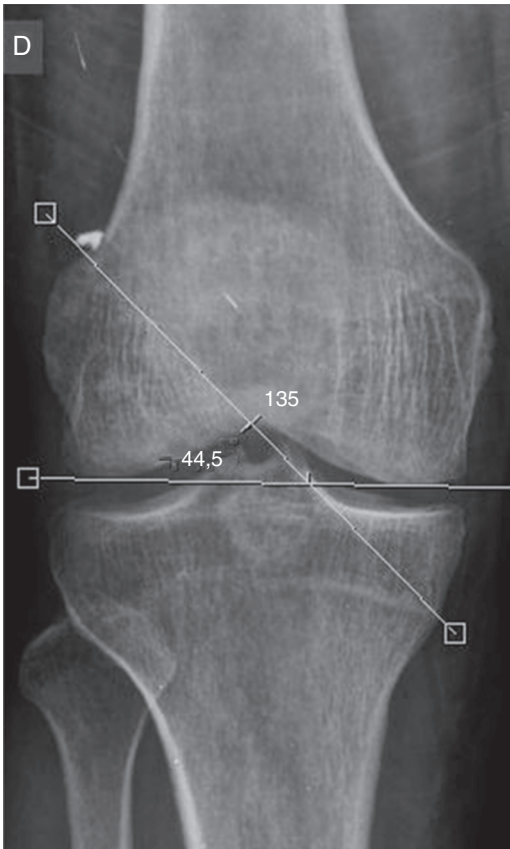
The aim of this study is to evaluate the inclination and length of femoral tunnels in patients who underwent ACL reconstruction through transtibial and anatomical techniques.

## Material and methods

This was an observational and analytical study conducted from February to December 2014, including 42 patients with ACL injuries that were attended at an outpatient knee surgery facility of a tertiary hospital.

The inclusion criterion was ACL injuries confirmed by magnetic resonance imaging. Patients with ACL injuries associated with other ligament injuries and/or osteochondral fractures that could jeopardize the positioning of the femoral or tibial tunnels were excluded.

Patients underwent arthroscopic reconstruction of the ACL through transtibial and accessory anteromedial transportal anatomical surgical techniques, with flexor tendons or patellar tendon grafts.



**Fig. 1 – Measurement of femoral tunnel inclination on X-ray.**

In the immediate postoperative period, anteroposterior (AP) view computed tomography (CT) and radiographs (X-rays) of the affected knee were made.

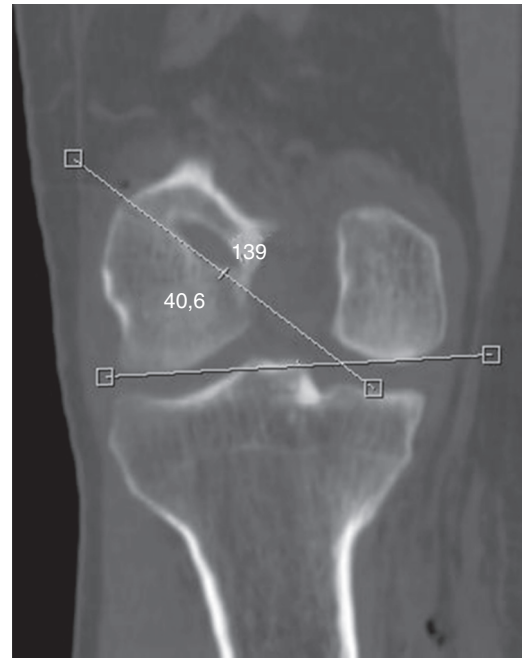The sample was studied regarding gender, age, and the surgical technique adopted. The inclination parameters and the femoral tunnel length by the transtibial and anatomical reconstruction techniques were compared.

Using the IMPAX<sup>®</sup> digital image filing and transmission system (version 6.3.1.7501, AGFA Health Care NV), the femoral tunnel inclination was digitally measured, in degrees, on the AP X-ray, taking into account the inferior border of the femoral tunnel in relation to a line parallel to the lower portion of the medial and lateral femoral condyle (Fig. 1).

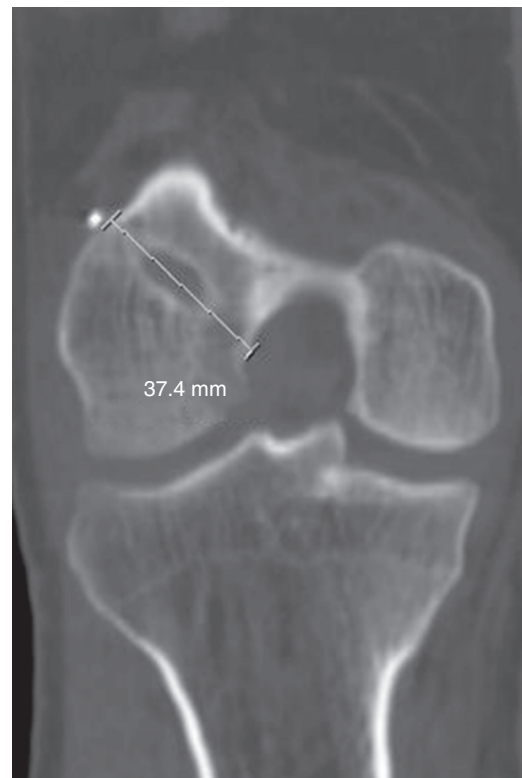
On the CT, the inclination (in degrees) of the femoral tunnel was also digitally evaluated; the inferior border of the tunnel was also taken into account, as well as the lower portion of the femoral condyles (Fig. 2).

The length of the femoral tunnel was assessed by CT, based on its extension from the medial cortex of the lateral femoral condyle to the lateral cortex of the femur (Fig. 3).

The angle of inclination of the femoral tunnel on the AP X-ray and on CT was comparatively assessed, both between the two imaging methods and between the surgical techniques applied, using the paired Student's t-test. The correlation between the angle of inclination measured on CT, and tunnel length was assessed using Pearson's correlation test.



**Fig. 2 – Measurement of femoral tunnel inclination on CT.**



**Fig. 3 – Measurement of femoral tunnel length on CT.**

The relative distribution according to gender was assessed with the equality test of two proportions; the ANOVA test was used to compare the means of age, angle, and length between the techniques. For all tests, the level of significance was set at 5%.

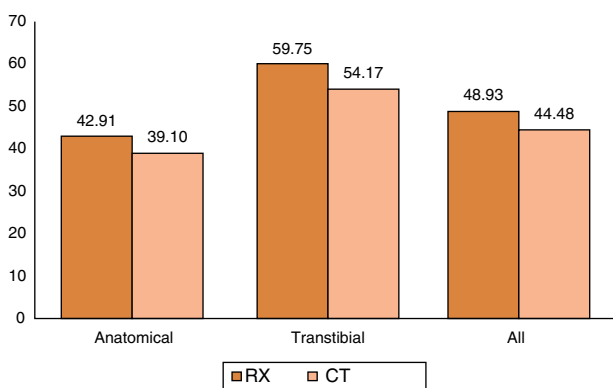
**Table 1 – Distribution of surgical techniques according to gender.**

| Gender | Anatomical |      | Transtibial |      | p     |
|--------|------------|------|-------------|------|-------|
|        | n          | %    | n           | %    |       |
| Female | 6          | 22.2 | 5           | 33.3 | 0.433 |
| Male   | 21         | 77.8 | 10          | 66.7 |       |

**Table 2 – Femoral tunnel inclination angles measured by X-ray and CT, according to surgical technique.**

|                    | Mean  | Median | Min  | Max  | n  | p      |
|--------------------|-------|--------|------|------|----|--------|
| <b>Anatomical</b>  |       |        |      |      |    |        |
| X-ray              | 42.91 | 44.0   | 29.3 | 57.4 | 27 | <0.001 |
| CT                 | 39.10 | 40.6   | 23.8 | 50.6 | 27 |        |
| <b>Transtibial</b> |       |        |      |      |    |        |
| X-ray              | 59.75 | 59.4   | 53.9 | 66.1 | 15 | <0.001 |
| CT                 | 54.17 | 56.2   | 43.5 | 62.3 | 15 |        |
| <b>All</b>         |       |        |      |      |    |        |
| X-ray              | 48.93 | 50.1   | 29.3 | 66.1 | 42 | <0.001 |
| CT                 | 44.48 | 43.5   | 23.8 | 62.3 | 42 |        |

X-ray, simple digital radiography; CT, computed tomography.



**Fig. 4 – Comparison of angles measured by X-ray and CT according to the surgical technique.**

The study was submitted to the Ethics and Research Committee of the Hospital, and approved through Plataforma Brasil, under No. 49115615.8.0000.5463.

**Results**

Data from 42 patients were analyzed, of whom 27 underwent ACL reconstruction by the anatomical technique and 15 by the transtibial technique (Table 1).

When comparing the mean angle of the femoral tunnel inclination on X-ray and CT for each surgical technique and both together, it was observed that the mean angle value on X-ray was always greater than on CT, ranging from 29.3° to 66.1° on X-ray and from 23.8° to 62.3° on CT. The mean measurements were 48.9° and 44.5°, respectively ( $p < 0.001$  – Fig. 4 and Table 2).

When assessing the correlation between the angle of inclination and the length of the femoral tunnel measured on CT, no correlation was observed between these values,

**Table 3 – Correlation between inclination angle and femoral tunnel length per surgical technique.**

|             | Correlation (r) | p-Value |
|-------------|-----------------|---------|
| Anatomical  | 0.172           | 0.390   |
| Transtibial | 0.191           | 0.495   |

regardless of the technique used. Therefore, these variables can be considered as statistically independent (Table 3).

When comparing the mean angle and length of the femoral tunnels between the techniques, it was verified that the values obtained with the transtibial technique were always superior to those of the anatomical technique, but without significant correlation (Fig. 5).

The patients’ ages ranged from 15 to 55 years. Regarding the angles, by the transtibial technique the mean values obtained by X-ray were 59.7° (range: 53.9° to 66.1°) and by CT, 54.2° (range: 43.5° to 62.3°). Regarding the anatomical technique, the values were 42.9° (range: 29.3° to 57.4°) on X-ray and 39.10° (range: 23.8° to 50.6°) on CT. The mean length of the tunnels was 35.5 mm (range: 24.5 mm to 47 mm) by the anatomical technique and 55.7 mm (range: 40.0 mm to 70.2 mm) by the transtibial reconstruction (Table 4 and Fig. 6).

**Discussion**

The correct positioning of the tunnels is the prime factor for successful ACL reconstruction surgery. Currently, there is a growing interest in adequately visualizing the position of the bone tunnels, their length, and their relationship with ACL insertions.

The main finding of the present study was that the mean angle of inclination of the femoral tunnel by the transtibial technique (X-ray: 59.7° and CT: 54.2°) is always greater than by the anatomical technique (X-ray: 42.9 and CT: 39.10°). It is a consensus in the literature that, in non-anatomical ligament

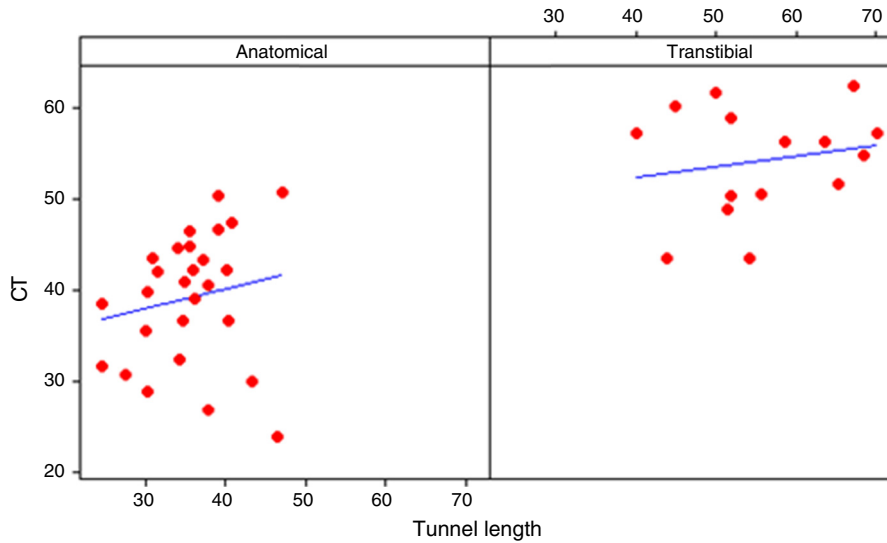


Fig. 5 – Comparison between angle and tunnel length by surgical technique.

Table 4 – Assessment of the age, inclination angle, and tunnel length, according to the surgical technique.

| Surgical technique   | Mean  | Median | Standard deviation | CV (%) | Min  | Max  | n  | p      |
|----------------------|-------|--------|--------------------|--------|------|------|----|--------|
| <b>Age</b>           |       |        |                    |        |      |      |    |        |
| Anatomical           | 35.2  | 37     | 10.2               | 29     | 15   | 49   | 27 | 0.192  |
| Transtibial          | 30.7  | 29     | 11.2               | 37     | 16   | 55   | 15 |        |
| <b>X-ray angle</b>   |       |        |                    |        |      |      |    |        |
| Anatomical           | 42.91 | 44.0   | 7.94               | 19     | 29.3 | 57.4 | 27 | <0.001 |
| Transtibial          | 59.75 | 59.4   | 4.16               | 7      | 53.9 | 66.1 | 15 |        |
| <b>CT angle</b>      |       |        |                    |        |      |      |    |        |
| Anatomical           | 39.10 | 40.6   | 7.16               | 18     | 23.8 | 50.6 | 27 | <0.001 |
| Transtibial          | 54.17 | 56.2   | 5.94               | 11     | 43.5 | 62.3 | 15 |        |
| <b>Tunnel length</b> |       |        |                    |        |      |      |    |        |
| Anatomical           | 35.50 | 35.5   | 5.74               | 16     | 24.5 | 47.0 | 27 | <0.001 |
| Transtibial          | 55.76 | 54.2   | 9.50               | 17     | 40.0 | 70.2 | 15 |        |

CV, coefficient of variation; X-ray, simple digital radiography; CT, computed tomography.

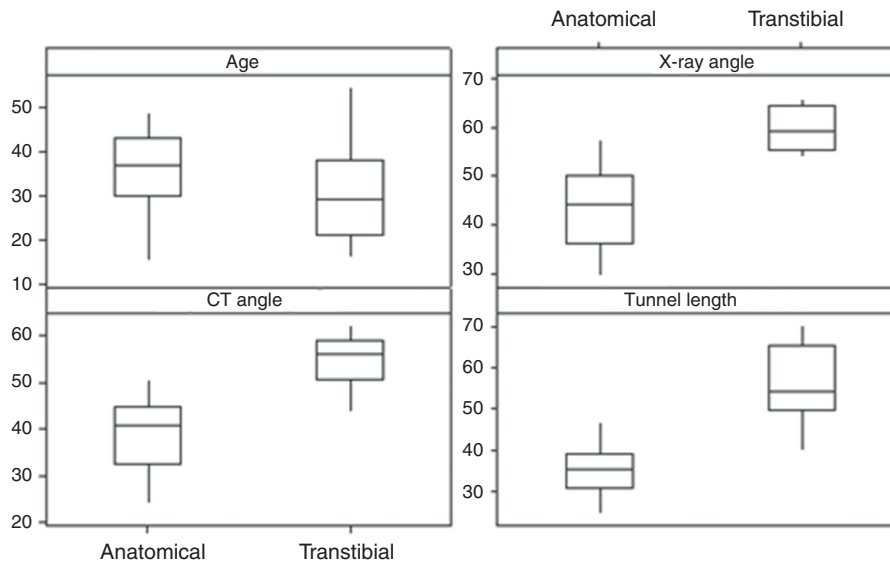


Fig. 6 – Boxplot of the techniques by age, angle on X-ray and CT, and tunnel length.



reconstruction, the femoral tunnel is in a more vertical and anterior position than the insertion site of the native ligament.<sup>12</sup> A study by Aglietti et al.<sup>13</sup> demonstrated that the two-incision technique presented a significantly lower mean femoral angle in the AP X-ray (37°) when compared with the one-incision technique (68°). Vieira et al.<sup>14</sup> observed that the angles in anatomical reconstructions are smaller than in transtibial procedures, as the former have a more horizontal orientation. The mean difference between the tunnel angles, measured on X-rays, was 16.74°. In this study, the mean difference between the angles was 16.8°. However, unlike the present study, Vieira et al.<sup>14</sup> measured the inclination of the tunnels in relation to the anatomical axis of the femur.

Illingworth et al.<sup>5</sup> reported that tunnels positioned more anteriorly, compatible with non-anatomical reconstruction techniques, are significantly correlated with a reduction in the femoral tunnel angle and an increase in the inclination angle. Patients who present an angle of inclination of the femoral tunnel on X-rays lower than 32.7° or greater than 55° are likely to have their ACL rebuilt outside anatomical limits.<sup>5</sup> In the present study, it was observed that the patients who underwent anatomical reconstruction presented a femoral tunnel angle ranging from 29.3° to 57.4°, while in those who underwent transtibial reconstruction, this angle ranged from 53.9° to 66.1°. However, the method used by those authors to measure the angles is not the same adopted in the present study, and their data were compared with MRI images rather than CT.

Regarding the length of the tunnels measured on CT, it was not possible to establish an association between inclination and length. In the present study, the mean tunnel length was 35.5 mm (range: 24.5–47) by the anatomical reconstruction and 55.7 mm (range: 40–70.2) by the transtibial method. In a cadaveric study, Golish et al.<sup>15</sup> assessed the position and technique of knee drilling and found that increased obliquity causes a decrease in tunnel length.<sup>15,16</sup> The mean length obtained by anatomical reconstruction was 23.1 mm; by transtibial reconstruction, the values ranged from 37 to 61 mm. These values are lower than those obtained in the present study. In turn, Golish et al.<sup>15</sup> used only AP X-ray to perform the measurements, and the inclination was assessed according to the clock position, which makes the analyses less accurate than those made using CT images.

Also in a cadaveric study, Chang et al.<sup>17</sup> evaluated the relationship between the inclination and the length of the femoral tunnel by the anatomical and transtibial techniques. Their results demonstrated that an increase in the inclination leads to shorter tunnels, regardless of the surgical technique used. However, in their study the inclination parameters were also evaluated according to the clock position, and a sulcoplasty was performed in all cases to facilitate drilling the medial wall of the lateral femoral condyle.

Although the minimum femoral tunnel length required for adequate fixation is still slightly controversial,<sup>10,11</sup> tunnels shorter than 25 mm may have an insufficient bone-tendon contact surface.<sup>10,11,18</sup> Zantop et al.<sup>18</sup> compared ACL reconstructions on goat knees with graft lengths of 25 or 15 mm in the femoral tunnel. After six and 12 weeks, no differences were observed between the groups regarding stiffness and

maximum graft tension. In turn, Qi et al.<sup>11</sup> compared 5 mm, 10 mm, 15 mm, and 20 mm grafts in a canine model and found that biomechanical resistance was considerably reduced in grafts with a length of less than 15 mm. No significant differences were observed between the 15 mm and 20 mm grafts.

When comparing the inclination values obtained by X-ray and CT, it was observed that the mean angle on X-ray is always greater than on CT, regardless of the surgical technique: 48.9° and 44.5°, respectively. This can be explained by the fact that X-rays provide a two-dimensional projection of the three-dimensional bone geometry.<sup>12</sup> Accurate X-ray measurements are dependent on the alignment of the bone with the image plane, which can be difficult to achieve and can induce errors in the estimated tunnel position due to distortions and expansion of the image. Furthermore, important bone markers, such as the lateral intercondylar crest, are not visible on conventional radiographs.<sup>12,19</sup>

Hoser et al.<sup>20</sup> compared X-ray and CT for postoperative evaluation and found that the position of the femoral tunnel cannot be reliably measured in 92.2% of the AP X-rays and in 21.6% of the lateral view X-rays, due to inadequate visualization of the tunnels, especially in cases where there is no bone-tendon graft or radiopaque markers in the tunnel. In addition, the femoral tunnel may be difficult to visualize from a lateral X-ray by the quadrant method,<sup>21</sup> particularly in the case of non-anatomical reconstructions, as those tunnels are situated in a high position along the Blumensaat line. However, differently from the present study, Hoser et al.<sup>20</sup> did not analyze tunnel inclination; they only checked to see whether it was possible measuring the tunnels in the late postoperative period.

In their study, the anatomical reconstruction was performed using the transportal technique, which can lead to a more horizontal positioning of the femoral tunnel. X-ray measurements were made through a tangent line inferior to the image formed by the overlap of the entire femoral condyle. In turn, because the tunnel is posterior to the femoral condyle, the axial cut used for the calibration of CT images takes into account a more proximal position of the condyle curvature, which makes comparison impossible, since the reference lines for measurement cannot be parallel. Moreover, it would be necessary to know the true value of the femoral tunnel inclination; only in this way can the measurements of these exams be compared.

More effective ways of verifying the true inclination of the femoral tunnel and its relationship with the radiological assessment methods of its positioning are still required.

The present study has its limitations: only the positioning of the femoral tunnel was studied, disregarding the position of the tibial tunnel. Furthermore, the radiological exams were performed by different radiology technicians, and the surgeries were performed by different knee surgeons of a tertiary hospital.

---

## Conclusion

The anatomical reconstruction technique presented shorter femoral tunnels with a lower inclination angle when compared with the transtibial technique. CT presented lower

values of tunnel inclination than X-rays, regardless of the surgical technique.

### Conflicts of interest

The authors declare no conflicts of interest.

### REFERENCES

- Miyasaka K, Daniel DM, Stone ML, Hirshman P. The incidence of knee ligament injuries in the general population. *Am J Knee Surg.* 1991;4:3-8.
- Hootman JM, Dick R, Agel J. Epidemiology of collegiate injuries for 15 sports: summary and recommendations for injury prevention initiatives. *J Athl Train.* 2007;42(2):311-9.
- Karlsson J, Irrgang JJ, van Eck CF, Samuelsson K, Mejia HA, Fu FH. Anatomic single- and double-bundle anterior cruciate ligament reconstruction, part 2: clinical application of surgical technique. *Am J Sports Med.* 2011;39(09):2016-26.
- Yasuda K, Kondo E, Ichiyama H, Kitamura N, Tanabi Y, Tohyama H, et al. Anatomic reconstruction of the anteromedial and posteromedial bundles of the anterior cruciate ligament using hamstring tendon graft. *Arthroscopy.* 2004;20(10):1015-25.
- Illingworth KD, Hensler D, Working ZM, Macalena JA, Tashman S, Fu FH. A simple evaluation of anterior cruciate ligament femoral tunnel position: the inclination angle and femoral tunnel angle. *Am J Sports Med.* 2011;39(12):2611-8.
- Jeppesen CF, Lundberg-Jensen AK, Faunoe P. Does the position of the femoral tunnel affect the laxity or clinical outcome of the anterior cruciate ligament-reconstructed knee? A clinical, prospective, randomized, double-blind study. *Arthroscopy.* 2007;23(12):1326-33.
- Harner CD, Giffin JR, Duntzman RC, Annunziata CC, Friedman MJ. Evaluation and treatment of recurrent instability after anterior cruciate ligament reconstruction. *Instr Course Lect.* 2001;50:463-74.
- Zavras TD, Race A, Amis AA. The effect of femoral attachment location on anterior cruciate ligament reconstruction: graft tension patterns and restoration of normal anterior-posterior laxity patterns. *Knee Surg Sports Traumatol Arthrosc.* 2005;13(2):92-100.
- Lee MC, Seong SC, Lee S, Chang CB, Park YK, Jo H, et al. Vertical femoral tunnel placement results in rotational knee laxity after anterior cruciate ligament reconstruction. *Arthroscopy.* 2007;23(7):771-8.
- Yamazaki S, Yasuda K, Tomita F, Minami A, Tohyama H. The effect of intraosseous graft length on tendon-bone healing in anterior cruciate ligament reconstruction using flexor tendon. *Knee Surg Sports Traumatol Arthrosc.* 2006;14(11):1086-93.
- Qi L, Chang C, Jian L, Xin T, Gang Z. Effect of varying the length of soft-tissue grafts in the tibial tunnel in a canine anterior cruciate ligament reconstruction model. *Arthroscopy.* 2011;27(6):825-33.
- Zantop T, Wellmann M, Fu FH, Petersen W. Tunnel positioning of anteromedial and posterolateral bundles in anatomic anterior cruciate ligament reconstruction: anatomic and radiographic findings. *Am J Sports Med.* 2008;36(1):65-72.
- Aglietti P, Zaccherotti G, Menchetti PP, De Biase P. A comparison of clinical and radiological parameters with two arthroscopic techniques for anterior cruciate ligament reconstruction. *Knee Surg Sports Traumatol Arthrosc.* 1995;3(1):2-8.
- Vieira RB, Tavares LAP, Lasmar RCP, Da Cunha FA, Lisboa LAM. Análise radiológica do posicionamento do túnel femoral com as técnicas de reconstrução isométrica ou de reconstrução anatômica do LCA. *Rev Bras Ortop.* 2014;49(2):160-6.
- Golish SR, Baumfeld JA, Schoderbek RJ, Miller MD. The effect of femoral tunnel starting position on tunnel length in anterior cruciate ligament reconstruction: a cadaveric study. *Arthroscopy.* 2007;23(11):1187-92.
- Hensler D, Working ZM, Illingworth KD, Tashman S, Fu FH. Correlation between femoral tunnel length and tunnel position in ACL reconstruction. *J Bone Joint Surg Am.* 2013;95(22):2029-34.
- Chang CB, Yoo JH, Chung BJ, Seong SC, Kim TK. Oblique femoral tunnel placement can increase risks of short femoral tunnel and cross-pin protrusion in anterior cruciate ligament reconstruction. *Am J Sports Med.* 2010;38(6):1237-45.
- Zantop T, Ferretti M, Bell KM, Brucker PU, Gilbertson L, Fu FH. Effect of tunnel-graft length on the biomechanics of anterior cruciate ligament-reconstructed knees: intra-articular study in a goat model. *Am J Sports Med.* 2008;36(11):2158-66.
- Forsythe B, Kopf S, Wong AK, Martins CA, Anderst W, Tashman S, et al. The location of femoral and tibial tunnels in anatomic double-bundle anterior cruciate ligament reconstruction analyzed by three-dimensional computed tomography models. *J Bone Joint Surg Am.* 2010;92(6):1418-26.
- Hoser C, Tecklenburg K, Kuenzel KH, Fink C. Postoperative evaluation of femoral tunnel position in ACL reconstruction: plain radiography versus computed tomography. *Knee Surg Sports Traumatol Arthrosc.* 2005;13(4):256-62.
- Bernard M, Hertel P, Hornung H, Cierpinski T. Femoral insertion of the ACL. Radiographic quadrant method. *Am J Knee Surg.* 1997;10(1):14-21.