

Available online at www.sciencedirect.com

ScienceDirect

journal homepage: www.elsevier.com/locate/radcr

Case Report

Is horseshoe lung a component of VACTERL spectrum? Case report and review of literature ☆,☆☆

Carmen Cerron-Vela, MD^a, Fouad Youssef, MD^{b,d}, Kyle N. Cowan, MD, FRCSC^{c,d}, Jorge Davila, MD, FRCPC^{a,*}

Department of Medical Imaging, Children's Hospital of Eastern Ontario, University of Ottawa, Ottawa, Ontario, Canada

^a Molecular Biomedicine Program, Children's Hospital of Eastern Ontario, Ottawa, Ontario, Canada

^b Department of Cellular and Molecular Medicine, University of Ottawa, Ottawa, Ontario, Canada

^c Department of Surgery, Children's Hospital of Eastern Ontario, University of Ottawa, Ottawa, Ontario, Canada

ARTICLE INFO

Article history:

Received 12 January 2022

Revised 1 February 2022

Accepted 2 February 2022

Keywords:

Horseshoe lung

VACTERL

VACTERL association

Scimitar syndrome

Computed tomography angiography

ABSTRACT

Horseshoe lung (HL) is a rare congenital anomaly that has been classically associated with Scimitar syndrome. Very few cases have been described in the context of the VACTERL spectrum. We present a case of a newborn girl with mesocardia, tracheoesophageal fistula, and imperforated anus, who required O₂ support at birth and during hospitalization. A chest CT angiography revealed a HL as an incidental finding. We suspect that HL and the VACTERL spectrum, are not separated entities but likely a further expansion of VACTERL-associated symptoms. HL might be underdiagnosed in asymptomatic patients as Chest CT angiography is not part of the routine work up for patients with VACTERL association.

© 2022 The Authors. Published by Elsevier Inc. on behalf of University of Washington.

This is an open access article under the CC BY-NC-ND license

(<http://creativecommons.org/licenses/by-nc-nd/4.0/>)

Introduction

Horseshoe lung (HL) is a rare congenital anomaly of the lungs characterized by the presence of a midline isthmus of pulmonary parenchyma connecting bilateral posterobasal segments [1,2]. Almost 80% of HL cases have been associated with the classic features of Scimitar syndrome; [2] however, very few cases have been described in the context of the VACTERL spectrum [3]. We present a case of a newborn with tracheoe-

sophageal fistula (TEF), imperforated anus and an incidental diagnosis of HL. We explore if HL should be considered as a component of VACTERL spectrum.

Case report

A newborn girl, born via Cesarean section at 37 weeks, 4 days of gestation due to polyhydramnios and fetal distress, presented to our hospital at 5 hours of life. At birth, she weighed

☆ Competing Interest: No conflict of interest exists.

☆☆ Funding: No funding was received for this work.

* Corresponding author.

E-mail address: jdavila@cheo.on.ca (J. Davila).

<https://doi.org/10.1016/j.radcr.2022.02.014>

1930-0433/© 2022 The Authors. Published by Elsevier Inc. on behalf of University of Washington. This is an open access article under the CC BY-NC-ND license (<http://creativecommons.org/licenses/by-nc-nd/4.0/>)

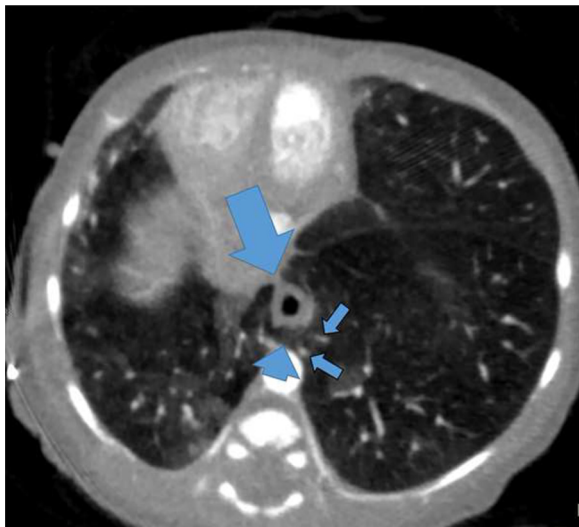


Fig. 1 – Axial chest CT angiography shows horseshoe isthmus (short arrow) surrounding the esophagus in almost 360 degrees (large arrow), with branches from the right pulmonary artery crossing through the isthmus to reach the left lower lobe (short arrows).

3.04 kg. Family history was not contributory, especially for congenital malformations. She is the fourth child in the family.

During prenatal care, unexplained mesocardia was found in three consecutive fetal ultrasounds. A fetal echocardiogram was showed the heart in mesocardic position, although the apex was pointing to the left. Other than this, there were no fetal cardiac abnormalities. A prenatal MRI was also performed at 31 weeks of gestational age for further evaluation. The fetal MRI showed mesocardia and two vessel cord without evidence of diaphragmatic hernia or mass.

At birth, she initially required CPAP at 40% due to grunting, and then eventually changed to low flow O₂. On examination, the patient was noted to have an imperforate anus and TEF given failure to pass a nasogastric tube (NG) and accumulation of oropharyngeal secretions.

Given her post-natal anomalies and prenatal diagnosis of mesocardia, a VACTERL workup was performed. A postnatal echocardiogram (ECO) showed a patent foramen ovale (PFO) with left to right flow and a small persistent ductus arteriosus (PDA) shunting bidirectionally. Additionally, bilateral superior vena cava was also noted, with a left superior vena cava (SVC) draining into a dilated coronary sinus and a left aortic arch with aberrant right subclavian artery. During her hospitalization, the patient continued with episodes of increased work of breathing, intermittent tachypnea and occasional grunting.

Chest CT angiography was performed to exclude a vascular ring. It showed a HL configuration, with the isthmus in the posterior mediastinum, anterior to the descending aorta, which was in midline position, and surrounding the distal esophagus posteriorly (Figs. 1 and 2). Branches of the right pulmonary artery were seen crossing the midline through the lung isthmus, feeding the left lower lobe parenchyma, and its venous return to the left lower pulmonary vein (Fig. 2). A distal branch of the right lower lobe bronchus was seen reaching

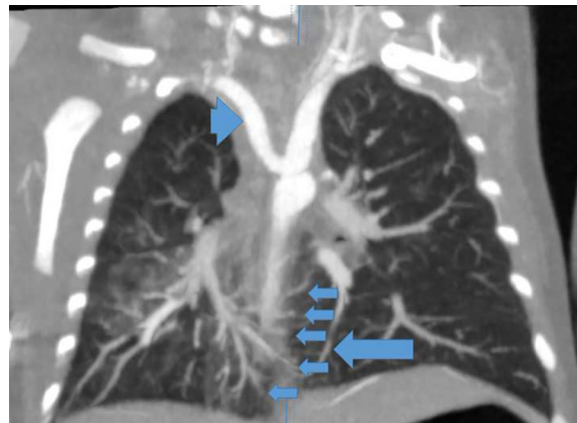

Fig. 2 – Coronal reformat chest CT angiography shows an aberrant right subclavian artery (long arrowhead), distal branches of the right pulmonary artery reaching the left lower lobe after crossing through the isthmus of the horseshoe lung (short arrows) and pulmonary veins from the left lower lobe draining into the left pulmonary venous system (long arrow).

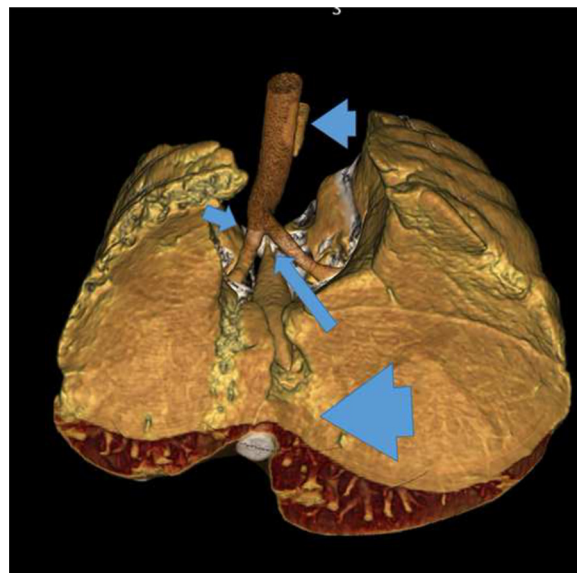


Fig. 3 – 3D reformat of chest CT angiography shows esophageal atresia (small arrowhead) with the distal esophageal segment originated from the tracheal carina (long arrow), absence of the right upper bronchial bronchus (short arrow) and horseshoe lung (large arrowhead).

the lung isthmus, possibly extending into the left lower lobe. Other findings included an esophageal atresia with distal TEF originated from the carina (N type/Gross type C) (Fig. 3), an absent upper right bronchus with hypoplastic/absent right upper lobe with hypoplasia of the right upper lobe, ground glass consolidations in the right and medial portion of left lung, and a left sided aortic arch with an aberrant right subclavian artery arising from the descending aorta at the level of the TEF without vascular ring.

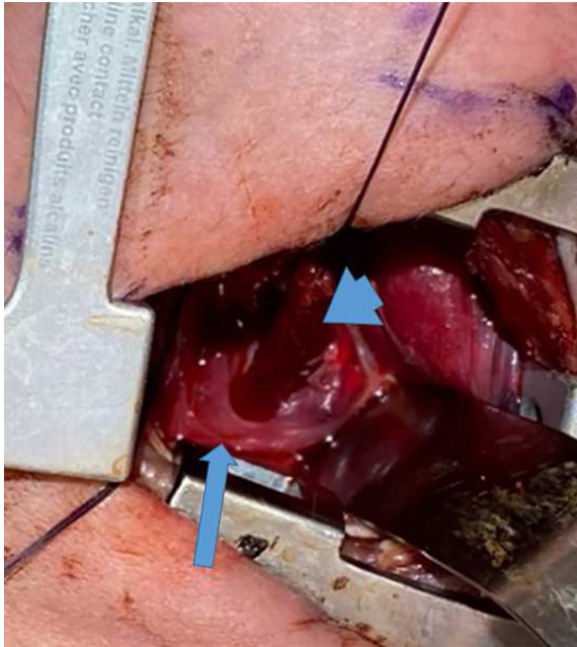


Fig. 4 – Intraoperative photography during right thoracotomy shows the distal esophagus (arrowhead) surrounded by the horseshoe lung (arrow).

The patient underwent an uncomplicated extra pleural repair of the TEF performed through a right thoracotomy on day 3 of life. The distal esophagus was completely surrounded by the HL (Fig. 4); however, there were no adhesions with the pulmonary tissue and the distal esophagus was readily dissected from the surround pleura of the horseshoe lung sufficient to approximate it to the proximal esophageal pouch. A primary anastomosis with the proximal pouch could be completed with minimal tension. As such, the horseshoe lung tissue was not resected. A temporary diverting loop colostomy was performed for the anorectal malformation. The patient had an uncomplicated postoperative course with an upper gastrointestinal study on post-operative day (POD) 7 confirming no anastomotic leak. The chest tube was removed on POD 8 and feeding was slowly advanced until full oral feeding was achieved and the patient was discharged home on day 20 of life.

Follow up echocardiogram showed spontaneous closure of the PDA, a small PFO shunting left to right, but significant persistent elevation of right ventricle (RV) pressures. The RV was not dilated and had reasonable function. The left ventricle was normal in size and function, giving a final diagnosis of persistent pulmonary hypertension, likely related to lung disease.

Discussion

Horseshoe lung (HL) was first described by Spencer in 1962 [4] and since its original description only a few cases have been reported in the world literature [1,3,2,5,6]. It is a rare congenital anomaly of the lungs that is characterized by the presence of a midline isthmus of pulmonary parenchyma, connecting the

posterobasal segments of the right and left lungs. [1,2]. Classic description includes vascular supply from a branch of the right pulmonary artery, and aeration from a distal branch of the right bronchial tree [7], as it was described in our case. Figa et al. [8] classified HL into three patterns: [1] lung fusion without the intervening pleura; [2] the presence of two pleural layers between the crossover lung tissue; and [3] the presence of four pleural layers between the crossover lung tissue, and the isthmus lung tissue is surrounded by its own visceral and parietal pleural envelopes. Our patient had lung fusion without an intervening pleura.

Almost 80% of HL cases have been associated with the classic features of Scimitar syndrome, also known as congenital pulmonary venolobar syndrome [2]. This complex of anomalies include: hypoplasia of the right lung, anomalous right pulmonary venous return, anomalous arterial supply to the right lung and anomalies of the right bronchial tree [2]. Posteriorly, although rare, HL has been reported in association with a left pulmonary artery sling and left pulmonary hypoplasia [9,10]. Association with other cardiovascular abnormalities, such as atrial septal defect, interventricular septal defect, persistent arteriosus ductus, and single left ventricle, may occur [11,12]. In addition, patients with HL have been reported to have tracheal and bronchial stenosis and anomalous bronchial bifurcation [11,13].

Our patient shares some of the mentioned pathological features above, including hypoplasia of the right lung (although the pulmonary venous return was normal bilaterally) and absence of the right upper lobe bronchus. The patient also had a patent foramen ovale and persistent ductus arteriosus; however these are expected with the patient's age. No clear association of HL with a left SVC or aberrant left right subclavian artery has been described. Only one case of a left SVC in an adult patient with HL was found in the literature [11].

In 1987 Hawass et al. [14], reported the first case of HL in a dead fetus, in association with multiple congenital anomalies including imperforated anus, horseshoe kidney, trachea-esophageal fistula and butterfly vertebra among others, suggesting a mesodermal error as a common embryologic origin. Obregon et al. [15] described additional cases of HL with a similar constellation of findings, suggesting that HL could be an additional component of the VACTERL association, arising as a result of the same disruption in development.

Other pulmonary anomalies including Scimitar syndrome have been reported in association with the VACTERL spectrum [16–18]. These associations may be a result of the same dysmorphogenetic process during blastogenesis [3,19]. In the same context, association of HL with Facio-Auriculo-Vertebral sequence has also been described [20].

The criteria for the diagnosis of VACTERL association, requires the presence of three or more of the six classically described anomalies [21]. Our patient presented with the following features for VACTERL: cardiovascular anomalies: aberrant subclavian artery, single umbilical artery; N-type, Gross C type tracheoesophageal fistula, and anorectal malformation [22].

The diagnosis of HL relies on demonstration of the isthmus, which could be easily achieved with the use of chest CT angiography. Imaging is also critical to identify the vascular and tracheobronchial anomalies associated with HL. HL was an incidental finding on the CT angiography in this infant. Un-

fortunately, chest CT angiography is not part of the routine presurgical work up in neonates with esophageal atresia, tracheoesophageal fistula or suspected VACTERL spectrum. Prognosis of HL depends on the degree of pulmonary hypoplasia and the severity of associated congenital malformations. This information may also be useful to inform and guide surgical planning [9,23].

The clinical presentation of patients with HL is variable, particularly because it usually occurs in the presence of other anomalies. Asymptomatic patients are usually diagnosed after an incidental finding on radiographic imaging [5,6], as was the case with our patient.

Based on published articles that have described a strong association between HL and VACTERL spectrum [3,14,15,19] and the reported association of Scimitar syndrome and VACTERL spectrum [17,18], we considered that HL syndrome should be considered as one of the criteria for diagnosis of this spectrum. Also, we suspect that there is underdiagnosis of HL in VACTERL spectrum, given the lack of inclusion of chest CT angiography as part of routine workup in these individuals.

In addition, our patient developed pulmonary hypertension. Although it is described that patients with HL involving left pulmonary hypoplasia are at high risk of pulmonary hypertension, there is no clear relationship between these two factors, given the limited number of cases [10]. Other features described in the literature resulting in pulmonary hypertension include a large ductus arteriosus, AV defect or obstruction of an anomalous vein [7], none of these were present in our patient.

The prognosis in cases of HL is dependent on the pulmonary artery pressure. Usually, the types of HL associated with normal pulmonary artery pressure are asymptomatic [6].

In conclusion, HL is a rare congenital anomaly, usually associated with Scimitar syndrome. Recent literature has shown evidence of association between HL with multiple midline abnormalities including VACTERL association; however, we suspect that HL is underdiagnosed in the setting of VACTERL spectrum, as chest CT angiography is not part of the routine work up in this entity. The combination of HL and VACTERL spectrum, HL and Scimitar syndrome, as well as the concomitant presentation of Scimitar syndrome and VACTERL association, as previously described in literature, are not random separated entities but likely a further expansion of VACTERL-associated symptoms.

Such comprehension should raise perinatal awareness for children with VACTERL association, leading to an earlier prenatal or postnatal diagnosis and therapy.

Authorship

We confirm that the manuscript has been read and approved by all named authors.

Intellectual Property

We confirm that we have given due consideration to the protection of intellectual property associated with this work and

that there are no impediments to publication, including the timing of publication, with respect to intellectual property. In doing so, we confirm that we have followed the regulations of our institutions concerning intellectual property.

Research Ethics

We further confirm that any aspect of the work covered in this manuscript that has involved human patients has been conducted with the ethical approval of all relevant bodies and that such approvals are acknowledged within the manuscript.

Patient Consent

Written consent to publish potentially identifying information, such as details or the case and photographs, was obtained from the patient(s) or their legal guardian(s).

Acknowledgement

We thank Cassandra Kapoor, research administrator in the Medical Imaging Department at CHEO, for her administrative and editorial support.

REFERENCES

- [1] Männer J, Jakob C, Steding G, Fuzesi L. Horseshoe lung: Report on a new variant - "Inverted" horseshoe lung - with embryological reflections on the formal pathogenesis of horseshoe lungs. *Ann Anat Anat Anz Off Organ Anat Ges* 2001;183:261–5.
- [2] Frank JL, Poole CA, Rosas G. Horseshoe lung: clinical, pathologic, and radiologic features and a new plain film finding. *AJR Am J Roentgenol* 1986;146(2):217–26.
- [3] Wales PW, Drab SA, Connolly B, Kim PCW. Horseshoe lung in association with other foregut anomalies: what is the significance? *J Pediatr Surg* 2002;37(August 8):1205–7.
- [4] Rogers SP. Spencer's pathology of the lung. *Histopathology* 1999;34(May 5):470.
- [5] Freedom RM, Burrows PE, Moes CA. Horseshoe lung: report of five new cases. *AJR Am J Roentgenol* 1986;146(February 2):211–15.
- [6] Dupuis C, Rémy J, Rémy-Jardin M, Coulomb M, Brevière GM, Ben Laden S. The "horseshoe" lung: six new cases. *Pediatr Pulmonol* 1994;17(February 2):124–30.
- [7] Haworth SG, Sauer U, Bühlmeier K. Pulmonary hypertension in scimitar syndrome in infancy. *Br Heart J* 1983;50(August 2):182–9.
- [8] Figa FH, Yoo SJ, Burrows PE, Turner-Gomes S, Freedom RM. Horseshoe lung—a case report with unusual bronchial and pleural anomalies and a proposed new classification. *Pediatr Radiol* 1993;23(1):44–7.
- [9] Oguz B, Alan S, Ozcelik U, Haliloglu M. Horseshoe lung associated with left-lung hypoplasia, left pulmonary artery sling and bilateral agenesis of upper lobe bronchi. *Pediatr Radiol* 2009;39(September 9):1002–5.

- [10] Bando Y, Nakagawa M, Ito K, Ozawa Y, Sakurai K, Shimohira M, et al. Horseshoe lung associated with left lung hypoplasia: case report and systematic review of the literature. *Pol J Radiol* 2015;80:464–9.
- [11] Amuthabharathi M., Venkatesh M., Nagarajan K. A rare case of horseshoe lung with scimitar syndrome and persistent left superior vena cava. *Lung India Off Organ Indian Chest Soc.* 2018;35 August (4):354–6.
- [12] Takeda K, Kato N, Nakagawa T, Aoki K, Matsuda A. Horseshoe lung without respiratory distress. *Pediatr Radiol* 1990;20(8):604.
- [13] Cipriano P, Sweeney LJ, Hutchins GM, Rosenquist GC. Horseshoe lung in an infant with recurrent pulmonary infections. *Am J Dis Child* 1960 1975;129(November 11):1343–5.
- [14] Hawass ND, Badawi MG, Fatani JA, Meshari AA, Edrees YB. Horseshoe lung with multiple congenital anomalies. Case report and review of the literature. *Acta Radiol Stockh Swed* 1987 1987;28(December 6):751–4.
- [15] Obregon MG, Giannotti A, Digilio MC, Barbuti D, Mingarelli R, Dallapiccola B. Horseshoe lung: an additional component of the Vater association. *Pediatr Radiol* 1992;22(2):158.
- [16] Knowles S, Thomas RM, Lindenbaum RH, Keeling JW, Winter RM. Pulmonary agenesis as part of the VACTERL sequence. *Arch Dis Child* 1988;63(7 Spec No):723–6.
- [17] Fritz CJ, Reutter HM, Herberg U. Scimitar syndrome in a case with VACTERL association. *Cardiol Young* 2015;25(March 3):606–9.
- [18] Takawira FF, Omar F. Unusual variant of scimitar syndrome associated with an absent right pulmonary artery, stenosis of the inferior vena cava, hemi-azygous continuation and the VACTERL association. *Cardiovasc J Afr* 2013;24(3):e3–6.
- [19] Ipek MS, Zenciroglu A, Aydin M, Okumus N, Orun UA, Uner C. An uncommon association of vacterl complex with hypertrophic pyloric stenosis and horseshoe lung. *Genet Couns Geneva Switz* 2010;21(3):289–92.
- [20] D’Alessandro L, Kovesi T, Massoud S, Lougheed J, Hunter A, Reisman J. Horseshoe lung and facio-auriculo-vertebral sequence: a previously unreported association. *Pediatr Pulmonol* 2006;41(June 6):592–6.
- [21] van de Putte R, van Rooij IALM, Marcelis CLM, Guo M, Brunner HG, Addor M-C, et al. Spectrum of congenital anomalies among VACTERL cases: a EUROCAT population-based study. *Pediatr Res* 2020;87(February 3):541–9.
- [22] La Placa S, Giuffrè M, Gangemi A, Di Noto S, Matina F, Nociforo F, et al. Esophageal atresia in newborns: a wide spectrum from the isolated forms to a full VACTERL phenotype? *Ital J Pediatr* 2013;39:45.
- [23] Takahashi M, Murata K, Yamori M, Okuno M, Nakagawa M, Mori M, et al. Horseshoe lung: demonstration by electron-beam CT. *Br J Radiol* 1997;70(September 837):964–6.