Case Reports in Oncology

Case Rep Oncol 2023;16:1028–1032
DOI: 10.1159/000533888
Received: February 28, 2023
Accepted: August 11, 2023
Published online: September 25, 2023

Case Report

Use of Sotrovimab for COVID-19 in a Patient with International Germ Cell Consensus Classification Poor Prognosis Testicular Germ Cell Tumor

Hirotaka Nagasaka Shinichi Takebe Shotaro Yamamoto Takuya Kondo Hideyuki Terao Noboru Nakaigawa Takeshi Kishida

Department of Urology, Kanagawa Cancer Center, Yokohama, Japan

Keywords
COVID-19 · Non-seminoma · BEP · Germ cell tumor · Sotrovimab

Abstract
A 35-year-old man was diagnosed with stage IIIC non-seminoma with paralysis of the lower half of his body due to 8th thoracic spine metastasis. The patient received bleomycin, etoposide, and cisplatin (BEP) therapy. On day 4 of the second course of BEP, the patient developed a fever and was diagnosed with coronavirus disease (COVID-19). COVID-19 was suspected to worsen because of cancer and chemotherapy-induced immunosuppression. However, the benefits of continuing BEP therapy outweighed these risks. After obtaining fully informed consent, BEP therapy was continued from day 5, while sotrovimab (anti-COVID-19 drug) was administered. The second course of BEP was completed without worsening severe COVID-19 or bleomycin-induced lung injury. The patient completed four courses of BEP, with normalization of tumor markers, partial response on imaging, and improvement in lower body paralysis. In this case, we successfully treated a patient with testicular germ cell tumor with chemotherapy while having COVID-19 without treatment delay. During the COVID-19 pandemic, concomitant chemotherapy and COVID-19 treatment are warranted because delaying treatment will decrease the efficacy of highly curative diseases such as germ cell tumors.

Correspondence to:
Hirotaka Nagasaka, nagasakauro@gmail.com

Introduction

In the era of coronavirus disease (COVID-19) pandemic, concomitant treatment for cancer and COVID-19 may be required. However, the mortality risk from COVID-19 is 2.34–2.35 times higher in patients with cancer [1, 2]. COVID-19 may be more severe during chemotherapy due to myelosuppression. Granulocyte colony-stimulating factor (G-CSF) preparations have been associated with increased inflammatory cytokine levels, which may exacerbate pneumonia [3]. Furthermore, data on the safety of combination therapy with COVID-19 agents and chemotherapy are limited. However, it has been suggested that chemotherapy should be used in patients with potentially curative tumors, such as acute myelogenous leukemia, even when COVID-19 occurs. Here, we report a case of testicular tumor in which COVID-19 was detected during BEP therapy. A patient could complete chemotherapy without delay or dose reduction while controlling COVID-19. The CARE Checklist has been completed by the authors for this case report, attached as online supplementary material (for all online suppl. material, see https://doi.org/10.1159/000533888).

Case Presentation

A 35-year-old man visited our hospital with chief complaints of lower limb paralysis and enlarged testes. Tumor markers for germ cell tumors were alpha-fetoprotein 6,740 ng/mL, human chorionic gonadotropin 1.5 ng/mL, and lactate dehydrogenase 353 U/L. Magnetic resonance imaging showed bone metastasis at the 8th thoracic spine and spinal cord compression. Radiotherapy was immediately administered to 8th thoracic spine, and high-ligated orchiectomy was performed. Pathological results showed a mixed germ cell yolk sac tumor and teratoma. The patient was diagnosed with a poor-risk International Germ Cell Consensus Classification (IGCCC) stage IIIC metastatic testicular tumor. Four courses of bleomycin, etoposide, and cisplatin (BEP) therapy were planned for induction chemotherapy. On day 4 of the second course, the patient had a fever and showed a positive PCR test for COVID-19. Unfortunately, we were unable to examine the subtype because of equipment malfunctions and the urgency of the circumstance. The administration of sotrovimab was determined in accordance with the diagnosis of community-acquired infection. As no oxygenation was required and no radiological evidence of pneumonia was found, the patient was judged to have mild COVID-19 infection. However, worsening of COVID-19 infection was also a concern due to concomitant cancer and chemotherapy-induced bone marrow suppression. Finally, because of the IGCCC poor prognosis and paralysis due to metastatic spinal cord compression, the benefits of continuing BEP therapy were judged to outweigh the risks of worsening COVID-19. After obtaining fully informed consent, BEP therapy was continued from day 5, while sotrovimab (anti-COVID-19 drug) was administered. Sotrovimab is a monoclonal antibody that has been used for the treatment of mild-to-moderate COVID-19 with positive results of direct SARS-CoV-2 viral testing, and who are at high risk for progression to severe COVID-19, including hospitalization or death [4, 5]. G-CSF for prevention of myelosuppression was administered on days 13 and 14. The detailed treatment course is shown in Figure 1. The second course of BEP was administered without severe COVID-19 or bleomycin-induced lung damage. The treatment was completed with four courses of BEP chemotherapy without delay or dose reduction, with normalization of tumor markers, partial response on imaging, and resolution of lower extremity paralysis (Fig. 2). The patient has been progression-free for 8 months after completion of chemotherapy.

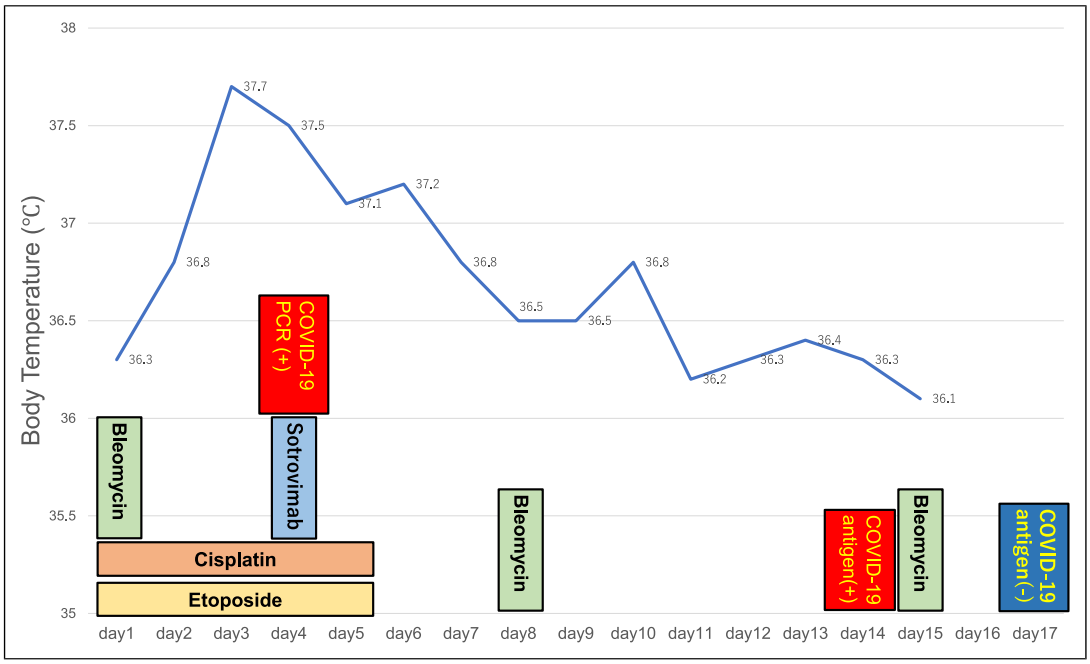

Fig. 1. Treatment course and temperature of a patient during hospitalization.

Discussion

We report a patient with non-seminoma who contracted COVID-19 during BEP therapy. Treatment was successfully completed without worsening the COVID-19 infection. One study reported that administering cytotoxic anticancer drugs for thoracic tumor treatment within 3 months of COVID-19 infection may increase mortality risk from COVID-19 [6]; however, another study reported no increased mortality risk [7]. When treating germ cell tumors, experts have recommended postponing chemotherapy until active COVID-19 infection has resolved or has been excluded by molecular testing [8]. In contrast, a multicenter study of 890 patients with various cancer types revealed that chemotherapy can be safely administered without worsening the course of COVID-19 [9]. The European Germ Cell Carcinoma Consensus Group (EGCCCG) and treatment guideline shows that four cycles of BEP should be administered at 22-day intervals and treatment deferral should rarely be considered to improve the prognosis of patients with poor prognosis [10, 11]. Although 80% of metastatic testicular tumors can be cured with appropriate chemotherapy, dose reduction and schedule delay can be factors in refractoriness. Several case reports have also demonstrated the safety of chemotherapy for COVID-19-positive patients with high-risk germ cell tumors [12, 13]. Therefore, in cases of poor prognosis or paralysis due to spinal cord compression that require early intervention, continuing chemotherapy even during COVID-19 infection is worthwhile. It was observed that there was a gap between the discovery of infection and the administration of bleomycin. However, as the patient did not experience any respiratory or pulmonary issues during this time, it was decided to proceed with administering bleomycin. In the case of a patient with multiple lung metastases and a respiratory disease history who contracts COVID-19, a shift in treatment approach from BEP regimen to VIP regimen (cisplatin, etoposide, ifosfamide) could be considered. It is important to take caution when transitioning to a VIP regimen due to the possibility of severe myelosuppression. To our knowledge, this is the first case in which sotrovimab, etoposide, and cisplatin were co-administered. There was one case in which sotrovimab was safely co-administered with chemotherapy for lymphoma [14] without any additional adverse events. In

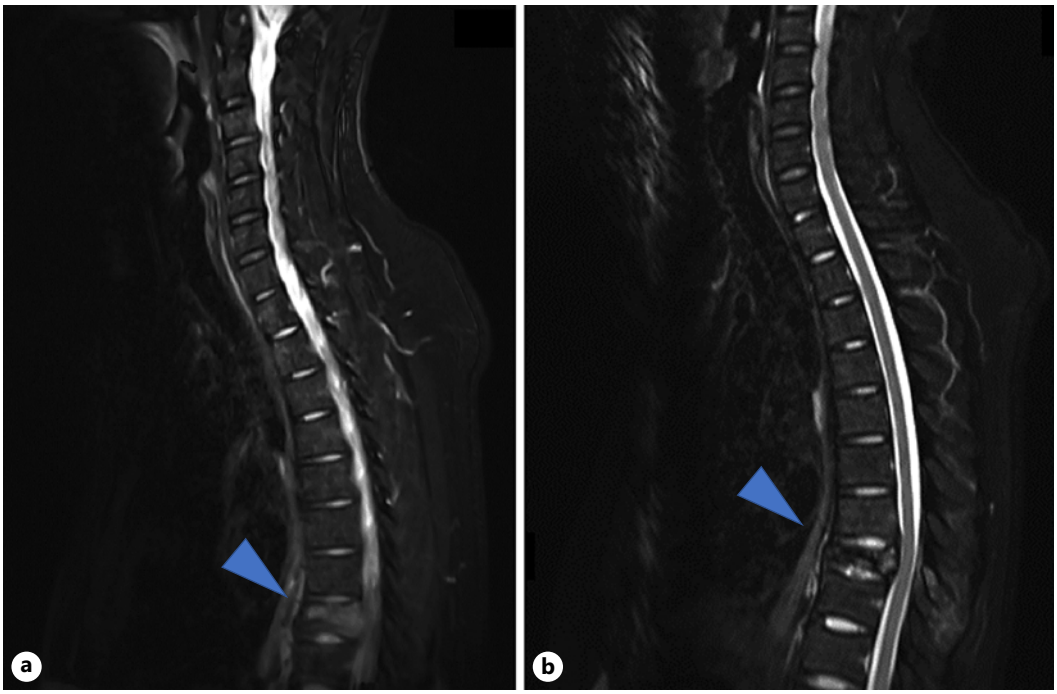

Fig. 2. a Magnetic resonance imaging (MRI) of Th8 spinal metastasis before treatment. **b** MRI of Th8 spinal metastasis at the end of treatment. Th8, 8th thoracic spine.

our case, G-CSF was administered during COVID-19 infection to prevent myelosuppression; however, no exacerbation of lung damage due to an increase in inflammatory cytokine levels was observed. However, administration of G-CSF to patients with neutropenic cancer and COVID-19 may lead to deterioration of their clinical condition and respiratory system [15]. It is important to be cautious when administering G-CSF to prevent myelosuppression. Adequate informed consent is necessary for each treatment, and a composite of various patient factors, such as age, medical history, tumor histology, and type of chemotherapy, must be considered.

Acknowledgments

We express our appreciation to all staff in ward 5E for this study. We would like to thank Editage (www.editage.com) for English language editing.

Statement of Ethics

Written informed consent was obtained from the patient for the publication of this case report and accompanying images. This study protocol was reviewed and approved by the Institutional Review Board at Kanagawa Cancer Center, approval number 2022-155.

Conflict of Interest Statement

The authors have no conflicts of interest to declare.

Funding Sources

The authors received no funds for this article.

Author Contributions

Hirotaka Nagasaka: data collection, manuscript writing, and hospital management. Shinichi Takebe, Shotaro Yamamoto, Takuya Kondo, Hideyuki Terao, and Noboru Nakaigawa: hospital management and manuscript editing. Takeshi Kishida: manuscript editing, supervision, and hospital management. All the authors have read and approved the final manuscript.

Data Availability Statement

All data generated or analyzed in this study are included in this article and its online supplementary material files. Further inquiries can be directed to the corresponding author.

References

1 Mehta V, Goel S, Kabarriti R, Cole D, Goldfinger M, Acuna-Villaorduna A, et al. Case fatality rate of cancer patients with COVID-19 in a New York hospital system. Cancer Discov. 2020 Jul;10(7):935–41.
2 Dai M, Liu D, Liu M, Zhou F, Li G, Chen Z, et al. Patients with cancer appear more vulnerable to SARS-CoV-2: a multicenter study during the COVID-19 outbreak. Cancer Discov. 2020 Jun;10(6):783–91.
3 Nawar T, Morjaria S, Kaltsas A, Patel D, Perez-Johnston R, Daniyan AF, et al. Granulocyte-colony stimulating factor in COVID-19: is it stimulating more than just the bone marrow? Am J Hematol. 2020 Aug;95(8):E210–3.
4 Gupta A, Gonzalez-Rojas Y, Juarez E, Crespo Casal M, Moya J, Falci DR, et al. Early treatment for covid-19 with SARS-CoV-2 neutralizing antibody sotrovimab. N Engl J Med. 2021 Nov 18;385(21):1941–50.
5 Aggarwal NR, Beaty LE, Bennett TD, Carlson NE, Davis CB, Kwan BM, et al. Real-world evidence of the neutralizing monoclonal antibody sotrovimab for preventing hospitalization and mortality in COVID-19 outpatients. J Infect Dis. 2022 Dec 13;226(12):2129–36.
6 Garassino MC, Whisenant JG, Huang LC, Trama A, Torri V, Agustoni F, et al. COVID-19 in patients with thoracic malignancies (TERAVOLT): first results of an international, registry-based, cohort study. Lancet Oncol. 2020 Jul;21(7):914–22.
7 Lee LY, Cazier JB, Angelis V, Arnold R, Bisht V, Campton NA, et al. COVID-19 mortality in patients with cancer on chemotherapy or other anticancer treatments: a prospective cohort study. Lancet. 2020 Jun 20;395(10241):1919–26.
8 Nappi L, Ottaviano M, Rescigno P, Tortora M, Banna GL, Baciarello G, et al. Management of germ cell tumors during the outbreak of the novel coronavirus disease-19 pandemic: a survey of international expertise centers. Oncologist. 2020 Oct;25(10):e1509–15.
9 Pinato DJ, Zambelli A, Aguilar-Company J, Bower M, Sng C, Salazar R, et al. Clinical portrait of the SARS-CoV-2 epidemic in European cancer patients. Cancer Discov. 2020 Jul 31;10(10):1465–74.
10 European Association of Urology. Guidelines: testicular cancer. 2023. Available from: https://uroweb.org/guidelines/testicular-cancer/.
11 Krege S, Beyer J, Souchon R, Albers P, Albrecht W, Algaba F, et al. European consensus conference on diagnosis and treatment of germ cell cancer: a report of the second meeting of the European Germ Cell Cancer Consensus group (EGCCCG): part I. Eur Urol. 2008 Mar;53(3):478–96.
12 Pedrazzoli P, Rondonotti D, Cattrini C, Secondino S, Ravanini P, Piralla A, et al. Metastatic mediastinal germ-cell tumor and concurrent COVID-19: when chemotherapy is not deferrable. Oncologist. 2021 Feb;26(2):e347–9.
13 Tanabe Y, Shukuya T, Nagata Y, Watanabe T, Seto K, Takahashi R, et al. Successful restart of chemotherapy in a patient with primary mediastinal nonseminomatous germ cell tumor after COVID-19 infection. Thorac Cancer. 2022 Sep;13(18):2654–8.
14 Cassin R, Rampi N, C FC, Muscatello A, Mariani B, Noto A, et al. Reply to "successful early use of anti-SARS-CoV-2 monoclonal neutralizing antibodies in SARS-CoV-2 infected hematological patients-A Czech multicenter experience": a case series of SARS-CoV-2 Omicron infection and aggressive lymphoma in the Sotrovimab era. Hematol Oncol. 2023;41(1):213–7.
15 Zhang AW, Morjaria S, Kaltsas A, Hohl TM, Parameswaran R, Patel D, et al. The effect of neutropenia and filgrastim (G-CSF) on cancer patients with coronavirus disease 2019 (COVID-19) infection. Clin Infect Dis. 2022 Mar 1;74(4):567–74.