




Utility of Follow-Up Echocardiograms in Uncomplicated PDA Device Closures Performed After Infancy

Rachel Reo · Erin Van Pelt · Casey Lovelace · Anne Eshelman ·
Brian Beckman · Joanne Chisolm · Brian Boe · Carl Backes ·
Clifford L. Cua 

Received: December 23, 2021 / Accepted: June 14, 2022 / Published online: July 3, 2022
© The Author(s) 2022

ABSTRACT

Introduction: Guidelines recommend lifelong follow-up with transthoracic echocardiograms (TTE) for patients who had a patent ductus arteriosus (PDA) device closure via catheterization. The goal of this study was to determine the utility of follow-up TTE in patients who underwent an uncomplicated PDA device closure after infancy.

Methods: Chart review was performed on patients who had a PDA closure ≥ 1 year of age between 1/1/2002 and 6/1/2020. Patients were excluded if they had other congenital heart disease, did not have a follow-up TTE ≥ 6 months after procedure, had a residual PDA or velocity > 2.0 m/s in the left pulmonary artery (LPA) or descending aorta (DAo) on the first TTE ≥ 6 months after device placement. Time points included the initial TTE after the procedure, first TTE ≥ 6 months after procedure, and the most recent TTE.

Results: A total of 189 patients met the study criteria. The median age and weight at initial procedure were 2.7 (1.0–64.7) years and 12.5

(3.4–69.2) kg. Most recent TTE was performed 2.0 (0.4–17.0) years after PDA closure. There were no significant differences in fractional shortening ($36.4 \pm 5.0\%$ vs. $36.9 \pm 5.6\%$) or LPA velocity (1.1 ± 0.4 m/s vs. 1.1 ± 0.4 m/s) from initial to most recent TTE, respectively. Left ventricular internal diastolic diameter Z-score significantly decreased (1.4 ± 1.8 vs. -0.01 ± 1.2 , $p < 0.01$) and DAo peak velocity significantly increased (1.2 ± 0.3 m/s vs. 1.3 ± 0.3 m/s, $p = 0.02$) from initial to most recent TTE, respectively. No patient died or underwent an intervention on the LPA or DAo for stenosis. Seventy-five patients had a total of 208 repeat TTE > 1 year after PDA procedure with no change in clinical management.

Conclusions: In patients who underwent an uncomplicated PDA closure after infancy, TTE parameters improved or stayed within normal limits on the most recent TTE. Repeat lifetime TTEs after 1-year post-device placement in this population may not necessarily be needed if there are no clinical concerns.

Keywords: Patent ductus arteriosus; Transthoracic echocardiogram; Echocardiogram

R. Reo · E. Van Pelt · C. Lovelace · A. Eshelman ·
B. Beckman · J. Chisolm · B. Boe · C. Backes ·
C. L. Cua (✉)
Heart Center, Nationwide Children's Hospital,
Columbus, OH, USA
e-mail: clcua@hotmail.com

Key Summary Points

Guidelines recommend intermittent lifelong echocardiograms in patients who underwent a transcatheter patent ductus arteriosus (PDA) device closure.

In this study, no significant complications were noted in patients that had an uncomplicated PDA device closure with follow-up echocardiograms.

The need for routine lifelong echocardiograms in this population should be further evaluated to determine the cost-effectiveness of this recommendation.

INTRODUCTION

A patent ductus arteriosus (PDA) represents one of the most common cardiovascular conditions observed in approximately 1 in 2000 term births, accounting for 5–10% of all congenital heart disease [1]. Usual treatment of a hemodynamically significant PDA during infancy has been via pharmacological, surgical, or transcatheter closure depending on the clinical situation [2–7]. In addition, PDAs may also be first diagnosed when patients are older [8]. PDAs discovered later in life may still meet indications for treatment [9]. In these older patients, device closure via catheterization procedure is a reasonable treatment option [10–17].

Complications associated with PDA device closure are well documented and include venous vascular damage, tricuspid valve damage, device embolization, left pulmonary artery stenosis, and descending aorta stenosis [18–28]. That said, most of these complications are noted early after device placement [20, 21, 24, 28]. Close echocardiographic follow-up in patients with device complications are clearly indicated. However, guidelines also state “in the first 2 years after PDA closure, either surgically or with a device, annual transthoracic echocardiogram (TTE) was rated appropriate (8/

9). TTE every 5 years was rated appropriate for surveillance of patients after successful device closure, even with no or mild sequelae (7/9)” [29]. The utility of follow-up TTEs in patients undergoing an uncomplicated PDA device placement is unknown.

The goal of this study was to determine the utility of follow-up echocardiograms in patients who underwent an uncomplicated PDA device closure performed after infancy.

METHODS

This study was approved by PDA Follow Up Echocardiograms (STUDY00001277). A retrospective chart review on all patients that underwent a PDA device closure ≥ 1 year of age between 1/1/2002 and 6/1/2020 was performed. Patients that had a PDA device closure < 1 year of age were excluded because believe that is a unique population due to possible prematurity issues that may affect outcomes. Patients were included if they had an uncomplicated PDA device placement in the catheterization laboratory and had no concerns on their first follow-up TTE 6 months post device placement. A ≥ 6 -month time period was chosen because there did not appear to be clinically significant TTE changes between TTE performed between 6 and 12 months versus TTE performed more than 12 months post device placement in post hoc analysis. This allowed for a larger “n” to be evaluated versus using a ≥ 12 -month post device cut off. Patients who had small muscular ventricular septal defects and/or patent foramen ovals were included. Patients were excluded if they had other congenital heart disease, had \geq moderate tricuspid regurgitation on initial post device TTE, had a velocity > 2.0 m/s in the left pulmonary artery (LPA) or descending aorta (DAo) on the first TTE ≥ 6 months after device placement, had a residual PDA on the first TTE ≥ 6 months after device placement, or did not have a follow-up TTE ≥ 6 months after procedure.

Demographic data collected included age and weight at time of PDA device placement, and most recent clinical status. Type of PDA device was recorded. The initial TTE post device placement,

the first TTE \geq 6 months post device placement, and the most recent TTE were reviewed. Echocardiographic data recorded included shortening fraction, left ventricular internal diastolic dimension Z-score, left pulmonary artery velocity, and descending aorta velocity.

Data are presented as means and standard deviations unless otherwise stated. Paired *t* tests were used for data analysis. Significance was set at $p < 0.05$.

RESULTS

Total of 363 patients were reviewed. One hundred seventy-four patients were excluded (no follow-up echocardiogram \geq 6 months post device placement, $n = 123$, congenital heart disease, $n = 41$; velocity > 2.0 m/s in the LPA on the first TTE \geq 6 months after device placement, $n = 5$; velocity > 2.0 m/s in the DAo on the first TTE \geq 6 months after device placement, $n = 3$; and residual PDA \geq 6 months after PDA device placement, $n = 2$). There were no deaths noted post-device placement as could be determined by hospital records for those patients discharged from clinic or lost to follow-up. This study therefore consisted of 189 patients.

Table 1 PDA device data

Device ($n = 189$)	<i>n</i>	%
Amplatzer Duct Occluder ^a	68	36.0
Amplatzer Duct Occluder II ^a	6	3.2
Amplatzer Duct Occluder II AS/Piccolo ^a	2	1.1
Amplatzer Vascular Plug ^a	10	5.3
Amplatzer Vascular Plug II ^a	13	6.9
Amplatzer muscular ventricular septal defect ^a	2	1.1
Nit Occlud ^b	63	33.3
Flipper Detachable Embolization Coil ^c	25	13.2

PDA patent ductus arteriosus

^aAbbott Cardiovascular

^bPlymouth, MN, USA; B Braun Interventional Systems, Bethlehem, PA, USA

^cCook Medical, Bloomington, IN, USA

Median age and weight at initial procedure were 2.7 (1.0–64.7) years and 12.5 (3.4–69.2) kg. Devices used for PDA closure are presented in Table 1. All patients were noted to be clinically doing well at their last clinic visit with no cardiac medications being administered and activity similar to peers documented in the clinic chart. Seventy-eight patients were discharged from cardiology clinic, 61 patients were lost to follow-up, and 50 patients are still being followed in cardiology clinic.

Initial TTE was performed 33.3 ± 125.3 days, median 0 days (0–1231 days) after PDA device placement, first follow-up TTE \geq 6 months post device placement was performed at 1.3 ± 1.4 years, median 1.0 year (0.5–13.5 years), and the most recent TTE was performed at 3.2 ± 3.2 years, median 2.0 years (0.5–17 years) post device placement. The left pulmonary artery velocity and left ventricular internal diastolic diameter were significantly different between the initial TTE post device placement and the first follow-up TTE \geq 6 months post device placement (Table 2). The DAo velocity and left ventricular internal diastolic diameter were significantly different between the initial TTE post device placement and the most recent

Table 2 Initial echocardiographic changes

	Initial echocardiogram ($n = 189$)	Follow-up echocardiogram ($n = 189$)
DAo velocity (m/s)	1.22 ± 0.33	1.23 ± 0.27
LPA velocity (m/s)	$1.14 \pm 0.39^*$	$1.07 \pm 0.29^*$
Shortening fraction (%)	36.51 ± 5.03	37.17 ± 4.85
LVIDD Z score	$0.88 \pm 1.58^*$	$0.03 \pm 1.14^*$
	$0.64 (- 2.44 to 6.59)$	$0.03 (- 3.29 to 3.09)$

DAo descending aorta, LPA left pulmonary artery, LVIDD left ventricular internal diastolic dimension

*Significant difference ($p < 0.05$)

Table 3 Final echocardiographic changes

	Initial echocardiogram (n = 94)	Most recent echocardiogram (n = 94)
DAo velocity (m/s)	1.20 ± 0.32*	1.28 ± 0.28*
LPA velocity (m/s)	1.14 ± 0.40	1.12 ± 0.35
Shortening fraction (%)	36.42 ± 5.03	36.94 ± 5.58
LVIDD Z score	1.36 ± 1.77*	− 0.05 ± 1.16*
	1.14 (− 2.31 to 6.59)	− 0.03 (− 4.20 to 2.42)

DAo descending aorta, LPA left pulmonary artery, LVIDD left ventricular internal diastolic dimension

*Significant difference

TTE (Table 3). Left pulmonary artery and descending aorta velocities over time are presented in Fig. 1.

No patient underwent a surgical or catheter intervention for left pulmonary artery or descending aorta stenosis. Seventy-five patients had a total of 208 TTE ≥ 1 year after PDA device placement. No clinical changes were made based on the follow-up TTE results.

DISCUSSION

Device closure for PDAs in the catheterization laboratory is a reasonable treatment option, especially for older patients [11, 19, 24]. Immediate complications are well known, but longer-term results are less well delineated. Because of the lack of long-term data, current guidelines state that it is appropriate to obtain TTEs on a regular basis, even in patients with no or mild sequelae [29]. In this study, patients

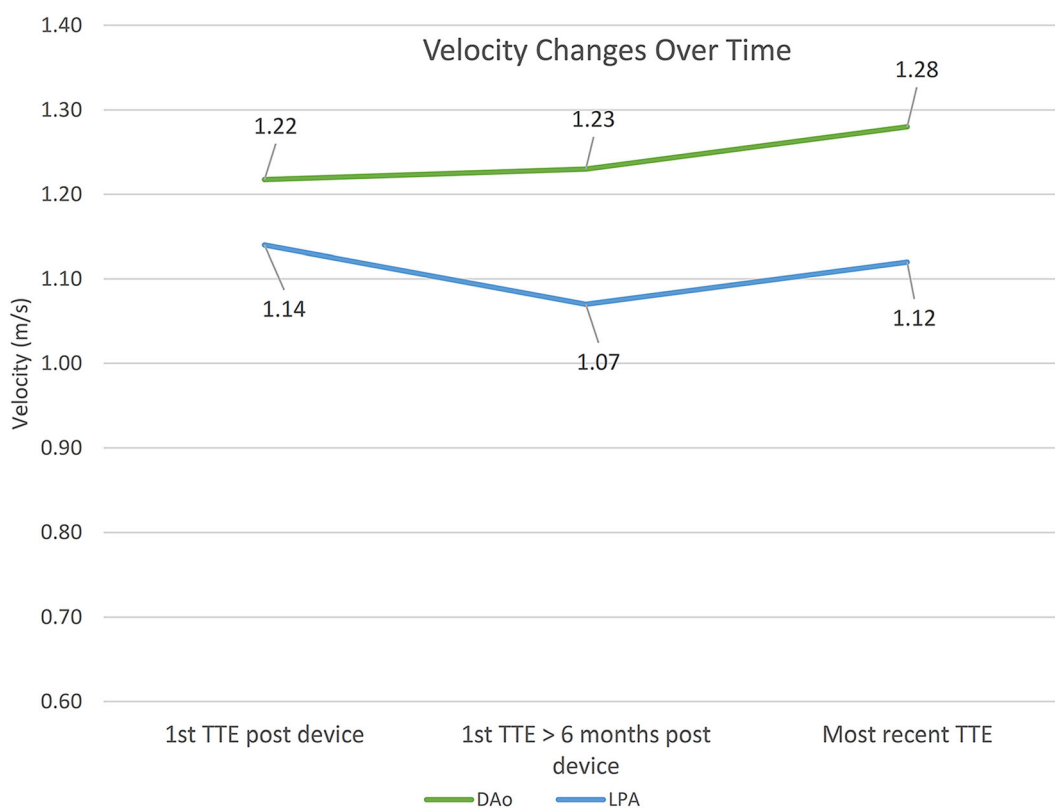


Fig. 1 Velocity changes over time in the left pulmonary artery and descending aorta

that underwent an uncomplicated PDA device closure after infancy had no long-term complications related to the PDA device. Follow-up surveillance TTEs for these patients did not change clinical management.

Reported complications after PDA device closure include venous/arterial vascular damage, tricuspid valve damage, device embolization, left pulmonary artery stenosis, and descending aorta stenosis [19, 22, 24, 28]. Most of these complications can be appreciated during the device procedure or relatively soon after the device procedure [19, 28]. In addition, most of these studies evaluated device closures performed during infancy with a large percentage of these patients being premature. Reported complications are significantly less in the older patient undergoing PDA device closure [10, 12–17]. This is likely due to technical issues based on the size of the patient.

Of these complications, left pulmonary artery and descending aorta stenosis are the complications that may be noted weeks to months after device placement [20, 21, 24, 30]. Previous studies in infants have noted increased velocities in the LPA and DAo immediately after PDA device placement that generally remained stable or improved over time [18, 20, 25]. Actual catheterization or surgical interventions to relieve LPA or DAo stenosis in infants is relatively rare with the incidence ranging from 0 to 4% [20–22, 25]. Most of these interventions also appeared to occur within the first few months after PDA device placement [20, 21, 24]. In patients undergoing PDA device closure at an older age, no reports of subsequent LPA or DAo stenosis requiring intervention have been reported [10–17]. Again, this is likely because the patients are larger and thus the device may be more easily judged as seated well or not in respect to the LPA or DAo.

This study, using an uncomplicated cohort of patients undergoing PDA device closure, reaffirms the above-noted published findings of stable ventricular function, normalization of left ventricular dimensions, and clinically stable velocities in the LPA and DAo with no need for catheter or surgical intervention in these vessels in the majority of patients [11–15, 20, 24, 30]. The DAo velocity did

significantly increase from initial TTE to most recent TTE in this study. The most recent DAo velocity of 1.3 m/s, however, is well within normal limits, and though statistically significant, is likely clinically not significant.

The earlier studies noted above studying PDA device closure evaluated all patients that underwent closure whereas this study only evaluated a select group of patients > 1 year of age that had no concerns after PDA device placement after a 6-month time-period. This may explain why no complications were reported in this study. This cohort was specifically chosen because of the recent guidelines that state that TTEs is generally acceptable and is generally reasonable for surveillance for the patient's lifetime even in an asymptomatic patient with no or mild sequelae [29]. There is no question if there are concerns on the immediate follow-up TTEs that close follow-up should be performed. That said, it is expressly stated, TTEs annually for the first 2 years and then every 5 years after device placement are appropriate in patients with no concerns. This study noted that there were no cardiac complications seen if there were no concerns on the first TTE \geq 6 months post device placement. The long-term complications of worsening LPA or DAo stenosis did not occur in this single-center patient cohort. To our knowledge, it has not been reported in other studies evaluating PDA device closures in children and adults. It may be that if there was no significant stenosis noted immediately post device placement, there would be no nidus for fibrosis and narrowing of the respective vessels, and somatic growth would prevent any subsequent stenosis [20, 25, 30].

These findings would suggest that the guidelines of lifelong TTE surveillance for this uncomplicated patient cohort could be changed from an "appropriate" rating of 7–9, to "may be appropriate" with a rating of 4–6. These guidelines do consider if clinical status and/or new concerning signs or symptoms arise that a TTE is appropriate with a rating of 9 (29). Follow-up for these patients could be changed to intermittent cardiology or even routine primary physician clinic visits with TTE only obtained if new findings such as upper-lower blood

pressure discrepancies, new-onset hypertension, or new murmur arise. Limiting the use of TTEs in this low-risk group would substantially decrease their lifetime healthcare cost. As seen in this study, there was a significant amount of TTEs \geq 1-year post device placement that did not change clinical management.

There were multiple limitations to this study. This was a single-center retrospective chart review study with all the inherent limitations of such a design. This was a relatively small select population evaluated, though one of the largest studies with a reasonable length of follow-up available. This study evaluated patients over an 18-year time span, so variances in individual and institutional management of PDA follow-up occurred and were not taken into account for analysis. There was no set echocardiographic timing schedule for these patients with the schedule determined by the primary cardiologist, so a more uniform analysis of TTE changes could not be performed. There were no long-term complications documented, so risk factors could not be determined. Approximately a third of patients were lost to follow-up so it is possible that late complications or mortality may have been missed, but we think that this is unlikely since these patients would have probably been referred back to our institution if clinical concerns had arisen or would have had mortality records noted in the hospital chart.

CONCLUSIONS

In patients who underwent an uncomplicated PDA closure after infancy, TTE parameters improved or stayed within normal limits on the most recent TTE. These findings need to be corroborated with larger studies with longer follow-up. If verified, the TTE guidelines need to be reassessed. Repeat lifetime TTEs after 1-year post-device placement in this population may not necessarily be needed if there are no clinical concerns.

ACKNOWLEDGEMENTS

Funding. No funding or sponsorship was received for this study or publication of this article.

Author Contributions. Concept/design: Carl Backes, Clifford L Cua. Data analysis/col-lection: Rachel Reo, Erin Van Pelt, Casey Lovelace, Anne Eshelman, Brian Beckman, Joanne Chisolm. Drafting: Rachel Reo, Clifford L Cua. Review/Approval: Rachel Reo, Erin Van Pelt, Casey Lovelace, Anne Eshelman, Brian Beckman, Joanne Chisolm, Brian Boe, Carl Backes, Clifford L Cua.

Disclosures. Rachel Reo, Erin Van Pelt, Casey Lovelace, Anne Eshelman, Brian Beckman, Joanne Chisolm, Brian Boe, Carl Backes, and Clifford L Cua all have nothing to disclose.

Compliance with Ethics Guidelines. This study was approved by PDA Follow Up Echocardiograms (STUDY00001277).

Data Availability. The data underlying this article will be shared on reasonable request to the corresponding author.

Open Access. This article is licensed under a Creative Commons Attribution-NonCommercial 4.0 International License, which permits any non-commercial use, sharing, adaptation, distribution and reproduction in any medium or format, as long as you give appropriate credit to the original author(s) and the source, provide a link to the Creative Commons licence, and indicate if changes were made. The images or other third party material in this article are included in the article's Creative Commons licence, unless indicated otherwise in a credit line to the material. If material is not included in the article's Creative Commons licence and your intended use is not permitted by statutory regulation or exceeds the permitted use, you will need to obtain permission directly from the copyright holder. To view a copy of this licence, visit <http://creativecommons.org/licenses/by-nc/4.0/>.

REFERENCES

- Mitchell SC, Korones SB, Berendes HW. Congenital heart disease in 56,109 births. *Incid Nat Hist Circ.* 1971;43:323–32.
- Martini S, Galletti S, Kelsall W, et al. Ductal ligation timing and neonatal outcomes: a 12-year bicentric comparison. *Eur J Pediatr.* 2021;180:2261–70.
- Lee JH, Lee HJ, Park HK, et al. Surgical ligation of patent ductus arteriosus in preterm neonates weighing less than 1500g: a 9-year single center experience. *J Cardiothorac Surg.* 2020;15:144.
- Kabra NS, Schmidt B, Roberts RS, et al. Neurosensory impairment after surgical closure of patent ductus arteriosus in extremely low birth weight infants: results from the Trial of Indomethacin Prophylaxis in Preterms. *J Pediatr.* 2007;150:229–34 (234 e1).
- Scerbo D, Cua CL, Rivera BK, et al. Percutaneous closure of the patent ductus arteriosus in very-low-weight infants. *NeoReviews.* 2020;21:e469–78.
- Heyden CM, El-Said HG, Moore JW, Guyon PW Jr, Katheria AC, Ratnayaka K. Early experience with the Micro Plug Set for preterm patent ductus arteriosus closure. *Catheter Cardiovasc Interv.* 2020;96:1439–44.
- Sathanandam SK, Gutfinger D, O'Brien L, et al. Amplatzer Piccolo Occluder clinical trial for percutaneous closure of the patent ductus arteriosus in patients \geq 700 grams. *Catheter Cardiovasc Interv.* 2020;96:1266–76.
- Connuck D, Sun JP, Super DM, et al. Incidence of patent ductus arteriosus and patent foramen ovale in normal infants. *Am J Cardiol.* 2002;89:244–7.
- Feltes TF, Bacha E, Beekman RH 3rd, et al. Indications for cardiac catheterization and intervention in pediatric cardiac disease: a scientific statement from the American Heart Association. *Circulation.* 2011;123:2607–52.
- Jin M, Liang YM, Wang XF, et al. A retrospective study of 1,526 cases of transcatheter occlusion of patent ductus arteriosus. *Chin Med J (Engl).* 2015;128:2284–9.
- Lam JY, Lopushinsky SR, Ma IWY, Dicke F, Brindle ME. Treatment options for pediatric patent ductus arteriosus: systematic review and meta-analysis. *Chest.* 2015;148:784–93.
- El-Said HG, Bratincsak A, Foerster SR, et al. Safety of percutaneous patent ductus arteriosus closure: an unselected multicenter population experience. *J Am Heart Assoc.* 2013;2: e000424.
- VanLoozen D, Sandoval JP, Delaney JW, et al. Use of Amplatzer vascular plugs and Amplatzer Duct Occluder II additional sizes for occlusion of patent ductus arteriosus: a multi-institutional study. *Catheter Cardiovasc Interv.* 2018;92:1323–8.
- Sudhakar P, Jose J, George OK. Contemporary outcomes of percutaneous closure of patent ductus arteriosus in adolescents and adults. *Indian Heart J.* 2018;70:308–15.
- Kobayashi D, Salem MM, Forbes TJ, et al. Results of the combined US multicenter postapproval study of the Nit-Occlud PDA device for percutaneous closure of patent ductus arteriosus. *Catheter Cardiovasc Interv.* 2019;93:645–51.
- Alkashkari W, Albugami S, Alrahimi J, et al. Percutaneous Device Closure of Patent Ductus Arteriosus in Adult Patients with 10-Year Follow-up. *Heart Views.* 2019;20:139–45.
- Wilson WM, Shah A, Osten MD, et al. Clinical outcomes after percutaneous patent ductus arteriosus closure in adults. *Can J Cardiol.* 2020;36: 837–43.
- Nealon E, Rivera BK, Cua CL, et al. Follow-up after percutaneous patent ductus arteriosus occlusion in lower weight infants. *J Pediatr.* 2019;212(144–150): e3.
- Backes CH, Kennedy KF, Locke M, et al. Transcatheter occlusion of the patent ductus arteriosus in 747 infants $<$ 6 kg: insights from the NCDR IMPACT Registry. *JACC Cardiovasc Interv.* 2017;10: 1729–37.
- Markush D, Tsing JC, Gupta S, et al. Fate of the left pulmonary artery and thoracic aorta after transcatheter patent ductus arteriosus closure in low birth weight premature infants. *Pediatr Cardiol.* 2021;42:628–36.
- Zahn EM, Peck D, Phillips A, et al. Transcatheter closure of patent ductus arteriosus in extremely premature newborns: early results and midterm follow-up. *JACC Cardiovasc Interv.* 2016;9: 2429–37.
- Sathanandam S, Balduf K, Chilakala S, et al. Role of transcatheter patent ductus arteriosus closure in extremely low birth weight infants. *Catheter Cardiovasc Interv.* 2019;93:89–96.
- Morville P, Akhavi A. Transcatheter closure of hemodynamic significant patent ductus arteriosus in 32 premature infants by Amplatzer Ductal

- Occluder additional size-ADOIIAS. *Catheter Cardiovasc Interv.* 2017;90:612–7.
24. Malekzadeh-Milani S, Akhavi A, Douchin S, et al. Percutaneous closure of patent ductus arteriosus in premature infants: a French national survey. *Catheter Cardiovasc Interv.* 2020;95:71–7.
 25. Tomasulo CE, Gillespie MJ, Munson D, et al. Incidence and fate of device-related left pulmonary artery stenosis and aortic coarctation in small infants undergoing transcatheter patent ductus arteriosus closure. *Catheter Cardiovasc Interv.* 2020;96:889–97.
 26. Chien YH, Wang HH, Lin MT, et al. Device deformation and left pulmonary artery obstruction after transcatheter patent ductus arteriosus closure in preterm infants. *Int J Cardiol.* 2020;312:50–5.
 27. Demir F, Celebi A, Saritas T, et al. Long-term follow-up results of lung perfusion studies after transcatheter closure of patent ductus arteriosus. *Congenit Heart Dis.* 2013;8:159–66.
 28. Dimas VV, Takao C, Ing FF, et al. Outcomes of transcatheter occlusion of patent ductus arteriosus in infants weighing \leq 6 kg. *JACC Cardiovasc Interv.* 2010;3:1295–9.
 29. Sachdeva R, Valente AM, Armstrong AK, et al. ACC/AHA/ASE/HRS/ISACHD/SCAI/SCCT/SCMR/SOPE 2020 appropriate use criteria for multimodality imaging during the follow-up care of patients with congenital heart disease: a report of the American College of Cardiology solution set oversight committee and appropriate use criteria task force, American Heart Association, American Society of Echocardiography, Heart Rhythm Society, International Society for Adult Congenital Heart Disease, Society for Cardiovascular Angiography and Interventions, Society of Cardiovascular Computed Tomography, Society for Cardiovascular Magnetic Resonance, and Society of Pediatric Echocardiography. *J Am Coll Cardiol.* 2020;75:657–703.
 30. Kramoh EK, Miro J, Bigras JL, et al. Differential pulmonary perfusion scan after percutaneous occlusion of the patent ductus arteriosus: one-decade consecutive longitudinal study from a single institution. *Pediatr Cardiol.* 2008;29:918–22.