

Eosinophilic granuloma with Splendore-Hoeppli material caused by *Mannheimia granulomatis* in a calf

Yuuto KAWASHIMA¹), Hiroyasu TAKAHASHI¹), Megumi SHIMOO²), Yukino TAMAMURA³), Yoshiharu ISHIKAWA³) and Koichi KADOTA³)*

¹)Tokachi Livestock Hygiene Service Center, 59–6 Kisen, Kawanishi, Obihiro, Hokkaido 089–1182, Japan

²)Agricultural Insurance Scheme of Tokachi, 23–3 Chuwakabamachi, Toyokoro, Nakagawa District, Hokkaido 089–5235, Japan

³)Hokkaido Research Station, National Institute of Animal Health, 4 Hitsujigaoka, Toyohira, Sapporo, Hokkaido 062–0045, Japan

(Received 23 December 2015/Accepted 23 February 2016/Published online in J-STAGE 4 March 2016)

ABSTRACT. A large subcutaneous mass, formed on the left lower jaw of a 4-month-old Japanese Black male calf, was partially excised for histological and bacteriological examinations. Antibiotic treatment resulted in a good prognosis. Bacteria isolated from the excised material were characterized by weak hemolysis and positive reactions for catalase and oxidase, and were 99% identical to *Mannheimia granulomatis* strains. The presence of the leukotoxin gene product was demonstrated by polymerase chain reaction amplification. Histological examination showed that the excised material was composed of dense fibrous connective tissue with sparsely distributed eosinophilic granulomas or abscesses. These foci frequently contained Splendore-Hoeppli material with rod-shaped Gram-negative bacteria. Except for the absence of lymphangitis and the presence of basophils and mast cells, the histology of this lesion resembled that of lechiguana associated with coinfection of *M. granulomatis* and *Dermatobia hominis*. Leukotoxin was demonstrated by immunohistochemistry within Splendore-Hoeppli material and was judged to be responsible for its formation.

KEY WORDS: cattle, eosinophilic granuloma, leukotoxin, *Mannheimia granulomatis*

doi: 10.1292/jvms.15-0717; *J. Vet. Med. Sci.* 78(6): 1075–1078, 2016

The Splendore-Hoeppli phenomenon is caused by the formation of intensely eosinophilic material around microorganisms (bacteria, fungi and parasites) or biologically inert substances *in vivo* [9]. Sulfur granules consisting of bacterial colonies and surrounding Splendore-Hoeppli material are usually encircled by neutrophils [10, 11]. No infectious agent has been found in eosinophilic gastroenteritis with similar material in ferrets [8], because this is caused by allergic reactions, and allergens usually cannot be detected by light microscopy. In contrast, either *Corynebacterium ulcerans* or *Nocardia* spp. are commonly observed in bovine nasal eosinophilic granulomas with Splendore-Hoeppli material [13, 15].

Mannheimia granulomatis, which is one of the five recognized species of the genus *Mannheimia* [2], mostly infects rabbits and hares, rarely cattle, and is associated with suppurative diseases [4, 5, 17]. However, eosinophilic lymphangitis and microabscesses with Splendore-Hoeppli material have been observed in bovine focal fibrogranulomatous proliferative panniculitis (lechiguana) associated with *M. granulomatis* and *Dermatobia hominis* warble [1]. The current study reports a case of mandibular eosinophilic granuloma in a 4-month-old calf, with particular emphasis on the relationship between the Splendore-Hoeppli phenom-

enon and leukotoxin produced by *M. granulomatis*.

In a farm in Hokkaido, the northern island of Japan, a 4 × 3 × 2 cm subcutaneous nodule was observed on the left lower jaw of a 3-month-old Japanese Black male calf in November 2014. From the clinical characteristics, a bacterial abscess was suspected, and antimicrobial treatment using penicillin and streptomycin was initiated. However, the lesion enlarged to 40 × 25 × 25 cm and was therefore partially excised for histological and bacteriological examinations one month later. Tissues from the deep part were firm and elastic, whereas those from the superficial part were soft and relatively vascular. Yellowish white microabscesses containing sulfur granules were scattered throughout these tissues, and some in the latter, softer, tissues were used for bacterial culture. Despite intramuscular penicillin injection, the mass became larger in size. Because of the penicillin and kanamycin resistance but marbofloxacin and chloramphenicol sensitivity of the isolated bacteria, the antibiotic was changed to marbofloxacin, and the mass diminished somewhat in size one month after surgery. Because an outbreak of pneumonia occurred on the farm, prophylactic florfenicol and tylosin were given to this animal 1.5 months after surgery. At the age of 6 months, the animal no longer appeared to have any lesions on the jaw, although several very hard nodules up to 2 cm in diameter were palpable.

The surgically removed tissues were fixed in 10% neutral buffered formalin, embedded in paraffin, sectioned at 4 μm and stained with hematoxylin and eosin (HE), Giemsa and Gram. Immunohistochemistry was carried out by the streptavidin-biotin complex/horseradish peroxidase (SAB) method on paraffin sections using a commercially available kit (Nichirei, Tokyo, Japan). A mouse monoclonal antibody

*CORRESPONDENCE TO: KADOTA, K., Hokkaido Research Station, National Institute of Animal Health, 4 Hitsujigaoka, Toyohira, Sapporo, Hokkaido 062–0045, Japan. e-mail: kkadota@affrc.go.jp

©2016 The Japanese Society of Veterinary Science

This is an open-access article distributed under the terms of the Creative Commons Attribution Non-Commercial No Derivatives (by-nc-nd) License <http://creativecommons.org/licenses/by-nc-nd/4.0/>.

to tryptase (clone AA-1, 1:200) (Lab Vision, Fremont, CA, U.S.A.) was used as the primary antibody. Immunostaining was also performed using a biotin-conjugated rabbit polyclonal antibody to *Mannheimia haemolytica* leukotoxin (1:5) (Cusabio, Hubei, China) as part of the kit. Antigen retrieval was done by microwave heating in 10 mM citrate buffer, pH 6.0 at 90°C for 9 min (tryptase) or enzymatic digestion with pepsin at 37°C for 25 min (leukotoxin).

Abscess material obtained from the excised tissues was cultured on 5% sheep blood agar at 37°C. The dominant strain was subcultured on MacConkey agar and used for Gram staining. In addition to catalase and oxidase, other biochemical characteristics of the strain were examined using the ID-test-HN-20 Rapid (Nissui Pharmaceutical Co., Tokyo, Japan), according to the manufacturer's instructions. A fragment of the 16S rRNA gene of the isolate was amplified by polymerase chain reaction (PCR) using the primers 27F and 1525R [12]. DNA sequencing was performed with an automated DNA sequencer ABI 3130 using an ABI Prism BigDye Terminator, version 3.1, Cycle Sequencing Kit (Applied Biosystems, Foster City, CA, U.S.A.), according to the manufacturer's protocol. The consensus sequence was imported into Genetyx, version 10.0 (Genetyx, Tokyo, Japan). The 16S rRNA gene sequence was analyzed using the BLAST search program. In order to detect the presence of the leukotoxin (lktA) gene product, the primers, Mg-lktA-F (5'-CAGGTTTATCTACWACAGG-3') and Mg-lktA-R (5'-GCTGCAATTCAGGTGGTG-3'), were designed based on reported sequences (Accession number: DQ301941, DQ301940 and DQ301939).

Although actinomycosis was macroscopically suspected, the isolated rod-shaped bacteria, which grew poorly on MacConkey agar, were negative for Gram, weakly hemolytic on bovine blood agar, positive for oxidase and weakly positive for catalase. The ID-test HN-20 Rapid system classified the bacteria as *M. haemolytica* complex. The 16S rRNA of this isolate shared 99% identity with *M. granulomatis* strains, W4672/1 and ATCC 49244. The lktA gene product was detected by PCR in the isolate.

On histological examination, the submandibular mass consisted of dense fibrous connective tissue, with sparsely distributed eosinophils, lymphocytes, plasma cells and mast cells. In some areas, collagenous fibers were calcified and were surrounded or phagocytosed by multinuclear giant cells. Cellular foci were detected in places. The majority was composed of eosinophil abscesses surrounded by histiocytes or epithelioid cells, frequently with eosinophilic hyaline deposits of Splendore-Hoeppli material (Fig. 1A). The presence of rod-shaped bacteria within the material was readily recognized by Giemsa staining (Fig. 1B); these were Gram-negative. Some deposits, which were full of necrotic eosinophils, were surrounded by epithelioid cells (Fig. 1C). Deposits encircled by well-developed epithelioid cells were accompanied by lymphocyte accumulation (Fig. 1D) and were rarely calcified. The presence of leukotoxin was demonstrated by immunohistochemistry in these deposits (Fig. 2A). In general, necrotic eosinophils tend to be confused with neutrophils, but in the abscesses, nearly all component

cells were eosinophils, and basophils, which stained purple with Giemsa and positive for tryptase (Fig. 2B), were admixed with them.

M. granulomatis has been isolated from cattle with subclinical mastitis, oral cavity abscesses and suppurative bronchopneumonia [4, 5], and from roe deer with diseases, such as pneumonia, stomatitis, glossitis, keratoconjunctivitis, and neck phlegmon and abscess [6]. In contrast to the lesions characterized by neutrophil infiltration or accumulation in the above diseases, this organism is also associated with eosinophilic lymphangitis and abscesses with Splendore-Hoeppli material in lechiguana, which is a disease caused by an interaction between the bacteria and *D. hominis* larvae [1]. Unlike in this disease [19], lymphangitis was not observed, but tryptase-positive basophils and mast cells were detected in the current case. Considering that *D. hominis* is not found in Japan and that human allergic bronchopulmonary aspergillosis occurs most commonly in patients with asthma or cystic fibrosis, especially those with coexisting atopy [7, 16], the present animal may have had a constitutional hypersensitivity to *M. granulomatis* [13].

In bovine nocardial eosinophilic granuloma, eosinophilic deposits of Splendore-Hoeppli material are formed between live epithelioid cells and intact filamentous bacteria, which are considered to play important roles in its formation [15]. In the current case, the presence of leukotoxin [20] was demonstrated at the transcriptional and protein levels, and a similar situation has been reported in a case of eosinophilic granuloma caused by *C. ulcerans* with diphtheria toxin production [13]. Leukotoxin exerts cytolytic activity against ruminant leukocytes, and also weak hemolytic activity [14], which was observed here in the cultured bacteria. Because eosinophils become incorporated into Splendore-Hoeppli material in human allergic conjunctival granulomas [18], it is highly probable that eosinophils undergoing coagulation necrosis by leukotoxin or diphtheria toxin [13] are the source of Splendore-Hoeppli material in the animals studied here and previously. Similarly, neutrophils phagocytosing intact bacteria underwent coagulation necrosis, with transformation to sulfur granules in a case of *Trueperella pyogenes* abscess in a heifer [15], although the presence of hemolysin (pyolysin) exhibiting cytotoxic effects on bovine neutrophils was not determined [3]. Splendore-Hoeppli material in the case of *C. ulcerans* was more abundant than in the current case [13]; the amount produced may depend on the cytotoxicity and quantity of the exotoxin produced by the bacteria in each case.

In human eosinophilic pneumonia associated with *Aspergillus* infection, steroid administration is effective in suppressing allergic reactions, but aggravates aspergilloma despite antifungal treatment [21]. Likewise, two heifers with nasal eosinophilic granuloma caused by *Nocardia* spp. died or had a poor prognosis, although antibiotic treatment with or without steroid medication was given [15]. In contrast, as in a case of *Corynebacterium* infection [13], the animal studied here had a good prognosis. In the former, surgical excision was very helpful in eliminating the majority of bacteria acting as pathogens as well as allergens [13]. Remission

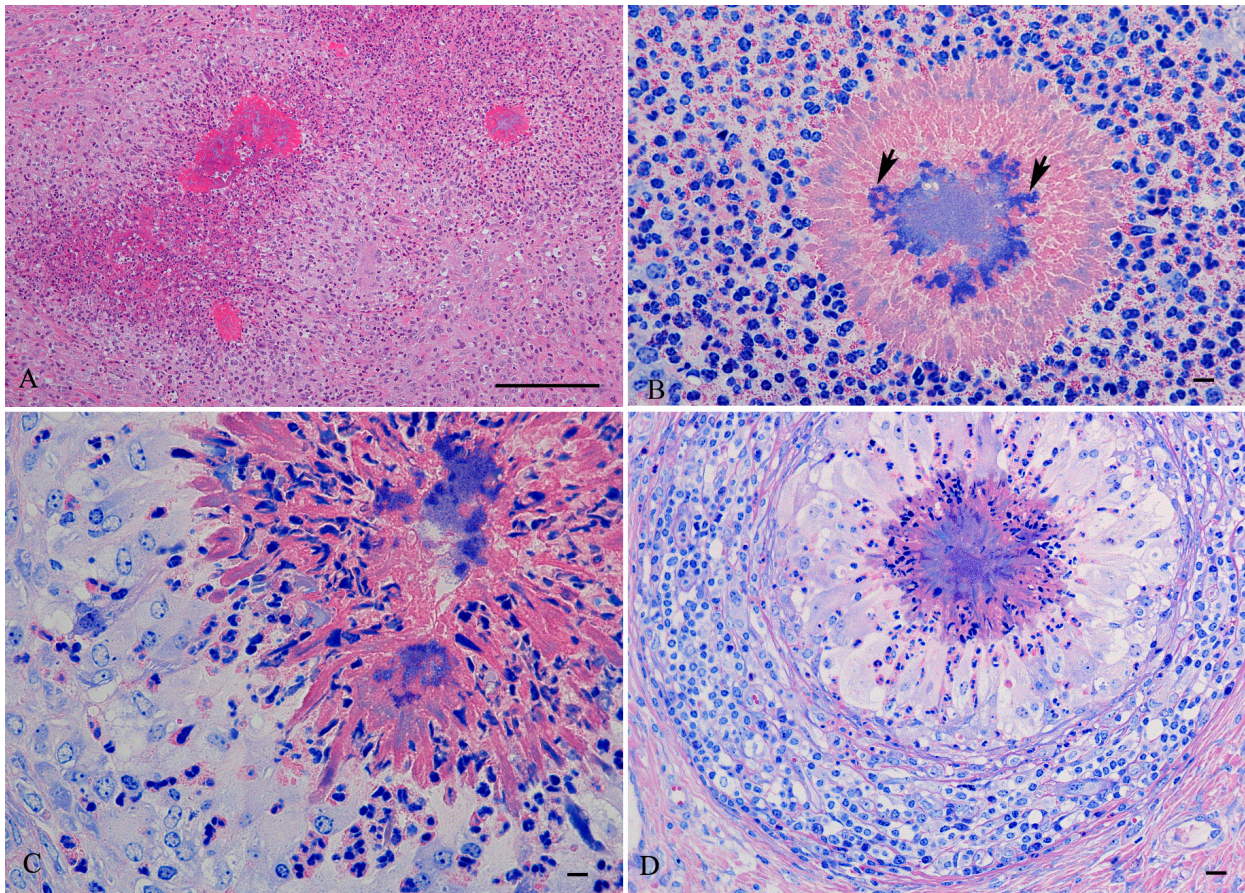


Fig. 1. Histology. (A) Eosinophilic hyaline deposits of Splendore-Hoeppli material are visible within eosinophilic abscesses, around which histiocytes or epithelioid cells are seen. HE. Bar=100 μ m. (B) This Splendore-Hoeppli material is surrounded by many eosinophils, and contains a bacterial colony, in which intact organisms are stained more intensely blue (arrows). Giemsa. Bar=5 μ m. (C) Eosinophils are becoming incorporated into the Splendore-Hoeppli material. Giemsa. Bar=5 μ m. (D) Well-developed epithelioid cells are observed around a sulfur granule composed of hyaline material, bacteria and necrotic eosinophils, and are encircled by accumulated lymphocytes. Giemsa. Bar=10 μ m.

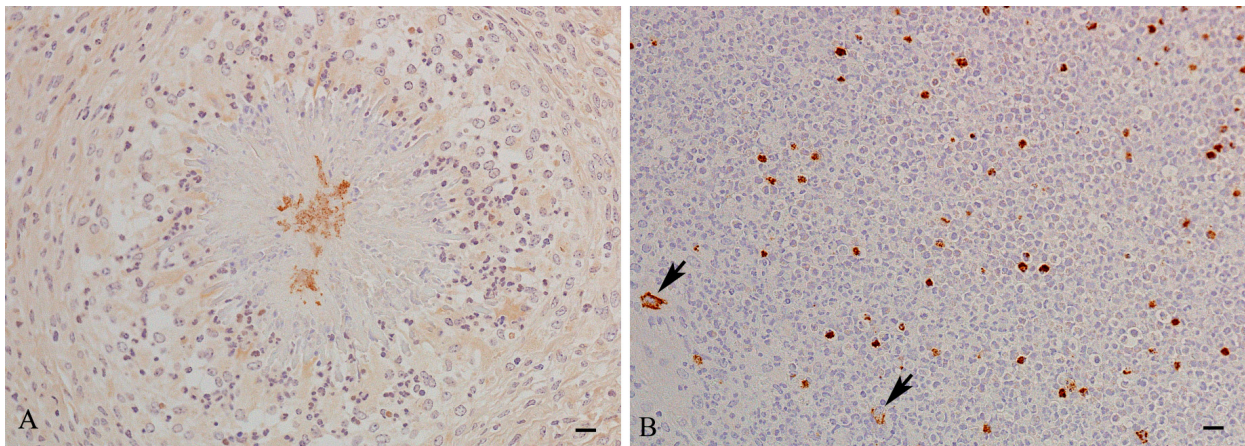


Fig. 2. Immunohistochemistry. (A) Staining for leukotoxin shows positivity within the same material as depicted in Fig. 1C. SAB. Bar=10 μ m. (B) Tryptase-positive basophils are scattered within an eosinophilic abscess and are smaller in size than mast cells located at its periphery (arrows). SAB. Bar=10 μ m.

of the lesion was achieved by chloramphenicol treatment in lechiguana [19] and also by injection of some antibiotics in the current case. Thus, antibiotic treatment is recommended for cattle with eosinophilic granuloma or abscesses caused by *M. granulomatis*, irrespective of botfly larvae infestation [19].

REFERENCES

- Andrade, G. B., Herrera, H. M., Barreto, W. T. G., Ladeira, S. L., Mota, E. M., Caputo, L. G. and Lenzi, H. L. 2015. Pathological aspects of bovine focal fibrogranulomatous proliferative panniculitis (Lechiguana). *Vet. Res. Commun.* **39**: 39–44. [Medline] [CrossRef]
- Angen, O., Mutters, R., Caugant, D. A., Olsen, J. E. and Bisgaard, M. 1999. Taxonomic relationships of the [*Pasteurella*] *haemolytica* complex as evaluated by DNA-DNA hybridizations and 16S rRNA sequencing with proposal of *Mannheimia haemolytica* gen. nov., comb. nov., *Mannheimia granulomatis* comb. nov., *Mannheimia glucosida* sp. nov., *Mannheimia ruminalis* sp. nov. and *Mannheimia varigena* sp. nov. *Int. J. Syst. Bacteriol.* **49**: 67–86. [Medline] [CrossRef]
- Billington, S. J., Jost, B. H., Cuevas, W. A., Bright, K. R. and Songer, J. G. 1997. The *Arcanobacterium* (*Actinomyces*) *pyogenes* hemolysin, pyolysin, is a novel member of the thiol-activated cytolysin family. *J. Bacteriol.* **179**: 6100–6106. [Medline]
- Blackall, P. J., Bisgaard, M. and Stephens, C. P. 2002. Phenotypic characterisation of Australian sheep and cattle isolates of *Mannheimia haemolytica*, *Mannheimia granulomatis* and *Mannheimia varigena*. *Aust. Vet. J.* **80**: 87–91. [Medline] [CrossRef]
- Blum, S., Freed, M., Zukin, N., Shwimmer, A., Weissblit, L., Khatib, N., Bojesen, A. M., Larsen, J., Friedman, S. and Elad, D. 2010. Bovine subclinical mastitis caused by *Mannheimia granulomatis*. *J. Vet. Diagn. Invest.* **22**: 995–997. [Medline] [CrossRef]
- Bojesen, A. M., Larsen, J., Pedersen, A. G., Mörner, T., Mattson, R. and Bisgaard, M. 2007. Identification of a novel *Mannheimia granulomatis* lineage from lesions in roe deer (*Capreolus capreolus*). *J. Wildl. Dis.* **43**: 345–352. [Medline] [CrossRef]
- Chetty, A. 2003. Pathology of allergic bronchopulmonary aspergillosis. *Front. Biosci.* **8**: e110–e114. [Medline] [CrossRef]
- Fox, J. G., Palley, L. S. and Rose, R. 1992. Eosinophilic gastroenteritis with Splendore-Hoeppli material in the ferret (*Mustela putorius furo*). *Vet. Pathol.* **29**: 21–26. [Medline] [CrossRef]
- Hussein, M. R. 2008. Mucocutaneous Splendore-Hoeppli phenomenon. *J. Cutan. Pathol.* **35**: 979–988. [Medline] [CrossRef]
- Kubo, M., Osada, M. and Konno, S. 1980. A histological and ultrastructural comparison of the sulfur granule of the actinomycosis and actinobacillosis. *Natl. Inst. Anim. Health Q. (Tokyo)* **20**: 53–59. [Medline]
- Kubo, M., Osada, M. and Konno, S. 1982. Morphology of sulfur granules produced by *Staphylococcus aureus* and *Corynebacterium pyogenes* in cows. *Natl. Inst. Anim. Health Q. (Tokyo)* **22**: 130–137. [Medline]
- Lane, D. J. 1991. 16S/23S rRNA sequencing. pp. 115–148. In: *Nucleic Acids Techniques in Bacterial Systematics* (Stackebrandt, E. and Goodfellow, M. eds.), Wiley, Chichester.
- Murakami, K., Hata, E., Hatama, S., Wada, Y., Ito, M., Ishikawa, Y. and Kadota, K. 2014. Eosinophilic granuloma with Splendore-Hoeppli material caused by toxigenic *Corynebacterium ulcerans* in a heifer. *J. Vet. Med. Sci.* **76**: 931–935. [Medline] [CrossRef]
- Murphy, G. L., Whitworth, L. C., Clinkenbeard, K. D. and Clinkenbeard, P. A. 1995. Hemolytic activity of the *Pasteurella haemolytica* leukotoxin. *Infect. Immun.* **63**: 3209–3212. [Medline]
- Oyama, T., Higashi, T., Taniguchi, Y., Hata, E., Hatama, S., Ishikawa, Y. and Kadota, K. 2016. Histological study of bovine nocardial eosinophilic granuloma with comparison of Splendore-Hoeppli material. *Jpn. Agric. Res. Q.* **50**: 169–173. [CrossRef]
- Patterson, K. and Streck, M. E. 2010. Allergic bronchopulmonary aspergillosis. *Proc. Am. Thorac. Soc.* **7**: 237–244. [Medline] [CrossRef]
- Tefera, G. and Smola, J. 2001. *Pasteurella haemolytica* complex of *Pasteurella sensu stricto* as new genus *Mannheimia*: changes in taxonomy. *Vet. Med. (Czech)* **46**: 119–124.
- Read, R. W., Zhang, J., Albini, T., Evans, M. and Rao, N. A. 2005. Splendore-Hoeppli phenomenon in the conjunctiva: immunohistochemical analysis. *Am. J. Ophthalmol.* **140**: 262–266. [Medline] [CrossRef]
- Riet-Correa, F., Méndez, M. C., Schild, A. L., Ribeiro, G. A. and Almeida, S. M. 1992. Bovine focal proliferative fibrogranulomatous panniculitis (Lechiguana) associated with *Pasteurella granulomatis*. *Vet. Pathol.* **29**: 93–103. [Medline] [CrossRef]
- Stevens, P. K. and Czuprynski, C. J. 1996. *Pasteurella haemolytica* leukotoxin induces bovine leukocytes to undergo morphologic changes consistent with apoptosis in vitro. *Infect. Immun.* **64**: 2687–2694. [Medline]
- Tsukamoto, H., Mochiduki, Y., Nakahara, Y., Kawamura, T., Sasaki, S., Nishio, C., Morimoto, A. and Mayumi, T. 2006. [A case of pulmonary aspergillosis accompanied with eosinophilic pneumonia]. *Nihon Kokyuki Gakkai Zasshi* **44**: 436–441 [in Japanese with English summary]. [Medline]