

Original Article

The infratentorial supracerebellar approach in surgery of lesions of the pineal region

Joana Oliveira, António Cerejo, Pedro Santos Silva, Patrícia Polónia, Josué Pereira, Rui Vaz

Department of Neurosurgery, Hospital S. João, Porto, Portugal

E-mail: *Joana Oliveira - jago79@gmail.com; António Cerejo - a.cerejo@sapo.pt; Pedro Santos Silva - pedrodossantossilva@gmail.com; Patrícia Polónia - titapolonia@yahoo.com.br; Josué Pereira - josuепereira@sapo.pt; Rui Vaz - ruimcvaz@gmail.com

*Corresponding author

Received: 08 september 13 Accepted: 16 November 13 Published: 30 November 13

This article may be cited as:Oliveira J, Cerejo A, Silva PS, Polónia P, Pereira J, Vaz R. The infratentorial supracerebellar approach in surgery of lesions of the pineal region. *Surg Neurol Int* 2013;4:154. Available FREE in open access from: <http://www.surgicalneurologyint.com/text.asp?2013/4/1/154/122504>

Copyright: © 2013 Oliveira J. This is an open-access article distributed under the terms of the Creative Commons Attribution License, which permits unrestricted use, distribution, and reproduction in any medium, provided the original author and source are credited.

Abstract

Background: Surgery of pineal region lesions is considered a challenging task, due to the particular relationship of lesions in this location with neural and vascular structures. Few series with a significant experience of dealing with these patients have been reported.

Methods: We review our experience using infratentorial supracerebellar approach in the surgery of pineal region, regarding the extension of the removal, postoperative morbidity, and discussing details of the surgical technique. In all cases, a supracerebellar infratentorial approach was used in the semi sitting position.

Results: A total of 32 patients were operated in the past 20 years (3 germinomas, 3 teratoma, 3 pineocytoma, 2 pineal tumor of intermediate differentiation, 6 pineoblastomas, 6 low grade astrocytoma, 2 glioblastoma, 2 metastasis, 1 ependymoma, 1 epidermoid tumor, 1 cavernoma, and 2 arachnoid cyst). Total removal was achieved in 15 cases and subtotal extensive removal in 7 patients. In the remaining cases, only partial removal was possible, due to the involved pathological types. There was no surgical mortality and no cases of cerebellar venous infarction. Morbidity consisted of transient ocular movement disturbance in 14 patients, transient ataxia in 3 patients, and 1 case of local cerebrospinal fluid (CSF) fistula with meningitis that required surgical treatment.

Conclusion: Supracerebellar infratentorial is a safe approach to lesions in the pineal region, and total or extensive subtotal removal is possible in most cases, with acceptable morbidity.

Key Words: Infratentorial, pineal, surgery, supracerebellar

Access this article online**Website:**www.surgicalneurologyint.com**DOI:**

10.4103/2152-7806.122504

Quick Response Code:

INTRODUCTION

Neurosurgical resection of lesions in the pineal region is challenging, due to the close relationship with important neural and vascular structures, especially the vein of Galen draining system.^[3,4,8,15-17,22,23,26,32] Infratentorial

supracerebellar (ITSC) approach is commonly used to deal with these lesions. This approach gives a direct access to the lesions, and, especially if used in the semi-sitting position, provides an easier dissection of the adhesions of the lesions to the deep venous system.^[10,15,16,18,20,23,26] However, the ITSC approach is generally considered to

have limitations when the tumors have lateral or caudal extension.^[16,17,23]

One of the problems in surgery of pineal lesions concerns the relatively small number of cases admitted for treatment; therefore, only a few series with a significant experience of dealing with these patients have been reported,^[5,10,17] and a perspective about the potential surgical hazards is difficult to obtain. In this work, we revise the experience in our department in a series of 32 patients, operated over a 20-year period using the ITSC approach, analyzing the surgical results and discussing several aspects of the surgical procedure.

MATERIALS AND METHODS

A total of 32 patients with pineal region lesions were operated in our Department, by the same surgeon (AC), from 1993 to 2012, using the ITSC approach. There were 11 female and 21 male patients, and the mean age was 27.2 years (4-65 years). The clinical symptoms at the time of diagnosis are presented in Table 1. The mean follow-up time was of 91 months.

Hydrocephalus was present before surgery in 10 patients. Of these, five patients required ventriculoperitoneal shunting and four were treated by third ventriculostomy. In another patient, a transient external ventricular drainage was applied.

In the majority of cases, the objective of surgery was to remove as much as possible of the lesions, as well as the obtainance of pathological diagnosis. In arachnoid cysts, the objective was the extensive opening of the cyst walls. Germinomas were operated due to lack of elevated levels of alpha-fetoprotein (AFP) and beta-human chorionic gonadotropin (β -HCG) in preoperative examination of blood or cerebrospinal fluid (CSF). In two cases of germinoma, surgery proceeded to total or near total removal of the tumor after inconclusive pathological specimens at the beginning of tumor removal. In the case of metastasis, the diagnosis was established after surgery, since there was no suspected tumor before operation.

Surgical procedure

All the patients were operated in the semi-sitting position, with slight flexion of the neck. From the beginning of

the procedure until dural opening, the surgical table was tilted in order to keep patient's feet 10 cm over the head. After dural opening, the table was tilted to keep the feet at the level of the upper point of head, until the end of the surgery. Bilateral jugular compression was frequently applied during opening, until reaching the pineal region.

A linear incision about 7-8 cm long was made in the midline, from theinion to the level of C2. A suboccipital craniotomy was then performed, exposing the inferior border of transverse sinus and going laterally until the transverse/sigmoid junction, on both sides. Inferiorly, the craniotomy did not include the opening of the foramen magnum, but allowed exposure of cistern magna. After craniotomy, the dura mater was opened in a V-shaped incision, beginning about 5 mm below the transverse/sigmoid junction on both sides and exposing the cistern magna. The edge of the dura mater was turned superiorly by tenting sutures [Figure 1].

The cistern magna was opened in all cases, allowing the exit of CSF and the relaxation of the cerebellum, and obtaining enough space to approach the superior cerebellar surface. Without any retraction, all the bridging veins between the tentorium and the cerebellar surface were divided, both in the midline and in the cerebellar hemispheres, and the working space between the tentorium and the superior cerebellar surface was progressively enlarged due to the effect of gravity. At that point, the tentorial notch and the arachnoid membrane, generally very thick, of the quadrigeminal cistern come into view [Figure 2]. A retractor was then applied to the cerebellar surface, close to the quadrigeminal cistern. The retractor was kept in place until the end of tumor removal, but slightly moved to one side or the other if needed for tumor dissection in its lateral portion, around the Rosenthal veins.

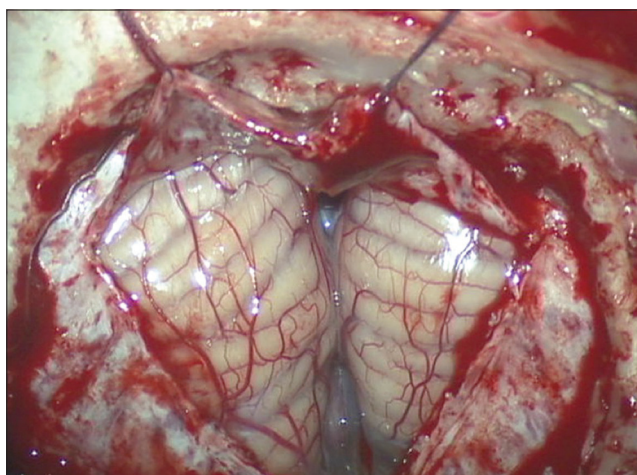


Figure 1: Craniotomy going laterally until the transverse/sigmoid junction, on both sides. Inferiorly, the craniotomy went inferiorly enough to allow exposure of cistern magna. The dura mater was opened in a V-shaped incision exposing the cistern magna

Table 1: Clinical findings at diagnosis in 32 patients

Symptoms	Number of patients
Headache	25
Nausea/vomiting	10
Hydrocephalus with CSF diversion	10
Visual disturbances	3
Precocious puberty	1
Gait disturbance/Ataxia	3

CSF: Cerebrospinal fluid

During the approach, bilateral jugular compression was performed regularly.

The arachnoid of the quadrigeminal cistern was then opened. The identification of precentral cerebellar vein, the vein of Galen, and the basal veins of Rosenthal was the main objective at this point, prior to any tumor removal. In cases of arachnoid cyst, opening of the cyst wall was performed, followed by removal of cyst wall on both sides of the precentral vein, going upwards to the vicinity of the vein of Galen, and, laterally, to the basal veins of Rosenthal. In tumor cases, surgery proceeded with tumor removal, using ultrasonic aspiration for extensive tumor debulking, initially on both sides of precentral vein. When necessary, the precentral vein was readily divided, as far as possible from the vein of Galen. After debulking, dissection of the tumor from the surrounding structures was performed. Dissection was started in the superior portion of the tumor, completely separating the lesion from the vein of Galen and the internal cerebral veins. This was facilitated by the effect of gravity, after extensive debulking. The anterior portion of the lesions, extended into the third ventricle was then removed, and the ventricular structures came into view. Dissection proceeded to the lateral aspects of the tumor. Special care was taken in preservation of the medial posterior choroidal arteries and the basal veins of Rosenthal. In cases of lateral extension of the lesion, dissection was performed medially to the basal vein and also laterally, in the space between the basal vein and the tentorium [Figure 3]. The inferior part of the tumor was then dissected. Great care was needed in identification of the quadrigeminal plate and in separation of the tumor from this structure. In cases with a significant downwards extension, gentle pressure on the retractor in the inferior direction was applied [Figures 4 and 5]. Generally, the dissection comes from lateral to medial, dividing small feeders from the posterior choroidal and superior cerebellar arteries, and the tumor was then completely removed, whenever possible.

After tumor removal, bilateral jugular compression was applied, detecting and stopping any venous bleeding. The dura mater was closed in a water tight way, and, in cases operated in the past 10 years, a dural substitute and fibrin glue were applied over the closed dura mater.

Postoperative evaluation

Patients were transferred anesthetized to the Neurocritical Care Unit, and this transfer is done keeping the patient's head elevated 30°. Anesthetic drugs were removed during the following 6-8 hours. A computed tomography (CT) scan was performed 6-8 hours after dural closure, to detect postoperative bleeding or any other complications, as hydrocephalus. Patients were encouraged to sit 24 hours after surgery, and to walk after 48 hours. In general, patients were discharged 5-7 days

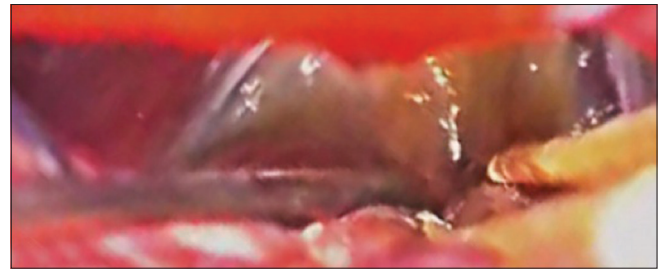


Figure 2: Thick arachnoid membrane of the quadrigeminal cistern comes into view without retraction

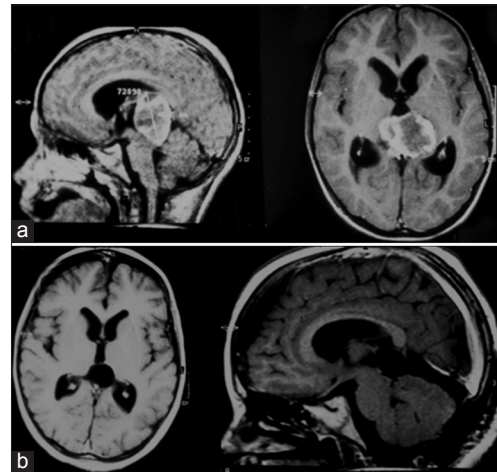


Figure 3: Teratoma with left lateral extension; (a) preoperative; (b) after complete removal

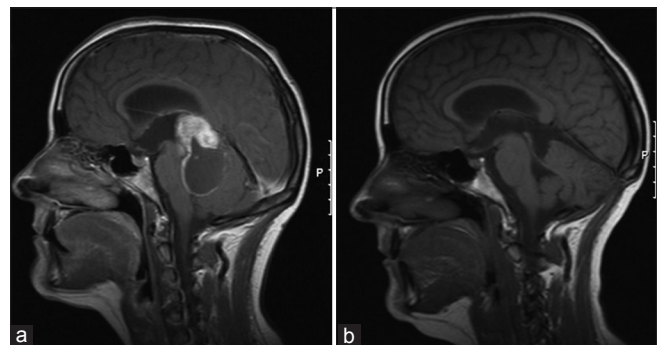


Figure 4: Partially cystic teratoma with downwards projection; (a) preoperative; (b) after complete removal

after the surgical procedure. After hospital discharge, patients were evaluated after 1 week, 1 month, and every 6 months.

The mean follow up time was of 91 months, and five patients were lost to follow-up.

After surgery, all patients with glioblastoma were submitted to Radiotherapy after surgery, and the same happened to one of the patients with low grade astrocytoma. Patients with pineocytomas and pineal parenchymal tumor of intermediate differentiation, all

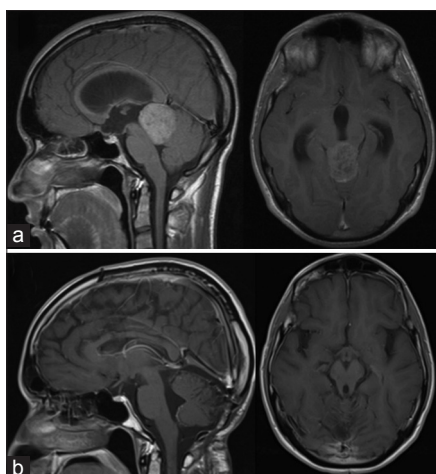


Figure 5: Germinoma extending downwards to the level of the 4th ventricle; (a) preoperative; (b) after complete removal

of them with complete surgical removal, did not receive any adjuvant treatment. Patients with pineoblastomas were submitted to Radiotherapy after surgery and one of the patients with pineoblastoma also received adjuvant chemotherapy. In all germinoma cases, postoperative radiotherapy was performed. Teratoma cases (all of them completely removed) did not receive any adjuvant treatment. The same happened in the only ependymoma patient. Metastasis patients were also submitted to appropriate radio and chemotherapy, postoperatively.

The extension of surgical removal and the postoperative complications were the studied parameters. The extension of removal was evaluated with postoperative magnetic resonance imaging (MRI). The results were classified in one of three groups: Complete removal (no tumor visible in postoperative MRI), subtotal extensive removal (removal of 90% or more of the tumor mass), and partial removal (extension of removal of less than 90% of the tumor mass).

RESULTS

Extension of removal

In the 30 cases of tumoral or vascular pathology, complete removal was achieved in 15 patients (50%) [Figures 6 and 7]. In seven cases (23%), a subtotal extensive removal was performed [Figure 8]. In the remaining eight cases (27%), only a partial removal was possible. The extension of removal according to pathology is displayed in Table 2.

Postoperative complications

Postoperative complications are displayed in Table 3. There was no surgical mortality.

The most common surgical complication was the new onset (in 11 cases) or the worsening of preoperative ocular movement disturbances (in 3 patients). In all patients, ocular disorders improved progressively and disappeared in

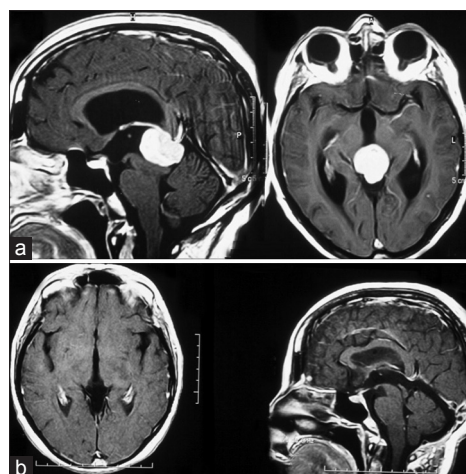


Figure 6: Pineal parenchymal tumor of intermediate differentiation; (a) preoperative; (b) after complete removal

Table 2: Extension of removal according to pathology (tumours/vascular pathology-30 cases)

Pathology	Extension of removal			Total
	Complete	Subtotal extensive	Partial	
Astrocytoma (OMS II)	1	4	1	6
Pineoblastoma	2	2	2	6
Pineocytoma	3	-	-	3
Teratoma	3	-	-	3
Germinomas	1	1	1	3
PPTID*	2	-	-	2
Glioblastoma	-	-	2	2
Metastasis	1	-	1	2
Ependymoma	1	-	-	1
Epidermoid	-	-	1	1
Cavernoma	1	-	-	1
Total	15	7	8	30

*Pineal parenchymal tumor of intermediate differentiation

Table 3: Post-operative complications

Post-operative complications	Number of cases
New ocular movement disturbances	11
Worsening of preoperative ocular movement disturbances	3
Ataxia (postoperative new onset or worsening)	3
CSF fistulae* and Meningitis	1

*Surgical treatment required, CSF: Cerebrospinal fluid

one year after operation. Ataxia was noticed in three patients after surgery, although in two of the cases, ataxia was already present preoperatively. Ataxia also improved progressively, disappearing in all cases 6 months after surgery.

There was one case of local CSF fistula and meningitis in a germinoma patient, treated with appropriate antibodyotherapy and revision of the surgical wound.

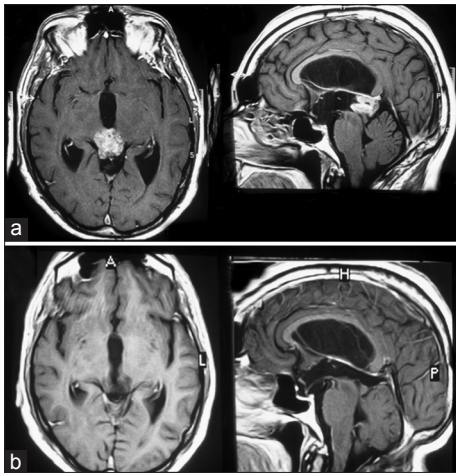


Figure 7: Ependymoma; (a) preoperative; (b) after complete removal

DISCUSSION

A neurosurgical procedure is indicated in the majority of the patients with lesions in the pineal region.^[3,4,15,16,20,22] Most cases present with obstructive hydrocephalus, and an operation for CSF diversion is frequently necessary.^[6,16,19] In recent years, endoscopic third ventriculostomy has been developed. In the same procedure, endoscopy may permit the removal of tumoral tissue specimens to histopathological diagnosis, necessary to establish the appropriate plan of treatment, at least in lesions without blood and/or CSF elevated levels of AFP and/or β -HCG.^[6,19]

Besides obtaining a histopathological diagnosis, neurosurgical resection is needed in many cases,^[3,4,8,15,16,20,22] with the goal to completely remove the benign lesions. In malignant tumors, mass reduction is the objective of the surgical procedure, although in the presented cases, complete removal was possible in two cases of pineoblastoma [Figures 9 and 10].

Several approaches have been described to access lesions in the pineal region:^[24] The posterior transcalsal, described by Dandy,^[7] is usually restricted to tumors extending anteriorly into the 3rd ventricle or invading the corpus callosum. The transcortical transventricular approach^[30] may be used in tumors extending into the posterior part of the lateral ventricle, on the nondominant side. The ITSC^[25] and the occipital transtentorial^[21] are the most common approaches used to access the pineal region. These two approaches have disadvantages, including the risk of air embolism in the semi-sitting position, and the retraction of occipital lobe in the case of occipital transtentorial approach. Ausman^[1,2] developed the three-quarter prone approach to the pineal-tentorial region, avoiding the risk of air embolism, minimizing the retraction of the occipital lobe, and providing a more comfortable operating position to the surgeon. Endoscopic supracerebellar infratentorial approaches to

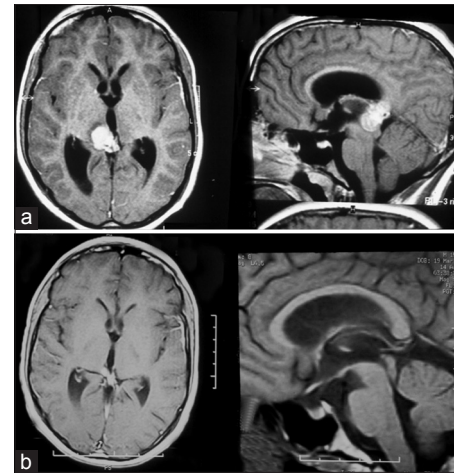


Figure 8: Germinoma; (a) preoperative; (b) after subtotal extensive removal

this region have also been recently developed.^[6,11,27,29,31]

The choice of approach is dependent mainly on the situation of the lesions and its relationship with the deep venous system, since it is difficult to resect lesions with interposition these venous structures in the working operative field.^[8,15,16,20,22] In general, the occipital transtentorial approach is preferable when the lesions are situated superiorly to the Galenic venous draining system.

In this work, we report our experience with ITSC approach, in semi-sitting position. The results concerning the extent of removal and surgical complications are in the range usually reported for this procedure.^[9,10,16,23]

Although this position is associated with risk for venous air embolism^[12,18] the conjugation of ITSC approach with the semi-sitting position may provide an adequate surgical operative field, especially when some nuances of the surgical technique are used to provide maximal relaxation of the cerebellum, with limited use of cerebellar retraction and taking advantage of the effect of gravity. Therefore, it is possible to remove lesions with considerable dimensions, even when there are significant lateral and inferior extensions of the tumors.

In the included patients, there were no cases of air embolism with hemodynamic or clinical repercussion. In an attempt to minimize the risk of air embolism, extreme care is taken in the correct positioning the patient. Venous pressure is elevated by positioning the patient's feet slightly above the medium point of the head in the opening period of the surgery. Bilateral jugular compression is frequently applied during opening. In this way, any venous bleeding is identified and stopped, therefore avoiding as much as possible the entrance of air in the venous system.

In the reported cases, a midline linear incision was used, from theinion the level of C2, allowing for a craniotomy suitable for complete exposure of the superior surface of both cerebellar hemispheres and the cisterna magna,

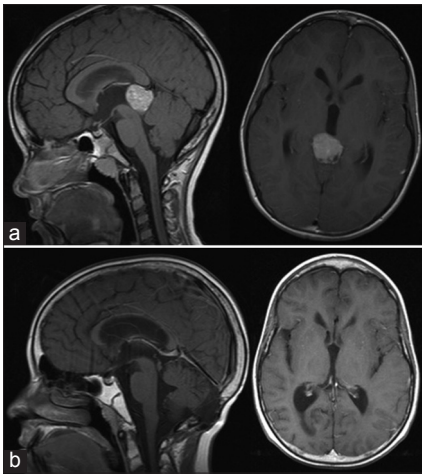


Figure 9: Pineoblastoma (a) preoperative (b) after complete removal

after dural opening. The cistern magna was then opened in all cases, allowing for the exit of a large amount of CSF, making possible the access to the superior surface of both cerebellar hemispheres without retraction. Although significant improvements with the use of smaller craniotomies and endoscopic approaches have been described,^[6,11,26,27,29,31] a large craniotomy makes possible to take full advantage of the effect of gravity.

Another important aspect concerns the bridging veins between the superior cerebellar surface and the tentorium. The large craniotomy and the relaxation of the cerebellum provided by the opening of the cistern magna make possible the identification of all bridging veins. In order to obtain the maximum operating room, all the bridging veins were coagulated and divided, taking advantage of the positioning and the effect of gravity, therefore allowing for even more evident cerebellar relaxation. Besides, an incidental rupture of the bridging veins increases the risk of air embolism. Although the onset of cerebellar venous infarction has been reported in the literature,^[10,13,14,16,28] cases of cerebellar venous infarction were not detected in the present series.

With this procedure, the tentorial notch may be reached without retraction on the cerebellar surface. At this point, a retractor is applied, only with light pressure. During surgery, this retractor may be slightly moved to both sides and downwards, when the dissection is carried away in the lateral extension and in the lower portion of the lesion. The arachnoid membrane of the quadrigeminal cistern is then opened, with great care in the identification of the venous complex. Generally, the first identifiable vein is the precentral cerebellar, situated on the midline, although a displacement to one side or another is not unusual. The vein of Galen is visible above the precentral vein, and the basal veins of Rosenthal are seen close to the tentorial notch, on both

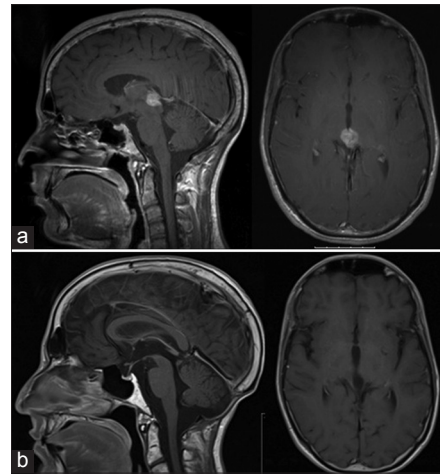


Figure 10: Pineoblastoma; (a) preoperative; (b) after complete removal

sides. Whenever needed, the precentral vein was divided, without any problems.

After identification of the tumor and removal of small fragments to determine the pathological diagnosis, removal is started, with debulking as extensive as possible of the lesion, using ultrasonic aspiration and/or piecemeal removal.

In our experience, dissection of the lesion preferably starts in the superior portion, beginning with detachment from the deep venous system. This is facilitated by the position of the patient and effect of gravity. Great care is needed at this point to avoid lesions of the veins, since the basal veins of Rosenthal and the vein of Galen must always be preserved.^[10,15,16,22,23] In case of a small laceration, local hemostatics are applied, and the stop of bleeding is always confirmed with repeated jugular compression.

The dissection of the superior portion of the tumor is crucial in the remaining surgery by providing the identification of structures in the 3rd ventricle and its walls. Besides, the dimensions of the lesions are clear to the surgeon from this point of the procedure.

Dissection usually proceeds to the lateral portion of the lesions. The presence of a significant lateral extension is considered a major disadvantage of ITSC approach to the pineal region, due to the fact that surgical view is obstructed by the tentorial edge and to the difficulty in moving the surgical instruments laterally using this approach.^[15-17,20,22,23,32] However, a careful separation of the basal vein of Rosenthal from its attachments may provide enough working space between the basal vein and the tentorial edge. The retractor is slightly moved to the side for tumor dissection laterally to the Rosenthal vein. The tumor is then slowly pulled by piecemeal removal and careful dissection from its surroundings.

The last step of the surgical procedure is the removal of the inferior portion of the tumor. Another referred problem using the ITSC approach is the difficult access to the caudal limits of the lesions, due to the angle of approach^[16,17] This portion is the most difficult part of the surgery, and great care is needed in identification of the quadrigeminal plate, since the interface between the tumor and this structure may be hard to distinguish. In lesions with a downwards extension, gentle pressure on the retractor in the inferior direction may be applied. This maneuver, together with the maximal cerebellar relaxation at this point of the surgery, may provide access to significant inferior extensions of the tumors. Since the lateral portions of the tumor have already been removed, the dissection comes from lateral to medial, dividing small feeders from the posterior choroidal and superior cerebellar arteries. The tumor is then completely removed, whenever possible.

CONCLUSION

In our experience, there are nuances of the surgical procedure that may bring an easier access to lesions in the pineal region when using the ITSC approach. As an overview, the following aspects should be considered:

1. Careful positioning of the patient in the semi-sitting position.
2. Obtainance of the maximal cerebellar relaxation (taking advantage of the effect of gravity) by:
 - Large craniotomy, extending laterally to the transverse/sigmoid junction on both sides.
 - Opening the cistern magna.
 - Division of all the bridging veins between the tentorium and the superior surface of the cerebellum.
3. Complete removal of the tumor is possible in cases of significant lateral extension, through a surgical working space between the basal vein of Rosenthal and the tentorial edge.
4. Complete removal of the tumor is also possible in cases of inferior projection, taking advantage of the maximal cerebellar relaxation together with gentle downwards retraction.

REFERENCES

1. Ausman JI, Malik GM, Dujovny M, Mann R. Three-quarter prone approach to the pineal-tentorial region. *Surg Neurol* 1988;29:298-306.
2. Ausman JI, Malik GM, Pearce J, Rogers JS. A new operative approach to the pineal region. In: Samii M, editor. *Surgery in and Around the Brain Stem and the Third Ventricle*. Berlin: Springer-Verlag; 1986. p. 326-8.
3. Blakeley JO, Grossman SA. Management of pineal region tumors. *Curr Treat Options Oncol* 2006;7:505-16.
4. Bruce JN, Ogden AT. Surgical strategies for treating patients with pineal region tumors. *J Neurooncol* 2004;69:221-36.
5. Bruce JN, Stein BM. Surgical management of pineal region tumors. *Acta Neurochir* 1995;134:130-5.
6. Chibbaro S, Di Rocco F, Makiese O, Reiss A, Poczos P, Mirone G, et al. Neuroendoscopic management of posterior third ventricle and pineal region

- tumors: Technique, limitation, and possible complication avoidance. *Neurosurg Rev* 2012;35:331-8.
7. Dandy WE. An operation for the removal of pineal tumors. *Surg Gynecol Obstet* 1921;33:113-9.
8. Hart MG, Santarius T, Kirollos RW. How I do it-pineal surgery: Supracerebellar infratentorial versus occipital transtentorial. *Acta Neurochir* 2013;155:463-7.
9. Hart MG, Sarkies NJ, Santarius T, Kirollos RW. Ophthalmological outcome after resection of tumors based on the pineal gland. *J Neurosurg* 2013;119:420-6.
10. Hernesniemi J, Romani R, Albayrak BS, Lehto H, Dashti R, Ramsey C 3rd, et al. Microsurgical management of pineal region lesions: Personal experience with 119 patients. *Surg Neurol* 2008;70:576-83.
11. Herrada-Pineda T, Revilla-Pacheco F, Manrique-Guzman S. Endoscopic approach for the treatment of pineal region tumors. *J Neurol Surg A Cent Eur Neurosurg* 2013. [Epub ahead of print]
12. Jadik S, Wissing H, Friedrich K, Beck J, Seifert V, Raabe A. A standardized protocol for the prevention of clinically relevant venous air embolism during neurosurgical interventions in the semisitting position. *Neurosurgery* 2009;64:533-8.
13. Jakola AS, Bartek J Jr., Mathiesen T. Venous complications in supracerebellar infratentorial approach. *Acta Neurochir* 2013;155:477-8.
14. Kanno T. Surgical pitfalls in pinealoma surgery. *Minim Invasive Neurosurg* 1995;38:153-7.
15. Kennedy BC, Bruce JN. Surgical approaches to the pineal region. *Neurosurg Clin North Am* 2011;22:367-80, viii.
16. Koderka T, Bozinov O, Surucu O, Ulrich NH, Burkhardt JK, Bertalanffy H. Neurosurgical venous considerations for tumors of the pineal region resected using the infratentorial supracerebellar approach. *J Clin Neurosci* 2011;18:1481-5.
17. Konovalov AN, Pitskhelauri DI. Principles of treatment of the pineal region tumors. *Surg Neurol* 2003;59:250-68.
18. Lindroos AC, Niiya T, Randell T, Romani R, Hernesniemi J, Niemi T. Sitting position for removal of pineal region lesions: The Helsinki experience. *World Neurosurg* 2010;74:505-13.
19. Morgenstern PF, Souweidane MM. Pineal region tumors: Simultaneous endoscopic third ventriculostomy and tumor biopsy. *World Neurosurg* 2013;79 (2 Suppl):S18.e9-13.
20. Pollack IF. Surgical options for pineal region tumors. *World Neurosurg* 2012;77:302-3.
21. Poppen JL. The right occipital approach to a pinealoma. *J Neurosurg* 1966;25:706-10.
22. Radovanovic I, Dizdarevic K, de Tribolet N, Masic T, Muminagic S. Pineal region tumors-neurosurgical review. *Med Arh* 2009;63:171-3.
23. Sajko T, Kudelic N, Lupret V, Lupret V Jr., Nola IA. Treatment of pineal region lesions: Our experience in 39 patients. *Coll Antropol* 2009;33:1259-63.
24. Slavin KV, Ausman JI. Tumors of the Pineal Region. In: Rengachary SS, Wilkins RH, editors. *Principles of Neurosurgery*. London: Wolfe Publishing; 1994. p. 29.21-29.15.
25. Stein BM. The infratentorial supracerebellar approach to pineal lesions. *J Neurosurg* 1971;35:197-202.
26. Sughrue ME. Minimally invasive approaches to the pineal region. *Neurosurg Clin North Am* 2011;22:381-4, viii.
27. Tseng KY, Ma HI, Liu WH, Tang CT. Endoscopic supracerebellar infratentorial retropineal approach for tumor resection. *World Neurosurg* 2012;77:399. E1-4.
28. Ueyama T, Al-Mefty O, Tamaki N. Bridging veins on the tentorial surface of the cerebellum: A microsurgical anatomic study and operative considerations. *Neurosurgery* 1998;43:1137-45.
29. Uschold T, Abila AA, Fusco D, Bristol RE, Nakaji P. Supracerebellar infratentorial endoscopically controlled resection of pineal lesions: Case series and operative technique. *J Neurosurg Pediatr* 2011;8:554-64.
30. Van Wagenen WP. A surgical approach for the removal of certain pineal tumors: Report of a case. *Surg Gynecol Obstet* 1931;53:216-20.
31. Wong TT, Chen HH, Liang ML, Yen YS, Chang FC. Neuroendoscopy in the management of pineal tumors. *Childs Nerv Syst* 2011;27:949-59.
32. Yamamoto I. Pineal region tumor: Surgical anatomy and approach. *J Neurooncol* 2001;54:263-75.