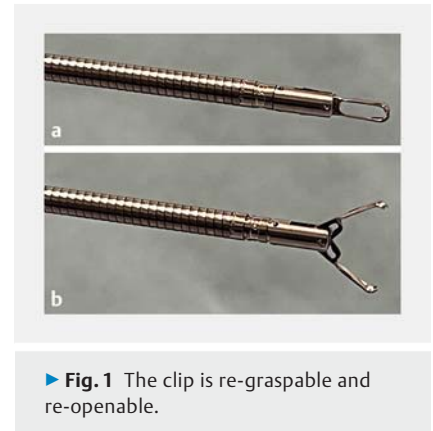
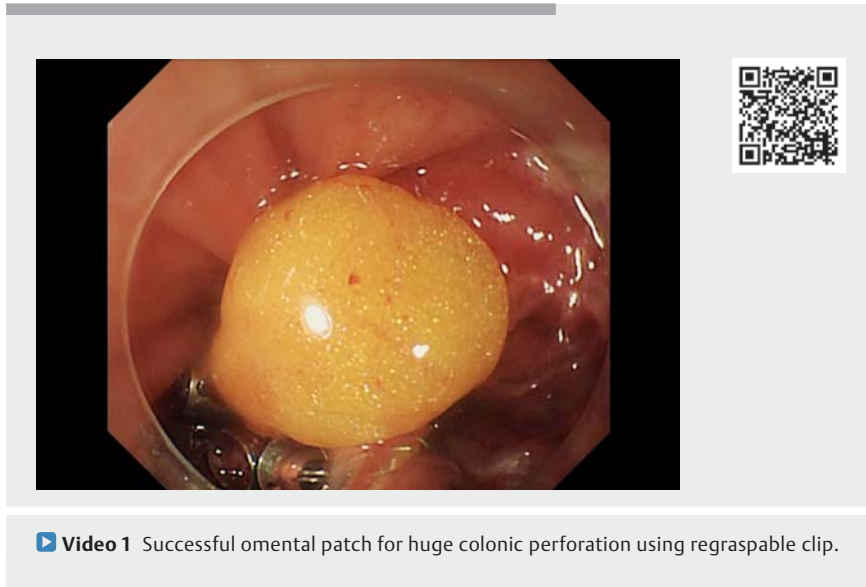


Successful omental patch for huge colonic perforation using re-graspable clip

OPEN
ACCESS



A 79-year-old woman with a 20-mm early-stage colorectal cancer of the ascending colon underwent endoscopic submucosal dissection (ESD). A novel complete closure using a re-graspable clip (Sureclip; Micro-Tech Co., Ltd, Nanjing, China) (▶ **Fig. 1**) was applied for a large perforation that occurred during procedure.

Initially the intra-abdominal fatty tissue of the greater omentum was grasped and pulled by the clip into the colon lumen. Subsequently, the clip was opened, and the mucosa re-grasped at both ends of the perforation with the retracting omentum. After confirmation that the omentum and mucosa at both ends were grasped together, the clip was released.

The first clip was then used as an anchor, and it was held down with a transparent attachment to narrow the shape of the perforated site and shorten the diameter. Then, additional clips were placed one after another with fatty tissue drawn into the colon lumen in the same manner (▶ **Video 1**, ▶ **Fig. 2**). In this way, we succeeded in completing the closure (▶ **Fig. 3**).

Postoperatively, the patient was conservatively managed and discharged 6 days after ESD. We also confirmed complete closure by follow-up endoscopy performed 2 months later (▶ **Fig. 4**).

During the ESD, a large perforation of more than 10mm occurred, but using the Sureclip, the perforation was closed completely by drawing fatty tissue into the lumen of the colon, and the patient was managed conservatively without any major problems.

There have been several reports showing complete closure of colonic perforations. However, all of them required the use of specific devices such as the endoloop [1], endoscopic band ligation [2], and the OTSC clip [3]. In our case, it was simpler to use only Sureclips. This method may be useful in sites where the scope can easily approach fatty tissue of the greater omentum.

Endoscopy_UCTN_Code_CPL_1AJ_2AD

Competing interests

The authors declare that they have no conflict of interest.

The authors

Kohei Ono, Ken Ohata, Nao Takeuchi, Shunya Takayanagi, Yoshiaki Kimoto, Ryoju Negishi, Yohei Minato

Department of Gastrointestinal Endoscopy, NTT Medical Center Tokyo, Tokyo, Japan

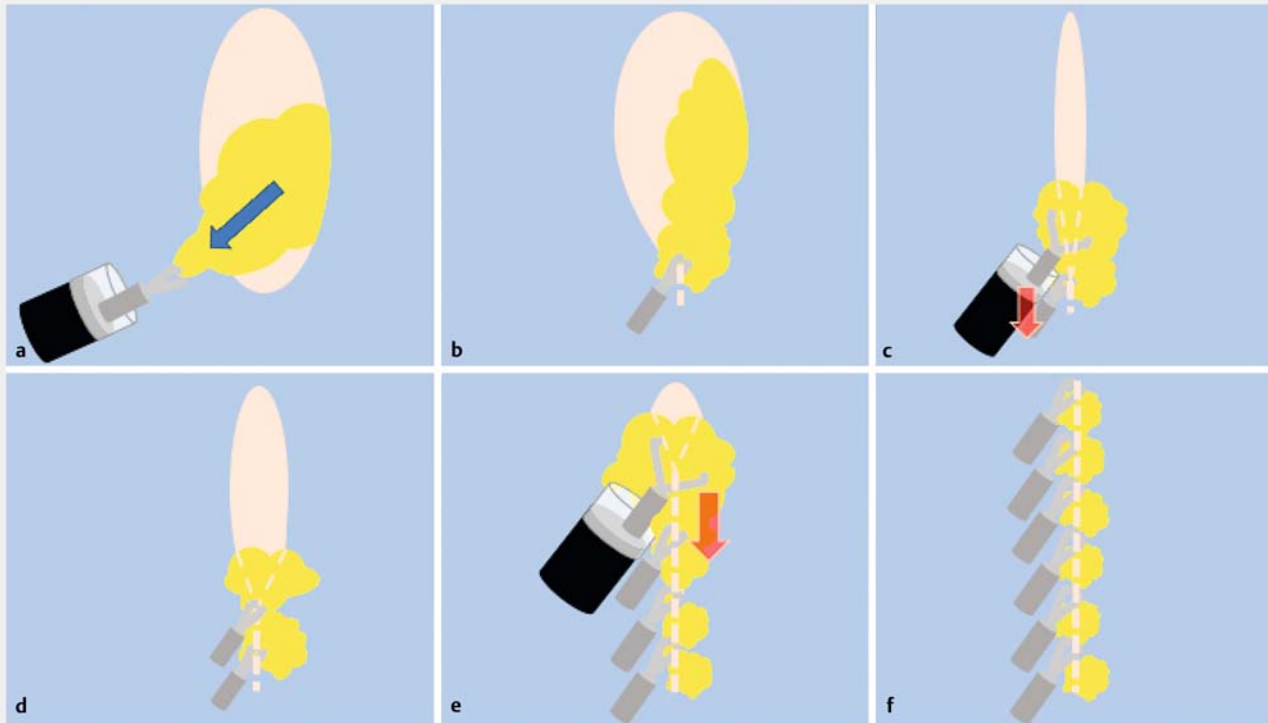
Corresponding author

Ken Ohata, MD

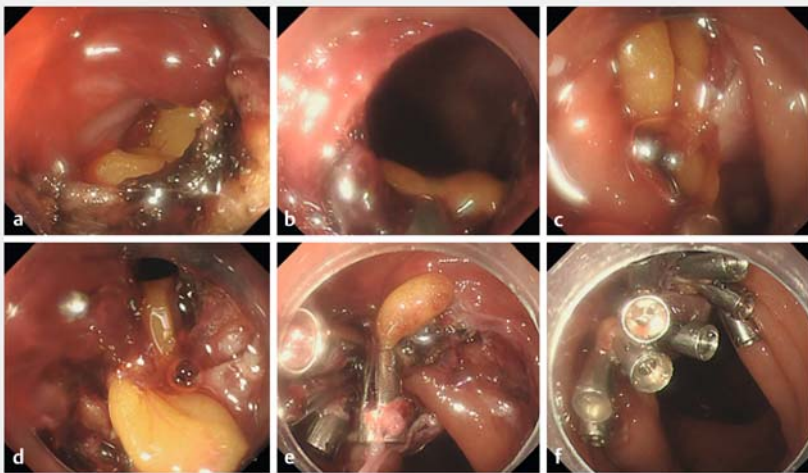Department of Gastrointestinal Endoscopy, NTT Medical Center Tokyo, 5-9-22 Higashi-gotanda Shinagawa-ku, Tokyo 141-8625, Japan

Fax: +81-3-3448-6541

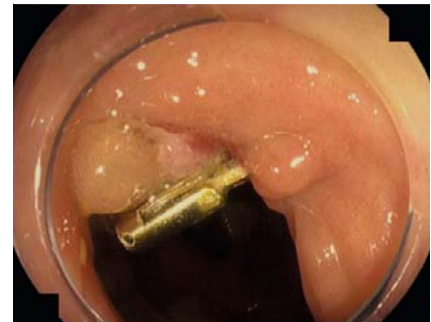ken.ohata1974@gmail.com



► **Fig. 2** Shema of this procedure. **a** Intra-abdominal fat tissue was pulled into the lumen. **b** Both ends of the mucosa were clipped with drawn fat tissue. **c** The first clip was pressed down with a transparent attachment to narrow the shape of the perforation site. **d** Then, after fat was drawn with sufficient suction, mucosa was clipped at both ends with fat. **e** Additional clips were applied in the same manner. **f** Successfully completed closure.



► **Fig. 3** Endoscopic views. **a** A large perforation occurred. **b** The omentum from within the abdomen was grasped. **c** Omentum was pulled into the colon lumen. **d** Mucosa was re-grasped at both ends together with omentum. **e** Additional clipping in the same manner. **f** Complete closure.



► **Fig. 4** Follow-up endoscopy (2 months later) showed complete closure and epithelialization.

References

- [1] Galtieri PA, Auriemma F, Maselli R et al. Omental patch for closure of a cecal perforation during endoscopic resection of a laterally spreading tumor. *Endoscopy* 2019; 51: E237–E238
- [2] Angsuwatcharakon P, Thienchanachaiya P, Pantongrag-Brown L. Endoscopic band ligation to create an omental patch for closure of a colonic perforation. *Endoscopy* 2012; 44: E90–E91
- [3] Parodi A, Repici A, Pedroni A et al. Endoscopic management of GI perforations with a new over-the-scope clip device. *Gastrointest Endosc* 2010; 72: 881–886

Bibliography

Endoscopy 2023; 55: E433–E435

DOI 10.1055/a-2008-0227

ISSN 0013-726X

© 2023. The Author(s).

This is an open access article published by Thieme under the terms of the Creative Commons Attribution-NonDerivative-NonCommercial License, permitting copying and reproduction so long as the original work is given appropriate credit. Contents may not be used for commercial purposes, or adapted, remixed, transformed or built upon. (<https://creativecommons.org/licenses/by-nc-nd/4.0/>)

Georg Thieme Verlag KG, Rüdigerstraße 14,
70469 Stuttgart, Germany



ENDOSCOPY E-VIDEOS

<https://eref.thieme.de/e-videos>



Endoscopy E-Videos is an open access online section, reporting on interesting cases and new techniques in gastroenterological endoscopy. All papers include a high quality video and all contributions are freely accessible online. Processing charges apply (currently EUR 375), discounts and waivers acc. to HINARI are available.

This section has its own submission website at

<https://mc.manuscriptcentral.com/e-videos>