

Received: 2019.08.18

Accepted: 2019.09.16

Published: 2019.10.01

# Clinical Investigation of the Association of Opening Size with Sagittal Canal Diameter Based on Single-Door Cervical Laminoplasty

Authors' Contribution:

Study Design A  
Data Collection B  
Statistical Analysis C  
Data Interpretation D  
Manuscript Preparation E  
Literature Search F  
Funds Collection G

BCDEF 1 **Chang-bo Lu\***  
BEF 1 **Xiao-jiang Yang\***  
BCD 2 **Jia-chang Wu\***  
BF 2 **Yun-zhi Lin**  
ACG 2 **Hong-xun Sang**

1 Department of Orthopedics, Xijing Hospital, The Air Force Medical University, Xi'an, Shaanxi, P.R. China

2 Department of Orthopedics, Shenzhen Hospital, Southern Medical University, Shenzhen, Guangdong, P.R. China

\* Chang-bo Lu, Xiao-jiang Yang and Jia-chang Wu contribute equally to this work

Hong-xun Sang, e-mail: [sanghongxun11@163.com](mailto:sanghongxun11@163.com)

**Corresponding Author:**

**Source of support:**

Sanming Project of Medicine in Shenzhen (No. SZSM201612019) to Hong-xun Sang

**Background:** Many clinical studies have assessed the association of laminoplasty opening size (LOS) with sagittal canal diameter (SCD) based on single-door cervical laminoplasty (SDCL). Nevertheless, the "worn-off" lamina extracted in SDCL was neglected in these reports. We aimed to develop a simple mathematical model to analyze the relationship between the effective LOS and SCD, taking into consideration the worn-off lamina.


**Material/Methods:** A total of 106 patients treated by SDCL at our hospital were included in this study. Pre-operative and post-operative SCDs were assessed using a picture archiving and communication system (PACS) based on computed tomography scans. Mini-plate sizes as well as drill bit diameters were recorded in detail in order to determine the effective LOS for each vertebral lamina involved.

**Results:** SCD in all patients was increased significantly after SDCL ( $P < 0.01$ ). A linear correlation was found between effective LOS and the post-operative SCD increment from C3 to C7 ( $R^2 > 0.933$ ,  $P < 0.001$ ). The 12 mm mini-plate was most often used in SDCL, accounting for 64.45% of all cases, whereas 10 mm and 16 mm mini-plates were the least used, accounting for 3.85% and 3.00%, respectively.

**Conclusions:** There is a strong linear correlation between effective LOS and the post-operative SCD increment. The SCD was increased by about 0.5 mm per mm increase in effective LOS. Thus, post-operative SCD could be precisely calculated and predicted, enabling the selection of optimal mini-plate prior to SDCL.

**MeSH Keywords:** Cervical Vertebrae • Spinal Canal • Spinal Cord Injuries • Spondylosis

**Full-text PDF:** <https://www.medscimonit.com/abstract/index/idArt/919485>

 1995

 2

 5

 25



## Background

Single-door cervical laminoplasty (SDCL) is broadly used for patients with ossification of the posterior longitudinal ligament (OPLL), multi-level spondylosis-associated spinal cord injury, or multiple herniated cervical discs accompanying spinal stenosis [1–3]. Many trials have suggested SDCL results in a better recovery in patients alongside long-term functional improvement [4–6]. In addition, SDCL is a markedly more convenient and easier surgical method compared with laminectomy [7,8].

The laminoplasty opening size (LOS) has an important function and effectively determines the enlargement of sagittal canal diameter (SCD) during SDCL. It might result in undesirable treatment results with either inadequate or excessive LOS [9,10]. Inadequate LOS is usually not sufficient to relieve nerve compression and associated symptoms. Meanwhile, excessive LOS may cause other adverse symptoms, such as postsurgical C5 nerve root palsy and increased generation of epidural scar tissues [11–13].

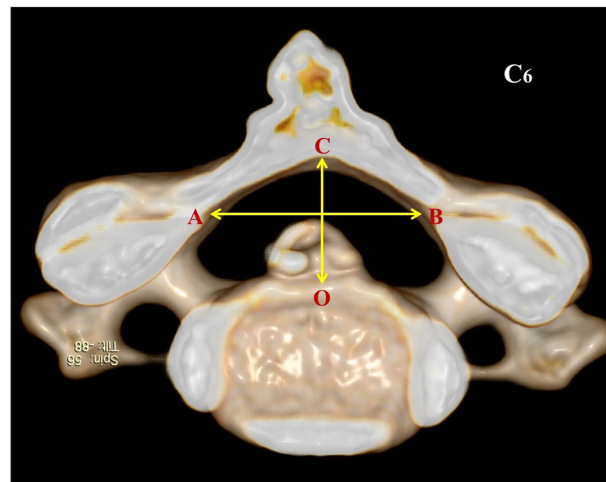
Multiple trials have assessed the association of LOS with SCD [1,14,15]. Nevertheless, the reported research findings were too complex to be widely adopted in clinical practice. Moreover, it is worth noting that the “worn-off” lamina extracted with the drill bit in SDCL was neglected in the above-mentioned research, which would lead to errors in the derived relationship between LOS and SCD [16].

The main objective of this study was to analyze the relationship between LOS and SCD, taking into consideration the worn-off lamina, developing a simple and precise mathematical model for SDCL. The developed model could increase the efficacy and reliability of SDCL in clinical settings.

## Material and Methods

### Patient data

In the present trial, we collected the data of 106 cases (65 males and 41 females; CSM and OPLL in 74 and 32 patients, respectively) administered SDCL at our hospital from March 2016 to March 2018. Their average age was 57.1 years (age ranging between 37 and 81 years). Symptom duration pre-operation averaged 9.3 months (range, 6–58 months). All cases have undergone conservative therapy for >3 months before surgery, but poor effect, if not none, was observed. Magnetic resonance imaging (MRI) indicated cervical disc herniation or spinal stenosis involving  $\geq 3$  intervertebral levels and spinal cord compression. All surgeries were carried out by a single surgeon for statistical consistence. Using a high-speed surgical drill, the left side was considered the lamina opening and the right side constituted a



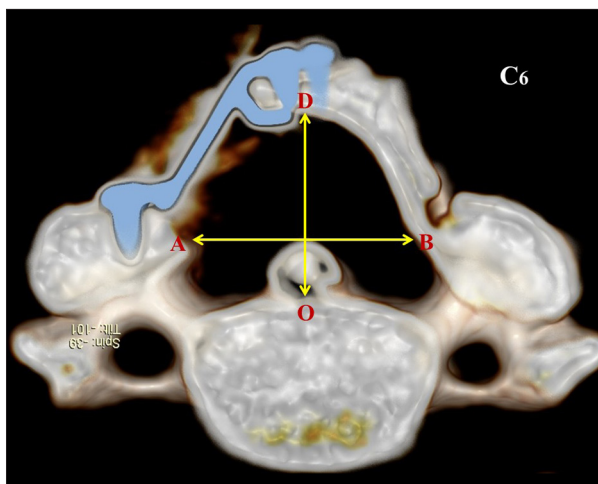
**Figure 1.** Three-dimensional reconstruction of a patient's cervical spine prior to single-door cervical laminoplasty (SDCL). (A and B) Represent the innermost points of both laminar gutters. O is the midpoint of the vertebral body's posterior surface. The vertical line A–B was drawn through point O, intersecting the lamina's inner edge at point C pre-operatively. The length of O–C represents the pre-operative sagittal canal diameter (SCD).

hinge for lamina opening. Centerpiece mini-plates were provided by Medtronic (Medtronic Inc., USA). This study was officially approved by the institutional Ethics Committee (No. 320160103).

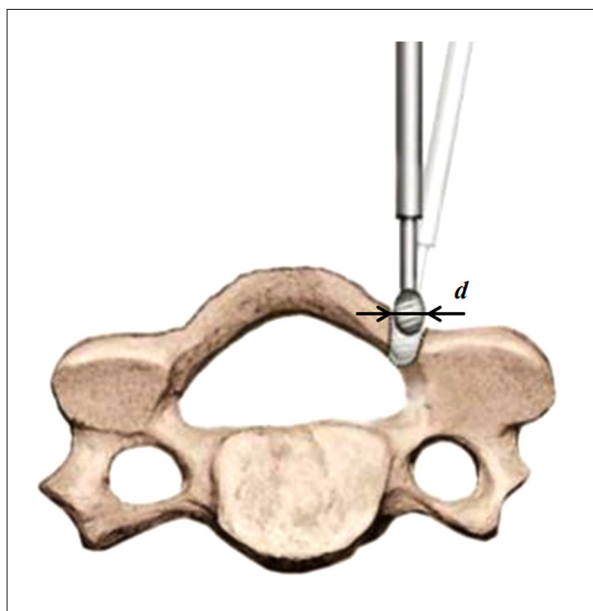
### Radiology

The GE Light Speed 64 slice VCT computed tomography (CT) instrument (GE Healthcare, USA) was used for scanning pre-operatively and 1-week post-surgery. The CT scans ranged from C1 to C7. The main CT parameters were: tube voltage, 120 kV; tube current, 220 mA; slice thickness, 0.625 mm; reconstruction interval, 0.625 mm; gantry rotation time, 0.5 s; pitch, 0.925; matrix, 512×512; FOV, 200×200 mm. Aiming to keep the same measurement position before and after surgery, axial CT sections were obtained at each pedicle level for assessment. The picture archiving and communication system (PACS) was used for these measurements.

Figures 1 and 2 show the 3-dimensional reconstruction of a patient's cervical spine before (Figure 1) and after (Figure 2) SDCL. A and B represent the innermost points of both laminar gutters. O is the midpoint of the vertebral body's posterior surface. The vertical line A–B was drawn through point O, intersecting the lamina's inner edge at points C and D pre- and post-operatively. The length of O–C represents the pre-operative SCD, while O–D stands for post-operative SCD. Parameter measurements were performed by 2 members of our research group, in 3 independent measurements (accuracy, 0.01 mm) and averaged for statistical evaluation.



**Figure 2.** Three-dimensional reconstruction of a patient's cervical spine after single-door cervical laminoplasty (SDCL). (A and B) Represent the innermost points of both laminae gutters. O is the midpoint of the vertebral body's posterior surface. The vertical line A-B was drawn through point O, intersecting the lamina's inner edge at point D post-operatively. The length of O-D represents the post-operative sagittal canal diameter (SCD).



**Figure 3.** Preparation of the lamina opening with a high-speed hand drill in single-door cervical laminoplasty. During the clinical operation, lamina tissues were partly extracted using the drill bit. The sizes of "worn-off" lamina tissues depend on the drill bit's diameter (*d*).

**Table 1.** Pre- and postoperative sagittal canal diameters (SCDs).

	Mean Preoperative (SCD)	Mean Postoperative (SCD)	<i>P</i>	Mean Increase (SCD)	Effective LOS	N
C3	8.87 mm (0.45)	14.17 mm (0.67)	<0.01	5.36 mm (0.72)	10.46 mm (0.96)	84
C4	8.85 mm (0.57)	14.64 mm (0.81)	<0.01	5.79 mm (0.64)	10.67 mm (1.11)	101
C5	8.63 mm (0.72)	14.11 mm (0.78)	<0.01	5.48 mm (0.53)	10.48 mm (1.11)	106
C6	8.64 mm (0.62)	14.14 mm (0.64)	<0.01	5.50 mm (0.57)	10.69 mm (1.19)	101
C7	8.72 mm (0.67)	14.35 mm (0.75)	<0.01	5.63 mm (0.31)	10.68 mm (1.25)	75
C3-C7	8.75 mm (0.54)	14.43 mm (0.91)	<0.01	5.68 mm (0.62)	10.60 mm (1.13)	467

Some vertebral laminae could be worn off during lamina opening (Figure 3). The sizes of worn-off laminae are closely related to the drill bit's diameter, as indicated by *d*; the mini-plate size is indicated by *c*. The effective LOS was derived as *c-d*.

**Statistical analysis**

The Statistical Product and Service Solutions (SPSS) software v24.0 (SPSS, USA) was applied for statistical analysis in this study. Data are mean±standard deviation (SD). Pre-operative and post-operative SCDs measured by the PACS were assessed by paired *t*-test to verify the effectiveness of the surgery. *P*<0.05 indicated statistical significance. Linear and curvilinear regression models (first and second order polynomials)

were used to assess the correlation between the post-operative SCD increment and the effective LOS. The higher the *R*<sup>2</sup>, the more satisfactory the correlation.

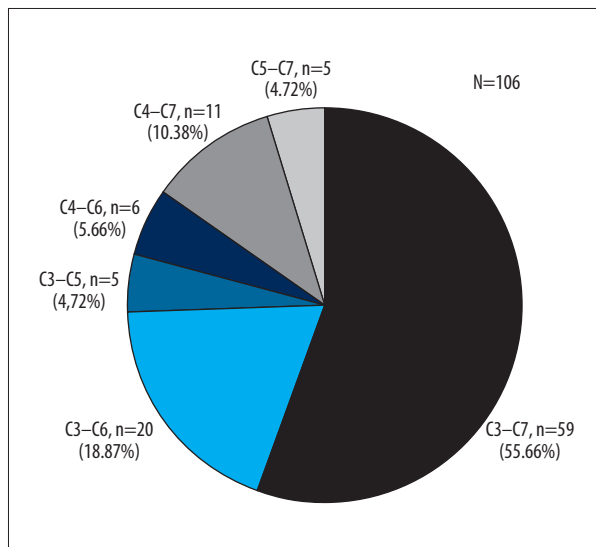
**Results**

All surgeries were successfully performed, and all patients recovered satisfactorily. The SCD in all cases were increased significantly after surgery (*P*<0.01) (Table 1). The weighted least squares regression method was used to analyze the relationship between the post-operative SCD increment and effective LOS from C3 to C7. The results indicated a strong linear correlation (*R*<sup>2</sup>>0.933, *P*<0.001) (Table 2). By analyzing all the

**Table 2.** Linear regression data of effective laminoplasty opening size (LOS) against the postoperative sagittal canal diameter (SCD) increment.

	Regression Relationship	R <sup>2</sup> value	p	N
C3	$y=0.529x-0.176$	0.971	<0.001	84
C4	$y=0.513x+0.324$	0.964	<0.001	101
C5	$y=0.547x-0.254$	0.942	<0.001	106
C6	$y=0.531x-0.178$	0.933	<0.001	101
C7	$y=0.515x+0.131$	0.951	<0.001	75
C3-C7	$y=0.521x+0.182$	0.957	<0.001	467

y – postoperative SCD increment; x – effective LOS.

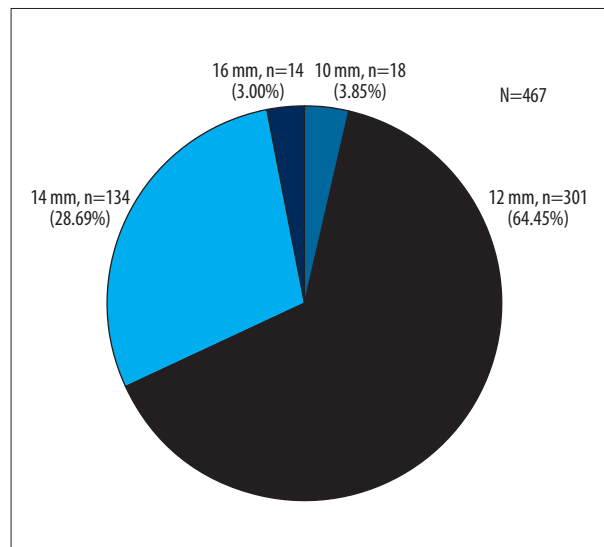


**Figure 4.** Analysis of all cervical vertebrae involved in single-door cervical laminoplasty (SDCL).

cervical vertebrae concerned by the operation, it was found that C3-C7 was the most involved level, accounting for 55.66%, while C3-C5 and C5-C7 were the least, accounting for 4.72% each (Figure 4). For single cervical vertebrae, C4, C5, and C6 were the most involved, with C5 involved in all operations. By analyzing the sizes of the mini-plates used in the operation, it was found that the size of 12 mm was the most often used, accounting for 64.45%, while 10 mm and 16 mm were least used, accounting for 3.85% and 3.00%, respectively (Figure 5).

## Discussion

Since it was first proposed and applied by Hirabayashi et al. [1] in the 1980s, SDCL has shown improved reliability compared with laminectomy and better-preserved ROM than anterior fusion, and it has been widely used in clinical treatments [7,8]. However, the issue of highly incident post-operative re-closure



**Figure 5.** Analysis of the sizes of mini-plates used in single-door cervical laminoplasty (SDCL).

after SDCL has troubled surgeons and patients for a long time. This problem was not resolved until mini-plates were applied in SDCL. In the past few years, centerpiece mini-plates have been the primary selection for SDCL due to their safe quality and operational convenience [17-19]. Clinical findings proved that SDCL with centerpiece mini-plates could effectively prevent post-operative re-closure, while fully protecting the dural sac in the spinal canal and avoiding post-operative scar tissue formation [20].

As shown in this study, all surgeries were successful. The SCD in all cases was significantly increased post-surgery (Table 1). Because the LOS has a tight association with mini-plate size, it is important in choosing mini-plates for the most satisfactory operative procedures. However, mini-plate selection is not currently standardized. Instead, most surgeons select mini-plates based on clinical experience, which would potentially lead to adverse consequences.

It was found in other studies that recovery of post-operative nerve function was closely related to the SCD and LOS [15,21]. The post-operative SCD increment seems to be more important than spinal canal area enlargement in alleviating spinal cord compression [10,22]. Lubelski et al. reported that for every 1 mm increase of SCD, the probability of C5 nerve root paralysis decreases by 69% [23]. Because the LOS and SCD determine the outcome of SDCL, multiple clinical studies have investigated the association of LOS with SCD. Itoh and Tsuji reported that a SCD increment of 4.1 mm is optimum and could be obtained via LOS enlargement to 8 mm [14]. Some researchers proposed the optimal post-operative SCD increment to be 4–5 mm in SDCL [1,15].

Although the size of the mini-plate determines the LOS, it does not necessarily mean that both are equal. It is important to note that the worn-off lamina extracted by the drill bit in SDCL has been neglected in relevant research, which could result in errors in the corresponding relationship between LOS and SCD [24]. In this study, we introduced for the first time the concept of effective LOS with the worn-off lamina, which takes the drill bit's diameter into consideration [24]. By geometric analysis, the effective LOS is mini-plate size minus the drill bit's diameter. For example, in an operation using a 12 mm mini-plate and a drill bit of 2 mm in diameter, the effective LOS should be 10 mm instead of 12 mm as previously assumed. The present research findings confirmed that it is necessary to take the worn-off lamina into consideration for more accuracy.

In this study, linear and curvilinear regression models (first and second order polynomials) were used to assess the correlation between the post-operative SCD increment and effective LOS. There was a strong linear correlation between the post-operative SCD increment and effective LOS from C3 to C7 because this model had a high  $R^2$  value (Table 2). For different vertebral laminae, the corresponding regression equation could be used to obtain accurate results in SDCL. For simplicity's sake, it is recommended to adopt the regression equation of C3–C7 in clinical practice. As shown in Table 2, the regression equation of C3–C7 was concluded as  $y=0.521x+0.182$ , where  $y$  is the post-operative SCD increment, and  $x$  the effective LOS. By further simplifying this equation, the SCD would increase by about 0.5 mm for each 1 mm increment of effective LOS. Therefore, post-operative SCDs for different mini-plates and drill bits could be precisely predicted, enabling optimal mini-plate selection for a convenient, highly precise and satisfactory SDCL procedure.

It is well-known that SDCL has the most satisfactory surgical results when the SCD is increased by 4–5 mm post-operatively [1,14,15]. Thus, the effective LOS needs to be at least around 8–10 mm for adequate spinal cord decompression based on the regression equation, which is consistent with the present findings (Table 1). However, no standard

regarding the optimal SCD for SDCL has been proposed previously [25]. Although this study mostly aimed to determine the post-operative SCD increment, it could also help evaluate post-operative SCD. Pre-operative SCD could be measured conveniently; thus, post-operative SCD could be calculated by the regression equation derived in this study.

After statistical analysis of the sizes of mini-plates used for the operation, it was found that plates of 12 mm were most often used, accounting for 64.45%, while those of 10 mm and 16 mm were least often used, accounting for 3.85% and 3.00%, respectively. Given the fact that it might lead to undesired treatment results with either inadequate or excessive LOS, more attention should be paid when selecting 10 mm and 16 mm mini-plates for surgery.

### Study limitations

It is acknowledged that there are some inadequacies in the present study which could be further improved. For example, lateral hinge location is normally at the medial border of facet joints [9,10]. Unfortunately, it was hard to identify the same position in all individuals, even with a single surgeon conducting the operations. Besides, the sizes of the worn-off laminae removed in SDCL were also influenced by the operating angle of the drill bit. However, the operating angle cannot remain exactly the same for all the patients because of anatomical differences. Moreover, the accuracy of measurements would be affected by deviations from the precise location of CT scans.

It must be stressed that the amount of worn-off lamina depends on the angle of the drill. Ideally, the drill should be perpendicular to the vertebral plate during the operation and the size of the worn-off lamina is the same as the bit diameter. In practice, however, the high-speed bit is often in an inclined position, causing the worn-off lamina to be larger than the bit diameter. Therefore, the surgeon should make the drill as perpendicular to the vertebral plate as possible according to the patient's imaging data and adequate intraoperative exposure.

### Conclusions

This research characterized the geometric relationship between the post-operative SCD increment and LOS in SDCL, considering the worn-off lamina. It introduced, for the first time, the concept of effective LOS. There was a strong linear correlation between effective LOS and the post-operative SCD increment. The SCD was increased by about 0.5 mm for each 1 mm increment of effective LOS. Therefore, post-operative SCD could be precisely predicted, which might help choose optimal mini-plates for SDCL.

## Acknowledgements

The authors are grateful for the support and help of the Imaging Department of Xijing Hospital.

## References:

1. Hirabayashi K, Watanabe K, Wakano K et al: Expansive ODCL for cervical spinal stenotic myelopathy. *Spine*, 1983; 8: 693–99
2. Du W, Wang L, Shen Y et al: Long-term impacts of different posterior operations on curvature, neurological recovery and axial symptoms for multilevel cervical degenerative myelopathy. *Eur Spine J*, 2013; 22: 1594–602
3. Liu Y, Luo X, Zhou J et al: Prognosis of posterior osteophyte after anterior cervical decompression and fusion in patients with cervical spondylotic myelopathy using three-dimensional computed tomography study. *Eur Spine J*, 2016; 25: 1861–68
4. Hyun SJ, Riew KD, Rhim SC: Range of motion loss after cervical laminoplasty: A prospective study with minimum 5-year follow-up data. *Spine J*, 2013; 13: 384–90
5. Jiang Y, Li X L, Zhou X et al: A prospective randomized trial comparing anterior cervical discectomy and fusion versus plate-only open-door laminoplasty for the treatment of spinal stenosis in degenerative diseases. *Eur Spine J*, 2017 2 6: 1162–72
6. Matsumoto M, Watanabe K, Hosogane N et al: Impact of lamina closure on long-term outcomes of ODCL in patients with cervical myelopathy: minimum 5-year follow-up study. *Spine (Phila Pa 1976)*, 2012; 37: 1288–91
7. Liu X, Chen Y, Yang H et al: Expansive open-door laminoplasty versus laminectomy and instrumented fusion for cases with cervical ossification of the posterior longitudinal ligament and straight lordosis. *Eu Spine J*, 2017; 26: 1173–80
8. Manzano GR, Casella G, Wang MY et al: A prospective, randomized trial comparing expansile cervical laminoplasty and cervical laminectomy and fusion for multilevel cervical myelopathy. *Neurosurgery*, 2012; 70: 264–77
9. Yang L, Gu Y, Shi J et al: Modified plate-only ODCL versus laminectomy and fusion for the treatment of cervical stenotic myelopathy. *Orthopedics*, 2013; 36: e79–87
10. O'Brien MF, Peterson D, Casey AT et al: A novel technique for laminoplasty augmentation of spinal canal area using titanium miniplate stabilization: A computerized morphometric analysis. *Spine*, 1996; 21: 474–83
11. Imagama S, Matsuyama Y, Yukawa Y et al: C5 palsy after cervical laminoplasty: A multicentre study. *J Bone Joint Surg Br*, 2010; 92: 393–400
12. Hatta Y, Shiraishi T, Hase H et al: Is posterior spinal cord shifting by extensive posterior decompression clinically significant for multisegmental cervical spondylotic myelopathy? *Spine*, 2005; 30: 2414–19
13. Wang XY, Dai LY, Xu HZ et al: Prediction of spinal canal expansion following cervical laminoplasty: A computer-simulated comparison between single and double-door techniques. *Spine*, 2006; 31: 2863–70
14. Itoh T, Tsuji H: Technical improvements and results of laminoplasty for compressive myelopathy in the cervical spine. *Spine*, 1985; 10: 729–36
15. Gu Z, Zhang A, Shen Y et al: Relationship between the laminoplasty opening size and the laminoplasty opening angle, increased sagittal canal diameter and the prediction of spinal canal expansion following open-door cervical laminoplasty. *Eur Spine J*, 2015; 24: 1613–20
16. Yang XJ, Tian RJ, Su X et al: Relationship of actual laminoplasty opening size and increment of the cross-sectional area based on single-door cervical laminoplasty. *Medicine*, 2018; 97: e0216
17. Chen H, Liu H, Deng Y et al: Multivariate analysis of factors associated with axial symptoms in unilateral expansive open-door cervical laminoplasty with miniplate fixation. *Medicine*, 2016; 95: e2292
18. Chen H, Liu H, Zou L et al: Effect of mini-plate fixation on hinge fracture and bony fusion in unilateral open-door cervical expansive laminoplasty. *Clin Spine Surg*, 2016; 29: E288–95
19. Yeh KT, Yu TC, Chen H et al: Expansive open-door laminoplasty secured with titanium miniplates is a good surgical method for multiple-level cervical stenosis. *J Orthop Surg Res*, 2014; 9: 49–55
20. Petraglia A L, Srinivasan V, Coriddi M et al: Cervical laminoplasty as a management option for patients with cervical spondylotic myelopathy: A series of 40 patients. *Neurosurgery*, 2010; 67: 272–77
21. Kim SW, Hai DM, Sundaram S et al: Is cervical lordosis relevant in laminoplasty? *Spine J*, 2013; 13: 914–21
22. Aita I, Hayashi K, Wadano Y et al: Posterior movement and enlargement of the spinal cord after cervical laminoplasty. *J Bone Joint Surg Br*, 1998; 80: 33–37
23. Lubelski D, Derakhshan A, Nowacki AS et al: Predicting C5 palsy via the use of preoperative anatomic measurements. *Spine J*, 2014; 14: 1895–901
24. Li K, Zhang W, Li B et al: Safety and efficacy of cervical laminoplasty using a piezosurgery device compared with a high-speed drill. *Medicine (Baltimore)*, 2016; 95: e4913
25. Ghahreman A, Rao PJ, Ferch RD: Dynamic plates in anterior cervical fusion surgery: Graft settling and cervical alignment. *Spine (Phila Pa 1976)*, 2009; 34(15): 1567–71

## Conflict of interest

None.