

## review article

# Advances in diagnostics and management of gestational trophoblastic disease

Nusa Lukinovic<sup>1</sup>, Eva Pavla Malovrh<sup>1</sup>, Iztok Takac<sup>1,2</sup>, Monika Sobocan<sup>1,2</sup>, Jure Knez<sup>1,2</sup>

<sup>1</sup> Faculty of Medicine, University of Maribor, Maribor, Slovenia

<sup>2</sup> Division of Gynecology and Perinatology, University Medical Centre Maribor, Maribor, Slovenia

Radiol Oncol 2022; 56(4): 430-439.

Received 13 May 2022

Accepted 30 August 2022

Correspondence to: Assist. Monika Sobočan, M.D., Division for Gynecology and Perinatology, University Medical Centre Maribor, Ljubljanska ulica 5, SI-2000 Maribor, Slovenia. E-mail: monika.sobocan@gmail.com

Disclosure: No potential conflicts of interest were disclosed.

This is an open access article distributed under the terms of the CC-BY license (<https://creativecommons.org/licenses/by/4.0/>).

**Background.** Gestational trophoblastic disease (GTD) is a heterogeneous group of rare tumours characterised by abnormal proliferation of trophoblastic tissue. It consists of benign or premalignant conditions, such as complete and partial molar pregnancy and variants of malignant diseases. The malignant tumours specifically are commonly referred to as gestational trophoblastic neoplasia (GTN). They consist of invasive mole, choriocarcinoma, placental-site trophoblastic tumour (PSTT) and epithelioid trophoblastic tumour (ETT).

**Conclusions.** Patients with GTD are often asymptomatic, although vaginal bleeding is a common presenting symptom. With the advances in ultrasound imaging in early pregnancy, the diagnosis of molar pregnancy is most commonly made in the first trimester of pregnancy. Sometimes, additional imaging such as chest X-ray, CT or MRI can help detect metastatic disease. Most women can be cured, and their reproductive function can be preserved. In this review, we focus on the advances in management strategies for gestational trophoblastic disease as well as possible future research directions.

Key words: gestational trophoblastic disease; hydatidiform mole; molar pregnancy; gestational trophoblastic neoplasia; human chorionic gonadotropin; invasive mole; choriocarcinoma

## Introduction

Gestational trophoblastic disease (GTD) is a heterogeneous group of rare tumours characterised by abnormal proliferation of trophoblastic tissue. Complete and partial molar pregnancy are the most common GTDs. They are generally considered to be benign disorders, but they can develop into gestational trophoblastic neoplasia and can be considered as premalignant conditions. The malignant tumours specifically are commonly referred to as gestational trophoblastic neoplasia (GTN). They consist of invasive mole, choriocarcinoma, placental-site trophoblastic tumour (PSTT) and epithelioid trophoblastic tumour (ETT).<sup>1</sup> The malignant trophoblastic disorders are collectively known as gestational trophoblastic neoplasia.<sup>2</sup> GTD and GTN may both arise after normal preg-

nancies, miscarriage, ectopic pregnancies, or abortion, but most GTNs will develop from complete molar pregnancies.<sup>3</sup> Hydatidiform mole (HM) is the most common type of GTD. In most parts of the world, the incidence of hydatidiform mole is 1 per 1000 pregnancies, although higher frequencies have been reported.<sup>1,4</sup> A classification of GTD with incidences is presented in Figure 1. The aim of this review is to provide up-to-date information on current evaluation and management strategies for gestational trophoblastic disease.

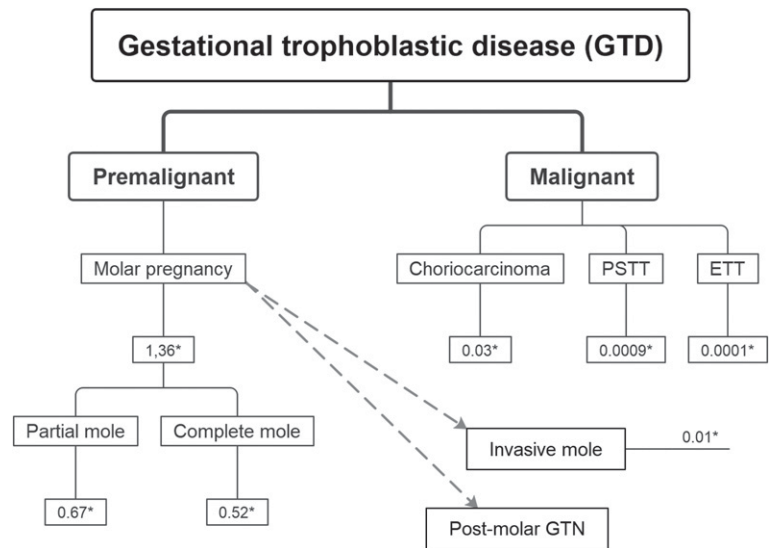
## Hydatidiform mole

Our understanding of HM has changed considerably over the last decades. It wasn't until the late 1970s that a partial mole was distinguished from

a complete mole.<sup>6</sup> Clinical presentation of HM also changed dramatically over the years. In the 1960–1970s, the mean gestational age at diagnosis was 16 weeks and classic clinical signs were vaginal bleeding, uterine enlargement greater than expected for gestational age, theca-lutein cysts due to ovarian hyperstimulation by high serum hCG values, hyperemesis, preeclampsia, hyperthyroidism, and respiratory insufficiency.<sup>1,6,7</sup> Nowadays, many patients are asymptomatic at diagnosis due to wide use of ultrasound scans in early pregnancy.<sup>1</sup> At present, mean gestational age at diagnosis is 10–12 weeks. A HM is therefore detected before the onset of classic clinical signs. However, vaginal bleeding continues to be the most common presenting symptom and it can occasionally present with passage of hydropic villi.<sup>1,7</sup> Because bleeding may be prolonged and occult, patients may be anaemic at presentation.<sup>6</sup> Symptoms can be vague and resemble complaints often present in normal pregnancy.<sup>1</sup>

### Classification of hydatidiform moles

HM can be classified as a complete hydatidiform mole (CHM) or partial hydatidiform mole (PHM) based on histopathological exam and genetics.<sup>8</sup> The common pathology of these lesions is excessive proliferation of trophoblast.<sup>6</sup> In both conditions, the placental villi become oedematous, forming hydatidiform structures.<sup>7</sup> In CHM hydrops is fully developed and most villi are involved. In PHM however, the hydrops remains characteristically focal.<sup>6</sup> In CHM foetal parts are absent.<sup>9</sup> In PHM evidence of foetal development, such as amnion vessels with foetal red blood cells, is a prominent pathologic feature.<sup>7</sup> HMs are genetically characterised with two copies of the paternal genome. Typical CHMs are diploid and androgenetic with both sets of chromosomes derived from the paternal genome and no contribution to the nuclear genome from the mother.<sup>8</sup> The monospermic 46, XX karyotype is most common, resulting from fertilisation of an ovum by a single sperm that then duplicates its DNA.<sup>8,10</sup> About 10% of CHMs are 46, XY, arising by dispermy. 46, YY embryos are presumed to be non-viable.<sup>8</sup> PHMs are almost always triploid, having an additional set of chromosomes from the father of the embryo. Most have a 69, XXX or 69, XXY karyotype usually resulting from fertilisation of an ovum by two sperms, or less frequently a diploid sperm.<sup>7,8</sup> Trisomy with XYY karyotype is rarely seen and YYY karyotype has not been observed.<sup>7</sup> Most molar pregnancies are sporadic. A small subset of women has an inherited predisposition to re-



\* Incidence rates per 1000 deliveries per year in Netherlands between 1994–2013; ETT = epithelioid type trophoblastic tumour; PSTT = placental-site trophoblastic tumour

FIGURE 1. Classification of GTD with incidence rates.

current molar pregnancies, referred to as familiar recurrent hydatidiform mole (FRHM).<sup>8,9</sup>

### Diagnosis of hydatidiform mole

The diagnosis of HM is usually suspected on ultrasound imaging. Clinical signs, symptoms, and human chorionic gonadotropin (hCG) levels can be helpful in the diagnostic process.<sup>11</sup> Diagnosis should always be confirmed by histology with or without ancillary techniques such as genotyping and p57kip2 staining.<sup>12</sup>

### Ultrasound

Ultrasound (US) is the imaging modality of choice for an initial diagnostic suspicion of GTD.<sup>13</sup> The advances of ultrasound imaging in the last decades and the wide availability of high-resolution transvaginal ultrasound (TVUS) in early pregnancy have shifted the diagnosis of HMs from the second to the first trimester of pregnancy.<sup>14,15</sup> This allows the detection of HM before the onset of systemic manifestations such as anaemia, hyperemesis, preeclampsia, hyperthyroidism or even signs of metastatic disease.<sup>16</sup>

In the first trimester, accurate US diagnosis of a CHM is more frequent than that of a PHM, because the latter has subtler US changes.<sup>13</sup> In a cohort study of 295 women<sup>14</sup> US imaging diagnosed

TABLE 1. Ultrasound characteristics of partial hydatidiform mole (PHM) versus complete hydatidiform mole (CHM)<sup>13,16,18</sup>

Feature	CHM	PHM
US characteristics	Enlarged uterus filled with a heterogeneous predominantly echogenic mass with several hypoechoic foci (snowstorm appearance), multiple small anechoic cystic spaces varying in size from 1 to 30 mm (cluster of grapes). Theca lutein cysts presenting as multiple large, bilateral, functional ovarian cysts can be present.	Subtler US changes. Hydropic changes of some villi are often not visible before 10 weeks of gestation. Enlarged placenta relative to the size of the uterine cavity with internal cystic changes producing a "Swiss cheese pattern" is often seen. Theca lutein cysts are infrequent.
Foetal parts	Absent, except in the rare event of a CHM with a coexisting diploid twin.	Present as amorphous echoes. If a foetus is formed, it carries a typical spectrum of severe abnormalities. Growth retardation is common.
Colour-power Doppler of the uterus	Variable	Variable

a significantly ( $p < 0.001$ ) higher number of CHM (74.2%) than PHM (40.7%). These data show that for PHM the diagnosis is more difficult. Hydropic villi in PHM are only focal and difficult to differentiate from the hydropic changes associated with prolonged retention after foetal demise often seen in missed abortions.<sup>18</sup>

Ultrasound feature suggestive of a complete molar pregnancy is thick, cystic tissue within the uterine cavity without a visible gestational sac. Partial hydatidiform mole is often suspected in women with intact gestational sac with cystic placental changes. The accuracy of ultrasound to diagnose molar pregnancy is difficult to assess in modern practice as the majority of miscarriages are managed conservatively and histological confirmation of diagnosis is available only in a minority of women.<sup>19</sup> The available data show that ultrasound diagnosis of complete molar pregnancy is very sensitive with the reported detection rates between 80% and 95%.<sup>16,17</sup> The diagnosis of partial molar pregnancy is less accurate with the detection rates between 20% and 30%. The accuracy of US diagnosis is also operator dependent, therefore a broader awareness of the early US signs of HM should improve the detection rate of molar pregnancy in women presenting with early pregnancy complications.<sup>15</sup>

Doppler US does not seem to differentiate between CHM and PHM. However, it is a useful tool in the diagnosis of GTN because abnormal myometrial vascularisation and lower uterine artery Doppler indices seem to be correlated with invasive disease.<sup>20</sup>

### Human chorionic gonadotropin (hCG)

Most GTDs secrete hCG which is therefore a sensitive tumour marker.<sup>1</sup> HCG is a glycoprotein hormone produced by trophoblastic tissue. It comprises

an  $\alpha$  and a  $\beta$  subunit. The  $\alpha$  subunit is shared with other members of the glycoprotein hormones, including thyroid-stimulating hormone (TSH), luteinizing hormone (LH) and follicle-stimulating hormone (FSH). In hCG, the  $\alpha$  subunit can mimic the  $\alpha$  subunit of the other glycoprotein hormones and therefore cause symptoms seen in hyperthyroidism.<sup>1,10</sup> The  $\beta$  subunit is a unique part of the hCG structure that allows the production of highly specific antibodies and the utilisation of highly specific immunologic assays.<sup>21</sup> In a healthy pregnancy, intact hCG is the predominant protein, whereas in cancer patients various hCG isoforms can be present. These include intact hCG ( $\alpha$  &  $\beta$ ), the partially degraded or nicked forms of hCG (hCG $\alpha$ n) and hCG $\beta$  (hCG $\beta$ n) and the  $\beta$ -core fragment (hCG  $\beta$ cf).<sup>22</sup> The combination of US findings with elevation of hCG above expected for gestational age is highly suggestive of molar pregnancy<sup>7</sup> and is crucial in diagnosis of GTD or GTN.<sup>1</sup> Due to hyperplastic trophoblastic cells in CHM, patients will have marked elevations in hCG, sometimes greater than 100,000 IU/L. However, such elevations are seen in fewer than 10% of patients with PHM.<sup>11</sup>

### Histological confirmation of diagnosis

HM is sometimes diagnosed only by pathology after suction dilation and curettage (D&C) is performed for a suspected early embryonic demise. When HM is suspected beforehand, it should be evacuated as soon as possible.<sup>7</sup> Histological confirmation of GTD after evacuation is mandatory.<sup>12</sup>

### Treatment of hydatidiform mole

The initial treatment of HM in women who wish to preserve fertility is D&C.<sup>23</sup> Pre-treatment evaluation consists of measurement of serum quantitative beta-hCG, complete blood count, clotting stud-

ies (PT, PTT), renal and liver functions, blood type and screen, pelvic ultrasound examination, chest X-ray and thyroid function test if hyperthyroidism is suspected.<sup>7</sup> Where available, D&C is performed under ultrasound guidance which helps to remove all molar tissue and avoid uterine perforation.<sup>11,24</sup> Usually, it is performed under general anaesthesia.<sup>7</sup> Intravenous oxytocin infusion may be started at the onset of suction D&C and may be continued for several hours after operation. Oxytocin enhances uterine contractility and decreases blood loss.<sup>24</sup> There is theoretical concern over the routine use of oxytocic agents, because of the potential to embolise and disseminate trophoblastic tissue through the venous system.<sup>25</sup> However, the authors recommend the use of oxytocin in management of molar pregnancy.<sup>2,7,24</sup> The risk of bleeding after suction D&C increases with uterine size. When the uterus is greater than 16 weeks in gestational size, blood transfusion should be available.<sup>24</sup> Because RhD factor is expressed on trophoblastic tissue, RhD immunoglobulin should be administered at the time of uterine evacuation in Rh negative women. If HM is diagnosed at early gestational age, complications during or after evacuation are uncommon.<sup>26</sup> Most common complications are excessive bleeding, uterine perforation, and respiratory distress syndrome.<sup>27</sup> Respiratory distress syndrome may be caused by trophoblastic embolization, high-output congestive heart failure caused by anaemia, hyperthyroidism, preeclampsia, or iatrogenic fluid overload.<sup>7</sup> At the end of suction D&C, the evacuated tissues should be inspected and sent for histological examination.<sup>27</sup> Uterine evacuation by medication only method is not recommended due to high failure rates, risk of haemorrhage, increased risk of post-molar GTN and increased maternal morbidity.<sup>7,23</sup>

Hysterectomy with salpingectomy is an alternative method to suction D&C if molar pregnancy is presumed and childbearing is complete.<sup>24,28</sup> Hysterectomy is especially used in women older than 40 years, because these patients have a higher risk of post molar GTN. Hysterectomy eliminates the possibility of local myometrial invasion as a source of persistent disease and hence reduces the need for subsequent chemotherapy.<sup>7,27,28</sup> Usually the adnexa may be preserved, even if theca lutein cysts are present. Theca lutein cysts usually regress over few months after uterine evacuation as hCG levels decrease.<sup>7,27</sup> Hysterectomy, compared to uterine evacuation, has a significant advantage in preventing post-molar GTN with an approximately 80% reduction in risk.<sup>26,28</sup> Because hysterectomy

does not eliminate the possibility of post molar gestational trophoblastic neoplasia these patients should also be monitored postoperatively with serial hCG measurements.<sup>7</sup>

Prophylactic administration of either methotrexate or actinomycin D chemotherapy at the time of or immediately following molar evacuation is associated with a reduction in the incidence of post molar GTN to 3%-8%. However, it should be limited to special situations where adequate hCG follow-up is not possible and the risk of post molar GTN is much greater than normal.<sup>24</sup>

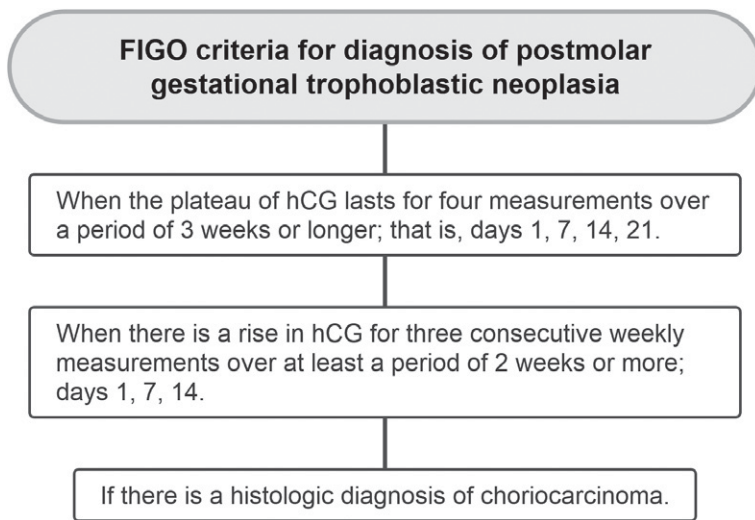
### Surveillance after molar evacuation

The gold standard for clinical management of women diagnosed with a HM is to monitor the hCG levels in urine or serum.<sup>22</sup> Following evacuation of molar pregnancy, monitoring of hCG levels postoperatively is mandatory to identify and manage post-molar GTN.<sup>27</sup> HCG is used as a marker in post molar monitoring because of the correlation between hCG levels and trophoblastic tumour burden, allowing early diagnosis and treatment of GTN.<sup>29</sup> The mean time to hCG normalization in case of partial HM is 6 weeks and in case of complete HM 7 weeks. For both complete and partial HM, 95% of patients reached normal serum hCG concentrations within 14 weeks after evacuation.<sup>30</sup> FIGO recommends hCG monitoring every 1-2 weeks until hCG is normalised, and then on monthly intervals. For PHM, one additional confirmatory normal hCG measurement 1 month after first hCG normalisation is recommended. For CHM, monthly hCG measurements are required for 6 months after hCG normalisation.<sup>27,31</sup> After evacuation of a HM effective contraception is crucial because a new pregnancy may confound the interpretation of hCG levels.<sup>29</sup>

### Gestational trophoblastic neoplasia (GTN)

GTN includes invasive mole, choriocarcinoma, placental site trophoblastic tumour (PSTT), and epithelioid trophoblastic tumour (ETT). Recently, atypical placental site nodule (APSN) has been added to the GTD spectrum.<sup>24</sup>

The reported incidence of GTN after molar pregnancy is 18% to 29%. This rate appears to be stable despite the progressively earlier diagnosis of HM.<sup>11</sup> Choriocarcinoma affects approximately 1 in 40,000 pregnancies and 1 in 40 HMs. It is 1000 times more



**FIGURE 2.** FIGO criteria for diagnosis of postmolar gestational trophoblastic neoplasia (GTN).<sup>24</sup>

likely after a CHM than another pregnancy event. 50% of choriocarcinoma cases arise from HMs, 25% follow abortion or tubal pregnancy and 25% are associated with other gestational events.<sup>11,32</sup> PSTT and ETT are rare subtypes of GTN with an incidence of 1 in 100,000 pregnancies. They represent approximately 1% of all GTN cases.<sup>11</sup>

## Post-molar GTN

Most GTN will arise after the evacuation of a HM.<sup>1</sup> GTN following a HM is referred to as post-molar GTN.<sup>24</sup> Post-molar GTN includes invasive mole and choriocarcinoma.<sup>11</sup> In contrast, PSTT and ETT can develop after any type of antecedent pregnancy, including normal pregnancy, non-molar abortion, or ectopic pregnancy.<sup>7</sup> Risk factors for post molar GTN include age 40 years, hCG levels more than 100,000 IU/L, excessive uterine enlargement, and/or theca lutein cysts larger than 6 cm.<sup>11</sup> In most patients, HMs regress spontaneously after evacuation of the molar tissue, but in approximately 15% - 20% of CHMs and 0.5% - 1% PHMs, trophoblastic tissue remains active. Consequently, hCG levels have a sustained rise or plateau, which indicates the need for evaluation and treatment.<sup>7</sup> At the FIGO Gynaecology Oncology Committee meeting in 2000, the definition of postmolar GTN based on hCG level changes were agreed (Figure 2).<sup>2,24,33</sup>

## Invasive mole

Invasive mole arises from invasion of CHM or PHM into the myometrium and/or uterine blood vessels.<sup>9,11</sup> The tendency of invasive mole to invade myometrium can result in uterine perforation and extension to adjacent organs. However, some degree of myometrial invasion of the trophoblast is probably present in most moles.<sup>9</sup> The diagnosis of invasive mole can only be histologically confirmed after hysterectomy.<sup>1</sup> As hysterectomy is nowadays rarely performed, chemotherapy is usually started without histologic confirmation of the diagnosis. Chemotherapy is essential to prevent further complications, although invasive moles rarely metastasize and are usually self-limited.<sup>7,9</sup>

## Choriocarcinoma

Choriocarcinoma is the most common malignant GTN. It is characterised by abnormal trophoblastic hyperplasia and anaplasia, absence of chorionic villi with varying degrees of haemorrhage and necrosis.<sup>9,34</sup> The tumour is mainly uterine but extrauterine sites such as fallopian tubes and ovaries can also be involved. Patients with gestational choriocarcinomas tend to develop early systemic metastasis.<sup>7</sup> Metastases have been reported in the lung, liver, spleen, kidney, bowel, or brain.<sup>9,24</sup> In contrast to ectopic tubal or ovarian choriocarcinoma, primary choriocarcinoma in other organs is likely to represent non-gestational carcinoma with trophoblastic differentiation.<sup>9</sup>

## Placental-site trophoblastic tumour (PSTT) and epithelioid trophoblastic tumour (ETT)

PSTT and ETT are the rarest subtypes of GTN. PSTT originates from the intermediate trophoblast on the maternal side of the placental bed with half of the cases invading deep into the myometrium. Chorionic villi are absent.<sup>1,24</sup> In contrast to choriocarcinoma, PSTT forms uterine lesions with less haemorrhage. Tumour necrosis is often extensive.<sup>35</sup> ETT is even rarer, and it develops from the chorionic type of intermediate trophoblast.<sup>1</sup> Nearly half arise in the cervix or lower segment of the uterus and some in the fundus or broad ligament. The characteristic nodular and expansive growth mimics cervical carcinoma.<sup>24,25</sup> PSTT and ETT share several overlapping features. They are both slow growing

tumours and can occur months to years after any type of antecedent pregnancy.<sup>35</sup> They both produce less hCG and metastasize in later stages. Typically, both tumours have limited chemosensitivity.<sup>1,7</sup>

### Clinical signs and symptoms

GTN has a varying presentation depending on the antecedent pregnancy event, disease type and extent. Post molar GTN can be associated with irregular bleeding after initial treatment for molar pregnancy, an enlarged and irregular uterus, and bilateral ovarian enlargement. However, these signs may be absent.<sup>11</sup> Patients often present with symptoms of metastatic disease. The most common metastatic sites are the lungs, but metastatic lesions can also be found in vagina, liver, brain, spleen, kidneys, and bowel. Characteristically, gestational choriocarcinoma forms a rapidly growing tumour with the ability to metastasize to virtually every body site and present with widespread dissemination. Metastatic lesions often produce abnormal bleeding because trophoblastic tumours have fragile vessels.<sup>9,11</sup> Embolization of trophoblastic tissue is also possible, and it can cause dyspnoea, coughing, chest pain, tachypnoea, and haemoptysis. Vaginal metastases can present with bleeding, which cannot be distinguished from the uterine blood loss. A gynaecological examination upon presentation is therefore important.<sup>1</sup> Liver metastases are rare and often have a poor prognosis, especially if they present with intra-abdominal bleeding, which is life-threatening. Central nervous system lesions may be asymptomatic or produce subtle neurologic symptoms such as headache. Symptoms from brain metastases can also be very severe, even fatal if they cause intracranial haemorrhage.<sup>1,7</sup> PSTT and ETT often present with irregular bleeding after some time has passed from a previous pregnancy and there may also be signs of metastatic disease.<sup>11</sup> Other rare symptoms such as virilisation and nephrotic syndrome have also been described.<sup>34</sup>

### Diagnosis of GTN

GTN is most frequently diagnosed based on hCG values as discussed above, most often without histologic verification.<sup>7</sup> It is essential to measure hCG in any woman of childbearing age who has unexplained metastatic disease.<sup>36</sup> A serum hCG determination and exclusion of normal pregnancy is essential to diagnose GTN in these circumstances, which can spare the patient an unnecessary surgery to establish the diagnosis.<sup>7</sup>

When a GTN diagnosis is made or suspected, immediate evaluation for metastases is needed. Along with the history and physical examination, the following evaluation should be performed: complete blood count, clotting function studies, renal and liver function studies, blood type and determination of pre-treatment hCG concentration.<sup>7,37</sup> A gynaecological examination should be done to exclude vaginal or pelvic metastases. Biopsy of metastatic lesions without the ability to control bleeding is highly risky due to abundant vascularisation of this type of tumours and is not essential before starting chemotherapy.<sup>11,36</sup> However, where complete excision is possible, histologic confirmation of the diagnosis is also valuable.<sup>36</sup>

Extensive radiographic evaluation should be performed. Chest X-ray is appropriate to diagnose lung metastases and can be used for counting the number of lung metastases to evaluate the risk score. Lung CT may not be used in the risk score. Liver metastases may be diagnosed by US or CT. Brain metastases may be diagnosed by MRI or CT.<sup>11,24</sup>

### Classification and staging of GTN

To categorise patients with GTN, two different systems can be used. They both correlate with clinical outcomes and identify patients at risk for failure of treatment.<sup>7</sup> Currently, the 2000 FIGO staging system is the standard classification (Table 2).

Patients are also assigned a modified World Health Organisation (WHO) prognostic index score based on prognostic factors modified as FIGO score (Table 3). It comprises age, antecedent pregnancy, interval from index pregnancy (in months), pre-treatment hCG (in mIU/mL), largest tumour size including uterus (in cm), site of metastases including uterus, number of metastases identified and previous failed chemotherapy.<sup>24</sup> A WHO risk score of 6 or lower is classified as low-risk and scores higher than 6 are classified as high-risk.<sup>7,24</sup> Staging notation uses a Roman numeral indicating FIGO anatomical staging followed by an Arabic numeral that represents WHO prognostic scoring.<sup>37</sup> FIGO risk scoring is not recommended in PSTT and ETT, although it may be of value in guiding management.<sup>35</sup>

### Treatment of low-risk GTN

Low-risk GTN (FIGO/WHO score 0–6) is primarily treated with one of two single-agent drugs,

TABLE 2. FIGO staging and classification for gestational trophoblastic neoplasia<sup>24</sup>

FIGO stage	Description
I	Gestational trophoblastic tumours strictly confined to the uterine corpus
II	Gestational trophoblastic tumours extending to the adnexa or to the vagina but limited to the genital structures
III	Gestational trophoblastic tumour extending to the lungs and may or may not involve the genital tract.
IV	Gestational trophoblastic tumours extending to all other metastatic sites

methotrexate (MTX) or actinomycin-D (Act-D). A variety of doses and infusion schedules for these drugs have been utilized.<sup>24,26</sup> To date, there is not a clearly superior regimen between these two drugs. Treatment therefore is often determined by institutional preference.<sup>26</sup> In Europe and North America, the methotrexate with folinic acid (MTX-FA) 8-day and MTX 5-day regimens are favoured over Act-D as first-line treatment.<sup>38</sup> Single-agent chemotherapy induces complete remission in 83.5% patients with stage I GTN, 80% patients with low risk stage II GTN and 81.8% patients with low risk stage III GTN.<sup>39</sup> Chemotherapy response is monitored by hCG measurements at least every 1 or 2 weeks. Chemotherapy resistance is indicated by plateau in hCG over 3 consecutive cycles or a rise in hCG over 2 consecutive cycles.<sup>11</sup> Approximately 25–30% of low-risk patients develop resistance or excessive toxicity to initial single-agent chemotherapy.<sup>38</sup> Resistance to initial single-agent chemotherapy is up to 70–80% in patients with FIGO/WHO score 5 or 6. Current challenge is whether these patients should be still considered low risk and initially treated with single-agent chemotherapy or treated with more intensive therapy from the onset.<sup>38,40</sup> Low-risk patients experiencing treatment failure with one single agent are treated with other.<sup>41</sup>

Patients with low-risk GTN resistant to either single-agent chemotherapy or relapsed disease following complete response to initial single-agent chemotherapy, are treated with multi-agent chemotherapy. Most commonly with EMA-CO regimen (etoposide, methotrexate, actinomycin D, cyclophosphamide, vincristine).<sup>38,41</sup> Multi-agent chemotherapy is associated with increased short- and longer-term toxicities. For this reason, promising new strategies are being investigated. For example, the use of carboplatin and immunotherapy agents (programmed death protein 1 (PD-1) inhibitors and programmed death ligand 1 (PD-L1) inhibitors).<sup>38,42-44</sup> In women who no longer wish to retain their fertility, first-line hysterectomy can be considered as an alternative to chemotherapy for treatment of low-risk non-metastatic GTN.<sup>27</sup> Once hCG has normalised treatment is continued for a minimum of four weeks, which represents at least two consolidation cycles.<sup>12,38</sup>

### Treatment of high-risk GTN

High-risk GTN (FIGO/WHO score > 6) is treated with multi-agent chemotherapy, with or without adjuvant surgery or radiotherapy. The most used chemotherapy protocol is EMA-CO.<sup>24</sup> In EMA-CO failures, the most employed regimen is EMA-EP (substituting etoposide and cisplatin for cyclophosphamide and vincristine in the EMA-CO regimen).<sup>26</sup> In high-risk GTN patients EMA-CO regimen induces complete response at rates of 71-78% and long-term survival rates of 85-94%.<sup>45</sup> Unlike for patients with low-risk GTN, primary hysterectomy is not effective in reducing requirement for chemotherapy or improving cure rates in patients with high-risk GTN.<sup>27</sup> As with low-risk disease, chemotherapy for high-risk disease is continued for at least 2 to 3 consolidation courses after the

TABLE 3. World Health Organization scoring system based on prognostic factors modified as FIGO score<sup>24</sup>

FIGO score	0	1	2	4
Age	<40	>40	-	-
Antecedent pregnancy	Mole	Abortion	Term	
Interval from index pregnancy, months	<4	4–6	7–12	>12
Pretreatment hCG IU/L	<10 <sup>3</sup>	>10 <sup>3</sup> –10 <sup>4</sup>	>10 <sup>4</sup> –10 <sup>5</sup>	>10 <sup>5</sup>
Largest tumour size including uterus, cm	-	3–4	≥5	-
Site of metastases including uterus	Lung	Spleen, kidney	Gastrointestinal tract	Brain, liver
Number of metastases identified	-	1–4	5–8	>8
Previous failed chemotherapy	-	-	Single drug	Two or more drugs

TABLE 4. Ongoing clinical trials involving treatment of gestational trophoblastic disease

	Trial Drug Design	Reg. Nr.	Recruitment status
<b>Immunotherapy</b>	Camrelizumab combined with apatinib for recurrent resistant GTN	NCT04047017	Completed
	Pebrolizumab for resistant GTN	NCT04303884	Not yet recruiting
	Camrelizumab combined with apatinib in patients with high-risk GTN	NCT05139095	Not yet recruiting
	Avelumab combined with methotrexate for low-risk GTN	NCT04396223	Recruiting
	Avelumab in chemo-resistant GTN	NCT03135769	Completed
	Camrelizumab combined with bevacizumab in high-risk GTN after combined chemotherapy	NCT04812002	Recruiting
	TRC105 and/or bevacizumab in refractory GTN	NCT02664961	Terminated
<b>Chemotherapy</b>	Paclitaxel plus cisplatin vs EMA-CO in high-risk GTN	NCT02639650	Unknown
	Rescue regimen with MTX vs high-dose MTX protocol in persistent GTN	NCT03280979	Unknown
	Pemetrexed disodium as salvage therapy for failed low-risk GTN	NCT00096187	Terminated
	Dactinomycin in patients with persistent or recurrent low-risk GTN	NCT00003688	Completed
	Single dose MTX vs MTX and Actinomycin-D single dose vs MTX multiple courses	NCT01823315	Unknow
	Biweekly actinomycin-D treatment vs multi-day methotrexate in low-risk GTN	NCT04562558	Recruiting
	Methotrexate vs dactinomycin in low-risk GTN	NCT00003702	Completed
	Methotrexate for prevention of postmolar GTN	NCT01984099	Completed
	Dactinomycin vs methotrexate in low-risk GTN	NCT01535053	Completed
	Chemotherapy vs follow up in hydatidiform mole with lung nodule	NCT03785574	Recruiting
	Pemetrexed in recurrent or persistent low-risk GTN	NCT00190918	Completed
	Methotrexate vs methotrexate plus actinomycin in low-risk GTN patients with score 5-6	NCT03885388	Recruiting
<b>Surgical treatment</b>	Hysteroscopic repeat curettage vs methotrexate in low-risk GTN	NCT03703271	Recruiting
	Total abdominal hysterectomy and methotrexate vs methotrexate plus folinic acid	NCT02606539	Unknown
	Second uterine evacuation vs chemotherapy in low-risk GTN	NCT04756713	Recruiting
	Second curettage in low-risk, non-metastatic GTN	NCT00521118	Completed
	Single evacuation vs double evacuation of mole	NCT01630954	Unknown

\* accurate date as of 22th January 2022; EMA-CO = etoposide, methotrexate, actinomycin D, vincristine, cyclophosphamide; GTN = gestational trophoblastic neoplasia; hCG = human chorionic gonadotropin; MTX = methotrexate

first hCG normalization.<sup>11,41</sup> A separate category of ultra-high-risk GTN, defined as WHO score 13 or more, identifies women at high risk of early death and poor outcome.<sup>26,41</sup> These patients are treated with low dose induction chemotherapy before initiating multi-agent chemotherapy. Induction chemotherapy reduces the risk of life-threatening complications, predominantly haemorrhage from metastatic implants.<sup>26</sup> For induction chemotherapy combination of low dose etoposide (100 mg/m<sup>2</sup>) and cisplatin (20 mg/m<sup>2</sup>) (EP on days 1 and 2 every 7 day, one to three cycles) is used.<sup>26,40</sup> Active areas of investigation include the utilization of high-dose chemotherapy with stem cell support, use of immunotherapy and other chemotherapy regimens.<sup>11,26</sup>

## Treatment of PSTT and ETT

Treatment of PSTT and ETT is determined by two independent poor prognostic factors: an interval of  $\geq 48$  months from the causative pregnancy and stage IV disease. Stage I tumours (confined to the uterus) arising  $< 48$  months since the antecedent pregnancy are treated with a total abdominal hysterectomy including removal of any suspicious pelvic and retroperitoneal lymph nodes. Adjuvant systemic therapy is not required. In contrast, if the PSTT/ETT originated from a pregnancy  $> 48$  months previously, then such stage I patients and stage II–IV patients should be offered aggressive platinum-based chemotherapy including the option for experimental treatments such as high-



dose chemotherapy or immunotherapy.<sup>41</sup> Residual masses after treatment should be excised wherever possible to confirm no active cancer remains.<sup>35,41</sup> The survival rate is approximately 100% for non-metastatic disease and 50-60% for metastatic disease.<sup>45</sup>

### The future in GTN management

Research in GTD is mainly focused on the development of new treatment strategies (Table 4). Especially, finding alternatives to multi-agent chemotherapy and associated short- and longer-term toxicities.<sup>38</sup> The use of immunotherapy is an important development in the management of GTN, particularly in drug-resistant disease.<sup>44</sup> The programmed cell death ligand 1 (PD-L1) is expressed in all pre-malignant and malignant GTD and anti-PD-1 monoclonal antibodies, such as pembrolizumab, are becoming important part of the management of relapsed chemo-resistant GTB.<sup>38,41,44</sup> The use of immunotherapy must be further evaluated, particularly because of the high cost and lack of longer-term safety data.<sup>38</sup>

### Surveillance after GTN

Remission of GTN is defined as three consecutive normal hCG (hCG normalisation).<sup>26</sup> Posttreatment surveillance for low and high-risk GTN consists of weekly hCG measurements for 6 weeks after normalisation, then monthly for at least 12 months.<sup>24,41,42</sup> Surveillance for ultra-high-risk GTN is longer and consists of monthly hCG measurements for 24 months after completion of consolidation chemotherapy.<sup>26</sup> A minimum of 5-year-follow-up is advised.<sup>12</sup> Rising serum hCG is not sensitive for identifying recurrence of PSTT and ETT. Therefore, in cases of PSTT and ETT surveillance with 6 monthly MRIs is recommended.<sup>26</sup> Throughout surveillance period, patients must use reliable contraception because a new pregnancy may confound the interpretation of hCG levels [24]. Because of the 1-2% risk for a second mole in subsequent pregnancy, early ultrasound examination is recommended during all future pregnancies in addition to histologic evaluation of the placenta, and postdelivery hCG.<sup>7</sup>

### Roots for further investigation

There is a need for possible future investigations to identify factors, predicting which molar pregnan-

cies will resolve spontaneously, persist as GTN or transform into choriocarcinoma, PSTT or ETT.<sup>25</sup>

It has become evident, a redefinition of the FIGO/WHO scoring system to predict resistance to single-agent chemotherapy, is needed. With an "intermediate" risk group patients scoring WHO 5 and 6 can be identified for more intensive multi-agent chemotherapy from the outset.<sup>25,38</sup>

Although medical outcomes of GTD have been widely explored, limited data are available regarding the related psychological, sexual and fertility issues.<sup>46</sup> Improved understanding of the impact of GTD on women and their families, and how they may suffer is warranted.<sup>25</sup>

## Conclusions

GTD is a rare disease and was historically associated with significant morbidity and mortality. Nowadays, many patients are asymptomatic at diagnosis due to wide use of ultrasound in early pregnancy. Initial detection of suspected HM is usually made based on ultrasound imaging, clinical signs, symptoms and hCG levels, which are above expected for gestational age. In a smaller proportion of patients, GTD leads to post molar GTN. This requires further systemic or surgical management. Posttreatment surveillance for GTN consists of regular hCG measurements. Most women with GTD can be successfully managed. One of the main future challenges in this regard is the optimization of treatment for patients with resistant GTN.

## References

1. Lok C, Frijstein M, van Trommel N. Clinical presentation and diagnosis of gestational trophoblastic disease. *Best Pract Res Clin Obstet Gynaecol* 2020; **74**: 42-52. doi: 10.1016/j.bpobgyn.2020.12.001
2. Ngan HYS, Seckl MJ, Berkowitz RS, Xiang Y, Golfier F, Sekharan PK, et al. Update on the diagnosis and management of gestational trophoblastic disease. *Int J Gynaecol Obstet* 2018; **143(Suppl 2)**: 79-85. doi: 10.1002/ijgo.12615
3. Fehlmann A, Benkortbi K, Rosseel G, Meyer-Hamme U, Tille JC, Sloan-Bena F, et al. Gestational trophoblastic disease in Switzerland: retrospective study of the impact of a regional reference centre. *Swiss Med Wkly* 2021; **151**: w20406. doi: 10.4414/sm.w.2021.20406
4. Capobianco G, Tinacci E, Saderi L, Dessole F, Petrillo M, Madonia M, et al. High incidence of gestational trophoblastic disease in a third-level university-hospital, Italy: a retrospective cohort study. *Front Oncol* 2021; **11**: 684700. doi: 10.3389/fonc.2021.684700
5. Eysbouts YK, Bulten J, Ottevanger PB, Thomas CMG, ten Kate-Booij MJ, van Herwaarden AE, et al. Trends in incidence for gestational trophoblastic disease over the last 20 years in a population-based study. *Gynecol Oncol* 2016; **140**: 70-5. doi: 10.1016/j.jgyno.2015.11.014

6. Hancock BW, Seckl MJ, Berkowitz RS. *Gestational trophoblastic disease*. London: Hodder Education Publishers; 2022.
7. Soper JT. Gestational trophoblastic disease: current evaluation and management. *Obstet Gynecol* 2021; **137**: 355-70. doi: 10.1097/AOG.0000000000004240
8. Fisher RA, Maher GJ. Genetics of gestational trophoblastic disease. *Best Pract Res Clin Obstet Gynaecol* 2021; **74**: 29-41. doi: 10.1016/j.bpobgyn.2021.01.004
9. Kaur B. Pathology of gestational trophoblastic disease (GTD). *Best Pract Res Clin Obstet Gynaecol* 2021; **74**: 3-28. doi: 10.1016/j.bpobgyn.2021.02.005
10. Seckl MJ, Sebire NJ, Berkowitz RS. Gestational trophoblastic disease. *Lancet* 2010; **376**: 717-29. doi: 10.1016/S0140-6736(10)60280-2
11. Abu-Rustum NR, Yashar CM, Bean S, Bradley K, Campos SM, Sook Chon H, et al. Gestational trophoblastic neoplasia, version 2.2019. *J Natl Compr Canc Netw* 2019; **17**: 1374-91. doi: 10.6004/jnccn.2019.0053
12. Lok C, van Trommel N, Massuger L, Golfier F, Seckl M. Practical clinical guidelines of the EOTTD for treatment and referral of gestational trophoblastic disease. *Eur J Cancer* 2020; **130**: 228-40. doi: 10.1016/j.ejca.2020.02.011
13. Cavoretto P, Cioffi R, Mangili G, Petroni M, Bergamini A, Rabaiotti E, et al. A pictorial ultrasound essay of gestational trophoblastic disease. *J Ultrasound Med* 2020; **39**: 597-613. doi: 10.1002/jum.15119
14. Memtsa M, Johns J, Jurkovic D, Ross JA, Sebire NJ, Jauniaux E. Diagnosis and outcome of hydatidiform moles in missed-miscarriage: a cohort-study, systematic review and meta-analysis. *Eur J Obstet Gynecol Reprod Biol* 2020; **253**: 206-12. doi: 10.1016/j.ejogrb.2020.07.030
15. Jauniaux E, Memtsa M, Johns J, Ross JA, Sebire NJ, Jurkovic D. Ultrasound diagnosis of complete and partial hydatidiform moles in early pregnancy failure: an inter-observer study. *Placenta* 2020; **97**: 65-7. doi: 10.1016/j.placenta.2020.06.013
16. Kirk E, Papageorgiou AT, Condous G, Bottomley C, Bourne T. The accuracy of first trimester ultrasound in the diagnosis of hydatidiform mole. *Ultrasound Obstet Gynecol* 2007; **29**: 70-5. doi: 10.1002/uog.3875
17. Shaaban AM, Rezvani M, Haroun RR, Kennedy AM, Elsayes KM, Olpin JD, et al. Gestational trophoblastic disease: clinical and imaging features. *Radiographics* 2017; **37**: 681-700. doi: 10.1148/rg.2017160140
18. Jauniaux E, Memtsa M, Johns J, Ross JA, Jurkovic D. New insights in the pathophysiology of complete hydatidiform mole. *Placenta* 2018; **62**: 28-33. doi: 10.1016/j.placenta.2017.12.008
19. Knez J, Day A, Jurkovic D. Ultrasound imaging in the management of bleeding and pain in early pregnancy. *Best Pract Res Clin Obstet Gynaecol* 2014; **28**: 621-36. doi: 10.1016/j.bpobgyn.2014.04.003
20. Lin LH, Bernardes LS, Hase EA, Fushida K, Francisco RPV. Is Doppler ultrasound useful for evaluating gestational trophoblastic disease? *Clinics* 2015; **70**: 810. doi: 10.6061/clinics/2015(12)08
21. Taylor HS, Pal L, Seli E. *Speroff's clinical gynecologic endocrinology and infertility*. Philadelphia: Wolters Kluwer; 2020.
22. McMahon LM, Stewart WW, Cuthill L. Human chorionic gonadotrophin assays to monitor GTD. *Best Pract Res Clin Obstet Gynaecol* 2021; **74**: 109-21. doi: 10.1016/j.bpobgyn.2021.05.001
23. Sato A, Usui H, Shozu M. Comparison between vacuum aspiration and forceps plus blunt curettage for the evacuation of complete hydatidiform moles. *Taiwan J Obstet Gynecol* 2019; **58**: 650-5. doi: 10.1016/j.tjog.2019.07.012
24. Ngan HYS, Seckl MJ, Berkowitz RS, Xiang Y, Golfier F, Sekharan PK, et al. Diagnosis and management of gestational trophoblastic disease: 2021 update. *Int J Gynaecol Obstet* 2021; **155**: 86-93. doi: 10.1002/ijgo.13877
25. Tidy J, Seckl M, Hancock BW, on behalf of the Royal College of Obstetricians and Gynaecologists. Management of gestational trophoblastic disease. *BJOG* 2021; **128**: e1-27. doi: 10.1111/1471-0528.16266
26. Horowitz NS, Eskander RN, Adelman MR, Burke W. Epidemiology, diagnosis, and treatment of gestational trophoblastic disease: a society of gynecologic oncology evidenced-based review and recommendation. *Gynecol Oncol* 2021; **163**: 605-13. doi: 10.1016/j.ygyno.2021.10.003
27. Ngu SF, Ngan HYS. Surgery including fertility-sparing treatment of GTD. *Best Pract Res Clin Obstet Gynaecol* 2021; **74**: 97-108. doi: 10.1016/j.bpobgyn.2020.10.005
28. Zhao P, Lu Y, Huang W, Tong B, Lu W. Total hysterectomy versus uterine evacuation for preventing post-molar gestational trophoblastic neoplasia in patients who are at least 40 years old: a systematic review and meta-analysis. *BMC Cancer* 2019; **19**: 13. doi: 10.1186/s12885-018-5168
29. Gockley AA, Lin LH, Davis M, Melamed A, Rizzo A, Sun SY, et al. Impact of clinical characteristics on human chorionic gonadotropin regression after molar pregnancy. *Clinics* 2021; **76**: e2830. doi: 10.6061/clinics/2021/e2830
30. Eysbouts Y, Brouwer R, Ottevanger P, Massuger L, Sweep F, Thomas C, et al. Serum human chorionic gonadotropin normogram for the detection of gestational trophoblastic neoplasia. *Int J Gynecol Cancer* 2017; **27**: 1035-41. doi: 10.1097/IGC.0000000000000966
31. Snyman LC. Gestational trophoblastic disease: an overview. *S Afr J Gynaecol Oncol* 2009; **1**: 32-7. doi: 10.1080/20742835.2009.11441132
32. Lurain JR. Gestational trophoblastic tumors. *Semin Surg Oncol* 1990; **6**: 347-53. doi: 10.1002/SSU.2980060610
33. FIGO Oncology Committee. FIGO staging for gestational trophoblastic neoplasia 2000. FIGO Oncology Committee. *Int J Gynaecol Obstet* 2002; **77**: 285-7. doi: 10.1016/S0020-7292(02)00063-2
34. Lurain JR. Gestational trophoblastic disease I: epidemiology, pathology, clinical presentation and diagnosis of gestational trophoblastic disease, and management of hydatidiform mole. *Am J Obstet Gynecol* 2010; **203**: 531-9. doi: 10.1016/j.ajog.2010.06.073
35. Hancock BW, Tidy J. Placental site trophoblastic tumour and epithelioid trophoblastic tumour. *Best Pract Res Clin Obstet Gynaecol* 2021; **74**: 131-48. doi: 10.1016/j.bpobgyn.2020.10.004
36. Seckl MJ, Sebire NJ, Fisher RA, Golfier F, Massuger L, Sessa C. Gestational trophoblastic disease: ESMO clinical practice guidelines for diagnosis, treatment and follow-up. *Ann Oncol* 2013; **24**(Suppl 6): 39-50. doi: 10.1093/annonc/mdt345
37. Biscaro A, Braga A, Berkowitz RS. Diagnosis, classification and treatment of gestational trophoblastic neoplasia. *Rev Bras Ginecol Obstet* 2015; **37**: 42-51. doi: 10.1590/S0100-720320140005198
38. Winter MC. Treatment of low-risk gestational trophoblastic neoplasia. *Best Pract Res Clin Obstet Gynaecol* 2021; **74**: 67-80. doi: 10.1016/j.bpobgyn.2021.01.006
39. Berkowitz RS, Goldstein DP. Current management of gestational trophoblastic diseases. *Gynecol Oncol* 2009; **112**: 654-62. doi: 10.1016/j.ygyno.2008.09.005
40. Braga A, Mora P, Melo AC de, Nogueira-Rodrigues A, Amim-Junior J, Rezende-Filho J, et al. Challenges in the diagnosis and treatment of gestational trophoblastic neoplasia worldwide. *World J Clin Oncol* 2019; **10**: 28-37. doi: 10.5306/wjco.v10.i2.28
41. Clark JJ, Slater S, Seckl MJ. Treatment of gestational trophoblastic disease in the 2020s. *Curr Opin Obstet Gynecol* 2021; **33**: 7-12. doi: 10.1097/GCO.0000000000000674
42. Clair KH, Gallegos N, Bristow RE. Successful treatment of metastatic refractory gestational choriocarcinoma with pembrolizumab: a case for immune checkpoint salvage therapy in trophoblastic tumors. *Gynecol Oncol Rep* 2020; **34**: 100625. doi: 10.1016/j.gore.2020.100625
43. Choi MC, Oh J, Lee C. Effective anti-programmed cell death 1 treatment for chemoresistant gestational trophoblastic neoplasia. *Eur J Cancer* 2019; **121**: 94-7. doi: 10.1016/j.ejca.2019.08.024
44. Ghorani E, Kaur B, Fisher RA, Short D, Joneborg U, Carlson JW, et al. Pembrolizumab is effective for drug-resistant gestational trophoblastic neoplasia. *Lancet* 2017; **390**: 2343-5. doi: 10.1016/S0140-6736(17)32894-5
45. Lurain JR. Gestational trophoblastic disease II: classification and management of gestational trophoblastic neoplasia. *Am J Obstet Gynecol* 2011; **204**: 11-8. doi: 10.1016/j.ajog.2010.06.072
46. di Mattei V, Mazzetti M, Perego G, Rottoli S, Mangili G, Bergamini A, et al. Psychological aspects and fertility issues of GTD. *Best Pract Res Clin Obstet Gynaecol* 2021; **74**: 53-66. doi: 10.1016/j.bpobgyn.2020.10.007