

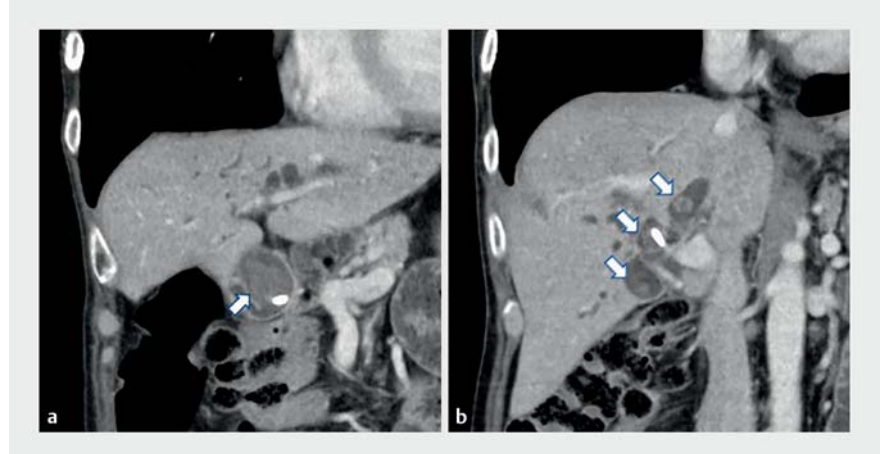
Peroral direct cholangioscopy using balloon endoscopy for massive bile duct stones after Roux-en-Y hepaticojejunostomy

OPEN
ACCESS

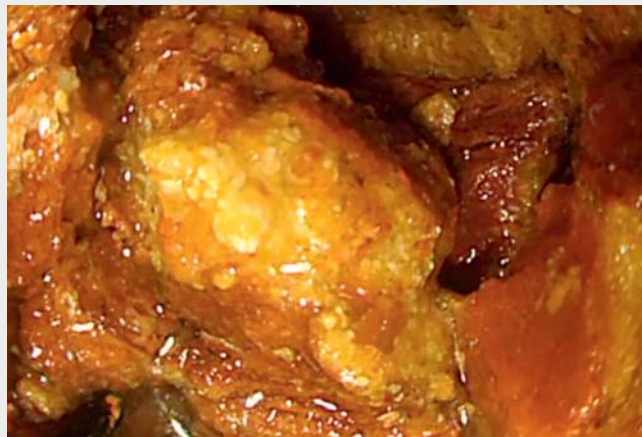A 63-year-old man with acute cholangitis was admitted to our hospital. He had undergone pancreaticoduodenectomy with Roux-en-Y hepaticojejunostomy for a duodenal ulcer 13 years previously. The patient was referred to our hospital for stone extraction after undergoing endoscopic retrograde cholangiopancreatography with plastic biliary stent placement.

Computed tomography revealed several stones (maximum size 30 mm) in multiple dilated biliary branches (► **Fig. 1**). We first attempted conventional endoscopic lithotomy, which failed due to the multiple large stones. Therefore, we performed peroral direct cholangioscopy (PDCS) to remove the bile duct stones (► **Video 1**). After reaching the anastomosis using a short-type, single-balloon endoscope (SBE, SIF-H290S; Olympus Medical System, Tokyo, Japan), we expanded the anastomosis with a large-diameter balloon (Giga 12–14 mm; Century Medical, Tokyo, Japan) and inserted the SBE directly into the bile duct. The stones were crushed using electric hydraulic lithotripsy (Nortech Autolith lithotripter with a 1.9Fr probe; Northgate Technologies, Elgin, Illinois, USA) under saline solution irrigation using an irrigation valve (BioShield irrigator; US Endoscopy, Mentor, Ohio, USA) connected to a water pump, which allowed immediate, intraprocedural, and hands-free (foot pedal control) irrigation with the device in the channel. The stones were then completely removed using a basket catheter and retrieval net under direct visualization (► **Fig. 2**).

The usefulness of PDCS for the confirmation and removal of residual stones has been reported [1]. Ultrathin endoscopes are usually used for PDCS [2]; however, conventional endoscopes often do not reach the duodenal papilla or anastomosis in patients with surgically altered anatomy. Because the channel diameter of the SBE is large, it has the advantages



► **Fig. 1** Computed tomography images. **a, b** Many stones, with a maximum size of 30 mm, were seen in multiple biliary dilated branches (arrows).



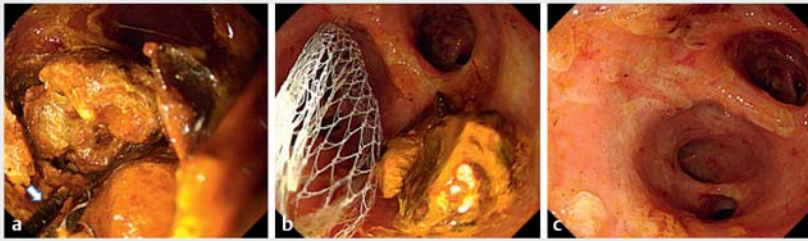
► **Video 1** Massive bile duct stones were removed with peroral direct cholangioscopy using a single-balloon endoscope after Roux-en-Y hepaticojejunostomy.

of enabling the use of various devices and strong suction power [3]. In hepaticojejunostomy cases, a frontal view of the anastomosis is often obtained. Therefore, lithotomy with PDCS using SBE should be considered an effective treatment for difficult stones with lower bile duct dilation.

Endoscopy_UCTN_Code_TTT_1AR_2AH

Competing interests

The authors declare that they have no conflict of interest.



► **Fig. 2** Endoscopic views. **a, b** The stones were crushed using electrohydraulic lithotripsy, and removed using a basket catheter and retrieval net (arrow; electrohydraulic lithotripsy probe). These procedures were performed by direct visualization (SIF-H290S; Olympus Medical System, Tokyo, Japan). **c** No residual stones were confirmed via endoscopic view.

The authors

Masatoshi Murakami^{1,2}, Nao Fujimori¹, Toyoma Kaku²

- 1 Department of Medicine and Bioregulatory Science, Graduate School of Medical Sciences, Kyushu University, Fukuoka, Japan
- 2 Department of Gastroenterology, National Hospital Organization Kyushu Medical Center, Fukuoka, Japan

Corresponding author

Nao Fujimori, MD, PhD

Department of Medicine and Bioregulatory Science, Graduate School of Medical Sciences, Kyushu University, 3-1-1 Maidashi, Higashi-ku, Fukuoka 812-8582, Japan
 Fujimori.nao.239@m.kyushu-u.ac.jp

References

- [1] Itoi T, Sofuni A, Itokawa F et al. Evaluation of residual bile duct stones by peroral cholangioscopy in comparison with balloon-cholangiography. *Dig Endosc* 2010; 22: S85–S89
- [2] Moon JH, Ko BM, Choi HJ et al. Direct peroral cholangioscopy using an ultra-slim upper endoscope for the treatment of retained bile duct stones. *Am J Gastroenterol* 2009; 104: 2729–2733
- [3] Yamauchi H, Kida M, Okuwaki K et al. Therapeutic peroral direct cholangioscopy using a single balloon enteroscope in patients with Roux-en-Y anastomosis (with videos). *Surg Endosc* 2018; 32: 498–506

Bibliography

Endoscopy 2023; 55: E177–E178

DOI 10.1055/a-1959-1500

ISSN 0013-726X

published online 11.11.2022

© 2022. The Author(s).

This is an open access article published by Thieme under the terms of the Creative Commons Attribution-NonDerivative-NonCommercial License, permitting copying and reproduction so long as the original work is given appropriate credit. Contents may not be used for commercial purposes, or adapted, remixed, transformed or built upon. (<https://creativecommons.org/licenses/by-nc-nd/4.0/>)

Georg Thieme Verlag KG, Rüdigerstraße 14, 70469 Stuttgart, Germany



ENDOSCOPY E-VIDEOS

<https://eref.thieme.de/e-videos>



Endoscopy E-Videos is an open access online section, reporting on interesting cases and new techniques in gastroenterological endoscopy. All papers include a high quality video and all contributions are freely accessible online. Processing charges apply (currently EUR 375), discounts and waivers acc. to HINARI are available.

This section has its own submission website at <https://mc.manuscriptcentral.com/e-videos>