



ORIGINAL ARTICLE

De novo antineutrophil cytoplasmic antibody-associated vasculitis in pregnancy: a systematic review on maternal, pregnancy and fetal outcomes

Nicole L. Veltri¹, Michelle Hladunewich², Artti Bhasin², Jocelyn Garland³ and Benjamin Thomson³

¹Division of Internal Medicine, Department of Medicine, Queen's University, Kingston, ON, Canada, ²Division of Nephrology, Department of Medicine, University of Toronto, Toronto, ON, Canada and ³Division of Nephrology, Department of Medicine, Queen's University, Kingston, ON, Canada

Correspondence and offprint requests to: Nicole L. Veltri; E-mail: 12nlv@queensu.ca; Twitter handle: @queensuim

ABSTRACT

Background. *De novo* antineutrophil cytoplasmic antibody-associated vasculitis typically arises in post-reproductive years, but can occur during pregnancy. Concerns of treatment-related teratogenicity persist, while efficacy and safety of new therapies including intravenous immunoglobulin (IVIG) and rituximab are uncertain. There remains a paucity of maternal, fetal and pregnancy outcome data in these women, and therefore a lack of guidance on safe treatment for clinicians.

Methods. We conducted a systematic review of the literature and a local, retrospective chart review of women with *de novo* antibody-associated vasculitis (AAV) in pregnancy. Cochrane, Embase and PubMed databases and relevant conference abstracts were searched. Patient demographics, clinical presentation, management and outcomes (maternal, fetal and pregnancy-related) were analyzed.

Results. Twenty-seven cases of *de novo* AAV in pregnancy were included. Women presented were from 5 to 39 weeks' gestation, of which a majority were in the second trimester (median 20 weeks). The median gravida of women was 2 and the median parity was 1. Women were treated with steroids (89%), cyclophosphamide (CYC) (37%), other immunosuppressive agents [azathioprine (AZA), IVIG, plasma exchange (PLEX)] or no therapy (11%). High rates of serious complications, including preeclampsia (29%) and maternal death (7%), were reported; however, most pregnancies resulted in live birth (73%). Prematurity was common; 73% of live births occurred prior to 37 weeks' gestation and 40% prior to 34 weeks' gestation. The majority of infants were born in the third trimester (median 34.5 weeks). Rates of pregnancy termination were high (23%) and only one intrauterine death was reported, shortly after initiation of therapy (4%). Congenital abnormalities were rare, with one infant having a solitary, pelvic kidney (6%) after maternal treatment with steroids, CYC and PLEX. Use of PLEX, IVIG and AZA increased after 2005, whereas CYC use decreased. Remission often occurred postpartum (60%).

Conclusions. *De novo* AAV in pregnancy can result in uncomplicated pregnancies; however, serious maternal risks exist. Further data on potentially pregnancy compatible therapies such as IVIG and rituximab are needed in this population.

Received: 23.10.2017. Editorial decision: 23.1.2018

© The Author(s) 2018. Published by Oxford University Press on behalf of ERA-EDTA.

This is an Open Access article distributed under the terms of the Creative Commons Attribution Non-Commercial License (<http://creativecommons.org/licenses/by-nc/4.0/>), which permits non-commercial re-use, distribution, and reproduction in any medium, provided the original work is properly cited. For commercial re-use, please contact journals.permissions@oup.com

Keywords: ANCA, eosinophilic granulomatosis with polyangiitis, granulomatosis with polyangiitis, microscopic polyangiitis, pregnancy

INTRODUCTION

Antineutrophil cytoplasmic antibody (ANCA)-associated vasculitides are a small vessel multi-system vasculitis characterized by necrotizing inflammation of the blood vessel wall and the presence of ANCAs [1]. Although classically a disease of the older population with peak incidence at age >40 years [1], ANCA associated vasculitis (AAV) can also be associated with pregnancy. Immunosuppression with combinations of corticosteroids (CORT) and other therapies, such as cyclophosphamide (CYC), azathioprine (AZA) and plasma exchange (PLEX), are the mainstay of treatment for AAV, with new therapies emerging such as intravenous immunoglobulin (IVIG) and rituximab [2, 3]. However, immunosuppressive therapies vary in teratogenicity and adverse risks, and thus have varying impact on maternal, fetal and pregnancy outcomes [2–5]. The advent of new induction immunosuppressive regimens raises the possibility that maternal, fetal and pregnancy outcomes have changed in pregnant women diagnosed with AAV.

There remain limited data on maternal, fetal and pregnancy outcomes of *de novo* AAV arising during pregnancy [6]. We performed a systematic review and a local, retrospective chart review of *de novo* ANCA-associated vasculitis in pregnancy to evaluate management strategies, and fetal, maternal and pregnancy-related outcomes.

MATERIALS AND METHODS

Search strategy and case selection criteria

A systematic review of the literature was performed using Cochrane, Embase and PubMed databases from 1 January 1960 to 1 February 2017, using English only. Conference abstracts were searched from annual meetings of nephrology (American Society of Nephrology 2003–15, Canadian Society of Nephrology 2012–16 and European Dialysis and Transplant Association 2002–15), rheumatology (American Rheumatology Association 2012–16, Canadian Rheumatology Association 2009–16 and European League Against Rheumatism 2002–16) and obstetrics (Fetal Medicine Foundation World Congress 2014–16 and Society for Maternal-Fetal Medicine 2008–16). Search terms were ‘ANCA’, ‘Churg-Strauss’, ‘Eosinophilic’, ‘Gestation’, ‘Polyangiitis’, ‘Pregnancy’, ‘Pregnant’, ‘Vasculitis’ and ‘Wegener’s’. Cases that were referenced in articles, but not found in the primary search, were collected separately. Cases were included if AAV symptom onset occurred during pregnancy with diagnosis either during pregnancy or postpartum (PP). Cases of drug-induced AAV were excluded. Cases in which c-ANCA or p-ANCA were either not reported or negative were only considered to be cases of AAV if there was a diagnostic biopsy.

A retrospective local chart review was performed of both local electronic medical records, in NephroCare[®]™, Patient Care System™ and Sunnybrook Health Sciences Centre Medical Records. Local electronic medical records were searched using the search term ‘ANCA’ and only charts of females diagnosed with ANCA-associated vasculitis during child-bearing age (<50 years) were examined. Of those, only women who developed symptoms and signs of AAV while pregnant who were diagnosed in pregnancy or PP were included.

Data extraction and quality assessment

One investigator (N.V.) used the search strategy to identify relevant cases. Full reports of cases were obtained and each reviewed. Data were collected for study and patient characteristics, induction and maintenance management strategy as well as maternal, fetal and pregnancy outcomes.

Data synthesis and analysis

Patient characteristics included maternal and gestational age (GA), obstetric history (gravida and parity), medical and surgical history. Information collected at presentation included symptoms at presentation, laboratory investigations, biopsy location and results and treatment.

Disease-related outcomes encompassed both disease sequelae and outcomes of therapy. Disease sequelae included short- and long-term manifestations in renal, pulmonary, hematologic, cardiac, neurologic, vascular, cutaneous, otolaryngologic and other systems.

Pregnancy-associated outcomes included (i) live birth versus fetal demise or therapeutic termination of pregnancy, (ii) prematurity, (iii) documented congenital anomalies/birth defects, (iv) admission to neonatal intensive care unit (NICU), (v) mode of delivery: vaginal versus Caesarean section (C-section), (vi) need for emergent C-section or induction of labor (IOL), (vii) preterm premature rupture of membranes (PPROM), (viii) intrauterine growth restriction (IUGR) and growth small for gestational age (SGA) with birth weight <10th centile, (ix) oligohydramnios, (x) preeclampsia and (xi) postpartum hemorrhage (PPH).

For the purposes of this study, acute kidney injury (AKI) was defined as a 1.5-fold increase in serum creatinine, renal failure requiring hemodialysis in a previously nondialysis-dependent patient or serum creatinine >100 $\mu\text{mol/L}$ with AKI or acute renal failure reported by the authors in the absence of defined previous values. Anemia was defined as serum hemoglobin <11 g/dL. Leukocytosis was defined as white blood cell count >13.6 $\times 10^3/\text{mm}^3$ in the first trimester, 14.8 $\times 10^3/\text{mm}^3$ in the second trimester and 16.9 $\times 10^3/\text{mm}^3$ in the third trimester [7]. Eosinophilia was defined as serum eosinophils >0.6 $\times 10^3/\text{mm}^3$ [7].

Analysis was performed using Microsoft Excel Version 14.1.0. For data reported in ranges, median value and quartiles were calculated if data were not normally distributed.

Ethics

Ethics approval was obtained through Queen’s University Health Sciences Research Ethics Board (identification number 6020107) and Sunnybrook Health Sciences Centre (REB PIN #146 2015).

RESULTS

Selected studies

Systematic review of literature yielded 153 abstracts, from which 7 were excluded because of language (Figure 1). Local retrospective review of electronic patient medical records revealed 13 patients, but only one developed *de novo* AAV in pregnancy and was included in the review. A total of 27 cases of *de novo* AAV during pregnancy were thus identified and included in this

review. One case of *de novo* ANCA-negative pauci-immune glomerulonephritis (GN) was considered, but not included in this group because authors did not state whether the case was considered AAV [8].

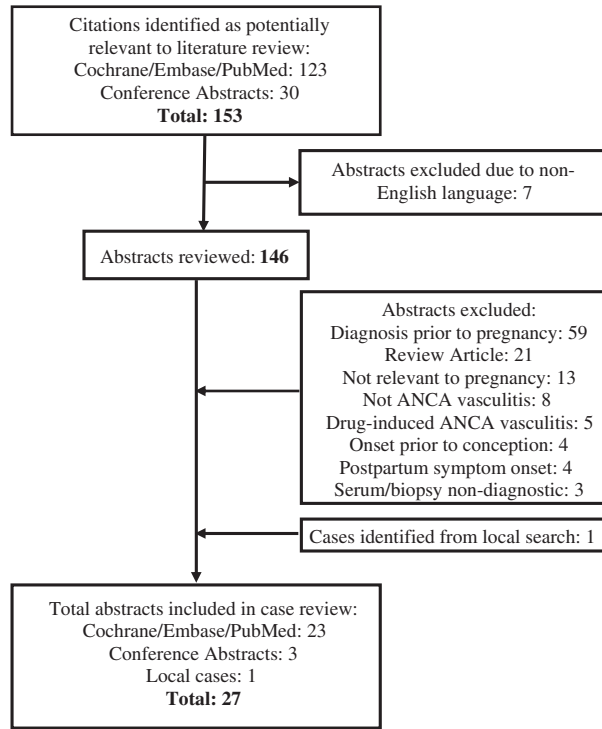


FIGURE 1: Flow of literature and local case search to identify cases of *de novo* ANCA vasculitis in pregnancy.

Patient characteristics

Maternal age ranged from 18 to 40 years at the time of pregnancy (median age 28 years) (Table 1). Women presented during their first to sixth pregnancy (median second) and were at anywhere from 5 to 39 weeks' gestation (median 20 weeks). The medical comorbidities in this group included asthma or atopy (5/16), sinusitis (2/16) and thyroid disease (2/16), with other comorbidities including non-ANCA-associated leukocytoclastic vasculitis (1/16) and diabetes mellitus (1/16). No patients were reported to have preexisting renal, autoimmune or other pulmonary diseases.

Investigations

Laboratory abnormalities at presentation included anemia (15/18), leukocytosis (4/15), eosinophilia (4/12), AKI (9/25), and presence of proteinuria (11/22) or hematuria (9/22). Bloodwork at presentation included rheumatoid factor (RF) (3/5), antinuclear antibody (ANA) (3/11) and anti-double-stranded DNA (anti-dsDNA) (1/5) (Table 1). Serum ANCA was positive in the majority of women (19/27: 13/19 c-ANCA, 4/19 p-ANCA, 1/19 both). In one case, serum ANCA was positive, but whether this was c-ANCA or p-ANCA was not reported [9]. In one case, the serum myeloperoxidase antibodies (MPO) titer was positive (153 U/mL), but serum ANCA was not reported [10]. Diagnosis was based on tissue biopsy, without serum ANCA reported, in seven cases. Anti-glomerular basement membrane (GBM) was negative in all reported cases (0/6).

When performed (24/27), biopsy sites were nasal cavity (9/24), kidney (8/24), skin (4/24), lung (3/24), vascular (2/24) and myocardium (2/24). Three women had biopsies taken at multiple sites [11–13]. Biopsies were performed during pregnancy (17/24), PP (5/24) and at delivery (1/24). One histological sample was examined in autopsy (1/24) [14]. Biopsy showed changes

Table 1. Maternal and disease demographics for reported cases of *de novo* ANCA vasculitis in pregnancy

		Cases reported, n (%)	Frequency, n (%)	Median	Range	
Maternal demographics	Age (years)	25 (92.6)	–	28	18–40	
	Gravida	16 (59.2)	–	2	1–6	
	Parity	12 (44.4)	–	1	0–5	
	GA at presentation (weeks)	25 (92.6)	–	20	5–39	
	Asthma/atopy	16 (59.2)	5 (31.2)	–	–	
	Sinusitis	16 (59.2)	2 (12.5)	–	–	
	Thyroid disease	16 (59.2)	2 (12.5)	–	–	
	Vasculitis	16 (59.2)	1 (6.25)	–	–	
	Diabetes mellitus	16 (59.2)	1 (6.25)	–	–	
Disease demographics	p-ANCA positive	19 (70.4)	6 (31.6)	–	–	
	c-ANCA positive	19 (70.4)	15 (78.9)	–	–	
	MPO positive	13 (48.1)	5 (38.5)	–	–	
	PR3 positive	13 (48.1)	8 (61.5)	–	–	
	Anti-GBM antibodies	6 (22.2)	0 (0.00)	–	–	
	ANA positive	11 (40.7)	3 (27.3)	–	–	
	Anti-dsDNA positive	5 (18.5)	1 (20.0)	–	–	
	RF positive	5 (18.5)	3 (60.0)	–	–	
	GPA diagnosis	24 (88.9)	16 (57.1)	–	–	
	MPA diagnosis	24 (88.9)	4 (14.3)	–	–	
	EGPA diagnosis	24 (88.9)	4 (14.3)	–	–	
	Biopsy performed	27 (100)	24 (88.9)	–	–	
	Biopsy location (%)	Nasal	24 (89.3)	9 (37.5)	–	–
		Renal	24 (89.3)	8 (33.3)	–	–
Skin		24 (89.3)	4 (16.7)	–	–	
Lung		24 (89.3)	3 (12.5)	–	–	
Vascular		24 (89.3)	2 (8.33)	–	–	
Cardiac		24 (89.3)	2 (8.33)	–	–	

consistent with vasculitis in most women (20/24; 8/9 nasal, 7/8 renal, 4/4 skin, 3/3 lung, 1/2 vascular, 2/2 myocardium). In all seven cases in which biopsy results did not confirm vasculitis, diagnosis was made by a combination of clinical and laboratory data, including positive serologic markers (i.e. ANCA, MPO or proteinase 3 antibodies (PR3)).

Induction and maintenance therapy

The most common antenatal induction therapy was CORT (24/27) followed by CYC (10/27), and the most common antenatal induction combination therapy was CYC and CORT (8/27) (Table 2). Other regimens included CORT monotherapy (7/27), as

well as AZA and CORT (2/27). In certain cases, CYC therapy was added to these regimens PP (4/17). In some cases, no antenatal therapy was given (3/27); however, in two of these cases either steroids (1/3) or a combination of CORT and CYC (1/3) was added PP. When given in pregnancy, CYC was given in the second trimester (7/10) and third trimester (2/10); the timing of CYC therapy was not reported in one case (1/10) (Table 3). The frequency of PLEX, AZA and IVIG use was similar (5/27, 4/27 and 4/27, respectively), and the use of PLEX and IVIG increased in frequency in later decades (Table 3). From before to after 2005, antenatal use of CYC induction therapy decreased (8/14 to 2/13), whereas antenatal use of AZA (1/14 to 3/13), PLEX (1/14 to 4/13) and IVIG (0/14 to 4/13) increased (Table 3). PP use of CYC

Table 2. Induction therapy regimens for cases of de novo ANCA vasculitis in pregnancy

Induction regimen	Cases reported, n (%)	Number treated, n (%)	PP additional therapy, n (%)	References
-	27 (100)	-	-	-
CORT ± other	-	24 (88.9)	2 (8.33)	-
CYC ± other	-	10 (37.0)	-	-
PLEX ± other	-	5 (18.5)	2 (40.0)	-
IVIG ± other	-	4 (14.8)	1 (25.0)	-
AZA ±- other	-	4 (14.8)	-	-
None	-	3 (11.1)	2 (66.7)	[10, 15, 16]
CYC + CORT	-	8 (29.6)	-	[11, 17–23]
CORT	-	7 (25.9)	2 (28.6)	[9, 14, 24–28]
AZA + CORT	-	2 (7.41)	-	[12, 29]
IVIG + CORT	-	1 (3.70)	-	[13]
PLEX + CORT	-	1 (3.70)	1 (100)	[30]
CYC + PLEX + CORT	-	1 (3.70)	-	[31]
IVIG + AZA + CORT	-	1 (3.70)	-	[32]
IVIG + PLEX + CORT	-	1 (3.70)	1, (100)	[33]
IVIG + CYC + PLEX + CORT	-	1 (3.70)	-	[34]
PLEX + AZA + CORT	-	1 (3.70)	-	[22]

Table 3. Induction and maintenance therapy in de novo ANCA vasculitis in pregnancy stratified by timing in pregnancy and decade of publication

		Symptom onset, n (%)	Therapy, n (%)					None
			CORT	CYC	PLEX	AZA	IVIG	
Timing of therapy ^a	First trimester	7 (25.9)	4 (14.8)	0 (0)	3 (11.1)	0 (0)	1 (3.70)	-
	Second trimester	10 (37.0)	13 (48.1)	7 (25.9)	1 (3.70)	2 (7.41)	0 (0)	-
	Third trimester	6 (22.2)	5 (18.5)	2 (7.41)	0 (0)	1 (3.70)	2 (7.41)	-
	Postpartum	0 (0.00)	2 (7.41)	5 (18.5)	0 (0)	0 (0.00)	0 (0)	-
	Induction	-	24 (88.9)	10 (37.0)	5 (18.5)	4 (14.8)	4 (14.8)	3 (11.1)
	Maintenance	-	13 (61.9)	11 (52.4)	0 (0)	2 (9.52)	0 (0)	5 (23.8)
	Not reported	4 (14.8)	2 (7.41)	1 (3.70)	1 (3.70)	1 (3.70)	1 (3.70)	-
Timing of publication (induction therapy) ^b	1980–89	-	2 (100)	1 (50.0)	0 (0)	1 (50.0)	0 (0)	0 (0)
	1990–99	-	9 (100)	5 (55.6)	0 (0)	0 (0)	0 (0)	0 (0)
	2000–09	-	8 (80.0)	2 (20.0)	1 (10.0)	2 (20.0)	2 (20.0)	2 (20.0)
	2010–17	-	5 (83.3)	2 (33.3)	4 (66.6)	1 (16.7)	2 (33.3)	1 (16.7)
	Prior to 2005	-	14 (100)	8 (57.1)	1 (7.14)	1 (7.14)	0 (0)	0 (0)
	2005 and later	-	10 (76.9)	2 (15.4)	4 (30.8)	3 (23.1)	4 (30.8)	3 (23.1)
Timing of publication (maintenance therapy) ^b	1980–89	-	1 (50.0)	1 (50.0)	0 (0)	0 (0)	0 (0)	-
	1990–99	-	4 (44.4)	4 (44.4)	0 (0)	0 (0)	0 (0)	-
	2000–09	-	5 (50.0)	3 (30.0)	0 (0)	1 (10.0)	0 (0)	-
	2010–17	-	3 (42.8)	3 (42.8)	0 (0)	1 (14.3)	0 (0)	-
	Prior to 2005	-	7 (50.0)	6 (42.8)	0 (0)	0 (0)	0 (0)	-
	2005 and later	-	6 (46.2)	5 (38.5)	0 (0)	2 (15.4)	0 (0)	-

^aPercentage of total women.

^bPercentage of total cases reported in the defined decade of publication.

increased from before to after 2005 (1/14 to 4/13). PLEX was administered in 4–10 doses in reported cases (median 7; 4/5 reported), and 5 doses of IVIG were administered in all cases (4/4 reported). No woman received rituximab (0/27). The most common maintenance therapy was CORT and CYC (8/16), followed by CYC monotherapy (3/16), CORT monotherapy (3/16), and CORT and AZA (2/16). The frequency of CYC usage as maintenance therapy did not change from before to after 2005 (6/12 to 5/9).

Disease-related outcomes

The most common manifestation of disease was pulmonary involvement (20/25), which included radiographic changes (20/25), alveolar hemorrhage (4/25), pleural effusion (3/25) and respiratory failure requiring intubation (2/25) (Table 4). Renal involvement was common (14/25), with AKI (9/25), proteinuria (11/22), hematuria (9/22), and the need for short-term (5/25) and long-term (2/25) hemodialysis. Additional serious maternal complications included acute limb ischemia resulting in amputation (2/26), splenic infarct (1/26), acute mesenteric ischemia requiring partial small bowel resection (1/26) and cardiomyopathy necessitating PP cardiac transplant (1/26) [15–18]. Infection occurred in women treated with CYC (3/10), AZA (1/4), steroids (5/24) and PLEX (1/5) (Table 5). Maternal death occurred in the peripartum period (2/26) and resulted from acute respiratory distress syndrome (ARDS) secondary to severe respiratory infection and intracranial bleeding [12, 19]. Remission of disease occurred during pregnancy (10/25) or PP (15/25). Antenatal remission occurred in most women treated with AZA (3/4) and less so with other therapies (2/4 IVIG, 5/10 CYC, 2/5 PLEX, 10/24 CORT and 0/3 none) (Table 4). Following remission, the majority of women continued maintenance therapy (16/23), and reported

relapse (4/17) occurred with tapering of therapy (2/4) and in subsequent pregnancies (2/4).

Maternal mortality was a reported complication of *de novo* AAV in pregnancy. One woman died shortly after presenting with malaise, nasal obstruction, epistaxis and cutaneous ulcerations in her second trimester [12]. Nasal and cutaneous biopsies were consistent with granulomatosis with Polyangiitis (GPA), so she was treated with prednisone and AZA induction therapy. During treatment, she developed bilateral intracranial hematomas and died. The second woman presented at 16 weeks' gestation with rash, arthralgia and fevers, and was diagnosed with microscopic polyangiitis (MPA) with renal involvement with positive MPO-ANCA and renal biopsy results [19]. She was treated with daily intravenous methylprednisolone and one dose of CYC, and suffered a spontaneous abortion on Day 3 of therapy. She then developed ARDS secondary to a methicillin-resistant staphylococcus aureus (MRSA) respiratory infection and died of respiratory failure.

Pregnancy-associated outcomes

The majority of pregnancies resulted in live birth (19/26; one case unreported). The GA of the infants ranged from 28 to 39 weeks (median 34.5 weeks). Prematurity (11/15 born <37 weeks and 6/15 <34 weeks) and SGA infants (34/15) were common. The location of newborn admission was seldom explicitly reported, but NICU admission was reported in two cases. Only one case of a birth defect, a solitary pelvic kidney (1/18), was reported [31]. Another case of possible skeletal dysplasia was reported, but testing was pending at the time of publication [10]. Infant death was not reported in any case (0/19). Several women underwent either therapeutic termination of pregnancy (6/26) at 12–33 weeks or

Table 4. Disease outcomes for cases of *de novo* ANCA vasculitis in pregnancy stratified by induction therapy

		Cases reported, n (%)	Frequency, n (%)	Therapy, n (%) ^a					
				CORT	CYC	PLEX	IVIG	AZA	None
Renal	AKI	25 (92.6)	9 (38.5)	8 (88.9)	5 (55.6)	5 (55.6)	2 (22.2)	1 (11.1)	1 (11.1)
	Proteinuria	22 (81.4)	11 (47.8)	11 (100)	5 (45.4)	4 (36.4)	4 (36.4)	3 (27.3)	0 (0)
	Hematuria	22 (81.4)	9 (43.5)	9 (100)	4 (44.4)	4 (44.4)	3 (33.3)	3 (33.3)	0 (0)
	HD, short-term	25 (92.6)	5 (20.0)	4 (80.0)	2 (40.0)	3 (60.0)	2 (40.0)	0 (0)	1 (20.0)
	HD, long-term	25 (92.6)	2 (8.00)	1 (50.0)	1 (50.0)	0 (0)	0 (0)	0 (0)	1 (50.0)
Pulmonary	Radiologic changes	25 (92.6)	20 (80.0)	18 (90.0)	7 (35.0)	3 (15.0)	3 (15.0)	2 (10.0)	2 (10.0)
	Alveolar hemorrhage	25 (92.6)	4 (16.0)	3 (75.0)	2 (50.0)	2 (50.0)	0 (0)	0 (0)	1 (25.0)
	Pleural effusion	25 (92.6)	3 (12.0)	2 (66.7)	1 (33.3)	0 (0)	0 (0)	0 (0)	1 (33.3)
	Respiratory failure	25 (92.6)	2 (8.00)	1 (50.0)	1 (50.0)	1 (50.0)	0 (0)	0 (0)	1 (50.0)
Hematologic	Anemia	18 (66.7)	15 (83.3)	13 (86.7)	6 (40.0)	4 (26.7)	3 (20.0)	3 (20.0)	2 (13.3)
	Leukocytosis	15 (55.6)	4 (26.7)	4 (100)	3 (75.0)	1 (25.0)	0 (0)	0 (0)	0 (0)
	Eosinophilia	12 (44.4)	4 (33.3)	4 (100)	1 (25.0)	0 (0)	0 (0)	0 (0)	0 (0)
Infectious	Infection	26 (96.3)	5 (18.5)	5 (100)	3 (60.0)	1 (20.0)	0 (0)	1 (20.0)	0 (0)
Neurologic	Neuropathy	26 (96.3)	3 (11.1)	3 (100)	0 (0)	0 (0)	0 (0)	0 (0)	0 (0)
Cardiac	Cardiac transplant	26 (96.3)	1 (3.70)	0 (0)	0 (0)	0 (0)	0 (0)	0 (0)	1 (100)
Vascular	Limb ischemia	26 (96.3)	2 (7.41)	1 (50.0)	1 (50.0)	0 (0)	0 (0)	0 (0)	1 (50.0)
	Splenic infarct	26 (96.3)	1 (3.70)	0 (0)	0 (0)	0 (0)	0 (0)	0 (0)	1 (100)
	Mesenteric ischemia	26 (96.3)	1 (3.70)	1 (100)	1 (100)	0 (0)	0 (0)	0 (0)	0 (0)
Cutaneous	Cutaneous involvement	26 (96.3)	10 (37.0)	9 (90.0)	3 (30.0)	1 (10.0)	1 (10.0)	2 (20.0)	1 (10.0)
ENT	ENT involvement	26 (96.3)	13 (48.1)	13 (100)	6 (46.2)	0 (0)	2 (15.4)	2 (15.4)	0 (0)
Disease remission	Antenatal remission	25 (92.6)	10 (40.0)	10 (100)	5 (50.0)	2 (20.0)	2 (20.0)	3 (30.0)	0 (0)
	Remission post pregnancy	25 (92.6)	15 (60.0)	13 (86.7)	4 (26.7)	3 (20.0)	2 (13.3)	0 (0)	2 (13.3)
	Maintenance therapy	21 (77.8)	16 (76.2)	15 (93.8)	7 (43.8)	4 (25.0)	4 (25.0)	2 (12.5)	1 (6.25)
	Relapse	17 (63.0)	4 (23.5)	4 (100)	1 (25.0)	0 (0)	1 (25.0)	1 (25.0)	0 (0)
Mortality	Maternal death	26 (96.3)	2 (7.69)	2 (100)	1 (50.0)	0 (0)	0 (0)	1 (50.0)	0 (0)

^aPercentage of number of cases with the indicated outcome that received the therapy, for example, 88.9% of patients with AKI received CORT. ENT, ear, nose and throat; HD, hemodialysis.

Table 5. Pregnancy-related outcomes for cases of de novo ANCA vasculitis in pregnancy stratified by induction therapy

	Cases reported, n (%)	Frequency, n (%)	Median	Therapy, n (%) ^a					
				CORT	CYC	PLEX	IVIG	AZA	None
Live birth	26 (96.3)	19 (73.1)		15 (78.9)	7 (36.8)	2 (10.5)	2 (10.5)	2 (10.5)	3 (15.8)
GA at delivery (weeks)	15 (78.9)	–	34.3	–	–	–	–	–	–
Prematurity: delivery prior to 37 weeks	15 (78.9)	11 (73.3)		9 (81.8)	6 (54.5)	2 (18.2)	0 (0)	1 (9.09)	2 (18.2)
Delivery prior to 34 weeks	15 (78.9)	6 (40.0)		5 (83.3)	4 (66.7)	1 (16.7)	0 (0)	1 (16.7)	1 (16.7)
SGA	14 (51.8)	3 (21.4)		3 (100)	2 (66.7)	2 (66.7)	0 (0)	1 (33.3)	1 (33.3)
NICU admission	2 (7.14)	2 (100)		2 (8.33)	1 (10.0)	1 (20.0)	0 (0)	1 (25.0)	0 (0)
Solitary, pelvic kidney	18 (94.7)	1 (5.56)		1 (100)	1 (100)	1 (100)	0 (0)	0 (0)	0 (0)
IUGR	17 (63.0)	1 (5.88)		1 (100)	0 (0)	1 (100)	0 (0)	1 (100)	0 (0)
Oligohydramnios	17 (63.0)	1 (5.88)		1 (100)	0 (0)	0 (0)	0 (0)	0 (0)	0 (0)
PPROM	17 (63.0)	4 (23.5)		4 (100)	3 (75.0)	1 (25.0)	0 (0)	0 (0)	0 (0)
Preeclampsia	17 (63.0)	5 (29.4)		4 (80.0)	2 (40.0)	1 (20.0)	0 (0)	1 (20.0)	1 (20.0)
Pregnancy termination	26 (96.3)	6 (23.1)		6 (100)	2 (33.3)	3 (50.0)	2 (33.3)	0 (0)	0 (0)
Miscarriage	26 (96.3)	1 (3.85)		1 (100)	1 (100.0)	0 (0)	0 (0)	0 (0)	0 (0)
GA at miscarriage or termination	6 (75.0)	–	16	–	–	–	–	–	–
IOL	17 (89.5)	7 (41.2)		7 (100)	4 (57.1)	1 (14.3)	2 (28.6)	1 (14.3)	0 (0)
Vaginal delivery	17 (89.5)	10 (58.8)		9 (90.0)	5 (50.0)	1 (10.0)	2 (20.0)	1 (10.0)	1 (10.0)
C-section	17 (89.5)	7 (41.2)		5 (71.4)	2 (28.6)	1 (14.3)	0 (0)	1 (14.3)	2 (28.6)
Emergent C-section	17 (89.5)	4 (23.5)		2 (50.0)	0 (0)	1 (25.0)	0 (0)	1 (25.0)	2 (50.0)
PPH	17 (89.5)	1 (5.88)		0 (0)	0 (0)	0 (0)	0 (0)	0 (0)	1 (100)

^aPercentage of number of cases with the indicated outcome that received the therapy, for example, 78.9% of cases resulting in live birth received CORT.

miscarriage (1/26) (2/26) at 16 weeks. The miscarriage occurred on Day 3 of methylprednisolone and CYC therapy. In some cases, pregnancy was complicated by preeclampsia (5/17), resulting in either C-section (4/5) or IOL (1/5). PPROM (<37 weeks) was common (5/17). The primary mode of delivery was vaginal (10/17) followed by C-section (7/17), of which over half were emergent (4/7).

Cases without induction therapy. All cases that underwent no induction therapy throughout their disease course (3/27) occurred from 2005 onwards. One woman presented at 34 weeks' gestation with fever, hemoptysis and leg pain, and subsequently developed recurrent leg ischemia requiring amputation [15]. She delivered a healthy infant at 34 weeks' gestation via C-section and was then diagnosed with GPA with positive c-ANCA. She dramatically improved with prednisolone and CYC induction therapy. Another woman presented at 10 weeks' gestation with fatigue, vomiting and oliguria and was found to have dialysis-dependent AKI [10]. She was diagnosed with MPA on the basis of positive MPO-ANCA and a diagnostic renal biopsy; however, induction therapy was not administered given the risks of immunosuppressive treatment in pregnancy. She subsequently developed resistant hypertension with poor fetal growth and concerns regarding possible skeletal dysplasia of the fetus, and emergent C-section was performed at 29 weeks' gestation complicated by PPH. The final woman with a history of atopy and asthma presented with progressive dyspnea at 39 weeks' gestation and 2 months PP developed respiratory failure and hemodynamic shock [16]. Echocardiogram revealed severe left ventricular dysfunction and mitral regurgitation, and myocardial biopsy was consistent with eosinophilic granulomatosis with polyangiitis (EGPA). She was treated with intravenous methylprednisolone and underwent successful cardiac transplant.

DISCUSSION

It is unclear whether AAV symptoms are affected by pregnancy. The literature reports risk of flares of GPA during pregnancy in women with preexisting EGPA or GPA to be 36.4% and 40%,

respectively [35]. In addition, in a study of 350 women with vasculitic diseases encompassing AAV, polyarteritis nodosa, Behçet's Disease and Takasayu's arteritis, 18% of women experienced worsening of symptoms, 59% were unchanged and 23% actually experienced improvement of symptoms during pregnancy [36]. The risk of relapse during pregnancy is unpredictable and bimodal, highest in the first/second trimester of pregnancy as well as 1 month PP [5]. Our results were consistent with these statistics; over 75% of women with *de novo* disease presented prior to the third trimester (median GA at presentation 20 weeks) and four other cases arose between 3 days and 3 months PP.

This review confirms that maternal outcomes of *de novo* AAV in pregnancy were quite poor, even with treatment. Of 27 cases, over half (56%) reported serious maternal complications, including alveolar hemorrhage, respiratory failure, renal failure resulting in short- or long-term hemodialysis, limb ischemia, mesenteric ischemia, severe cardiac failure requiring cardiac transplant and maternal death (Table 4). One woman died shortly after she developed bilateral intracerebral hematomas as described above [12]. There were no preexisting medical comorbidities reported that would have predisposed her to an intracranial hemorrhage, suggesting that this was a complication of severe GPA. This complication has been reported in GPA in the nonpregnant population, however, is more common in MPA and EGPA [37, 38]. The second maternal death was in the context of severe respiratory infection and ARDS as a complication of MPA [19]. There are obvious complications associated with immunosuppression, and in our study, the infection rate was as high as 21% in those treated versus 0% in those that went untreated. This can be compared with nonpregnant AAV patients treated with immunosuppressive therapy with infection rates of 20–60% in observational studies [39]. However, in the subgroup of women who were not treated in pregnancy, outcomes were very poor, as described above [10, 15, 16]. So, although many of the immunosuppressive therapies have risks and side effects, withholding treatment is likely not a viable alternative in this condition.

Our review showed a very high (73%) prematurity rate among those with *de novo* AAV who did not opt for termination of pregnancy (Table 5). Of those, over half (56%) delivered at under 34 weeks' gestation. This compares unfavorably with women who became pregnant while AAV disease was in remission, in whom prematurity rates were 23.2 and 28.5% in two studies [35, 36]. The likelihood of prematurity did not appear related to the GA of presentation. It is likely that prematurity was related to disease severity and possibly choice of induction therapy. In our review, exposure to CYC was reported in 10/27 cases, resulting in 7/10 live births, 6/7 and 1/7 cases with and without prematurity, respectively. Prematurity was much more likely in women who suffered serious outcomes (8/15), as defined above, versus those who did not (3/11). In addition, renal involvement, a condition that is independently associated with prematurity, was more likely in cases of prematurity (8/11) versus not premature (1/4) [40].

Our review showed high rates of PPRM (24%) and C-section delivery (41%) in women with *de novo* disease. This is higher than previously reported C-section rates in women with preexisting AAV in remission at the time of conception (9–23%) [6, 41]. In one European study, the C-section rate was as high as 48.2% in women with vasculitis in remission at the time of conception [35]. However, in nearly 40% of these cases no medical or obstetrical indication was given, aside from C-section being considered a safer method of delivery. Emergent C-section rates in our study (27.8%) are comparable to the literature, reported as high as 23% in a study of 19 pregnancies with previous diagnoses of systemic necrotizing vasculitis, secondary to preeclampsia, cardiac failure and infection [42]. For *de novo* AAV during pregnancy, delivery may be a definitive therapy, as remission during pregnancy occurred in under half (40%) and remission PP occurred in over half (60%) of cases. This suggests that, like in systemic lupus, pregnancy potentiates disease activity, and in those presenting early in pregnancy, termination should be considered.

CYC is traditionally one of the mainstays of induction therapy in AAV, however it is mutagenic, teratogenic and embryolethal, especially in the first trimester of pregnancy [4]. In our study, one case of *de novo* AAV with CYC exposure early in the second trimester resulted in fetal demise at 16 weeks' gestation [19]. In another case, an infant was born with a birth defect following treatment with CYC in the second trimester; a solitary pelvic kidney, which has not previously been reported in the literature as a complication of CYC therapy. In human embryology, renal genesis begins at the fourth week of gestation and renal ascent occurs in Weeks 6–8. Therefore, the likelihood of fetal exposure to CYC in the second trimester leading to this congenital defect is low. The remaining eight infants born after CYC exposure were not reported to have any birth defects. None of the cases reported fetal exposure to CYC in the first trimester. However, our review shows a shift in induction and maintenance regimens away from CYC and towards AZA, IVIG and PLEX in *de novo* AAV in pregnancy from 2005 onwards. This shift correlates to a movement in the literature towards finding alternative therapies to CYC due to concerns of maternal and fetal toxicity [2, 3, 5, 43–47]. Despite the treatment approach changing, the outcomes of women with *de novo* disease remained poor. Interestingly, all three cases of women who went untreated during pregnancy occurred in 2005 and later, but concerns regarding toxicities of therapy were the reasoning in only one case. Maternal mortality rate decreased from 14% prior to 2005 to 0% in 2005 and later, but the absolute number of women who died was quite small, and thus more data are needed on this topic.

Rituximab is another emerging alternative treatment option for AAV. It is known to cross the placenta in increasing amounts

throughout pregnancy. Fetal serum concentrations are negligible in the first trimester, but match maternal levels by 26 weeks' gestation and can actually exceed maternal levels at delivery [48, 49]. Rituximab use in pregnancy has not been associated with fetal complications; however, there is a risk of maternal and fetal neonatal B-cell depletion and therefore, increased risk of infection [4, 48–50]. One case was reported of *de novo* ANCA-negative, pauci-immune GN. The authors did not confirm that this was diagnostic for AAV; however, this particular case was refractory to steroids, rituximab and PLEX [8]. The outcome was pregnancy termination and maternal long-term hemodialysis. Clearly, more data are needed to determine if rituximab can improve pregnancy outcomes.

Conclusion

In conclusion, *de novo* AAV in pregnancy is associated with high rates of maternal and fetal pregnancy-related complications. As we attempt to move away from cytotoxic therapies in pregnancy, there remains a paucity of literature on the outcomes associated with the newer generation of therapies such as rituximab. This review highlights the need for practitioners to continue reporting cases of *de novo* AAV in pregnancy, especially those treated with rituximab. In addition, publishing cases where serious maternal complications or death occur is important in order to identify women with high-risk features wherein termination should be strongly recommended. When managing these patients, a multidisciplinary team is required to counsel patients and to optimize outcomes given the complexity of medical issues in this population.

AUTHORS' CONTRIBUTIONS

In manuscript preparation, N.V. completed the literature review, analysis, table and figure construction and manuscript preparation. A.B. analyzed the data from the local case that was included in our review. M.H. reviewed the manuscript and provided the local case in conjunction with A.B. J.G. reviewed the manuscript. B.T. was the principal investigator and was involved in data collection, data analysis and manuscript preparation.

CONFLICT OF INTEREST STATEMENT

None declared.

REFERENCES

- Rowaiye OO, Kuzstal M, Klinger M. The kidneys and ANCA-associated vasculitis: from pathogenesis to diagnosis. *Clin Kidney J* 2015; 8: 343–350
- Stone JH, Merkel PA, Spiera R et al. Rituximab versus cyclophosphamide for ANCA-associated vasculitis. *N Engl J Med* 2010; 363: 221–232
- Jones RB, Tervaert JWC, Hauser T et al. Rituximab versus cyclophosphamide in ANCA-associated renal vasculitis. *N Engl J Med* 2010; 363: 211–220
- Leroy C, Rigot J-M, Leroy M et al. Immunosuppressive drugs and fertility. *Orphanet J Rare Dis* 2015; 10: 136
- Harber MA, Tso A, Taheri S et al. Wegener's granulomatosis in pregnancy—the therapeutic dilemma. *Nephrol Dial Transplant* 1999; 14: 1789–1791
- Croft AP, Smith SW, Carr S et al. Successful outcome of pregnancy in patients with anti-neutrophil cytoplasm antibody-associated small vessel vasculitis. *Kidney Int* 2015; 87: 807–811

7. Abbassi-Ghanavati M, Greer LG, Cunningham FG. Pregnancy and laboratory studies: a reference table for clinicians. *Obstet Gynecol* 2009; 114: 1326–1331
8. Conduit C, Yew S, Jose M et al. A case of de novo diagnosis anca-negative pauci-immune necrotizing glomerulonephritis in pregnancy. *Nephrology* 2016; 21: 150–280
9. Palit J, Clague RB. Wegener's granulomatosis presenting during first trimester of pregnancy. *Br J Rheumatol* 1990; 29: 389–390
10. Ford S. An unexpected complication: a case of ANCA vasculitis in pregnancy. In: *RACP Future Directions in Health Congress*, vol. 42. Brisbane, QLD: Internal Medicine Journal, 2012, 1–13, doi:10.1111/j.1445-5994.2012.02779.x
11. Dayoan ES, Dimen LL, Boylen CT. Successful treatment of Wegener's granulomatosis during pregnancy: a case report and review of the medical literature. *Chest* 1998; 113: 836–838
12. Milford CA, Bellini M. Wegener's granulomatosis arising in pregnancy. *J Laryngol Otol* 1986; 100: 475–476
13. Kim SY, Linton JM, Kolasinski SL. Successful treatment of new onset Wegener's granulomatosis with IVIG (intravenous immunoglobulin) during pregnancy: a case report. *Mod Rheumatol* 2008; 18: 177–180
14. Connolly JO, Lanham JG, Partridge MR. Fulminant pregnancy-related Churg-Strauss syndrome. *Br J Rheumatol* 1994; 33: 776–777
15. Bessias N, Moulakakis KG, Lioupis C et al. Wegener's granulomatosis presenting during pregnancy with acute limb ischemia. *J Vasc Surg* 2005; 42: 800–804
16. Corradi D, Maestri R, Facchetti F. Postpartum Churg-Strauss syndrome with severe cardiac involvement: description of a case and review of the literature. *Clin Rheum* 2009; 28: 739–743
17. Habib A, MacKay K, Abrons HL. Wegener's granulomatosis complicating pregnancy: presentation of two patients and review of the literature. *Clin Nephrol* 1996; 46: 332–336
18. Talbot SF, Main DM, Levinson AI. Wegener's granulomatosis: first report of a case with onset during pregnancy. *Arthritis Rheum* 1984; 27: 109–112
19. Cetinkaya R, Odabas A, Gursan N et al. Microscopic polyangiitis in a pregnant woman. *South Med J* 2002; 95: 1441–1443
20. Luisiri P, Lance NJ, Curran JJ. Wegener's granulomatosis in pregnancy. *Arthritis Rheum* 1997; 40: 1354–1360
21. Spencer CP, Partington CK, Soon R et al. Pregnancy complicated by Wegener's granulomatosis. *J Obstet Gynaecol* 1995; 15: 387–388
22. Fields CL, Ossorio MA, Roy TM et al. Wegener's granulomatosis complicated by pregnancy. A case report. *J Reprod Med* 1991; 36: 463–466
23. Devakumar VN, Castelino M, Chow SC et al. Wegener's granulomatosis in pregnancy: a case report and review of the medical literature. *BMJ Case Rep* 2010; 2010
24. Noack-Wiemers F, Rytter M, Rogalski C et al. ANCA-associated cutaneous vasculitis in pregnancy. *Aktuelle Derm* 2002; 28: 35–39
25. Sahni V, Agarwal SK, Singh NP et al. Successful pregnancy in untreated limited Wegener's granulomatosis. *Med J Malaysia* 2005; 60: 492–494
26. Priori R, Tomassini M, Magrini L et al. Churg-Strauss syndrome during pregnancy after steroid withdrawal. *Lancet* 1998; 352: 1599–1600
27. Ogasawara M, Kajjura S, Inagaki H et al. Successful pregnancy in a Churg-Strauss syndrome patient with a history of intrauterine fetal death. *Int Arch Allergy Immunol* 1995; 108: 200–202
28. Zafar U, Sany O, Velmurugan U et al. Wegener's granulomatosis in pregnancy: a multidisciplinary approach. *J Obstet Gynaecol* 2008; 28: 532–533
29. Ravindran V, Watts RA. Pulmonary haemorrhage in ANCA-associated vasculitis. *Rheum* 2010; 49: 1410–1412
30. Porres-Aguilar M, Figueroa-Casas JB, Porres-Muñoz M et al. A 38-year-old pregnant woman with hemoptysis and acute renal failure. *Respiration* 2011; 82: 60–64
31. Milne KL, Stanley KP, Temple RC et al. Microscopic polyangiitis: first report of a case with onset during pregnancy. *Nephrol Dial Transplant* 2004; 19: 234–237
32. Alfhaily F, Watts R, Leather A. Wegener's granulomatosis occurring de novo during pregnancy. *Clin Exp Rheumatol* 2009; 27: S86–S88
33. Kunjal R, Makary R, Poenariu A. Granulomatosis with polyangiitis presenting as pauci-immune crescentic glomerulonephritis in pregnancy. *Case Rep Nephrol* 2016; 2016: 1075659
34. Riaz H, Shamim Q, Makary RF et al. Pauci immune ANCA associated vasculitis de novo in pregnancy. In: *J Am Soc Nephrol*, 2013; 24: 624A
35. Fredi M, Lazzaroni MG, Tani C et al. Systemic vasculitis and pregnancy: a multicenter study on maternal and neonatal outcome of 65 prospectively followed pregnancies. *Autoimmun Rev* 2015; 14: 686–691
36. Clowse ME, Richeson RL, Pieper C et al. Vasculitis clinical research C: pregnancy outcomes among patients with vasculitis. *Arthritis Care Res (Hoboken)* 2013; 65: 1370–1374
37. Cao Y, Tian Z, Li W et al. Hemorrhagic complications associated with PR3-ANCA crescentic glomerulonephritis. *Ren Fail* 2015; 37: 745–750
38. André R, Cottin V, Saraux J-L et al. Central nervous system involvement in eosinophilic granulomatosis with polyangiitis (Churg-Strauss): report of 26 patients and review of the literature. *Autoimmun Rev* 2017; 16: 963–969
39. Kronbichler A, Jayne DR, Mayer G. Frequency, risk factors and prophylaxis of infection in ANCA-associated vasculitis. *Eur J Clin Invest* 2015; 45: 346–368
40. Fischer MJ. Chronic kidney disease and pregnancy: maternal and fetal outcomes. *Adv Chronic Kidney Dis* 2007; 14: 132–145
41. Tuin J, Sanders JS, de Joode AA et al. Pregnancy in women diagnosed with antineutrophil cytoplasmic antibody-associated vasculitis: outcome for the mother and the child. *Arthritis Care Res (Hoboken)* 2012; 64: 539–545
42. Pagnoux C, Le Guern V, Goffinet F et al. Pregnancies in systemic necrotizing vasculitides: report on 12 women and their 20 pregnancies. *Rheumatology (Oxford)* 2011; 50: 953–961
43. Jayne D, Rasmussen N, Andrassy K et al. A randomized trial of maintenance therapy for vasculitis associated with antineutrophil cytoplasmic autoantibodies. *N Engl J Med* 2003; 349: 36–44
44. Jayne DR, Chapel H, Adu D et al. Intravenous immunoglobulin for ANCA-associated systemic vasculitis with persistent disease activity. *QJM* 2000; 93: 433–439
45. Klemmer PJ, Chalermkulrat W, Reif MS et al. Plasmapheresis therapy for diffuse alveolar hemorrhage in patients with small-vessel vasculitis. *Am J Kidney Dis* 2003; 42: 1149–1153
46. Hasegawa M, Kawamura N, Murase M et al. Efficacy of granulocytapheresis and leukocytapheresis for the treatment of microscopic polyangiitis. *Ther Apher Dial* 2004; 8: 212–216
47. de Groot K, Harper L, Jayne DRW et al. Pulse versus daily oral cyclophosphamide for induction of remission in antineutrophil cytoplasmic antibody-associated vasculitis: a randomized trial. *Ann Intern Med* 2009; 150: 670–680
48. Chakravarty EF, Murray ER, Kelman A et al. Pregnancy outcomes after maternal exposure to rituximab. *Blood* 2011; 117: 1499–1506
49. Friedrichs B, Tiemann M, Salwender H et al. The effects of rituximab treatment during pregnancy on a neonate. *Haematologica* 2006; 91: 1426–1427
50. Hou S. A woman with GN presenting during pregnancy. *Clin J Am Soc Nephrol* 2013; 8: 1027–1033