

Right superior vena cava draining in the left atrium associated with tetralogy of Fallot and pulmonary atresia

Mohammed A Al-Biltagi, Amjad Kouatli¹, Faris Al-Mousily¹

Department of Pediatric, Faculty of Medicine, Tanta University, Tanta, Egypt, ¹Department of Cardiology, King Faisal Specialist Hospital and Research Center, Jeddah, Saudi Arabia

ABSTRACT

We report a case of an anomalous drainage of the right superior vena cava to the left atrium with intact atrial septum associated with Tetralogy of Fallot, pulmonary atresia, and major aortopulmonary collateral arteries.

Keywords: Anomalous superior vena cava, left atrium, pulmonary atresia, tetralogy of Fallot

INTRODUCTION

The anomalies of superior vena cava (SVC) are a part of a heterogeneous group of congenital malformations affecting the systemic venous return with a wide range from completely normal physiology to severe forms of right-to-left shunt requiring surgical treatment.^[1] These anomalies are usually diagnosed early in life, but it can be occasionally discovered in older age, presenting with cyanosis, cardiomegaly, dyspnea, cerebral emboli, or brain abscess.

CASE REPORT

A 3-month-old girl delivered at term by normal vaginal delivery was referred to our institution with persistent cyanosis and respiratory distress since 2 weeks. She has a sister who had surgical repair of tetralogy of Fallot (TOF). When admitted, she was mechanically ventilated; her vital signs showed oxygen saturation of 50% on FiO₂ of 100%; her blood pressure was 100/90 mmHg; and heart rate was 100-140 beats per min. Chest roentgenogram demonstrated cardiomegaly with central congestion and oligemic left lung with a band of atelectasis in the right upper lobe.

An echocardiographic study showed situs solitus, levocardia, d-looped ventricles, and normally related great arteries. It also showed TOF, pulmonary atresia (PA) with absent main pulmonary artery and hypoplastic (possibly confluent) pulmonary artery branches. There were major aortopulmonary collateral arteries (MAPCAs) supplying the hypoplastic pulmonary arteries. The inter-atrial septum was intact and the right superior vena cava (RSVC) was mildly dilated, draining into the left atrium (LA) [Figures 1 and 2]. The pulmonary veins were well seen and were normally draining to the LA, whereas the inferior vena cava and the hepatic veins drain into the right atrium. The LA, Left ventricle (LV), aortic root, and descending aorta were mildly dilated.

The LV systolic functions were good while right ventricle functions were fair to good.

A cardiac computed tomography (CT) confirmed that superior vena cava (SVC) drains into the roof of the LA without communication with the right side system, whereas inferior vena cava does appear to drain into the right atrium with intact inter-atrial septum. The pulmonary veins were well visualized and draining to the LA. The right ventricle was small, with minimal contrast seen within. There were at least two collateral vessels arising from the aorta. The inferior collateral supplied the right lower lobe pulmonary artery and the more superior collateral vessel appeared to connect to the pulmonary artery confluence which then bifurcated into two hypoplastic pulmonary arteries. There was suspicion of presence of secondary supply to the left main pulmonary artery, as the peripheral left pulmonary artery appears of better caliber [Figure 3; Video 1].

A diagnostic cardiac catheterization was performed. An

Video available on www.annalspc.com

Access this article online

Quick Response Code:



Website:

www.annalspc.com

DOI:

10.4103/0974-2069.107237

Address for correspondence: Prof. Mohammed Al-Biltagi, Department of Pediatric, Faculty of Medicine, Tanta University, Tanta, Egypt.

E-mail: mbelem@hotmail.com

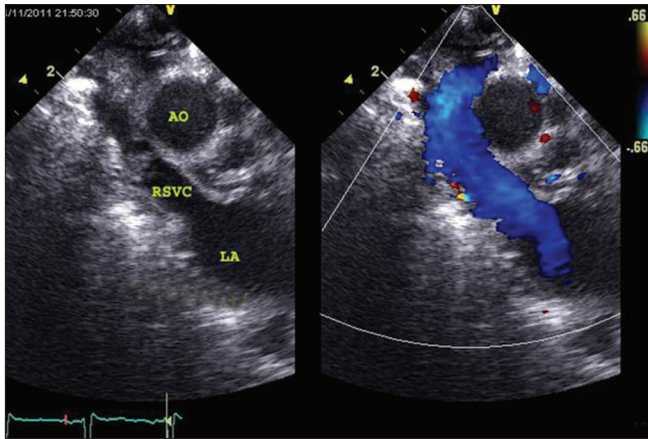


Figure 1: Suprasternal short axis view showed that the left innominate vein drain into the right superior vena cava which in turn drain to the posterior left atrium

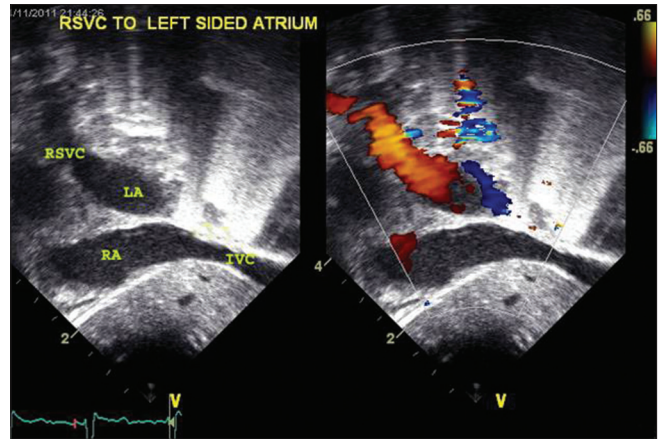


Figure 2: Subcostal inferior vena cava view showed the right superior vena cava which in turn drain to the posterior left atrium

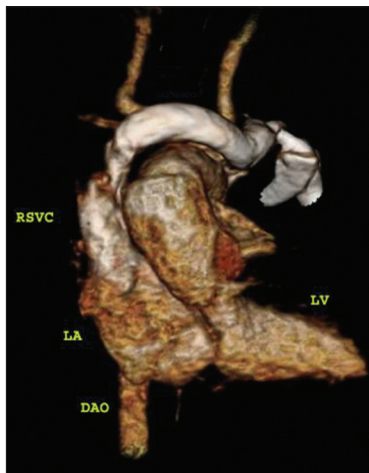

Figure 3: Multiplanar computerized reconstruction of cardiac computerized tomography angiogram showed the left innominate vein drain into the right superior vena cava which in turn drain to the posterior left atrium

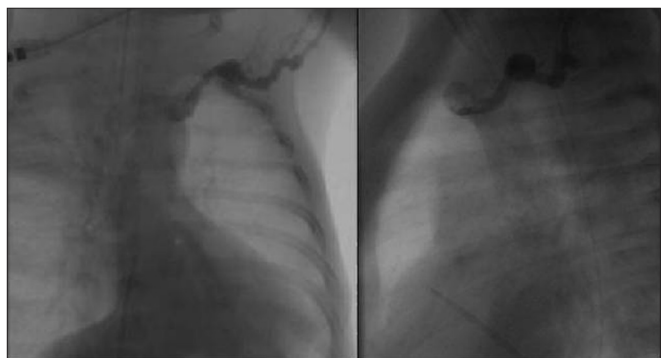

Figure 4: Antero-posterior and lateral views of angiograms; after dye injection in a peripheral vein in the left arm. It showed that the left innominate vein drain into the right superior vena cava which in turn drain to the posterior left atrium

injection in a peripheral vein in the left arm showed draining of the left innominate vein to the RSVC and consequently into the posterior LA [Figure 4]. It also delineated the presence of MAPCAs originating from the descending aorta and joining the hypoplastic pulmonary arterial tree. There were also two stenotic sites at the proximal parts of the pulmonary artery branches and normal pulmonary venous pattern

DISCUSSION

Left atrial drainage of the RSVC is a cyanotic congenital malformation that is usually associated with other anomalies of systemic or pulmonary venous drainage especially with partial anomalous pulmonary venous drainage with or without other anomalies.^[2] This abnormal drainage could be due to persistence of the cephalic portion of the right valve of the sinus venosus and leftward and cephalic displacement of the right horn

of sinus venosus.^[3] There were few case reports of left atrial drainage of the RSVC associated with TOF or PA.^[4] Echocardiography diagnosis of the RSVC draining into the LA may present a technical challenge. In our case, echocardiography was able to detect the anomaly with systematic examination. Contrast echocardiography can enhance the detection rate especially if suspected where opacification of the LA, left ventricle, and aorta without opacification of the right ventricle and right ventricular outflow tract with injection into both hands suggested drainage of the upper part of the body into the LA.^[3] Fetal echocardiography can detect this abnormal drainage as early as at 22-week gestation. It can reveal an enlarged SVC connecting abnormally with a mildly enlarged LA.^[5] Multi-detector contrast-enhanced chest CT scan can confirm the clinical and echocardiographic suspicions of anomalous drainage of the RSVC.^[6] Presence of abnormal drainage of RSVC to the LA should be suspected and considered in the differential diagnosis in infants who presented with cyanosis and significant systemic arterial desaturation and no other abnormal cardiac findings. Surgical correction is indicated to prevent complications of cyanosis and the risk of systemic embolization.^[1,4,7]

REFERENCES

1. Oppido G, Pace Napoleone C, Turci S, Giardini A, Formigari R, Angeli E, *et al.* Right superior vena cava draining in the left atrium: Anatomical, embryological, and surgical considerations. *Ann Thorac Surg* 2006;81:2313-5.
2. Hong SN, Nayar A, Srichai MB, Morgan JA, Meyer D, Katz E. A case of an anomalous superior vena cava with anomalous pulmonary veins-when two wrongs do not make a right. *Echocardiography* 2011;28:E39-41.
3. Truman AT, Rao PS, Kulangara RJ. Use of contrast echocardiography in diagnosis of anomalous connection of right superior vena cava to left atrium. *Br Heart J* 1980;44:718-23.
4. Van Praagh S, Geva T, Lock JE, Nido PJ, Vance MS, Van Praagh R. Batrial or left atrial drainage of the right superior vena cava: Anatomic, morphogenetic, and surgical considerations—report of three new cases and literature review. *Pediatr Cardiol.* 2003;24:350-63.
5. Vassallo M, Pascotto M, Pisacane C, Santoro G, Paladini D, Russo MG, *et al.* Right superior vena cava draining into the left atrium: Prenatal diagnosis and postnatal management. *Ultrasound Obstet Gynecol* 2006;27:445-8.
6. Calcagni G, Batisse A, Vouhé P, Sidi D, Bonnet D, Ou P. Right superior vena cava draining into the left atrium. *Pediatr Radiol* 2008;38:912-4.
7. Sajja LR, Koneti NR, Mannam G, Sundaram MK. Correction of anomalous drainage of right superior vena cava to left atrium. *Asian Cardiovasc Thorac Ann* 2008;16:e32-4.

How to cite this article: Al-Biltagi MA, Kouatli A, Al-Mousily F. Right superior vena cava draining in the left atrium associated with tetralogy of Fallot and pulmonary atresia. *Ann Pediatr Card* 2013;6:65-7.

Source of Support: Nil, **Conflict of Interest:** None declared