



OPEN ACCESS

CASE REPORT

Malignant deep brain stimulator withdrawal syndrome

Jehad Azar,¹ Hila Elinav,² Rifaat Safadi,² Mona Soliman¹

¹Internal Medicine, St. Vincent Charity Medical Center, Cleveland, Ohio, USA
²Internal Medicine, Hadassah Medical Center, Jerusalem, Israel

Correspondence to

Dr Jehad Azar,
 jehad.azar@gmail.com

Accepted 3 May 2019

SUMMARY

Parkinsonism-hyperpyrexia syndrome (PHS) is a neurologic potentially fatal emergency that mimics neuroleptic malignant syndrome. It commonly presents as systemic inflammatory response syndrome, acute onset worsening of muscular rigidity, autonomic instability, hyperpyrexia, confusion, diaphoresis and high creatine phosphokinase. The most common trigger for PHS is reduction or withdrawal of anti-Parkinson's medications, especially levodopa. It was also reported in a few cases following deep brain stimulation of the subthalamic nucleus surgery shortly after anti-Parkinson's medications were discontinued. Rare causes of PHS include deep brain stimulator (DBS) malfunction due to battery depletion. To the best of our knowledge, PHS following DBS battery depletion was reported only in three occasions. Here, we report a case of PHS due to DBS battery depletion presented as sepsis and was successfully treated with the administration of dopamine agonists, intravenous fluids and changing the DBS battery.

BACKGROUND

High-frequency deep brain stimulation (DBS) of the subthalamic nucleus (STN) is a well-established modality for treating Parkinson's disease (PD) for more than two decades. Our knowledge about the pathophysiology of PD and the clinical applications for STN DBS is rapidly evolving. Nevertheless, the exact mechanism of action of STN DBS remains an enigma.¹ The common hypothesis is that DBS acts through modulation or disruption of the pattern of neural signalling within targeted regions in the brain: the STN and the internal segment of globus pallidus.^{2,3} The long-term efficacy and safety of DBS are promising, as reported in many recent publications.⁴ Parkinsonism-hyperpyrexia syndrome (PHS) is a life-threatening disorder, commonly reported following withdrawal of anti-Parkinson medications. More rarely, PHS is concomitant with DBS malfunction. In this case report, we describe a novel syndrome of PHS due to DBS battery depletion, which presented as sepsis in our hospital in May 2014.

CASE PRESENTATION

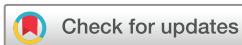A 67-year-old woman, previous medical history significant for Hashimoto hypothyroidism, essential hypertension, dementia, major depression and diabetes mellitus. She was diagnosed with PD in 1991. Over the years, her treatment included

levodopa/carbidopa and pramipexole, with poor control of her symptoms. In 2007, bilateral STN DBS was implanted, resulting in significant improvement of tremors and motor deficit. Her symptoms were well controlled for the following 7 years; however, the DBS battery was never replaced.

The patient presented to the emergency room (ER) in May 2014 with a 3-day history of high-grade fever (up to 39°C) (figure 1), altered mental status, poor oral intake and low urinary output. On admission, she was febrile 38.5°C, tachycardia at 110 beats/min with elevated blood pressure 180/77 mm Hg; her respiratory rate was 18 breaths/min, with pulse oximetry of 90% in room air. Her physical examination showed a somnolent, diaphoretic and severely dehydrated patient, with mild respiratory distress; neurologic examination demonstrated somnolence with lack of response to painful stimuli. Her breath sounds were diminished in the lung bases. The rest of the physical examination was unremarkable.

Laboratory tests were remarkable for acute prerenal failure with creatinine 123 µmol/L, hypernatraemia 157 mmol/L, elevated creatine kinase at 1015 U/L, leucocytosis 12 600/µL with a C reactive protein (CRP) of 1.6 mg/dL. A chest X-ray demonstrated atelectasis in the lung bases. Lumbar puncture ruled out central nervous system (CNS) infection, with normal cell count and negative viral PCR and cerebrospinal fluids (CSF) cultures. After blood, sputum, urinary and stool cultures were obtained, the patient was started on an antibiotic for possible pulmonary infection. Due to continued fevers and decreased consciousness, she underwent a whole-body CT that failed to localise a possible source of infection. Serology for cytomegalovirus (CMV) and Epstein-Barr Virus (EBV), respiratory viral swab and all other cultures came back negative. The patient's Thyroid Stimulating Hormone (TSH), calcium, ammonia, liver enzymes and vitamin B₁₂ levels were all within normal limits. She completed a course of antibiotics and thiamine with no improvement.

Due to lack of a similar reported cases in the literature, unfamiliarity with this presentation among the medical team, and given no history of neuroleptics administration or withdrawal of dopaminergic medications prior to the onset of symptoms. It was not until day 9 postadmission that the diagnosis of PHS was made, after the patient continued to have non-resolving high fever, severe muscular rigidity, altered mental status, autonomic instability (hypertension up to 180/90 and tachycardia



© BMJ Publishing Group Limited 2019. Re-use permitted under CC BY-NC. No commercial re-use. See rights and permissions. Published by BMJ.

To cite: Azar J, Elinav H, Safadi R, et al. *BMJ Case Rep* 2019;**12**:e229122. doi:10.1136/bcr-2018-229122

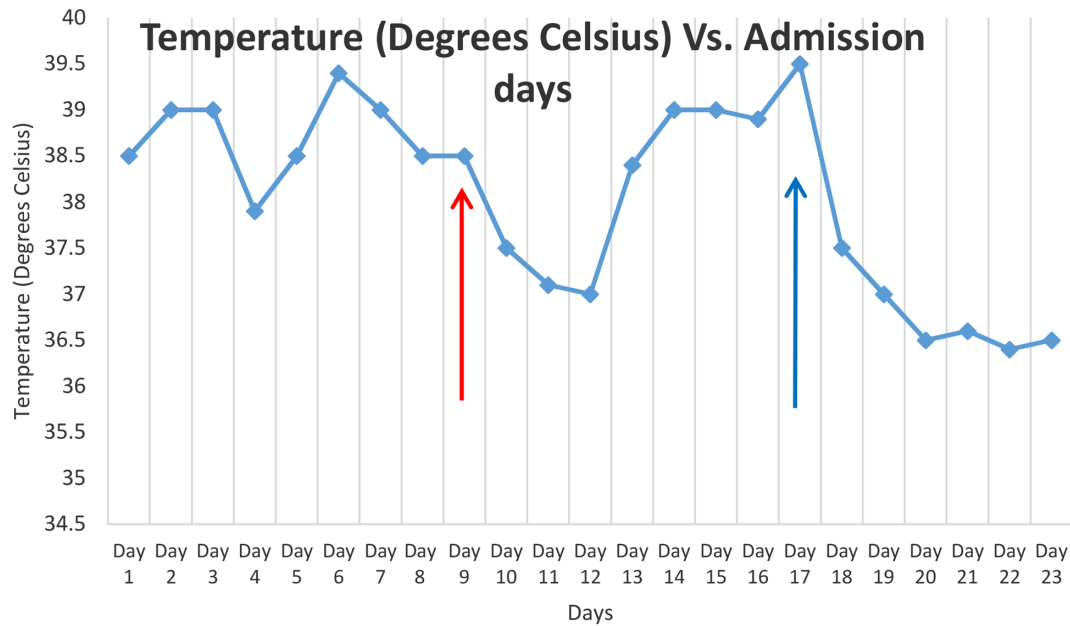


Figure 1 Fever chart in degrees Celsius. Day 1 is the first day of admission. Day 9 (red arrow) represents time of increasing her levodopa dose. Day 17 (blue arrow) is when her IPG Impulse Generator was replaced. On day 23, she was sent to rehabilitation.

between 110 and 125 beats/min) and elevated creatine kinase (CK) to 1615 U/L. Subsequently, the patient was treated with intravenous fluids, acetaminophen and ice packs; levodopa dose was tripled, with no clinical improvement. Yet, transient resolution of fever was noted before it spiked again 2 days later (figure 1). Considering the unsatisfactory results of conservative management, lack of clinical improvement and given that the estimated DBS battery life is between 3 and 5 years, DBS withdrawal syndrome due to battery depletion was suspected. However, the Implantable Pulse Generator (IPG) replacement was not accomplished until day 17 of admission due to lack of similar reported cases and unavailability of supportive evidences in the literature. A few hours later following successful IPG replacement, clinical improvement was documented. After 1 day post IPG replacement, there was no more fever (figure 1) or autonomic instability; CK, white blood cell (WBC) count, creatinine level and CRP all normalised. The patient's rigidity and mental status improved to full recovery until discharge.

OUTCOME AND FOLLOW-UP

During the course of admission, the patient continued to have non-resolving high fever, altered mental status and autonomic instability. CK level increased to 1615 U/L. After a delayed diagnosis of malignant DBS withdrawal syndrome due to battery depletion was made, she underwent successful IPG replacement with subsequent dramatic clinical improvement, as documented by rapid resolution of fever (figure 1), normalisation of CK, WBC count, creatinine and CRP levels. Full recovery with normal mental status was documented on discharge.

DISCUSSION

PHS is a medical emergency described in patients with PD. This syndrome was first shown in a PD patient in 1981 after discontinuation of his anti-Parkinson's medications even though no neuroleptics were prescribed.⁵ It is not uncommon to misdiagnose PHS because of the overlapping symptoms with advanced PD and sepsis. The classic presentation include muscle rigidity, tremors, rapidly evolving fever, autonomic instability,

reduced mental status, diaphoresis, elevated CRP, high CK due to rhabdomyolysis and increase in WBC counts.⁶ The exact pathogenesis behind the development of PHS remains unclear. A growing body of evidence suggests acute reduction of neurotransmission in the hypothalamus, nigrostriatal system and mesocortical dopaminergic system contributing to the development of PHS.⁷ Complications of PHS include aspiration pneumonia, renal failure due to rhabdomyolysis, disseminated intravascular coagulation and venous thromboembolism. In addition, patients may develop a potentially fatal CNS; hypodopaminergic crisis within hours to days. Supportive management and reinitiation of dopaminergic medications are the core stones of treatment.^{7,8}

The most common trigger for PHS is withdrawal of anti-Parkinson's medications, especially levodopa. Due to ultra-short half-life of levodopa, sudden withdrawal of dopaminergic medications during the perioperative period may cause PHS.⁹⁻¹⁵ Additional triggers reported in the PD patient include prescription of neuroleptic medication, infection, dehydration and excessive hot weather.^{16,17}

Cases of PHS reportedly associated with acute DBS withdrawal are summarised in table 1.

Chyong-yy *et al*¹⁸ reported a patient with a history of PD for 16 years, who developed PHS during preoperative assessment for planned DBS battery replacement, which was consequently postponed on account of suspected sepsis. Following significant deterioration despite broad-spectrum antibiotic administration, and the failure to identify a source of sepsis, PHS was suspected. Treatment of dantrolene and bromocriptine was commenced, as well as intense supportive care, and the dose of dopaminergic medications was increased. As a result of the failure of conservative management, the DBS battery was replaced with subsequent recovery. Artusi *et al*¹⁹ described a 63-year-old man with long-standing advanced PD with suspected PHS due to DBS battery depletion, showing gradual clinical and laboratory improvement after IPG replacement. Neuneier *et al*²⁰ reported a case of fatal PHS in a patient with advanced PD, who developed withdrawal syndrome a few days after battery depletion. IPG replacement was postponed in this

Table 1 Reported cases with DBS withdrawal syndrome (all patients had subthalamic nucleus DBS)

Report	A/S/YOD	PDD/DBSD	Treatment	Laboratory results	Cause of DBS failure	DBS restoration	Outcome
Chyong-jy <i>et al</i> ¹⁸	69/M/2017	16/9	↑Levodopa	↑CK (1250 IU/L)	Battery depletion	Battery was replaced	Recovery
			Conservative	↑WBC (12.1 x 10 ⁹ /L)			
			Bromocriptine				
			Dantrolene				
Artusi <i>et al</i> ¹⁹	63/M/2015	18/5	↑Levodopa	↑CK (2820 U/L)	Battery depletion	IPG was reimplanted	Recovery
			Conservative	↑CRP (50.1 mg/L)			
				↑WBC (10.0 x 10 ⁹ /L)			
Reuter <i>et al</i> ²²	75/M/2014	19/9	↑Levodopa	–	IPG infection	IPG was not reimplanted	Death
			IV Amantadine				
			Conservative				
Reuter <i>et al</i> ²²	74/M/2014	24/10	↑Levodopa	–	IPG infection	IPG was not reimplanted	Death
			Intravenous amantadine				
			Conservative				
Reuter <i>et al</i> ²²	52/M/2013	20/8	↑Levodopa	–	IPG infection	IPG was reimplanted	Recovery
			Intravenous amantadine				
			Apomorphine				
Neuneier <i>et al</i> ²⁰	77/M/2013	18/5	↑Levodopa	↑CK (1642 U/L)	Battery depletion	Late IPG reimplantation	Death
			Intravenous amantadine	↑CRP (50 mg/L)			
			Conservative				
Kadowaki <i>et al</i> ²¹	60/M/–	17/8	Conservative	↑CK (1878 U/L)	DBS switched off	DBS switched on	Recovery
				↑CRP (10.3 mg/L)			
				↑WBC (12.6 x 10 ⁹ /L)			
Our case	67/F/2014	23/7	↑Levodopa	↑CK (1615 U/L)	Battery depletion	Battery was replaced	Recovery
			Pramipexole	↑CRP (10.6 mg/L)			
			Conservative	↑WBC (16.5 x 10 ⁹ /L)			

Conservative treatment refers to intravenous fluids +/- (antipyretic, antibiotics, cooling measures, sedatives, eg, benzodiazepines).

A, age; CK creatine kinase; CRP, C reactive protein; DBS, deep brain stimulator; DBSD, DBS duration at PHS onset; PDD, Parkinson's disease duration; PHS, Parkinson-hyperpyrexia syndrome; S, sex; WBC, white blood cell; YOD, year of diagnosis.

case, due to risk of bleeding on account of concomitant antiplatelet administration, resulting in the death of the patient with disseminated intravascular coagulation (DIC) and multiorgan failure. Kadowaki *et al*²¹ described a PD patient with recurrent PHS following several attempts of discontinuing STN-DBS to improve psychiatric complications (manic symptoms). Reuter *et al*²² published three cases with PHS after the removal of DBS implant, due to hardware-related infection. Fatal outcomes were reported in patients who had no IPG replacement despite an increase in the dose of levodopa. In our reported case, we came to the conclusion on account of the knowledge that battery efficiency depletes within a specific time frame and replacement is advised regularly, as is the exclusion of possible diagnosis, which would explain presenting symptoms. PHS was suspected despite a lack of previous reported cases. Initial treatment involved the increase of levodopa dose, administration of intravenous fluids, as well as pramipexole, with no clinical improvement in a patient with advanced PD and long-term STN stimulation. It was only after IPG replacement that the patient began to show signs of recovery.

The exact mechanism by which DBS influences neurotransmission in the brain has yet to be determined. As seen in other reported cases, as well as in our case, dopaminergic transmission may have been enhanced during the patient's STN DBS stimulation; therefore, abrupt cessation of DBS results in a rebound effect with PHS development. In this scenario, patients

were not responsive to conservative treatment using intravenous fluids and an increase in the dosage of dopaminergic medications. On the contrary, patients responded to the restoration of STN stimulation after replacing the IPG, suggesting possible different mechanisms of action in the nigral pathways for the DBS versus oral dopaminergics. As a result, sudden withdrawal of DBS, independent of changes in dopaminergic therapy, may induce PHS, deeming dopaminergic therapy in these cases ineffective. Possible risk factors for life-threatening DBS withdrawal syndrome may include long-standing PD (mean is 19.3 years, table 1), prolonged DBS stimulation (mean is 7.6 years, table 1)

Learning points

- ▶ Malignant deep brain stimulation (DBS) withdrawal syndrome is a rare disease, which happens exclusively in patients with advanced Parkinson's disease as a result of abrupt cession of DBS activity.
- ▶ It has a hypothesised different mechanism of action, in comparison with dopaminergic medication.
- ▶ Treatment by augmenting the dopaminergic medications should be considered temporary, while immediate DBS restoration is considered the definitive treatment, preventing an otherwise fatal outcome.

and old age (mean is 67.1 years, table 1). An optimal prognosis can be achieved with high index of suspicion and immediate DBS restoration, while delayed restoration or failure to restore DBS activity can result in fatal outcomes.

Acknowledgements I would like to express my deep and sincere gratitude to my research supervisors; Professor Arie Ben Yehuda, Chairman of Internal Medicine at Hadassah Medical Center, and Dr Keyvan Ravakhah, Chairman of Internal Medicine at St. Vincent Charity Medical Center. Both have provided insight and expertise that greatly assisted the research.

Contributors JA is the first author, HE and RS were involved in the patient care and helped in reviewing the case. MS had reviewed the case report.

Funding The authors have not declared a specific grant for this research from any funding agency in the public, commercial or not-for-profit sectors.

Competing interests None declared.

Patient consent for publication Obtained.

Provenance and peer review Not commissioned; externally peer reviewed.

Open access This is an open access article distributed in accordance with the Creative Commons Attribution Non Commercial (CC BY-NC 4.0) license, which permits others to distribute, remix, adapt, build upon this work non-commercially, and license their derivative works on different terms, provided the original work is properly cited and the use is non-commercial. See: <http://creativecommons.org/licenses/by-nc/4.0/>

REFERENCES

- Benabid AL, Chabardes S, Mitrofanis J, *et al.* Deep brain stimulation of the subthalamic nucleus for the treatment of Parkinson's disease. *Lancet Neurol* 2009;8:67–81.
- Bronstein JM, Tagliati M, Alterman RL, *et al.* Deep brain stimulation for Parkinson disease: an expert consensus and review of key issues. *Arch Neurol* 2011;68:165.
- Kleiner-Fisman G, Herzog J, Fisman DN, *et al.* Subthalamic nucleus deep brain stimulation: summary and meta-analysis of outcomes. *Mov Disord* 2006;21(Suppl 14):S290–S304.
- Moro E, Lozano AM, Pollak P, *et al.* Long-term results of a multicenter study on subthalamic and pallidal stimulation in Parkinson's disease. *Mov Disord* 2010;25:578–86.
- Toru M, Matsuda O, Makiguchi K, *et al.* Neuroleptic malignant syndrome-like state following a withdrawal of antiparkinsonian drugs. *J Nerv Ment Dis* 1981;169:324–7.
- Newman EJ, Gossset DG, Kennedy PG. The parkinsonism-hyperpyrexia syndrome. *Neurocrit Care* 2009;10:136–40.
- Mizuno Y, Takubo H, Mizuta E, *et al.* Malignant syndrome in Parkinson's disease: concept and review of the literature. *Parkinsonism Relat Disord* 2003;9(Suppl 1):S3–S9.
- Granner MA, Wooten GF. Neuroleptic malignant syndrome or parkinsonism hyperpyrexia syndrome. *Semin Neurol* 1991;11:228–35.
- Urasaki E, Fukudome T, Hirose M, *et al.* Neuroleptic malignant syndrome (parkinsonism-hyperpyrexia syndrome) after deep brain stimulation of the subthalamic nucleus. *J Clin Neurosci* 2013;20:740–1.
- Govindappa ST, Abbas MM, Hosurkar G, *et al.* Parkinsonism Hyperpyrexia Syndrome following Deep Brain Stimulation. *Parkinsonism Relat Disord* 2015;21:1284–5.
- Akçakaya MO, Akçakaya NH, Kasımcıan MÖ, *et al.* Life-threatening parkinsonism-hyperpyrexia syndrome following bilateral deep brain stimulation of the subthalamic nucleus. *Neuro Neurochir Pol* 2018;52:289–92.
- Kim JH, Kwon TH, Koh SB, *et al.* Parkinsonism–hyperpyrexia syndrome after deep brain stimulation surgery: case report. *Neurosurgery* 2010;66:E1029.
- Themistocleous MS, Boviatisis EJ, Stavrinou LC, *et al.* Malignant neuroleptic syndrome following deep brain stimulation surgery: a case report. *J Med Case Rep* 2011;5:255.
- Linazasoro G, Van Blercom N, Castro A, *et al.* Subthalamic deep brain stimulation masking possible malignant syndrome in Parkinson disease. *Neurology* 2004;63:589–90.
- Factor SA. Fatal parkinsonism–hyperpyrexia syndrome in a Parkinson's disease while actively treated with deep brain stimulation. *Mov Disord* 2007;22:147–8.
- Douglas A, Morris J. It was not just a heatwave! Neuroleptic malignant-like syndrome in a patient with Parkinson's disease. *Age Ageing* 2006;35:640–1.
- Gaig C, Marti MJ, Tolosa E, *et al.* Parkinsonism-hyperpyrexia syndrome not related to antiparkinsonian treatment withdrawal during the 2003 summer heat wave. *J Neurol* 2005;252:1116–9.
- Chyong-jy Joyce LIU, Crnkovic A, Dalfino J, *et al.* Whether to proceed with Deep Brain Stimulator Battery Change in a Patient With Signs of Potential Sepsis and Parkinson Hyperpyrexia Syndrome: A Case Report. *A&A Case Reports* 2017;8:187–91.
- Artusi CA, Merola A, Espay AJ, *et al.* Parkinsonism-hyperpyrexia syndrome and deep brain stimulation. *J Neurol* 2015;262:2780–2.
- Neuneier J, Barbe MT, Dohmen C, *et al.* Malignant deep brain stimulation-withdrawal syndrome in a patient with Parkinson's disease. *Mov Disord* 2013;28:1640–1.
- Kadowaki T, Hashimoto K, Suzuki K, *et al.* Case report: recurrent parkinsonism–hyperpyrexia syndrome following discontinuation of subthalamic deep brain stimulation. *Mov Disord* 2011;26:1561–2.
- Reuter S, Deuschl G, Falk D, *et al.* Uncoupling of dopaminergic and subthalamic stimulation: life-threatening DBS withdrawal syndrome. *Mov Disord* 2015;17.

Copyright 2019 BMJ Publishing Group. All rights reserved. For permission to reuse any of this content visit <https://www.bmj.com/company/products-services/rights-and-licensing/permissions/> BMJ Case Report Fellows may re-use this article for personal use and teaching without any further permission.

Become a Fellow of BMJ Case Reports today and you can:

- ▶ Submit as many cases as you like
- ▶ Enjoy fast sympathetic peer review and rapid publication of accepted articles
- ▶ Access all the published articles
- ▶ Re-use any of the published material for personal use and teaching without further permission

For information on Institutional Fellowships contact consortiasales@bmjgroup.com

Visit casereports.bmj.com for more articles like this and to become a Fellow