

Neural fibrolipoma in pharyngeal mucosal space: A rare occurrence

Nishith Kumar, MK Mittal, Mukul Sinha, BB Thukral

Department of Radio-Diagnosis, VM Medical College and Safdarjung Hospital, New Delhi, India

Correspondence: Dr. M.K. Mittal, D-II/222, West Kidwai Nagar, New Delhi - 110023, India. E-mail: drmkmittal@rediffmail.com

Abstract

Neural fibrolipoma is a rare lesion presenting in early childhood, as a slow-growing fusiform swelling of a nerve, usually in the forearm or wrist (median nerve), associated with symptoms of compression neuropathy. There are only few case reports of neural fibrolipoma in neck and no such case has been reported in pharyngeal mucosal space.

Key words: Fibroma; head and neck neoplasm; lipoma

Introduction

Neural fibrolipoma is a benign neoplasm of nerves, resulting from anomalous growth of fibro adipose tissue of the nerve sheath. Most of these lesions usually occur in the forearm or wrist (median nerve), presenting as a slow-growing fusiform swelling of a nerve, associated with symptoms of compression neuropathy.

We hereby report a rare case of neural fibrolipoma in the pharyngeal mucosal space in a pediatric patient, emphasizing the imaging features that can aid in differentiating from other lipomatous lesions.

Case Report

A 12-year-old male child presented to the outpatient department of otorhinolaryngology with history of mass in the oral cavity since birth. The child complained of difficulty in breathing and swallowing for last 2 years. On physical examination, there was a soft lobulated non-tender mass with smooth margins and overlying congested mucosa and surface nodularity in the right side of oral cavity and oropharynx,

displacing the soft palate to the left. Indirect laryngoscopic examination was not feasible, and on direct laryngoscopy, the lesion was seen extending into the hypopharynx and the right pyriform sinus. The epiglottis, pre-epiglottis space, and the left pyriform sinus appeared normal.

Plain radiograph, soft tissue neck showed a broad-based radio-opacity arising from the posterior pharyngeal wall, extending from the C4 to C6 cervical vertebral level, compressing the airway anteriorly. The underlying bones appeared normal with no evidence of widening of the prevertebral soft tissue.

Contrast-enhanced CT scan of the neck revealed a well-defined (6 cm × 2 cm), hypodense mass lesion with predominant fat attenuation (mean attenuation: -50 HU) with linear intersecting soft tissue attenuation areas showing minimal contrast enhancement in the right pharyngeal wall, extending from the nasopharynx up to the level of hypopharynx [Figure 1A and B]. Mass effect was noted in the form of compression of airways with displacement of soft palate and the overlying enhancing mucosa to the left, with lateral displacement of prestyloid fat plane confirming the location of the lesion in the right pharyngeal mucosal space. Bilateral carotid-jugular vessels were normal in caliber and position.

On MRI examination, the mass in the right pharyngeal mucosal space was hyperintense on T1 and T2 sequences with few linear areas of hypointensity [Figure 2A and B] with homogenous suppression of the hyperintense areas of mass on fat-suppressed STIR sequence [Figure 2C].

Access this article online

Quick Response Code:



Website:
www.ijri.org

DOI:
10.4103/0971-3026.111491

Based on the clinical and imaging findings, a diagnosis of a fat containing tumor in right pharyngeal mucosal space was made with possibilities of lipoma, fibrolipoma and its variant, low-grade liposarcoma, and teratomas.

A 6.5 × 3 cm, ovoid smoothly margined firm mass with surface nodularity was excised after splitting the oropharyngeal mucosa] and the location of lesion in pharyngeal mucosa was confirmed. The postoperative period was uneventful and child was started on oral feeding on 3rd postoperative day.

Histopathologic examination revealed a lipomatous lesion with intersecting spindle cells [Figure 3A and B], which was analyzed by immunohistochemistry. The given pathological specimen was positive for S-100, confirming the neural

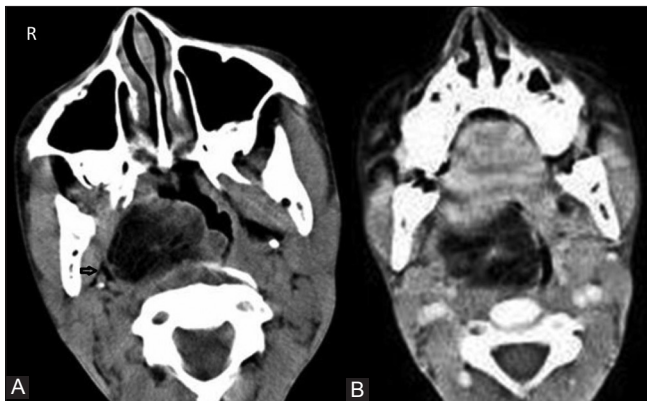


Figure 1 (A and B): Axial Plain and Contrast CT image of the neck shows hypodense mass lesion (predominantly fat attenuation) in right pharyngeal wall with displacement of prestyloid fat plane (black arrow). Post contrast image shows linear enhancing bands

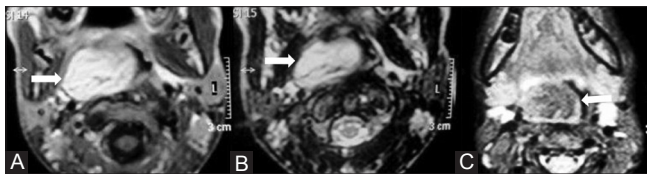


Figure 2 (A-C): Axial MRI images of neck shows T1 and T2 hyperintense mass lesion in the right pharyngeal mucosal space (white arrows) (A, B) with suppression of hyperintense signal in the fat-sat sequence (C) confirming the fatty nature of the lesion

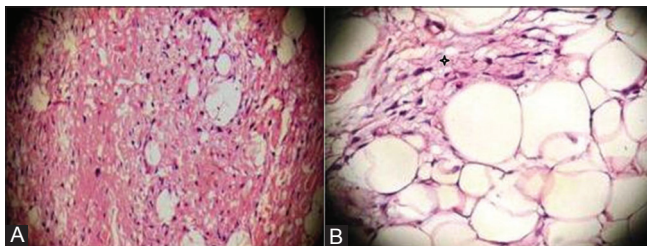


Figure 3 (A, B): Photomicrograph of the histopathology specimen (Haematoxylin and eosin; original and 200x magnification). The lesion is composed of uniform appearing adipocytes with strands of spindle cells (black star)

origin, and the final diagnosis of neural fibrolipoma in right pharyngeal mucosal space was established.

Discussion

Neck masses are a common indication for cross-sectional imaging, the various etiologies for which are determined by the location of the lesion. Thus, spatial localization of lesion is the most important aspect in the imaging of neck masses. The pattern of displacement of the fascial fat planes and the major neurovascular structures of neck provide important clues in localization of the epicenter of mass. Furthermore, the differential diagnosis is narrowed on the knowledge of the content of the space and the specific imaging features.

The common lesions of the pharyngeal mucosal space in pediatric population are lymphomas, minor salivary gland tumors, and Thornwaldt's cyst. Rare lesions include lipomas, hemangiomas, and mucosal retention cyst.

13% of all lipomatous tumors occur in head and neck region, but most of them are superficial in location and tumors in deeper locations are unusual.^[1] The common fat containing lesions include lipoma/liposarcoma, teratomas, and lipoma variants. Though a lipomatous origin of the mass can be ascertained on cross-sectional imaging, often it is not possible to differentiate these lesions radiologically and histopathology/immunohistochemistry is required to make the final diagnosis as it was in our case.

Neural fibrolipoma is a benign neoplasm of nerves, resulting from anomalous growth of fibro adipose tissue of the nerve sheath; however, the histogenesis of the fibro-fatty tissue is disputed. It may be related to hypertrophy of mature fat and fibroblasts in the epineurium of nerve. Mason initially described neural fibrolipoma of hand in the English literature in 1953. Additional names for this lesion have included fibrolipomatous hamartoma of nerve, perineural lipoma, fatty infiltration of the nerve, and intraneural lipoma.^[2,3]

It affects the median nerve most commonly, with a slow-growing tumor at the volar aspect of the wrist, with features of compressive neuropathy as the usual presenting features.^[3] Besides the median nerve, the tumor can affect the ulnar nerve, radial nerve, and brachial plexus. In 27-67% of cases, neural fibrolipoma is associated with macrodactyly, which is referred to as macrodystrophia lipomatosa.^[3,4] This entity usually involves the second and third digits of the hand or foot, but multiple digits may be affected. Besides the extremities, occasional cases of neural fibrolipoma have been reported in the head and neck region.^[5,6] To the best of our knowledge, there has been no case of neural fibrolipoma reported in the pharyngeal mucosal space.

On imaging, features suggestive of neural fibrolipoma

in neck include lobulated mass lesion with predominant negative attenuation with focal areas of soft tissue component corresponding to the neural element.^[5] Although sonographic evaluation of deep neck mass is not feasible, the characteristic appearance of superficial neurofibrolipoma is of hypoechoic and hyperechoic bands (cable-like appearance).^[7] The pathognomonic MRI appearance is of longitudinally oriented cylindrical foci (about 3 mm in diameter) of low signal intensity surrounded by fatty signal intensity representing nerve fascicles.^[7]

To conclude, the diagnosis of neural fibrolipoma can be suggested on the basis of imaging features with appropriate localization in neck done by identification of the pattern of displacement of adjoining structures.

References

1. Abdullah BJ, Liam CK, Kaur H, Mathew KM. Parapharyngeal space lipoma causing sleep apnoea. *Br J Radiol* 1997;70:1063-5.
2. Mason ML. Proceedings of American Society for Surgery of the Hand: Presentation of cases. *J Bone Joint Surg Am* 1953;35:273-5.
3. Silverman TA, Enzinger FM. Fibrolipomatous hamartoma of nerve: A clinicopathologic analysis of 26 cases. *Am J Surg Pathol* 1985;9:7-14.
4. Amadio PC, Reiman HM, Dobyns JH. Lipofibromatous hamartoma of nerve. *J Hand Surg* 1988;13:67-75.
5. Thornton MA, O'Leary G, Fitzgibbon J. Neural fibrolipoma: An unusual case. *J Laryngol Otol* 2000;114:231-2.
6. Taori K, Gyanchandani M, Rohatgi S, Ghonge N, Solanke R. Cervico-Mediastinal Neural Fibrolipoma: Spiral Ct Features. *Indian J Radiol Imaging* 2005;15:535-6.
7. Toms AP, Anastakis D, Bleakney R, Marshall T. Lipofibromatous hamartoma of the upper extremity: A review of the radiologic findings for 15 patients. *AJR Am J Roentgenol* 2006;186:805-11.

Cite this article as: Kumar N, Mittal MK, Sinha M, Thukral BB. Neural fibrolipoma in pharyngeal mucosal space: A rare occurrence. *Indian J Radiol Imaging* 2012;22:358-60.

Source of Support: Nil, **Conflict of Interest:** No.