



## Using ketamine in a patient with a near-occlusion tracheal tumor undergoing tracheal resection and reconstruction: A case report

Xiao-Han Xu, Hui Gao, Xing-Ming Chen, Hao-Bo Ma, Yu-Guang Huang

**Specialty type:** Anesthesiology

**Provenance and peer review:**

Unsolicited article; Externally peer reviewed.

**Peer-review model:** Single blind

**Peer-review report's scientific quality classification**

Grade A (Excellent): A

Grade B (Very good): B

Grade C (Good): 0

Grade D (Fair): 0

Grade E (Poor): 0

**P-Reviewer:** Cordunianu AGV, Romania; Ferreira GSA, Brazil

**Received:** April 18, 2022

**Peer-review started:** April 18, 2022

**First decision:** May 12, 2022

**Revised:** May 25, 2022

**Accepted:** July 5, 2022

**Article in press:** July 5, 2022

**Published online:** August 16, 2022



**Xiao-Han Xu, Hui Gao, Yu-Guang Huang,** Department of Anesthesiology, Peking Union Medical College Hospital, Beijing 100730, China

**Xing-Ming Chen,** Department of Otolaryngology-Head and Neck Surgery, Peking Union Medical College Hospital, Beijing 100730, China

**Hao-Bo Ma,** Department of Anesthesia, Critical Care and Pain Medicine, Beth Israel Deaconess Medical Center, Boston, MA 02215, United States

**Corresponding author:** Hui Gao, MD, Doctor, Department of Anesthesiology, Peking Union Medical College Hospital, No. 1 Shuaifuyuan, Dongcheng District, Beijing 100730, China. [hellohigh@163.com](mailto:hellohigh@163.com)

### Abstract

#### BACKGROUND

Tracheal tumors may cause airway obstruction and pose a significant risk to ventilation and oxygenation. Due to its rarity, there is currently no established protocol or guideline for anesthetic management of resection of upper tracheal tumors, therefore individualized strategies are necessary. There are limited number of reports regarding the anesthetic management of upper tracheal resection and reconstruction (TRR) in the literature. We successfully used intravenous ketamine to manage a patient with a near-occlusion upper tracheal tumor undergoing TRR.

#### CASE SUMMARY

A 25-year-old female reported progressive dyspnea and hemoptysis. Bronchoscopy showed an intratracheal tumor located one tracheal ring below the glottis, which occluded > 90% of the tracheal lumen. The patient was scheduled for TRR. Considering the risk of complete airway collapse after the induction of general anesthesia, we decided to secure the airway with a tracheostomy with spontaneous breathing. The surgeons needed to transect the trachea 1-2 cartilage rings below and above the tumor borders: a time-consuming process. Coughing and movement needed be minimized; thus, we added intravenous ketamine to local anesthetic infiltration. After tracheostomy, an endotracheal tube was placed into the distal trachea, and general anesthesia was induced. The surgeons resected four cartilage rings with the tumor attached and anastomosed the posterior tracheal wall. We performed a video-laryngoscopy to place a new endotracheal tube. Finally, the surgeons anastomosed the anterior tracheal walls. The patient was extubated uneventfully.

## CONCLUSION

Ketamine showed great advantages in the anesthesia of upper TRR by providing analgesia with minimal respiratory depression or airway collapse.

**Key Words:** Ketamine; Near-occlusion; Upper tracheal tumor; Tracheal resection and reconstruction; Tracheostomy; Case report

©The Author(s) 2022. Published by Baishideng Publishing Group Inc. All rights reserved.

**Core Tip:** The anesthetic management of upper tracheal resection and reconstruction (TRR) is challenging, since the tracheal tumor poses a significant risk to the patient's ventilation and oxygenation. In a patient with a near-occlusion upper tracheal tumor, we successfully maintained spontaneous breathing during tracheostomy in TRR with anesthesia provided by intravenous ketamine and local anesthetic infiltration. Ketamine shows great advantages in providing adequate analgesia and cough suppressant effects with minimal respiratory depression. We hope our experience adds to the knowledge of airway management of upper TRR.

**Citation:** Xu XH, Gao H, Chen XM, Ma HB, Huang YG. Using ketamine in a patient with a near-occlusion tracheal tumor undergoing tracheal resection and reconstruction: A case report. *World J Clin Cases* 2022; 10(23): 8417-8421

**URL:** <https://www.wjgnet.com/2307-8960/full/v10/i23/8417.htm>

**DOI:** <https://dx.doi.org/10.12998/wjcc.v10.i23.8417>

## INTRODUCTION

The tracheal tumor causes airway obstruction and poses a significant risk to the patient's ventilation and oxygenation. The incidence of primary tracheal tumors is as low as 2.6 cases per 1000000 people per year [1]. Due to its rarity, there is currently no established protocol or guideline for anesthetic management of resection of upper tracheal tumors, therefore individualized strategies are necessary. There are limited number of reports regarding anesthesia management of upper tracheal resection and reconstruction (TRR) in the literature. Laryngeal mask airway (LMA), high-frequency jet ventilation (HFJV), and extracorporeal membrane oxygenation (ECMO) have been successfully used for maintaining oxygenation during TRR[2-7].

We reported a case of a patient with a near-occlusion upper tracheal tumor undergoing TRR. In this case, we maintained spontaneous breathing during tracheostomy, and used intravenous ketamine to provide adequate analgesia and sedation.

## CASE PRESENTATION

### Chief complaints

A 25-year-old female with a body mass index of 22.03 kg/m<sup>2</sup> reported a 1-mo history of progressive dyspnea and hemoptysis.

### History of present illness

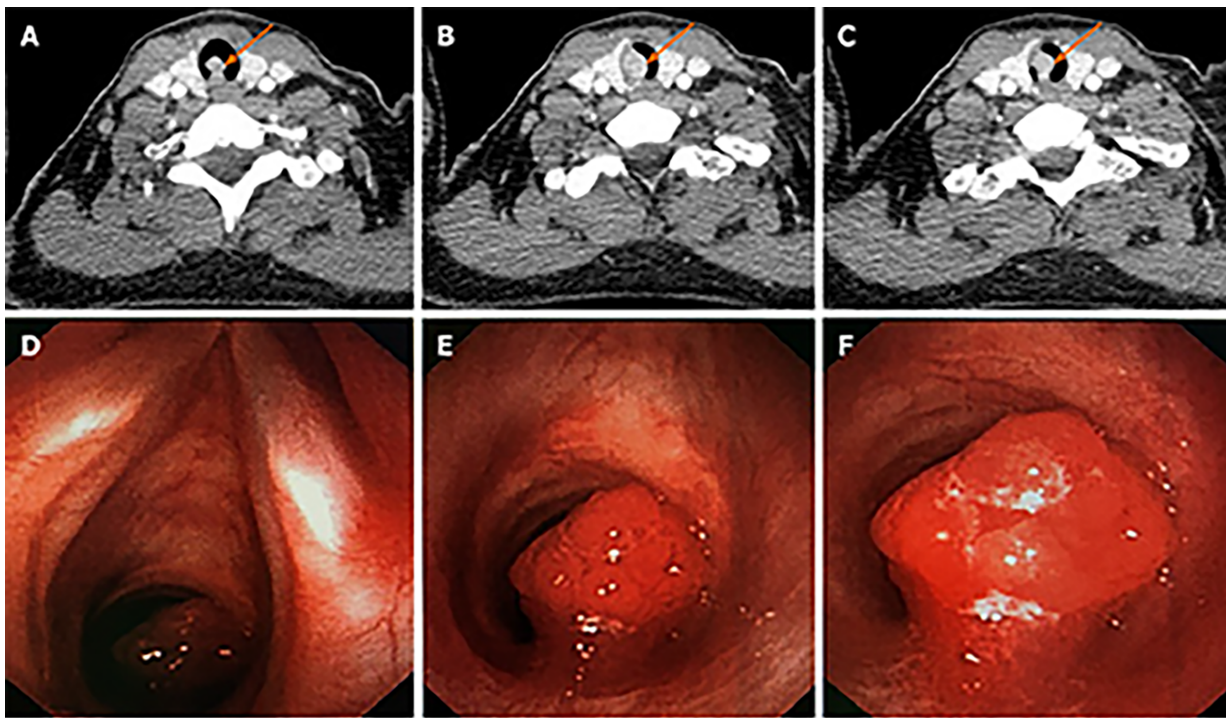
Dyspnea was aggravated in the supine position and relieved in the right lateral position.

### Physical examination

The airway evaluation showed normal mouth opening, Mallampati class II, mandibular protrusion, thyromental distance, and neck extension.

### Imaging examinations

A neck computed tomography (CT) scan showed an 8.4 mm × 11.2 mm contrast-enhanced mass with soft-tissue density protruding from the right posterior wall into the tracheal lumen (Figure 1A-C). Bronchoscopy showed an intratracheal tumor located one tracheal ring below the glottis, which occluded more than 90% of the tracheal lumen (Figure 1D-F). The tumor easily bled when being touched.



DOI: 10.12998/wjcc.v10.i23.8417 Copyright ©The Author(s) 2022.

**Figure 1 Neck computed tomography and bronchoscopic view.** A-C: Neck computed tomography showed a mass with soft-tissue density in the trachea pointed by orange arrows; D-F: In the bronchoscopic view, there was a mucosal neoplasm one cartilage ring below the glottis that occluded more than 90% of the lumen.

## FINAL DIAGNOSIS

The pathologic finding was mucoepidermoid carcinoma.

## TREATMENT

The patient was scheduled for TRR through a lower collar incision. The size and level of the patient's tracheal tumor precluded orotracheal intubation. To secure the patient's airway, we needed to maintain spontaneous breathing, provide pain control, and avoid coughing. To achieve these goals, we decided to secure the airway through tracheostomy with analgesia and sedation provided by intravenous ketamine and local anesthetic infiltration, followed by general anesthesia.

The patient entered the operating room with a pulse oxygen saturation of 100%. We provided continuous oxygen delivery through a nasal cannula at 2 L/min. The patient was positioned at a slight left lateral position where she could breathe most comfortably. The anesthesia was induced with 1 mg/kg ketamine. The sedation was then titrated with spontaneous breathing reserved. We gave 20 mg scopolamine intravenously to counteract the sialagogue effect from ketamine. Before skin incision, additional 0.5 mg/kg ketamine and 0.5 µg/kg fentanyl were administered intravenously to enhance analgesia, and the surgeons injected 1% lidocaine 10 mL subcutaneously around the incision. The tracheostomy took about 25 min with minimal blood loss. The entry site for tracheostomy was between the 4<sup>th</sup> and 5<sup>th</sup> cartilage rings, and a sterile endotracheal tube (ETT, internal diameter 6.5 mm) was placed into the distal trachea. The ETT was connected to a sterile breathing circuit, which was passed through the surgical field and connected to the anesthesia machine. The ventilation was confirmed by a normal end-tidal carbon dioxide waveform. The general anesthesia was induced with 2 mg/kg propofol, 0.8 mg/kg rocuronium, and 1.5 µg/kg fentanyl, and maintained with continuous infusions of propofol, remifentanyl, and lidocaine. The surgeons resected 1st to 4th cartilage rings with the tumor attached, anastomosed the posterior tracheal wall. We performed a video-laryngoscopy to place a new ETT. After the new ETT passed vocal cords, the surgeon removed the original ETT and guided the cuff balloon across the anastomotic line. Next, the surgical team anastomosed the anterior tracheal walls and closed the surgical incision. The overall surgery took a total of 75 min. At the end of the surgery, we suctioned the oropharynx thoroughly, administered 10 mg dexamethasone to prevent postoperative anastomosis edema, and stopped propofol and remifentanyl infusion. Neuromuscular blockade was reversed by 2 mg neostigmine and 1 mg atropine. After the spontaneous breathing was established, we extubated the patient uneventfully.

## OUTCOME AND FOLLOW-UP

The patient received adjuvant radiotherapy after the surgery. There was no sign of relapse during the postoperative two-year follow-up.

## DISCUSSION

The upper TRR presents challenges in airway and anesthetic management. In our case, the patient had a near-occlusion tracheal tumor, maintaining spontaneous breathing is of utmost importance. Local anesthetic infiltration for a tracheostomy to secure the airway at the first step is the safest approach. In this case, the surgeons used the subcutaneous injection of lidocaine before skin incision. The instillation of lidocaine directly on the trachea can also be considered after incision. However, the local anesthesia may not be adequate in this case due to the duration of the tracheostomy. The surgeons needed to accurately transect the trachea 1-2 cartilage rings below and above the tumor borders: a time-consuming process. Coughing and movement needed to be minimized. Ketamine provides analgesia and cough suppressant effects with minimal respiratory depression[8], and is superior to dexmedetomidine and propofol in minimizing upper airway collapse and maintaining compensatory responses to hypoxemia [9]. Adding intravenous ketamine to local anesthetic infiltration would provide better sedation and analgesia. Preoperative scopolamine or glycopyrrolate could counteract the sialagogue side effect from ketamine. Even though it did not happen in our case, hallucination from ketamine requires attention. Benzodiazepine or dexmedetomidine is helpful to control ketamine-induced hallucination[10].

There are several other options with their pros and cons in managing upper TRR. Bilateral cervical plexus block has been reported to maintain spontaneous breathing during TRR[5,6]. Nevertheless, a superficial plexus block would not be adequate, while a deep plexus block may block phrenic nerves and aggravate dyspnea, especially in the setting of a near-occlusion tracheal tumor. General anesthesia with LMA has been successfully used for tumors that occluded 65%-90% of the tracheal lumen[3,4]. However, there is a risk of complete airway collapse and obstruction after induction, especially in the high level of obstruction. If the tracheal tumor is small, a small endotracheal tube or HFJV cannula may be used to maintain ventilation[6,7]. Hemorrhage or tumor spreading would be a concern if the tumor is vascular or malignant in nature. For patients with a large tumor and respiratory distress, the ultimate backup plan is ECMO.

After TRR, the patient needs to maintain a neck-flexion position to minimize anastomosis tension. Agitation, coughing, laryngospasm, or vomiting may increase anastomosis tension. Anesthesia should be lightened cautiously during emergence. If reintubation is needed, a fiberoptic assisted approach is preferred.

## CONCLUSION

In conclusion, we successfully maintained spontaneous breathing during tracheostomy in TRR with anesthesia provided by intravenous ketamine and local anesthetic infiltration. Ketamine shows great advantages in the airway management in patients with near-occlusion tracheal tumors, since it provides adequate analgesia with minimal respiratory depression. The efficacy and safety of ketamine can be evaluated by in-depth comparative studies in the future.

## ACKNOWLEDGEMENTS

We would thank Dr. Philip Chan from Beth Israel Deaconess Medical Center, Harvard Medical School for helping revise the manuscript.

## FOOTNOTES

**Author contributions:** Xu XH and Gao H participated in the anesthesia management of the present case, and both were the major contributors of this manuscript; Chen XM completed the surgical procedure; Ma HB and Huang YG helped revise the manuscript; all authors read and approved the final manuscript.

**Informed consent statement:** A written informed consent was obtained from the patient for publication of this case report.

**Conflict-of-interest statement:** The authors have nothing to disclose.

**CARE Checklist (2016) statement:** The authors have read the CARE Checklist (2016), and the manuscript was prepared and revised according to the CARE Checklist (2016).

**Open-Access:** This article is an open-access article that was selected by an in-house editor and fully peer-reviewed by external reviewers. It is distributed in accordance with the Creative Commons Attribution NonCommercial (CC BY-NC 4.0) license, which permits others to distribute, remix, adapt, build upon this work non-commercially, and license their derivative works on different terms, provided the original work is properly cited and the use is non-commercial. See: <https://creativecommons.org/licenses/by-nc/4.0/>

**Country/Territory of origin:** China

**ORCID number:** Xiao-Han Xu 0000-0003-0243-9271; Hui Gao 0000-0002-4801-7851; Xing-Ming Chen 0000-0002-9930-2185; Hao-Bo Ma 0000-0003-3534-5108; Yu-Guang Huang 0000-0002-9278-6316.

**S-Editor:** Yan JP

**L-Editor:** A

**P-Editor:** Yan JP

## REFERENCES

- 1 Urdaneta AI, Yu JB, Wilson LD. Population based cancer registry analysis of primary tracheal carcinoma. *Am J Clin Oncol* 2011; **34**: 32-37 [PMID: 20087156 DOI: 10.1097/COC.0b013e3181cae8ab]
- 2 Andolfi M, Vaccarili M, Crisci R, Puma F. Management of tracheal chondrosarcoma almost completely obstructing the airway: a case report. *J Cardiothorac Surg* 2016; **11**: 101 [PMID: 27402094 DOI: 10.1186/s13019-016-0498-8]
- 3 Wendi C, Zongming J, Zhonghua C. Anesthesia airway management in a patient with upper tracheal tumor. *J Clin Anesth* 2016; **32**: 134-136 [PMID: 27290961 DOI: 10.1016/j.jclinane.2016.02.023]
- 4 Schieren M, Egyed E, Hartmann B, Aleksanyan A, Stoelben E, Wappler F, Defosse JM. Airway Management by Laryngeal Mask Airways for Cervical Tracheal Resection and Reconstruction: A Single-Center Retrospective Analysis. *Anesth Analg* 2018; **126**: 1257-1261 [PMID: 29293182 DOI: 10.1213/ANE.0000000000002753]
- 5 Liu J, Li S, Shen J, Dong Q, Liang L, Pan H, He J. Non-intubated resection and reconstruction of trachea for the treatment of a mass in the upper trachea. *J Thorac Dis* 2016; **8**: 594-599 [PMID: 27076957 DOI: 10.21037/jtd.2016.01.56]
- 6 Zhou Y, Liu H, Wu X, Li S, Liang L, Dong Q. Spontaneous breathing anesthesia for cervical tracheal resection and reconstruction. *J Thorac Dis* 2019; **11**: 5336-5342 [PMID: 32030251 DOI: 10.21037/jtd.2019.11.70]
- 7 Pang L, Feng YH, Ma HC, Dong S. Fiberoptic bronchoscopy-assisted endotracheal intubation in a patient with a large tracheal tumor. *Int Surg* 2015; **100**: 589-592 [PMID: 25875537 DOI: 10.9738/INTSURG-D-14-00020.1]
- 8 Chungsamarnyart Y, Pairart J, Munjupong S. Comparison of the effects of intravenous propofol and propofol with low-dose ketamine on preventing postextubation cough and laryngospasm among patients awakening from general anaesthesia: A prospective randomised clinical trial. *J Perioper Pract* 2022; **32**: 53-58 [PMID: 32301388 DOI: 10.1177/1750458920912636]
- 9 Mishima G, Sanuki T, Sato S, Kobayashi M, Kurata S, Ayuse T. Upper-airway collapsibility and compensatory responses under moderate sedation with ketamine, dexmedetomidine, and propofol in healthy volunteers. *Physiol Rep* 2020; **8**: e14439 [PMID: 32441458 DOI: 10.14814/phy2.14439]
- 10 Trivedi S, Kumar R, Tripathi AK, Mehta RK. A Comparative Study of Dexmedetomidine and Midazolam in Reducing Delirium Caused by Ketamine. *J Clin Diagn Res* 2016; **10**: UC01-UC04 [PMID: 27656531 DOI: 10.7860/JCDR/2016/18397.8225]





Published by **Baishideng Publishing Group Inc**  
7041 Koll Center Parkway, Suite 160, Pleasanton, CA 94566, USA

**Telephone:** +1-925-3991568

**E-mail:** [bpgoffice@wjgnet.com](mailto:bpgoffice@wjgnet.com)

**Help Desk:** <https://www.f6publishing.com/helpdesk>

<https://www.wjgnet.com>

