



ELSEVIER

Contents lists available at ScienceDirect

JPRAS Open

journal homepage: www.elsevier.com/locate/jpra

Review

Cleft-lip-plate patient with tracheobronchomalacia: A case report and review of the literature in Japan

Takashi Hitosugi^{a,*}, Takeshi Mitsuyasu^b, Takeshi Yokoyama^a^a Department of Dental Anesthesiology, Faculty of Dental Science, Kyushu University, 3-1-1 Maidashi, Higashi-ku, Fukuoka 812-8582, Japan^b Section of Oral and Maxillofacial Oncology, Division of Maxillofacial Diagnostic and Surgical Sciences, Faculty of Dental Science, Kyushu University, 3-1-1 Maidashi, Higashi-ku, Fukuoka 812-8582, Japan

ARTICLE INFO

Article history:

Received 2 August 2020

Accepted 9 September 2020

Available online 30 September 2020

Keywords:

Tracheobronchomalacia

Cleft-lip-plate

Congenital heart disease

General anesthesia

ABSTRACT

Background: Tracheobronchomalacia (TBM) is a severe life-threatening perioperative complication. It is a rare condition caused by congenital and developmental anomalies of the trachea and/or the bronchus. It is often difficult to diagnose TBM before surgery as this congenital disease presents very few symptoms preoperatively and most often appears postoperatively.

Case presentation and Review: The study describes a case of cleft-lip-plate (CL/P) in a 7-month-old Japanese female with TBM and Tetralogy of Fallot syndrome. Before undergoing cleft-lip surgery, her TBM was not fully elucidated by preoperative examinations, and the operation was completed uneventfully. After the surgery, however, she started showing severe respiratory distress and developed hypoxia and bradycardia in the operating room. CPR was performed successfully, but a bronchoscopy revealed a severely collapsed airway, and the pathological condition was diagnosed as TBM occurred postoperatively. Eight months later, she died of sudden respiratory failure similar to that of the postoperative event caused by TBM. A literature review was conducted on the complications of CL/P from 1990 to 2017 in Japan.

Conclusions: It was hypothesized that CL/P with congenital heart disease (CHD) and TBM with CHD may crossover in relatively high rates. Currently, there are very few solutions available to treat se-

* Corresponding author.

E-mail address: hitosugi.takashi.724@m.kyushu-u.ac.jp (T. Hitosugi).

vere airway obstruction related to TBM. This highlights the need for preoperative diagnosis of TBM as an important step in overcoming severe airway complications.

© 2020 The Author(s). Published by Elsevier Ltd on behalf of British Association of Plastic, Reconstructive and Aesthetic Surgeons.

This is an open access article under the CC BY-NC-ND license (<http://creativecommons.org/licenses/by-nc-nd/4.0/>)

Introduction

Tracheobronchomalacia (TBM) is a life-threatening perioperative complication that can cause severe airway obstruction. TBM is generally a congenital disease, while acquired TBM is rarely caused by tracheostomy or inflammation of tracheal cartilage in older adult patients.^{1–41} For pediatric patients, anesthetic procedures including use of inhalation analgesics, endotracheal intubation, and positive pressure ventilation during anesthesia can worsen the collapsibility of the trachea and bronchus. There should be a focus on patients with asymptomatic TBM as it often causes sudden airway obstruction during the perioperative period. TBM is difficult to diagnose during preoperative examinations. A respiratory condition and chest radiography often fall within normal limits.

TBM usually accompanies other congenital diseases and is often found in cases with cleft-lip and/or palate (CL/P) or in cases with congenital heart disease (CHD). TBM, CL/P, and CHD frequently occur together. TBM, however, is rarely recognized as a complication in patients with CL/P. Presently, there are no reports on patients with both TBM and CL/P. The present study highlights a case of TBM and CL/P. The pediatric patient presented with critical hypoxia just after cheiloplasty for cleft-lip. She had undergone tracheostomy due to repeating pneumonia. The operation was completed without any complications; however, she was diagnosed with TBM after the postoperative event of severe hypoxia. Thus, TBM should be considered a life-threatening complication during the perioperative period in patients with CL/P.

Case presentation

The patient involved in this study was a 7-month-old female with Tetralogy of Fallot (TOF). She was 60 cm in height and 4.75 kg in weight. She underwent the Blalock-Taussig shunt procedure and Patent ductus arteriosus ligation at 57 days of age and tracheostomy due to frequent recurrence of pneumonia and respiratory failure at 102 days of age. In addition to TOF, bilateral CLP and cheiloplasty were also performed. Before the surgery, TBM was unnoticed by respiratory specialists and otolaryngologists, although chest radiography (Fig. 1fA), bronchoscopy, and computed tomography (CT) had all been performed.

In operation, the 3.5ID cuffed tracheotomy-tube (COVIDEN Co. Ltd.) was kept for general anesthesia, and an anesthetic circuit was connected. Midazolam (Astellas Pharm. Inc.) 0.25 mg, rocuronium (MSD K.K.) 3 mg, and atropine (Mitsubishi Tanabe Pharm. Co.) 0.025 mg were administered for induction of anesthesia. Noninvasive hemodynamic monitoring (AESCUON®:OSYPKA MEDICAL) and direct monitoring of arterial pressure with dynamic and flow-based hemodynamic parameters (Flo-Trac sensor and Vigileo monitor®:Edwards Lifesciences) were used to evaluate cardiac output. Anesthesia was maintained with 2%–2.5% of desflurane gas (USP Baxter Inc.) in oxygen (1 L/min) and air (1 L/min). The operation was completed without any complications in four hours and six minutes. Total infusion volume was 251 ml, total blood loss volume was 7 ml, and urine volume was 7 ml. After the operation, the patient emerged from general anesthesia without any complications. Spontaneous respiration was stable, and SpO₂ was 86%–89% in room air.

However, when the patient was transferred over from the operating table to the stretcher, she started crying, and a severe respiratory distress response appeared simultaneously. Paradoxical breathing was observed, and severe airway obstruction was suspected. The anesthetic circuit was connected

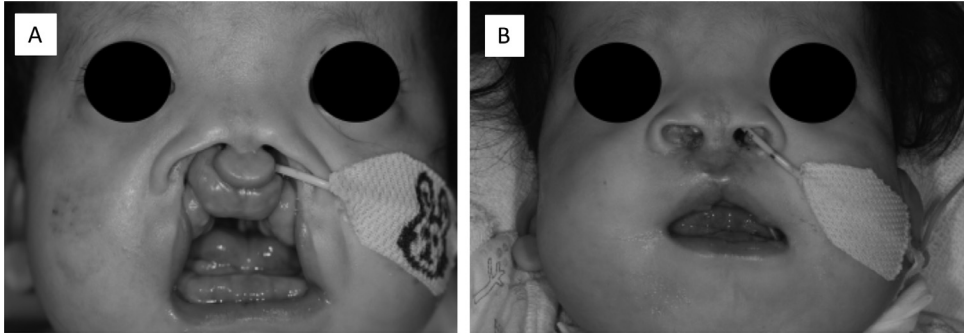


Fig. 1. (A) Chest Radiography shows normal lung, trachea, and bronchus before the operation. (B) CT image shows luminal narrowing of the trachea and bronchus (white arrow). The image was taken after the operation.

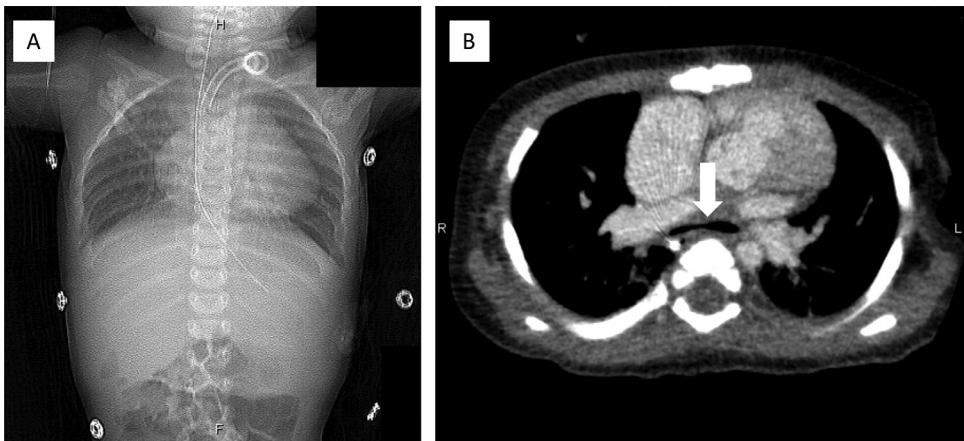


Fig. 2. Progress of the clinical report.

to the tracheotomy-tube again, and positive pressure ventilation was attempted. However, the doctors could not ventilate properly as the ventilation-bag was too stiff, and the inflated flow was released through the mouth when the pressure was increased to more than the leak pressure. At first, the patient was agitated and uncooperative. Soon after, she lost consciousness and collapsed. Her SpO_2 decreased suddenly, and severe bradycardia started. The heart rate dropped from 134 to 38 beats/min, and SpO_2 and blood pressure could not be assessed. The emergency team arrived in the operation room and started CPR with manual chest compression keeping continuous positive pressure ventilation. Atropine (Mitsubishi Tanabe Pharm. Co.) 0.025 mg IV was administered. Inflation of oxygen was possible only during chest compression. Gradually, these attempts lead to oxygen desaturation. Spontaneous respiration also recovered gradually (Fig. 2). Bronchoscopy through the tracheotomy-tube revealed that severe stenosis existed from the trachea to the mainstem bronchi (Fig. 3). TBM was diagnosed as the trachea and bronchus wall were collapsed and invaginated. The narrowest tracheal diameter was 2 mm (Fig. 3).

After CPR, SpO_2 recovered to 88%–90% (FiO_2 1.0) with positive pressure ventilation. However, SpO_2 was 80%–82% upon spontaneous breathing. In order to prevent the narrowing of the trachea and bronchi in relation to TBM during spontaneous respiration, respiratory support with noninvasive positive pressure ventilation was provided. The patient was transferred to NICU without any additional complications (Table 1). Anesthesia time lasted 7 h and 42 min. The patient was weaned off the ventilator two hours later and taken to the children's ward after two days. After a few days, however, her

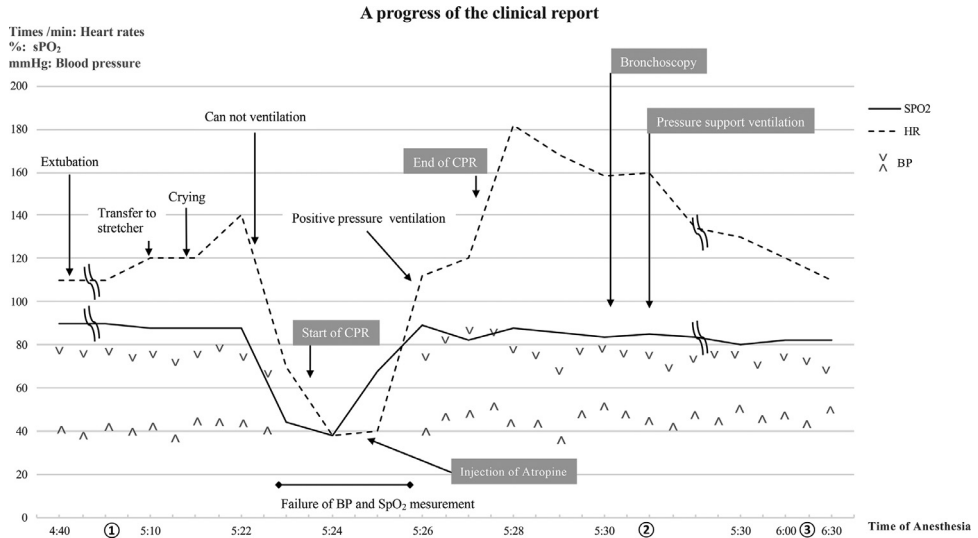


Fig. 3. Bronchoscopy image shows crescent type of collapsed trachea (A) and bronchi (B).

Table 1

Blood gas analysis and hemodynamic parameter findings during the operation. The patient showed hypoxia due to hypoventilation especially at time of ②.

Items	Average Measurement	Pre-operation	①	②	③
pH	7.40 ± 0.02	7.432	7.429	7.317	7.369
PaO ₂ (mm Hg)	80~100	36.4	39.0	42.3	34.2
PaCO ₂ (mm Hg)	35~45	36.4	38.4	38.7	37.8
SaO ₂ (%)	Less than 89	70.2	75.6	73.2	62.6
tHb _d (g/dL)	10~15	14.1	13.1	12.4	10.9
HCO ₃ ⁻ (m mol/L)	24±2	23.9	24.9	19.2	21.3
ABE _d (m mol/L)	0 ± 2	0.4	1.2	-5.9	-3.1
SV _d (ml/beat)	60~100	6.4	6.0	8.5	
CI _d (L/min/m ²)	2.5~4.0	2.5	2.3	3.7	
SVV _d (%)	10~15	16	13	16	

general condition started worsening. She had been hospitalized for heart transplantation and radical operation of the heart. Ultimately, she died from respiratory failure with tracheal obstruction caused by TBM and granuloma eight months later at NICU.

Consent: Informed consent was obtained from the parents of the patient for this case report (Fig 4).

Review of the literature

This study reviewed Japanese and English-language literature describing complication of CL/P from 1998 to 2017 in Japan. PubMed was used to search English-language literature, and Japana Centra Revuo Medicina Web was used for Japanese-language literature. Presence of TB/M, congenital heart disease, respiratory disease (which included history of chronic bronchitis, pulmonary disorders, and asthma), and chromosome aberration and syndrome were compared. After analyzing the titles, abstracts, and full-texts, 22 studies met the final inclusion criteria. Twenty studies reported between all CL/P and complications (Table 2). One study reported about submucous CP, and the other reported all CL/P and facial cleft. CP and CL/P were increased risk of complication of congenital heart disease (1.9–22.2%) and chromosome aberration and syndrome (17.5%). A smaller percentage of each kind of

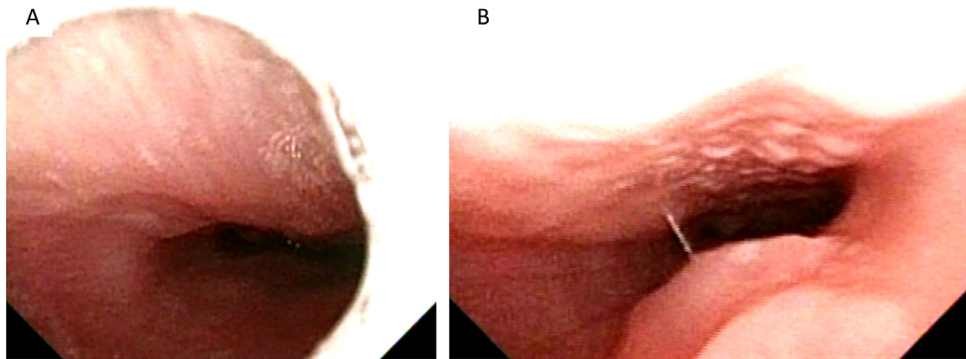


Fig. 4.

Table 2
Complications of CL/P from 1998 to 2017 in Japan.

Source	Cases	Total Patients, n	Complications(%)			
			TM and/or TBM	CHD	Respiratory diseases	Chromosomeaberation/ Syndrome
Kibe et al.,2017	CL/P	1100		4.0	NR	1.5
Shiraishi et al., 2017	CL/P	72		12.5	NR	8.3
Ominato et al., 2016	Submucous CP	84		9.5	NR	16.6
Nishimura et al., 2016	CL/P	1428		2.56	NR	4.68
Kato et al., 2015	CL/P	148		18.0	4.5	NR
Yoshida et al., 2014	CL/P	661		4.1	NR	4.5
Matsumura et al.,2014	CL/P	228		22.2	NR	NR
Mikoya et al.,2011	CL/P	461		13.8	2.4	NR
Yamamoto et al.,2009	CL/P	311		17.6	NR	17.6
Kohara et al.,2008	CL/P	1366		10.2	1.2	15.7
Kuninaka et al., 2007	CL/P	496		5.8	NR	NR
Saeki et al., 2007	CL/P	147	Not Reported	4.0	NR	3.4
Kanbara et al., 2005	CL/P	571		3.1	0.7	3.1
Yamamoto et al., 2004	CL/P	393		2.2	NR	2.5
Fujimota et al., 2003	CL/P	332		4.2	NR	11.1
Otsuki et al., 2002	CL/P	365		9.6	NR	NR
Hanaika et al., 2002	CL/P	569		3.6	NR	4.7
Sugiura et al., 2000	CL/P	47		15.6	4.4	NR
Ryoke et al.,1994	Orofacial cleft	497		2.8	NR	4.4
Kishiba et al., 1993	CL/P	472		5.0	NR	0.8
Nishio et al.,1993	CL/P	239		10.0	1.3	17.5
Mure et al., 1990	CL/P	462		1.9	NR	1.0

chromosome aberration and syndrome were at risk for complications with CL/P. Mucopolysaccharidosis, CHARGE syndrome, VATER syndrome, Trisomy 9, Trisomy 21, 11p13 deletion, 22q11 deletion, and Pierre-Robin syndrome were included. However, we could not find any information regarding TMB.

Discussion

Tracheomalacia (TM) is usually localized in either one portion or the entirety of the trachea. If the mainstem bronchi are also involved, the term tracheobronchomalacia (TBM) is employed. It should be noted that, historically, many authors have used TM and TBM interchangeably.¹ TBM may cause excessive collapsing of the airways. TBM is characterized by increased compliance of the central air-

way within the thorax. Some trigger events, such as crying in this case, can lead to excessive dynamic collapse.²

There are a few reports that cite the incidence of congenital TM as between 0.05%–4.5%.^{3–6} Cardiovascular abnormalities are found in 20%–58% of patients with TM.^{7,8} TM is related to substantial morbidity and mortality. In the case of severe TM, the mortality rate can reach almost 80%.⁹ CL/P is one of the most common craniofacial anomalies with an incidence rate of 7–10 in 10,000 births.^{10,11} CHD and CL/P may be associated with each other with high incidence. In 2017, Munabi et al.¹² conducted a literature review including a total of 6942 CL/P patients and found that 8.77% of CL/P patients had CHD. The literature review carried out for this study included a total of 10,449 CL/P (LP, CP, and CLP) patients in Japan from 1990 to 2017.^{13–34} CL/P had an increased risk of CHD complication (1.9%–22.2%) and chromosome aberration and syndrome (17.5%). A smaller percentage of each kind of chromosome aberration and syndrome were at risk for complications with CL/P. Mucopolysaccharidosis, CHARGE syndrome, VATER syndrome, Trisomy 9, Trisomy 21, 11p13 deletion, 22q11 deletion, and Pierre-Robin syndrome were included. However, no literature was found relating the aforementioned with TMB.

TBM is usually asymptomatic and cannot be found using chest radiography³⁵ as it rarely shows dyspnea, hemoptysis, and/or an intractable cough. Therefore, TBM is often overlooked. In the case of pediatric patients, they cannot often explain the details of their symptoms well, are usually not cooperative, and often refuse clinical examinations. Moreover, if these patients have cyanotic CHD who show daily hypoxic symptom or showed no abnormality in respiration. Subsequently, it is difficult for medical staff to obtain the diagnosis of TBM or vocal adhesion³⁶ before operation and administration of general anesthesia. Therefore, physicians may encounter patients with sudden severe respiratory trouble in the perioperative period.

Bronchoscopy has been considered as the standard method for diagnosing TBM.^{37,38} However, it often overlooks TBM, as in the case reported in this review wherein preoperative bronchoscopy did not reveal TBM. Both negative and positive airway pressure are necessary to obtain the exact diagnosis for TBM. It should be noted that deep inhalation and a strong cough during the examination may help in diagnosis. In recent years, multi-detector CT has provided accurate 3-dimensional (3D) imaging of the thoracic structure. In this case, preoperative examinations including a chest radiography and a bronchoscopy were within normal limits. The bronchoscopy also revealed no abnormalities. The patient showed no symptoms suggesting TBM before the cheiloplasty. She had undergone several operations under general anesthesia with tracheal intubation and/or tracheotomy with no complications. She had frequent hypoxic events due to TOF. These complex situations may have made it difficult to obtain accurate information about her trachea and bronchus. Hence, the presence of TBM could not have been detected in advance.

In CHD patients with TBM, 45% percent of them receive diagnosis of TBM after cardiac surgery. TBM had often been found as these patients suffered from difficulty of weaning from mechanical ventilation and/or extubation. This suggests that TBM should be suspected in patients with unexpected postoperative respiratory difficulty.³⁹ In general, tracheal intubation or tracheostomy are recommended strategies for dyspnea due to airway constriction. In the case of sudden bronchospasms, positive pressure ventilation with 100% oxygen should be attempted as soon as possible. In this specific case, it was suspected that there was acute obstruction of the trachea when the female suffered from dyspnea as she had no history of asthma. During induction of anesthesia, SpO₂ was maintained well under normal spontaneous respiration. After administration of the muscle relaxant, positive pressure ventilation was performed. Therefore, when sudden dyspnea appeared, bronchospasm had already been ruled out. It was expected that positive pressure ventilation and suction via tracheostomy-tube would remove secretion and that airway obstruction would be easily released. Collapsing of the trachea and bronchus were not expected, and positive pressure ventilation and suction did not improve the respiratory condition. Bronchoscopy showed clear collapsing of the trachea and bronchus, and TBM was then diagnosed. Strong negative intrathoracic pressure was caused by crying, which may have triggered the collapsing of the trachea and bronchus. In patients with congenital TBM, collapsing of the trachea and/or the bronchus often occurs under semi-conscious state after general anesthesia. In 1955, Proctor⁴⁰ explained the unstable condition of the trachea and/or the bronchus as “paradoxical respiration”. Therefore, attention should be given to the collapse during emergence from anesthesia.

Additionally, crying should be prevented as intrathoracic negative pressure may cause narrowing and adhesion of the tracheal mucosa, which can further lead to complete airway obstruction.

In this case, direct force of manual chest compression in CPR and positive pressure ventilation was fortunately able to open the trachea and bronchus. However, if the area of airway obstruction had extended to the bronchus, a normal tracheal-tube may have been too short to reach beyond the collapsed area. Further, if severe stenosis of the trachea and the bronchus had occurred, tracheal intubation and tracheostomy would have been insufficient for opening the collapse even with high pressure administered into the airway. Currently, only extracorporeal circulation or extra corporeal membrane oxygenator have been regarded as viable options for treatment.⁴¹ However, these cannot be used to respond appropriately to acute respiratory disorders as they require advance preparation. Prevention of sudden collapse may be the only way to save the life of a patient with TBM.

Conclusions

This review highlights a case of TBM-related collapsing of the trachea after cheiloplasty in a baby with CHD. It is difficult to diagnose TBM as this congenital disease presents relatively few symptoms preoperatively. Severe airway collapse due to TBM is a life-threatening situation and usually appears after surgery, especially during emergence from general anesthesia. There are very few ways of treating patients effectively when this occurs. It is therefore imperative that the existence of TBM in CL/P patients, especially those with CHD, be further scrutinized and studied.

Consent for publication

Written informed consent was obtained from the patient for publication of clinical details and clinical images. A copy of the consent form is available for review by the Editor of this journal.

Declaration of Competing Interest

The authors declare that they have no competing interests.

Funding

There was no financial support for the report.

Authors' contributions

TM performed the surgical intervention, TH followed the general anesthesia recovery of the patient, and TY was a major contributor in the writing of the manuscript. All authors have read and approved the final manuscript for publication.

Acknowledgments

We would like to thank the members of the Department of Dental Anesthesiology Faculty of Dental Science, Kyushu university, and the members of the Department of Oral and Maxillofacial Surgery, Kyushu university, for their cooperation.

References

1. Carden KA, Boiselle PM, Waltz DA, et al. Tracheomalacia and tracheobronchomalacia in children and adults: an in-depth review. *Chest*. 2005;127:984–1005.
2. Hysinger EB, Panitch HB. Paediatric Tracheomalacia. *Paediatr Respir Rev*. 2016;17:9–15.
3. Boogaard R, Huijsmans SH, Pijnenburg MW, et al. Tracheomalacia and bronchomalacia in children: incidence and patient characteristics. *Chest*. 2005;128:3391–3397.
4. Ghaye B, Szapiro D, Fanchamps JM, et al. Congenital bronchial abnormalities revisited. *Radiographics*. 2001;21:105–119.
5. Jokinen K, Palva T, Sutinen S, et al. Acquired tracheobronchomalacia. *Ann Clin Res*. 1977;9:52–57.
6. Jacobs IN, Wetmore RF, Tom LW. Tracheobroncho-malacia in children. *Arch Otolaryngol Head Neck Surg*. 1994;120:154–158.

7. Mair EA, Parsons DS. Pediatric tracheobronchomalacia and major airway collapse. *Ann Otol Rhinol Laryngol*. 1992;101:300–309.
8. Blair GK, Cohen R, Filler RM. Treatment of tracheomalacia: eight years' experience. *J Pediatr Surg*. 1986;21:781–785.
9. Picot C, Monnet P, Bethenod M, et al. Tracheomalacia in infants. *Arch Fr Pediatr*. 1969;26:493–506.
10. Working Group IPDTC. Prevalence at birth of cleft lip with or without cleft palate: data from the International Perinatal Database of Typical Oral Clefts (IPDTC). *Cleft Palate Craniofac J*. 2011;48:66–81.
11. Tanaka SA, Mahabir RC, Jupiter DC, et al. Updating the epidemiology of cleft lip with or without cleft palate. *Plast Reconstr Surg*. 2012;129:511–518.
12. Munabi NCO, Swanson J, Auslander A, et al. The prevalence of congenital heart disease in nonsyndromic cleft lip and/or palate: a systematic review of the literature. *Ann Plast Surg*. 2017;79:214–220.
13. Kibe T, Nishihara K, Fuchigami T, et al. Clinical statistical observations on patients with primary cleft lip, cleft palate, or both during 30 years in our department. *J Jpn Oral Maxillofac Surg*. 2017(63):140–147 [In Japanese]. doi:10.5794/jjoms.63.140.
14. Shiraiishi M, Mishima K, Umeda H, et al. Clinico-statistical study of the cases of cleft lip and/or palate in the past 10 years at our department. *Yamaguchi med J*. 2017(66):169–174. [In Japanese]. <http://petit.lib.yamaguchi-u.ac.jp/G0000006y2j2/metadata/B0300066000303>.
15. Ominato R, Kobayashi T, Kodama Y, et al. Clinical Investigation of patients with submucous cleft palate: diagnosis and clinical manifestations. *J Jpn CleftPalate Assoc*. 2016(41):24–30. [In Japanese]. <https://doi.org/10.11224/cleftpalate.41.24>.
16. Nishimura K, Kochi S, Igarashi K. Clinicostatistical investigation of cleft lip and/or palate patients in the clinics for maxillofacial disorders, Tohoku University Hospital. *J Jpn CleftPalate Assoc*. 2016;41:31–38 [In Japanese]. doi:10.11224/cleftpalate.41.31.
17. Kato S, Okumura Y, Yamada M, et al. A 26-year statistical analysis of cleft lip and/or palate patients at nagoya city west medical center: -a report on first-visit patients. *J Jpn CleftPalate Assoc*. 2015(40):226–232. [In Japanese]. <https://doi.org/10.11224/cleftpalate.40.226>.
18. Yoshida Y, Doi R, Nishio S, et al. Clinicostatistical analysis of cleft lip and/or palate: -associated congenital anomalies. *Jpn CleftPalate Assoc*. 2014;39:28–33. [In Japanese]. <https://doi.org/10.11224/cleftpalate.39.28>.
19. Matsumura K, Sasaguri K, Mitsuyasu T, et al. Clinicostatistical investigation of cleft lip and/or palate patients in the department of oral and maxillofacial surgery, Kyushu University Hospital. *J Jpn CleftPalate Assoc*. 2014;39:217–223. [In Japanese]. <https://doi.org/10.11224/cleftpalate.39.217>.
20. Mikoya T, Matsuzawa Y, Sogabe I, et al. Clinico-statistical study of cleft lip and/or palate patients in the past 16 years at the center for advanced oral medicine, Hokkaido University Hospital. *J Jpn CleftPalate Assoc*. 2011;36:166–173. [In Japanese]. <https://doi.org/10.11224/cleftpalate.36.158>.
21. Yamamoto M, Inagawa K, Urushihara K, et al. Clinicostatistical analysis of primary operative cases with cleft lip and/or palate in the department of plastic & reconstructive Surgery, Kawasaki Medical School Hospital: during the seven-year period from April 2002 to March 2009. *J Jpn CleftPalate Assoc*. 2009;34:273–282. [In Japanese]. <https://doi.org/10.11224/cleftpalate.34.273>.
22. Kohara H, Nishio J, Hirano Y, et al. 20-years statistical analysis of cleft lip and/or palate patients at Osaka medical center and research institute. *J Jpn CleftPalate Assoc*. 2008;33:330–337. [In Japanese]. https://doi.org/10.11224/cleftpalate1976.33.3_330.
23. Kuninaka R, Arakaki K, Tengan T, et al. Clinicostatistical observations of cleft lip and/or palate in department of oral and maxillofacial surgery, University of the Ryukyus Hospital Primary cases. *J Jpn CleftPalate Assoc*. 2007;32:299–306. [In Japanese]. https://doi.org/10.11224/cleftpalate1976.32.3_299.
24. Saeiki M, Yanagisawa S, Kawano K, et al. Incidence of cleft lip and/or palate in oita prefecture. *J Jpn CleftPalate Assoc*. 2007;32:78–84. [In Japanese]. https://doi.org/10.11224/cleftpalate1976.32.1_78.
25. Kanbara H, Abe A, Nakano M, et al. Clinico-statistical study on cleft lip and palate in the past 20 years at the Department of oral and maxillofacial surgery, Aichi-gakuin university. *J Jpn CleftPalate Assoc*. 2005;30:248–253. [In Japanese]. https://doi.org/10.11224/cleftpalate1976.33.3_330.
26. Yamamoto M, Moriguchi T, Hamanaka T, et al. A twelve-year clinicostatistical observation operative case with cleft lip and/or palate or isolated cleft palate -first report-. *J Jpn CleftPalate Assoc*. 2004;29:48–56. [In Japanese]. https://doi.org/10.11224/cleftpalate1976.29.1_48.
27. Fujimoto M, Yamamoto K, Kawakami M, et al. Clinico-statistical study on cleft lip and palate in the past 20 years at the department of oral and maxillofacial surgery, Nara medical university. *J Jpn CleftPalate Assoc*. 2003;28:238–249. [In Japanese]. https://doi.org/10.11224/cleftpalate1976.28.3_238.
28. Otsuki R, Morita N, Wada T, et al. clinical and statistical observations of patients cleft lip and/or palate -1st report: character of cleft type and complicating malformations-. *J Jpn Stomatol Soc*. 2002;51:132–136. [In Japanese]. <https://doi.org/10.11277/stomatology1952.51.132>.
29. Hanaike Y, Ryoike K, Kataoka S. Clinico-statistical investigation of cleft lip and/or palate and face: associated congenital anomalies. *Yonago Med J*. 2002;53:162–171. [In Japanese]. <http://mol.medicalonline.jp/library/journal/download?GoodsID=eb3yona1/2002/005302/010&name=0162-0171j&UserID=133.5.235.129&base=jamas.pdf>.
30. Sugiura M, Yuasa H, Hasegawa S, et al. 10-years Statistical analysis of cleft lip and/or palate patients at Nagoya city Johoku Municipal Hospital. *Aichi-Gakuin J Dent Sci*. 2011;38:405–412. [In Japanese]. <http://mol.medicalonline.jp/library/journal/download?GoodsID=ch8aichi/2000/003803/004&name=0405-0412j&UserID=133.5.235.129&base=jamas.pdf>.
31. Ryoike K, Kawasaki K, Fukumoto J, et al. Clinico-statistical investigation of cleft face, lip and l or palate. *J Jpn CleftPalate Assoc*. 1994;19:177–185. [In Japanese]. https://doi.org/10.11224/cleftpalate1976.19.3_177.
32. Kishiba M, Yamashiro M, Sunakawa H, et al. An 15 year clinical study of cleft lip and cleft palate. *J Jpn CleftPalate Assoc*. 1993;18:220–227 [In Japanese]. doi:10.11224/cleftpalate1976.18.2_220.
33. Nishio J, Kitamura R, Sako M, et al. 5-year statistical analysis of cleft lip and/or palate patients at Osaka Medical Center and Research Institute for Maternal and Child Health. *J Jpn CleftPalate Assoc*. 1993;18:123–132 [In Japanese]. doi:10.11224/cleftpalate1976.18.1_123.
34. Mure R, Moriguchi T, Koushima J, et al. Statistical observation of cleft lip alveolus and palate in the Department of PRS, Kawasaki Medical School Hospital during the past 10 years from 1978 to 1987. *J Jpn CleftPalate Assoc*. 1990;15:198–205 [In Japanese]. doi:10.11224/cleftpalate1976.15.3_198.

35. Carden KA, Boiselle PM, Waltz DA, et al. Tracheomalacia and tracheobronchomalacia in children and adults: an in-depth review. *Chest*. 2005;127:984–1005.
36. Hitosugi T, Tsukamoto M, Fujiwara S, et al. Perioperative management of a child with vocal adhesion leading to unexpected difficult airway. *Masui* 2016. 2016;65:590–593 [In Japanese].
37. Burden RJ, Shann F, Butt W, et al. Tracheobronchial malacia and stenosis in children in intensive care: bronchograms help to predict outcome. *Thorax*. 1999;54:511–517.
38. Rozyck HJ, Van Houten ML, Elliott GR. Quantitative assessment of intrathoracic airway collapse in infants and children with tracheobronchomalacia. *Pediatr Pulmonol*. 1996;21:241–245.
39. Chen Q, Langton-Hewer S, Marriage S, et al. Influence of tracheobronchomalacia on outcome of surgery in children with congenital heartdisease and its management. *Ann Thorac Surg*. 2009;88:1970–1974.
40. Proctor H. The stove-in chest with paradoxical respiration. *Br J Surg*. 1955;42:622–633.
41. Kim SH, Song S, Kim YD, et al. Outcomes of extracorporeal life support during surgery for the critical airway stenosis. *ASAIO J*. 2017;63:99–103.