

HOSTED BY



ELSEVIER

Contents lists available at ScienceDirect

# Chinese Journal of Traumatology

journal homepage: <http://www.elsevier.com/locate/CJTEE>

## Original article

# Diagnosis and treatment of rare complications of pelvic fractures

Zhao-Wen Zong<sup>\*,1</sup>, Quan-Wei Bao<sup>1</sup>, Hua-Yu Liu, Yue Shen, Yu-Feng Zhao, Xiang Hua, Qing-Shan Guo, Lian-Yang Zhang, Hui Chen

State Key Laboratory of Trauma, Burns and Combined Injury, Department of Trauma Surgery, Daping Hospital, Third Military Medical University, Chongqing, 400042, China

## ARTICLE INFO

### Article history:

Received 27 May 2015

Received in revised form

19 December 2015

Accepted 30 December 2015

Available online 29 March 2016

### Keywords:

Pelvis

Fractures, bone

Complications

Diagnosis

## ABSTRACT

**Purpose:** To enhance the awareness of rare complications of pelvic fracture and describe the correct diagnosis and effective treatment.

**Methods:** A total of 188 cases of pelvic fractures were retrospectively reviewed, and four patients who suffered from four types of rare pelvic fracture complications were described, namely ureteral obstruction caused by retroperitoneal hematoma-induced abdominal compartment syndrome (ACS), bowel entrapment, external iliac artery injury, and open scrotal sac injury.

**Results:** We demonstrated that combined measures should be employed to prevent the occurrence of ACS following major pelvic fractures. Ureteral catheter support may be a good option at an early stage when ACS occurred. Contrast computed tomography examination and sufficient awareness are keys to a correct diagnosis of bowel entrapment following pelvic fractures. Recognition of risk factors, early diagnosis, and prompt treatment of suspected injury of the external iliac artery are keys to patient survival and to avoid limb loss. Scrotal and/or testicular injury complicated by pelvic fractures should be carefully treated to maintain normal gonad function. Additionally, establishment of a sophisticated trauma care system and multi-disciplinary coordination are important for correct diagnosis and treatment of rare complications in pelvic fractures.

**Conclusions:** Rare complications of pelvic fractures are difficult to diagnose and negatively impact outcome. Recognition of risk factors and sufficient awareness are essential for correct diagnosis and prompt treatment.

© 2016 Production and hosting by Elsevier B.V. on behalf of Daping Hospital and the Research Institute of Surgery of the Third Military Medical University. This is an open access article under the CC BY-NC-ND license (<http://creativecommons.org/licenses/by-nc-nd/4.0/>).

## Introduction

Complications can be defined as a secondary disease, accident, or negative reaction that occur during the course of an illness and usually aggravate the illness. Complications of pelvic fractures are always described in a routine way and as associated injuries of pelvic fractures. Pelvic ring fractures require transmission of a tremendous amount of force, and often happen in severely injured patients with multiple organ injuries.<sup>1</sup> The most common associated injuries are bleeding and retroperitoneal hematoma, intra-abdominal and urogenital injuries, and never injuries in addition to severe pelvic fractures.<sup>1–3</sup> Approximately 12% of trauma patients

admitted to Level 1 or 2 trauma centers in the United States exhibit pelvic ring injury, and injuries to intra-abdominal or urogenital organs are present in an estimated 16% of these patients. Prompt diagnosis and effective management of these injuries is essential to a successful outcome.<sup>2,3</sup>

Great efforts have been made to improve treatment of pelvic fracture and its complications, and substantial improvements have been achieved. However rare complications of pelvic fractures, such as ureteral obstruction caused by retroperitoneal hematoma induced abdominal compartment syndrome (ACS), bowel entrapment, external iliac artery injury, and open scrotal sac injury are not easily diagnosed and treated. Unawareness of these rare conditions makes the diagnosis difficult, and failure to provide prompt treatment leads to poor outcomes.

In order to increase the awareness of these rare complications of pelvic fracture and describe the correct diagnosis and effective treatment, we present four cases that exhibit the above-mentioned four different types of rare complications.

\* Corresponding author. Tel.: +86 23 68757996; fax: +86 23 68757995.

E-mail address: [zongzhaowen@163.com](mailto:zongzhaowen@163.com) (Z.-W. Zong).

Peer review under responsibility of Daping Hospital and the Research Institute of Surgery of the Third Military Medical University.

<sup>1</sup> Those patients contribute evenly to this paper.

## Materials and methods

This study was reviewed and approved by the Ethical Committee of the Daping Hospital, Third Military Medical University, China. All four patients reported in this study have signed informed consent forms, agreeing that we could report their clinical courses.

Patients who suffered from pelvic fractures in our department from June 2009 to July 2012 were retrospectively reviewed. The mechanisms of injuries, the type of pelvic fracture, and the complications are analyzed.

Four cases exhibited the four types of rare complications, namely ureteral obstruction caused by retroperitoneal hematoma induced abdominal compartment syndrome, bowel entrapment, external iliac artery injury, and severe open scrotal sac injury.

Extensive literature search on Medline/PubMed was performed, including articles related to complications of pelvic and acetabular fractures. We carefully reviewed articles related to the above-mentioned four types of rare complications. Suggestions for diagnosis and recommendations for treatment of these rare complications of pelvic fractures were given.

## Results

A total of 188 cases of pelvic fractures were treated in our department between June 2009 and June 2012. There were 124 male and 64 female patients, with an average of 41.2 years of age. The mechanisms of injury included traffic injury (122 cases), high fall injury (35 cases), and heavy object pound injury (24 cases). Of the 188 cases, 37 were complicated by or associated with chest injuries, 14 with brain injuries, 45 with upper extremities injuries, 36 with lower extremities injuries, 12 with ureteral injuries, 3 with bladder injuries, 6 with bowel injuries, and 3 with spleen disruption. There were four cases that exhibited four types of rare complications, namely ureteral obstruction caused by retroperitoneal hematoma induced abdominal compartment syndrome, bowel entrapment, external iliac artery injury, and severe open scrotal sac injury. These cases are reported in detail below.

### Case one

A 48-year-old male cleaner fell from a 9 m high building when cleaning the outside window in our hospital and was transferred to the emergency room within 6 min following the accident. On admission, his blood pressure was 100/65 mmHg; it decreased to 65–72/40–46 mmHg 10 min after admission. After the patient was hemodynamically stabilized by infusion of 3000 ml crystalloid fluid and 1200 ml suspended red blood cells, plain roentgenogram and three-dimensional computed tomography (CT) were performed and demonstrated type 61-B2.1 pelvic fracture according to Arbeitsgemeinschaft für Osteosynthesefragen/Orthopaedic Trauma Association (AO/OTA) classification scheme (Fig. 1A). Additional injuries included a compound fracture of the left proximal femur, fractures of the tenth to twelfth ribs on the left side with lung contusion and hemothorax, fracture of the distal radius and proximal ulna and radius on the left side, and laceration of the head (Fig. 1B, C, D and E). Digital subtraction angiography (DSA) performed along with CT revealed no arterial bleeding of the internal iliac artery and its branches, and thus no need to perform embolism.

The patient exhibited oliguria 4 h post-trauma, even following successful fluid resuscitation. Continuous bedside ultrasound examination showed bilateral hydronephrosis and progressively enlarged retroperitoneal hematoma. The bladder pressure measured by a Foley catheter increased from 8 mmHg to 22 mmHg. There were no signs of abdominal, chest, or brain injury. Following

consultation by experts in our trauma center and the Department of Urology, the patient underwent double “J” bilateral ureteral catheter placement, during which no urine was observed in the ureteral orifice into the bladder. Immediately following the replacement of ureteral catheter, urine was observed in the urinary bag and urinary output continued at a rate of 50–105 ml/h. Bladder pressure increased slightly 1 h following the surgical operation, decreased slowly, and then reached approximately 8 mmHg 8 days following surgery. The ureteral catheter was then removed.

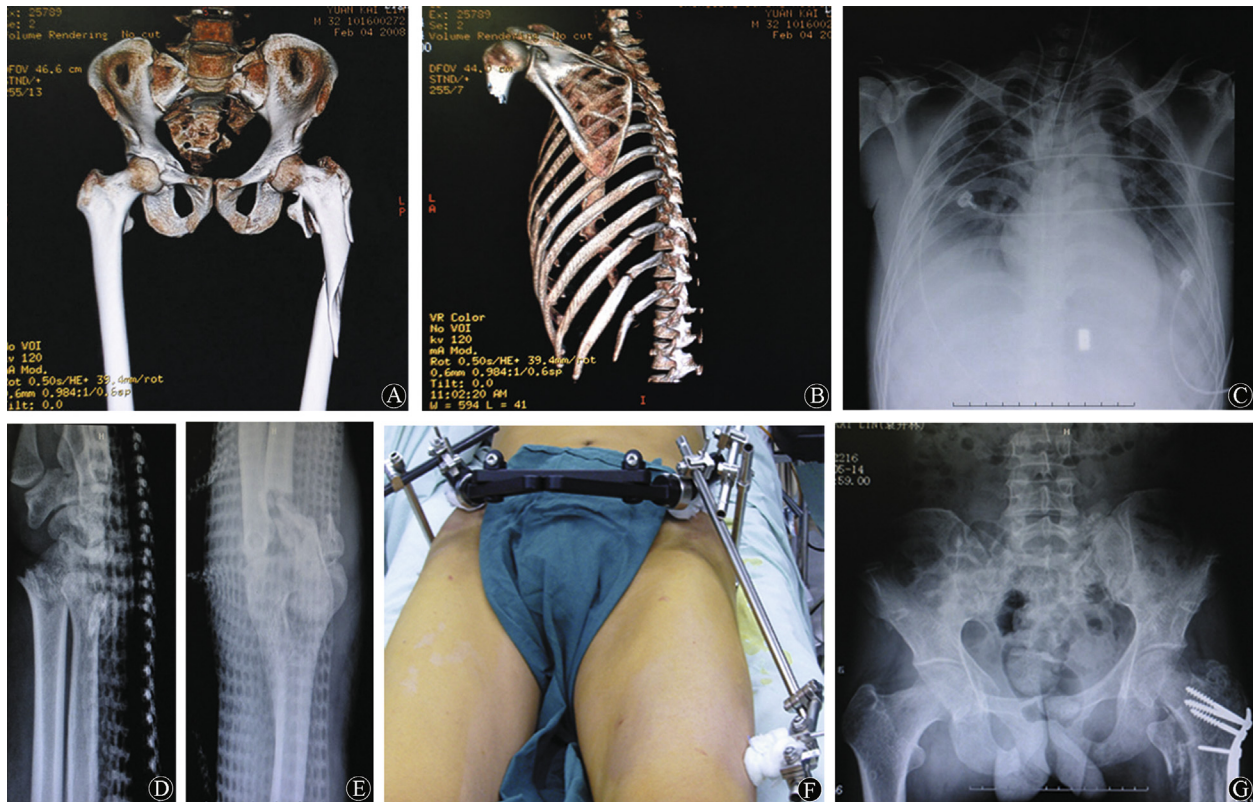
Following placement of the bilateral ureteral catheter, external fixation of the pelvis and left femur were performed (Fig. 1F). Ten days after surgery, the patient was discharged from the intensive care unit with good renal function and open reduction and internal fixation for the fracture of distal end of the left radius, proximal end fracture of the left femur. The pelvic fracture was thought to be stabilized with external fixation and no open reduction and internal fixation (ORIF) was performed. Further healing was uneventful. One month following the injury, the patient was released from our department and transferred to the department of rehabilitation for functional recovery. Four month after discharge, X-ray examination showed healing of the pelvic fracture (Fig. 1G).

### Case two

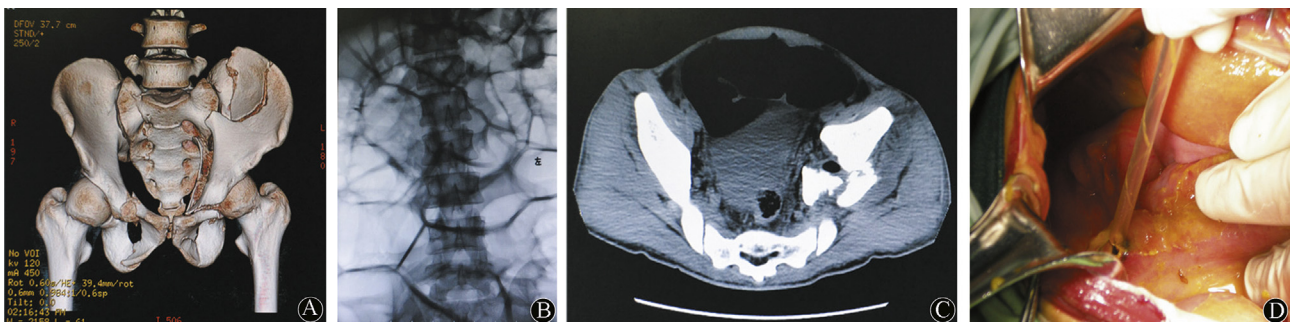
The second case involved in a 19-year old man who was injured in a traffic accident, but the victim failed to describe how he was injured. After injury, he was admitted to a level II hospital and demonstrated pain of the left shoulder, waist, and pelvis. The vital signs were normal. CT examination revealed AO/OTA type 61.A2.2 pelvic fracture, left AO/OTA type 62.A3.2 acetabulum fracture (Fig. 2A), and left rib fracture and hemato-pneumothorax. Pelvic external fixation and closed drainage of the thoracic cavity were performed. In the next few days the patient became febrile (range from 37.8 °C to 38.6 °C); the cause was considered to be absorbed fever of damaged tissues. However, his high fever did not resolve in the next 27 days following injury. In addition, abdominal pain developed day 4 after injury and physical examination found no obvious signs of peritoneal irritation. Anal exhaust and defecation were normal. Abdominal X-ray revealed severe distention but no free gas or fluid. Due to the unknown origin of fever and potential of infection, internal fixation and pelvic fixation were not performed, and the patient was transferred to our hospital for further treatment. Again, X-ray radiology found severe bowel distention but no free gas and fluid in the abdomen (Fig. 2B); however, CT examination showed that a small segment of bowel was entrapped in the fracture fragments (Fig. 2C). Immediate laparotomy was performed. The entrapped bowel had perforated and was put outside of the abdomen (Fig. 2D). Seven days after laparotomy, the high fever resolved and ORIF of the acetabulum fracture were performed through posterior approach. No fever developed and the patient was discharged. The next 3 months were uneventful and the patient was re-admitted for bowel reconstruction.

### Case three

A 25-year-old man was hit in the lower abdomen and groin region directly by a car with a speed of 50 miles per hour. He was admitted to a primary hospital close to the scene following the accident. At admission, the patient's heart rate was 100 beats per minute, blood pressure 95/65 mmHg, and Glasgow coma scale score 14; X-ray and CT scan revealed pelvic fracture (data were not obtained from this hospital). Eight hours later, he presented with severe pain, swelling, and weakened pulse of the left lower extremity. Injury to the main arteries of the lower limb extremity was suspected, and the patient was transferred to our department 12 h



**Fig. 1.** The patient suffered from ureteral obstruction caused by abdominal compartment syndrome. A: CT examination of the pelvis and the femur after injury. B: CT examination of the thoracic cage after injury. C: X-ray examination of the thoracic cage after injury. D: X-ray examination of the forearm after injury. E: X-ray examination of the elbow after injury. F: External fixation was performed to fix the pelvis and the femur. G: X-ray examination at the 4th month after injury revealing healed pelvic fracture.



**Fig. 2.** The patient suffered from bowel entrapment. A: CT examination of the pelvis. B: X-ray examination of the abdomen at the 28th day after injury when the patient was transferred to our hospital. C: CT examination of the pelvis at the 28th day after injury when the patient was transferred to our hospital. D: Entrapped bowel was found perforated.

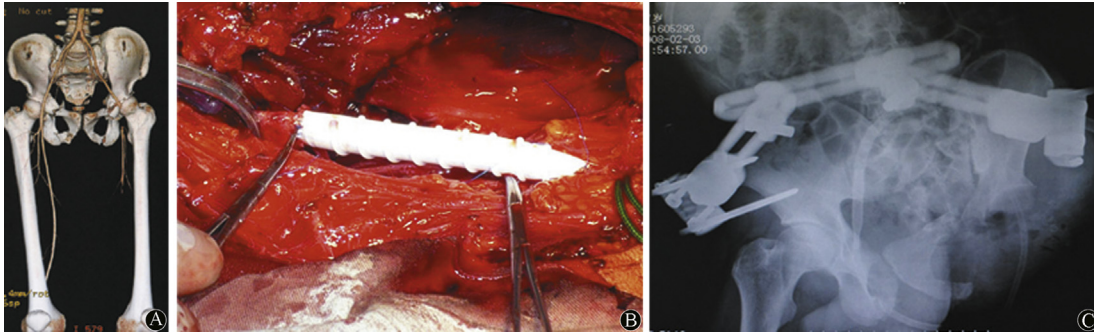
following the injury. He exhibited high fever with normal heart beat, blood pressure, and breath rate. Physical examination found contusion and ecchymosis in the groin region, and femoral and pedal pulse could not be detected. The muscles of the limb were soft. Angiography along with CT showed disruption of external iliac artery and bilateral pubic ramus fracture (AO/OTA type 61 A2.3, Fig. 3A), and lab examination showed slight elevation of serum creatinine (CRE) and blood urea nitrogen (BUN). Exploration of the groin region was performed and a 2-cm long thrombus was observed in the left proximal external iliac artery. The embolic artery was then excised and artificial blood vessel prosthesis transplantation was performed (Fig. 3B). In the 4th day following surgery, the patient developed high fever with increased serum CRE and blood BUN. Severe pain developed in the left lower extremity, followed by no sense of feeling. The thigh and leg became

stiff and hence amputation was performed to save his life (Fig. 3C). The patient recovered completely without signs of impairment to the kidney and other organs. Ten days following surgery he was discharged. The most recent follow-up visit was 1 year after injury. The patient used a wheelchair for ambulation. His only complaint is occasional phantom limb pain.

#### Case four

A 57-year old man was lying in rest on a sloped lawn with his legs open when he was struck onto the groin region by the rear part of a backing truck with a speed of approximately 15 miles per hour. He was admitted to the closest hospital 1 h after injury. On admission, his vital signs were stable. Physical examination found bleeding in the groin region and an open scrotum wound. X-ray radiology

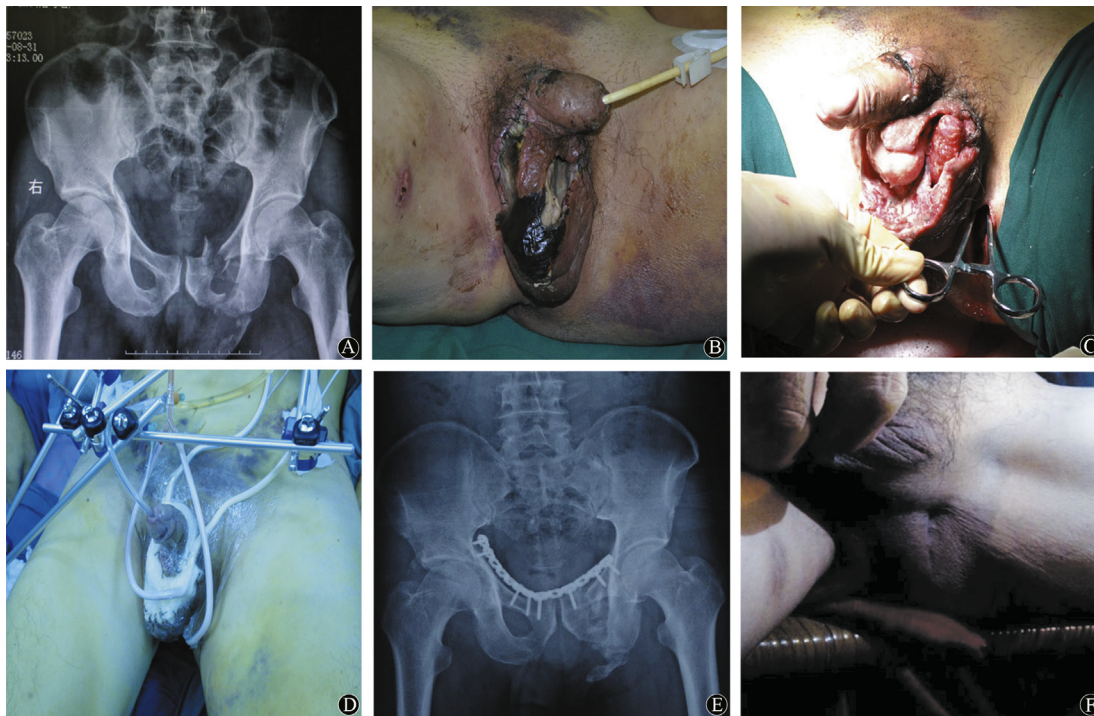



**Fig. 3.** The patient suffered from external iliac artery injury along with pelvic fracture. A: CT and angiography examinations of the pelvis and the lower extremities. B: Artificial blood vessel prosthesis transplantation was performed during the first operation. C: X-ray of the pelvis after amputation.

revealed fracture of the left pubic rami and right acetabulum (Fig. 4A). Debridement and suture of the wounded scrotum were performed and external fixation was applied to fix the pelvis. Three days later, the man became febrile (range from 38.1 °C to 39.9 °C) and the groin region exhibited an unpleasant smell. No measures were taken and the high fever did not resolve. Eight days after injury, the patient was transferred to our hospital for further treatment. On admission, physical examination found high fever, normal blood pressure, high heart rate (96–115 beat/minute) and high breath rate (16–25/min). Part of the scrotum became necrotic, and abscess was observed in the sutured scrotum (Fig. 4B), and thus emergent debridement was performed. A large quantity of abscesses was found in the sutured wound and was flushed out. The blood supply of both testes was confirmed well. The displaced fracture fragments of the pubic rami could be touched through the open wound

(Fig. 4C). After thorough debridement, vacuum sealing drainage was performed (Fig. 4D). The patient's high fever subsided gradually over the next 3 days following the operation. Two more operations were performed to remove and replace the new vacuum sealing drainage 6 and 12 days following the first operation, respectively. Six days later, the wound was clean, a large amount of granulated tissue developed, and the wound was closed. ORIF of the pelvic and acetabulum fracture was performed via the Stoppa approach simultaneously (Fig. 4E). The patient recovered completely without any signs of infection and was discharged 10 days later. The most recent follow-up visit was 5 months after the last surgical operation, and the patient had not infection of the scrotum and wound healed completely (Fig. 4F). X-ray revealed a healing fracture. The patient told us that he had a normal erectile function and had normal sexual intercourse one week prior to the last follow-up.



**Fig. 4.** The patient suffered from open scrotal sac injury along with pelvic fracture. A: X-ray examination of the pelvis after injury. B: The appearance of the groin region when the patient was transferred to our hospital. C: The pelvic fracture fragments could be touched through the open wound during the operation. D: Thorough debridement, vacuum sealing drainage and external fixation of the pelvis were performed. E: X-ray examination of the pelvis after open reduction and internal fixation of the pelvic fracture. F: The appearance of the groin region at the last follow-up.

## Discussion

*Combined measures should be employed to prevent the occurrence of ACS after pelvic fracture and ureteral catheter support is potentially a good option at the early stage of ACS when the kidney is the only affected organ*

Intra-abdominal hypertension (IAH) is defined as intra-abdominal pressure (IAP) >12 mmHg. ACS is defined as IAP above 20 mmHg with the evidence of organ dysfunction/failure.<sup>4</sup> ACS/IAH affects all body systems, in particular the cardiac, respiratory, renal, and neurologic systems, as a result of the blockage of blood flow.<sup>4</sup> Under these circumstances, abdominal decompression is indicated to reverse end-organ failure and minimize intra-abdominal hypertension-related morbidity and mortality.<sup>5,6</sup>

The origin of ACS can be divided into retroperitoneal, intra-peritoneal, parietal, and intestinal types. Although it is less common, ACS accompanying pelvic fracture has been previously reported.<sup>7,8</sup> The prevention of ACS in pelvic fracture is very important since ACS leads to severe morbidity regardless of what measures are taken. Combined measures have been established in our department to prevent the occurrence of ACS in pelvic fractured patients. We routinely perform digital subtraction angiography (DSA) in patients with major pelvic fracture following successful fluid resuscitation. When bleeding from arterial branches is identified, transcatheter arterial embolization (TAE) is performed, which can control arterial bleeding in most cases.<sup>3,9</sup> External fixation is performed to minimize bleeding from unstable fracture fragments.<sup>3</sup> Regarding bleeding from venous vessels of the presacral plexus, a stable hemodynamics can generally be achieved using the tamponade effect of the retroperitoneum. In extremely rare conditions, if the retroperitoneum is damaged and the tamponade effect does not exist, retroperitoneal packing is indicated.<sup>3,10</sup> Also, in the resuscitation stage, the mean arterial pressure (MAP) was maintained at approximately 80 mmHg, which is sufficient to provide blood supply to vital organs and reduce bleeding and the incidence of ACS because large/aggressive volume fluid resuscitation is one of predisposing factors for IAH/ACS.<sup>11</sup>

Utilizing the above-mentioned measures, we managed to reduce bleeding and limit the development of retroperitoneal hematoma. But even so, massive retroperitoneal hematoma and ACS have been formed and lead to bilateral ureteral obstruction and renal failure as reported in the current study. Under these circumstances, Hessmann et al<sup>8</sup> advocated evacuation of the retroperitoneal hematoma, whereas Flint et al<sup>12</sup> suggested that bilateral tube nephrostomy was a better option. Flint<sup>12</sup> and Rothenberger et al<sup>13</sup> believed that, because of the increased risk of sepsis and further hemorrhage, surgical exploration of the retroperitoneum to remove the hematoma should be avoided. In our cases, we selected bilateral ureteral catheter support to rescue renal function. Mohmand et al<sup>11</sup> suggested that acute kidney injury exhibits early and frequent consequences of IAH/ACS and can be present at relatively low levels of intra-abdominal pressure (IAP). It is also reported that at least several hours are required from the onset of ACS before irreversible respiratory dysfunction, cardiac dysfunction, and ischemia of the intra-abdominal organs occur.<sup>7</sup> Thus, if IAP does not increase continuously and remains less than 30 mmHg and no other systems or organs are affected by ACS, ureteral catheter support is a good option to cope with postrenal renal failure. However, when IAP continues to increase, or other organs are afflicted, opening the abdomen is warranted.<sup>14</sup>

In summary, combined measures, including digital subtraction angiography and embolism (if necessary), external fixation of the

pelvic ring, and controlling MAP at the proper level should be used to limit the development of retroperitoneal hematoma and to prevent the occurrence of ACS. At the early stage of ACS when only the urinary system is afflicted with IAP less than 30 mmHg, and no signs of other organ injury or failure, bilateral ureteral catheter support to rescue renal function can be used to save renal function. However, when IAP continues to increase, or other organs are afflicted, open the abdomen is mandatory.

*Sufficient awareness and contrasted CT examination are keys to the diagnosis of bowel entrapment following pelvic fractures*

Disruption of the bowel following pelvic fractures is relatively common.<sup>15</sup> The typical symptoms included peritoneal irritation, shock, and severe sepsis, making them easily diagnosed. In contrast, bowel entrapment is a rare complication in pelvic fracture. It is difficult to diagnose due to its clinical complexity, and the difficulty in distinguishing the adynamic ileus from bowel entrapment. In 24 such cases reported in the literature, the diagnosis were delayed in six cases.<sup>16–19</sup> Four cases of bowel entrapment were diagnosed during laparotomy, which was performed during the initial management of trauma. Of the remaining cases, the average time to diagnosis was 14.9 days (range 2–90 days). It is extremely difficult to diagnose when the entrapped bowel is only part of the bowel, as reported in the present case, due to the atypical symptoms. Delayed diagnosis and treatment often lead to severe sepsis and death.<sup>16–19</sup>

CT is generally considered a sensitive tool for the diagnosis of bowel entrapment. Combined use of oral and IV contrast in CT evaluation may increase diagnostic accuracy and reduce morbidity in patients with blunt abdominal injury.<sup>17,20</sup> However, caution and sufficient awareness are the principal determining factors to establish the correct diagnosis of bowel entrapment. If progressive ileus in a patient with a pelvic fracture persists for over 3 days, an occult bowel injury such as entrapment at the fracture site, should be suspected and contrasted CT should accordingly be performed.

Immediate laparotomy is recommended as long as the diagnosis is determined to repair or resect the entrapped bowel. The pelvic fracture should usually be fixed externally at the initial stage due to risk of infection. Definite internal fixation may be considered if no signs of potential infection develop.

*Sufficient awareness, recognition of risk factors, early diagnosis, and prompt treatment of suspected injury of the external iliac artery and its branches are keys to patient survival and to avoidance of limb loss*

The majority of pelvic injuries are not associated with significant bleeding. Most pelvic hemorrhages are thought to be caused by injury to small arteries or veins in the fractured cancellous pelvic bone or in the surrounding soft tissues, and only 6%–18% of patients with unstable pelvic fractures exhibit hemorrhage from large arteries.<sup>21</sup> When arterial injuries are present, the majority involve in branches of the internal iliac artery. There are only a few published reports of injuries to the branches of the external iliac artery, and fewer to the external iliac artery itself.<sup>22–24</sup> Injuries to the external iliac artery and its branches, such as the case described here, are thought to be extremely rare in pelvic fractures. The reason is due to the lower incidence of such complications, and diagnosis is sometimes delayed, thus increasing the risk of loss of both life and limb.<sup>22</sup>

Recognition of the risk factors for injury of the external iliac artery and its branches in pelvic fractures is helpful to make a correct diagnosis. Firstly, external iliac arterial injury should be

highly suspected in some injury patterns of pelvic fractures. Manson et al<sup>22</sup> suggested that caudal displacement of the hemipelvis in rare conditions disrupts the pelvic floor and pelvic vasculature far more than a standard vertical shear injury. It is reported that caudal displacement of the hemipelvis leads to significant disruption of the external iliac artery and to surgical hemipelvectomy. Pubic rami fracture is another pelvic fracture pattern in which the branch of external iliac artery (inferior epigastric artery or corona mortis) is highly susceptible to injury, even if the fracture is stable.<sup>23,24</sup> Secondly, anatomical variation is another factor for rare bleeding. The aberrant obturator artery (AOA) is a common arterial variant that occurs in more than half of the population and, if present in pelvic fractured patients, is commonly injured.<sup>25,26</sup> Thirdly, pre-injury medical conditions, such as anticoagulation treatment, are risk factors for external iliac artery injury.<sup>24</sup> Lastly, direct violence to the groin region as reported in the current study is a high risk factor for injury of the external iliac artery and its branches.

Although the incidence of external iliac artery injury is rare, the diagnosis is not difficult. The diagnosis of such injuries is based on clinical findings and confirmed by angiography. The key to correct diagnosis is sufficient awareness.<sup>24</sup> Delayed diagnosis leads to poor outcome. In our case, although the patient was grateful to be alive, we understood that the lost extremity could have been saved if early diagnosis had been established.

When injury of the external iliac artery and its branches is confirmed, TAE, endovascular blunting repair, open vascular reconstruction, and prosthetic bypass graft should be selectively performed.<sup>27–29</sup>

*Scrotal and/or testicular injury complicated by pelvic fracture is a rare condition that should be carefully treated to maintain normal gonad function*

During wartime, the incidence of scrotal and/or testicular injury complicated by pelvic fracture is high.<sup>30</sup> In contrast, the incidence of scrotal and/or testicular injury is rare in civilian injuries, and usually occurs in a situation called fuel tank injury. It is a rare condition involving motorcycle driver impact.<sup>31–34</sup> In our case, the mechanism of injury was not fuel tank injury. It was caused by direct crash into the groin region when two legs of the patient were open.

In open scrotal and/or testicular injury, the diagnosis is easy to establish; however, in closed injury, high suspicion, thorough physical examination and Doppler ultrasound are useful for correct diagnosis. The extent of soft tissue injury should be classified by multi-modality and multi-planar imaging so that correct treatment may be applied.<sup>35</sup>

Injuries to the scrotum and its contents may cause impaired fertility, chronic pain, hypogonadism, and altered self-image<sup>36</sup>; thus, selection of treatment is highly important. If an open wound exists, primary suture of the wound is not recommended, and debridement and vacuum sealing drainage are suggested to avoid infection.<sup>37,38</sup> However, aggressive debridement should be avoided if the patient is associated with pubic ramus fracture close to or connected to the scrotal wound, as reported in the current case. Aggressive debridement may lead to exposure of the fracture fragments or severe retroperitoneal infection. Also, when vacuum sealing drainage is applied, the pressure should be monitored to avoid testis necrosis caused by too high pressure. External fixation of the pelvic fracture along with simple reduction of the significantly displaced pubic ramus fracture is recommended. In closed injury, dislocation of testis should be replaced. In both open and closed injuries, the testis should be excised if it has been necrotic.

*Sophisticated trauma care system and multi-disciplinary coordination are important for the care of rare complications in pelvic fractures*

In North America, most European countries, and Japan in Asia, sophisticated trauma care systems have been established in the past couple of decades. In mainland China, greater attention is paid to the treatment of public health problems and trauma care remains in a nascent stage in small cities and rural and semi-urban areas.<sup>39</sup> Thus, many injured patients have a high chance of incorrect diagnosis and treatment when they are admitted to a lower level hospital. Three of the four cases reported in the current study did not receive proper care at the initial stage after trauma. These situations may also be true in other developing counties, and may only be solved through the establishment of a sophisticated trauma care system.

Another issue for the care of rare complications of pelvic fractures is multi-disciplinary coordination. Rare complications or associated injuries of pelvic fractures can be highly complex; thus, coordination is warranted to achieve prompt and correct diagnosis and treatment.<sup>2</sup>

## Conclusions

Rare complications of pelvic fracture are difficult to diagnose, and failure to make a correct diagnosis usually results in poor outcome. High suspicion and sufficient awareness are the principal elements that lead to correct diagnosis and treatment. Also, multi-disciplinary coordination is required under such circumstances.

## Fund

This study was supported by the National Science Foundation of China (81271935), Foundation of State Key Laboratory of Trauma, Burns and Combined injury (SKLZZ SKLZZ201124), and The Military Medical Research Foundation of China (AWS11J008).

## References

- Schmal H, Hauschild O, Culemann U, et al. Identification of risk factors for neurological deficits in patients with pelvic fractures. *Orthopedics*. 2010;33:625.
- Figler B, Hoffler CE, Reisman W, et al. Multi-disciplinary update on pelvic fracture associated bladder and urethral injuries. *Injury*. 2012;43:1242–1249.
- Cullinane DC, Schiller HJ, Zielinski MD, et al. Eastern association for the surgery of trauma practice management guidelines for hemorrhage in pelvic fracture—update and systematic review. *J Trauma*. 2011;71:1850–1868.
- Papavramidis TS, Marinis AD, Pliakos I, et al. Abdominal compartment syndrome – intra-abdominal hypertension: defining, diagnosing, and managing. *J Emerg Trauma Shock*. 2011;4:279–291.
- Parmeggiani D, Gubitosi A, Ruggiero R, et al. The abdominal compartment syndrome: review, experience report and description of an innovative biological mesh application. *Updates Surg*. 2011;63:271–275.
- Hedenstierna G, Larsson A. Influence of abdominal pressure on respiratory and abdominal organ function. *Curr Opin Crit Care*. 2012;18:80–85.
- Hagiwara A, Fukushima H, Inoue T, et al. Brain death due to abdominal compartment syndrome caused by massive venous bleeding in a patient with a stable pelvic fracture: report of a case. *Surg Today*. 2004;34:82–85.
- Hessmann M, Rommens P. Bilateral ureteral obstruction and renal failure caused by massive retroperitoneal hematoma: is there a pelvic compartment syndrome analogous to abdominal compartment syndrome? *J Orthop Trauma*. 1998;12:553–557.
- Bozeman MC, Cannon RM, Trombold JM, et al. Use of computed tomography findings and contrast extravasation in predicting the need for embolization with pelvic fractures. *Am Surg*. 2012;78:825–830.
- Tai DK, Li WH, Lee KY, et al. Retroperitoneal pelvic packing in the management of hemodynamically unstable pelvic fractures: a level I trauma center experience. *J Trauma*. 2011;71:79–86.
- Mohmand H, Goldfarb S. Renal dysfunction associated with intra-abdominal hypertension and the abdominal compartment syndrome. *J Am Soc Nephrol*. 2011;22:615–621.
- Flint P, Allen CF. Pelvic fracture complicated by bilateral ureteral obstruction: case report. *J Trauma*. 1994;36:285–287.



13. Rothenberger D, Fischer R, Strale R. The mortality associated with pelvic fractures. *Surgery*. 1978;84:356–361.
14. Chiara O, Cimbanassi S, Boati S, et al. Surgical management of abdominal compartment syndrome. *Minerva Anesthesiol*. 2011;77:457–462.
15. Kekez T, Augustin G. Small bowel entrapment associated with pelvic fracture: a case report with review of the literature and differentiation of clinical picture. *Eur J Emerg Med*. 2012;19:60–61.
16. Kuhnke M, Ross DS, Edwards M, et al. Bowel entrapment following pelvic fracture. A case report. *Orthopedics*. 1989;12:1115–1117.
17. Walcher F, Rose S, Roth R, et al. Double traumatic abdominal wall hernia and colon laceration due to a pelvic fracture. *Injury*. 2000;31:253–256.
18. Kim WY, Ryu JD, Choi MS, et al. Bowel herniation after traumatic symphysis pubis diastasis. *J Orthop Trauma*. 2001;15:445–447.
19. Sharma A, Jain PK, Shaw CJ, et al. Successful laparoscopic repair of a traumatic pubic symphysis hernia. *Surg Endosc*. 2004;18:345–349.
20. Ritchie ED, Veen EJ, Olsman J, et al. A case of bowel entrapment after penetrating injury of the pelvis: don't forget the omentoplasty. *Scand J Trauma Resusc Emerg Med*. 2011;19:34.
21. Tötterman A, Madsen JE, Røise O. Multifocal arterial haemorrhage in a partially stable pelvic fracture after a crush injury: a case report. *Arch Orthop Trauma Surg*. 2006;126:113–117.
22. Manson TT, Nascone JW, O'Toole RV. Traction vertical shear pelvic ring fracture: a marker for severe arterial injury? a case report. *J Orthop Trauma*. 2010;24:90–94.
23. Loffroy R, Yeguiayan JM, Guiu B, et al. Stable fracture of the pubic rami: a rare cause of life-threatening bleeding from the inferior epigastric artery managed with transcatheter embolization. *CJEM*. 2008;10:392–395.
24. Garrido-Gómez J, Pena-Rodríguez C, Martín-Noguerol T, et al. Corona mortis artery avulsion due to a stable pubic ramus fracture. *Orthopedics*. 2012;35:e80–82.
25. Ferrada PA, Jain K. Aberrant obturator artery: a hidden threat after pelvic fracture. *Am Surg*. 2011;77:126.
26. Requarth JA, Miller PR. Aberrant obturator artery is a common arterial variant that may be a source of unidentified hemorrhage in pelvic fracture patients. *J Trauma*. 2011;70:366–372.
27. Balogh Z, Vörös E, Süveges G, et al. Stent graft treatment of an external iliac artery injury associated with pelvic fracture. A case report. *J Bone Jt Surg Am*. 2003;85:919–922.
28. Carrillo EH, Wohltmann CD, Spain DA, et al. Common and external iliac artery injuries associated with pelvic fractures. *J Orthop Trauma*. 1999;13:351–355.
29. Brown SD, Ryan JM. Traumatic injury of the pelvis causing compression and acute critical stenosis of a common iliac artery stent with resultant critical leg ischemia: successful treatment with transbrachial balloon angioplasty: case report. *J Trauma*. 2003;54:190–192.
30. Mossadegh S, Tai N, Midwinter M, et al. Improvised explosive device related pelvi-perineal trauma: anatomic injuries and surgical management. *J Trauma Acute Care Surg*. 2012;73:S24–S31.
31. Ihama Y, Fuke C, Miyazaki T. A two-rider motorcycle accident involving injuries around groin area in both the driver and the passenger. *Leg Med (Tokyo)*. 2007;9:274–277.
32. Tauber M, Joos H, Karpik S, et al. Urogenital injuries accompanying pelvic ring fractures. *Unfallchirurg*. 2007;110:116–123.
33. Tsai HN, Wu WJ, Huang SP, et al. Bilateral traumatic testicular dislocation—a case report. *Kaohsiung J Med Sci*. 2002;18:95–98.
34. Smith CS, Rosenbaum CS, Harris AM. Traumatic bilateral testicular dislocation associated with an anterior posterior compression fracture of the pelvis: a case report. *J Surg Orthop Adv*. 2012;21:162–164.
35. Hammond CJ, Barron DA, Spencer J. Extensive perineal soft tissue disruption with 'open-book' pelvic fracture. *Emerg Radiol*. 2007;15:277–280.
36. Ozumba D, Starr AJ, Benedetti GE, et al. Male sexual function after pelvic fracture. *Orthopedics*. 2004;27:313–318.
37. Govaert G, Siriwardhane M, Hatzifotis M, et al. Prevention of pelvic sepsis in major open pelvipereineal injury. *Injury*. 2012;43:533–536.
38. Labler L, Trentz O. The use of vacuum assisted closure (VAC) in soft tissue injuries after high energy pelvic trauma. *Langenbecks Arch Surg*. 2007;392:601–609.
39. Zong ZW, Li N, Cheng TM, et al. Group for trauma emergency care and multiple injuries, trauma society of Chinese medical association. Current state and future perspectives of trauma care system in mainland China. *Injury*. 2011;42:874–878.