

Available online at www.sciencedirect.com

ScienceDirect

journal homepage: www.elsevier.com/locate/radcr

Case report

Inferior vena cava filter fracture with strut migration on CT with volume rendering [☆]

Pierce M. Cooper, BS^{*}, Pierre Maldjian, MD, Pratik Shukla, MD

Department of Radiology, Rutgers New Jersey Medical School, 185 South Orange Avenue, Newark, NJ, 07103

ARTICLE INFO

Article history:

Received 1 July 2021

Accepted 7 July 2021

Keywords:

IVC filter fracture

IVC filter migration

IVC filter integrity

Volume rendered CT images

Volumetric 3D imaging

ABSTRACT

We present the computed tomography findings in a patient with a fractured IVC filter and migration of a broken strut to the right lower quadrant. The filter morphology and strut fragment are well demonstrated on volume rendered images confirming the value of volumetric 3D computed tomography imaging to evaluate IVC filter integrity and identify migrated filter fragments.

© 2021 The Authors. Published by Elsevier Inc. on behalf of University of Washington.

This is an open access article under the CC BY-NC-ND license

(<http://creativecommons.org/licenses/by-nc-nd/4.0/>)

Introduction

Deep venous thrombosis can lead to pulmonary embolism, a major cause of morbidity and mortality. First line treatment for Deep venous thrombosis is anticoagulation therapy with heparin, warfarin or direct oral anticoagulants. Inferior Vena Cava (IVC) filters are used to prevent pulmonary embolism if anticoagulants are contraindicated or unsuccessful [1]. Complications of IVC filters include filter fracture, filter or strut migration/embolization, IVC perforation and IVC thrombosis [2]. The rate of filter complication increases the longer the filter is in place [3,4]. Hence, retrievable or temporary IVC filters have been developed to facilitate removal when patients can tolerate anticoagulation or are no longer at risk for thromboembolic disease [5].

We present the computed tomography (CT) findings in a patient with a fractured IVC filter and migration of a broken strut to the right lower quadrant. The filter morphology and strut fragment are well demonstrated on volume rendered images confirming the value of volumetric 3D CT imaging to evaluate IVC filter integrity and identify migrated filter fragments.

Case report

A 47-year-old woman presented to our emergency department with a two-day history of vomiting and abdominal pain. Fifteen years prior the patient had undergone a caesarian delivery due to arrest of labor. Her post-operative course at that

[☆] Competing of interest: There is no declaration of interest.

^{*} Corresponding author.

E-mail address: pmc171@njms.rutgers.edu (P.M. Cooper).

<https://doi.org/10.1016/j.radcr.2021.07.018>

1930-0433/© 2021 The Authors. Published by Elsevier Inc. on behalf of University of Washington. This is an open access article under the CC BY-NC-ND license (<http://creativecommons.org/licenses/by-nc-nd/4.0/>)

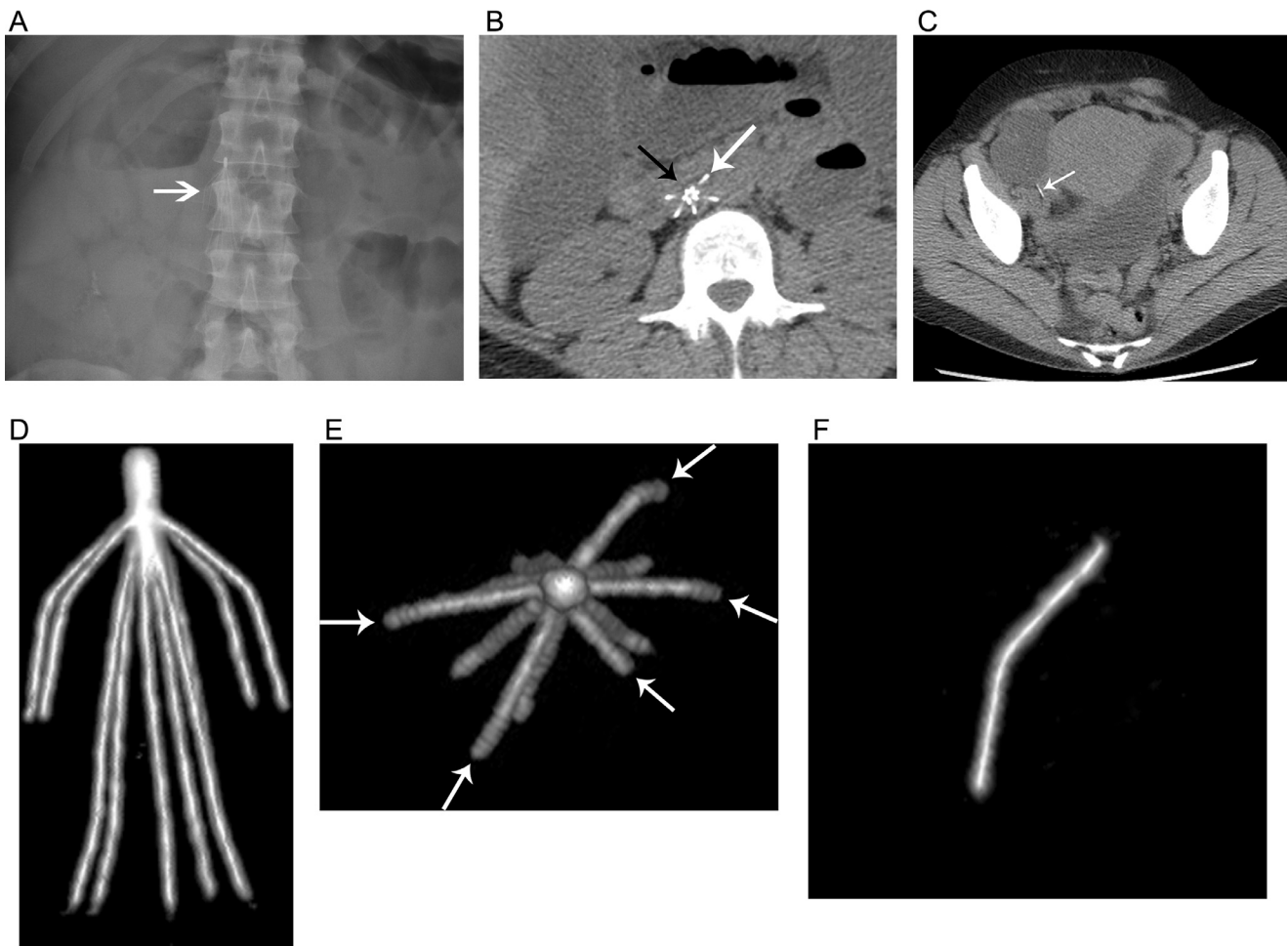


Fig. 1 – 47-year-old woman with fractured IVC filter. **A:** Radiograph of the abdomen shows IVC filter (arrow) to the right of the second lumbar vertebral body. It is difficult to discern the integrity of the filter struts on this view. **B:** Axial image at the level of the filter from abdominal CT shows 6 central struts but only 5 peripheral struts. White arrow indicates peripheral strut at 1 o'clock position. Note absence of peripheral strut at 11 o'clock position (black arrow). **C:** Axial image through the pelvis shows a linear metallic fragment (arrow) in the right lower quadrant. **D:** Volume-rendered image from a frontal perspective shows the morphology of the IVC filter. **E:** Volume-rendered image of filter from top-down perspective shows 5 peripheral struts (arrows) and confirms absence of strut at 11 o'clock position. **F:** Volume-rendered image of metallic fragment in right lower quadrant confirms that it represents the missing IVC filter strut.

time was complicated by a pulmonary embolism which necessitated treatment with anticoagulants. She subsequently developed small bowel obstruction requiring surgical intervention. Prior to surgery anticoagulation was discontinued and a Recovery IVC filter (C.R. Bard, Covington, GA) was placed. The patient recovered after successful surgical treatment of her small bowel obstruction and was lost to follow-up until the current presentation.

At this time, due to suspicion for recurrent small bowel obstruction, a CT scan of the abdomen was performed. As the patient had chronic renal insufficiency, no intravenous contrast was administered. The CT scan demonstrated dilated small bowel with air fluid levels consistent with small bowel obstruction. In addition, the CT study showed the patient's infrarenal IVC filter as well as a linear metallic fragment in the right lower quadrant (Fig. 1). Volume reformatted images confirmed that one of the filter's 6 external struts had broken off

and that the metallic density in the right lower quadrant was the broken strut. Laparotomy confirmed recurrent small bowel obstruction due to adhesions. The small bowel obstruction was believed to be unrelated to the broken strut. The patient recovered uneventfully and was discharged. The patient was scheduled for follow-up with interventional radiology clinic for management of her IVC filter.

Discussion

IVC filters can be used to prevent pulmonary embolism when anticoagulation is either contraindicated or unsuccessful. Permanent filters remain in place indefinitely, while retrievable filters can be removed when no longer indicated. Complications of indwelling IVC filters include migration of the entire

filter, tilt or shift of the filter, strut fracture, IVC perforation, embedding, and thrombosis [2].

Strut fractures have the potential to cause serious complications with migration to the heart and pulmonary arteries [6,7]. A prior study of Bard Recovery filters showed overall fracture rate of 7% at an average follow up time of 18 months. The earliest fracture occurred 4 months after implantation and fracture rate increased over time with a predicted fracture rate of 40% at 5 years [3]. Fracture rates of newer generation filters have been reported as low as less than 1% [8].

Filter penetration through the IVC wall is also common and increases over time. Penetration of a primary leg greater than 3mm outside the IVC wall has been reported in 39% of cases at 30 days and 80% of cases at 90 days after placement of Celect filters (Cook Medical, Bloomington, IN) [4]. Penetration of the IVC is most often benign but can result in aortic penetration and pancreatitis when the filter comes in contact with nearby structures [9,10]. Filter perforations can also extend into the peritoneal cavity [11,12]. In the case presented we believe the fractured strut penetrated the IVC into the peritoneal cavity and settled in the right lower quadrant. As complication rates increase with time, removal of a retrievable filter is advised when the filter is no longer necessary. Despite recommendations for removal, overall filter retrieval rates have been between 12%-45% [2].

IVC filter integrity can be difficult to assess on radiographic examination. Due to the risk of complications over time and low rate of filter retrieval, it is essential to assess the structure of an IVC filter whenever one is identified on CT. Filter morphology and integrity are easily evaluated with volumetric 3D reconstructions of the filter itself. Our case also shows that fractured filter fragments can be definitively identified on volumetric CT images. While prior case reports have described CT findings in cases of damaged IVC filters and migrated filter fragments, to our knowledge, ours is the first to depict an incidental strut fracture within the peritoneal cavity with volume rendered CT images [6,7,13,14].

In conclusion, given the risks of strut fracture, perforation and migration with longstanding IVC filters, we recommend that when these devices are identified on CT, imagers consider evaluating filter integrity with volume rendered CT to more readily identify complications.

Patient consent

This case report includes no identifying information of the patient described. All images are anonymized and do not include any identifying marks. No text within the case report can be used to identify the individual concerned.

According to Elsevier patient consent policy

“Formal consents are not required for the use of entirely anonymized images from which the individual cannot be identified- for example, x-rays, ultrasound images, pathology slides or laparoscopic images, provided that these do not con-

tain any identifying marks and are not accompanied by text that might identify the individual concerned.”

If further information regarding the patient consent is required, please contact the corresponding author, Pierce M. Cooper, at pmc171@njms.rutgers.edu.

REFERENCES

- [1] Sarosiek S, Crowther M, Sloan JM. Indications, complications, and management of inferior vena cava filters: the experience in 952 patients at an academic hospital with a level I trauma center. *JAMA Intern Med* 2013;173(7):513–17. doi:10.1001/jamainternmed.2013.343.
- [2] Angel LF, Tapson V, Galgon RE, Restrepo MI, Kaufman J. Systematic review of the use of retrievable inferior vena cava filters. *J Vasc Interv Radiol* 2011;22(11):1522–30 e3PMID: 22024114. doi:10.1016/j.jvir.2011.08.024.
- [3] Tam MD, Spain J, Lieber M, Geisinger M, Sands MJ, Wang W. Fracture and distant migration of the Bard Recovery filter: a retrospective review of 363 implantations for potentially life-threatening complications. *J Vasc Interv Radiol* 2012;23(2):199–205.e1 Epub 2011 Dec 20. PMID: 22188776. doi:10.1016/j.jvir.2011.10.017.
- [4] Zhou D, Moon E, Bullen J, Sands M, Levitin A, Wang W. Penetration of Celect inferior vena cava filters: retrospective review of CT scans in 265 patients. *AJR Am J Roentgenol* 2014;202(3):643–7 PMID: 24555603. doi:10.2214/AJR.13.11097.
- [5] Grande WJ, Trerotola SO, Reilly PM, Clark TW, Soulen MC, Patel A, et al. Experience with the recovery filter as a retrievable inferior vena cava filter. *J Vasc Interv Radiol* 2005;16(9):1189–93 PMID: 16151059. doi:10.1097/01.RVI.0000171689.52536.FD.
- [6] Mauermann WJ, MC Ross-Huot, Barbara DW, Burkhart HM, Rehfeldt KH. Multimodal imaging of an embolized vena cava filter strut causing right ventricular perforation. *Can J Anaesth* 2014;61(1):80–1 Epub 2013 Oct 17. PMID: 24132410. doi:10.1007/s12630-013-0056-y.
- [7] Kim J. Inferior vena cava filter fracture and migration to the pulmonary artery. *Radiol Case Rep* 2021;16(4):934–7 PMID: 33659032; PMCID: PMC7890090. doi:10.1016/j.radcr.2021.01.061.
- [8] McLoney ED, Krishnasamy VP, Castle JC, Yang X, Guy G. Complications of Celect, Günther tulip, and Greenfield inferior vena cava filters on CT follow-up: a single-institution experience. *J Vasc Interv Radiol* 2013;24(11):1723–9 Epub 2013 Sep 13. PMID: 24041915. doi:10.1016/j.jvir.2013.07.023.
- [9] Gupta P, Lopez JA, Ghole V, Rice GD, Ketkar M. Aortic and vertebral penetration by a G2 inferior vena cava filter: report of a case. *J Vasc Interv Radiol* 2009;20(6):829–32 Epub 2009 May 5. PMID: 19406670. doi:10.1016/j.jvir.2009.02.017.
- [10] Ford ME, Lippert JA, McGraw JK. Symptomatic filter penetration presenting as pancreatitis. *J Vasc Interv Radiol* 2010;21(4):574–6 PMID: 20346885. doi:10.1016/j.jvir.2009.12.394.
- [11] Umoh NJ, Alessi CM, Franklin DP, Udekwo AO. Small bowel volvulus in a quadriplegic: a rare complication of the simon nitinol inferior vena cava filter. *Eur J Trauma Emerg Surg* 2010;36(3):250–3 Epub 2009 Oct 14. PMID: 26815869. doi:10.1007/s00068-009-9113-1.
- [12] Kappa SF, Morgan TM, Keegan KA, Cookson MS. Inferior vena cava filter strut perforation discovered during right robotic-assisted laparoscopic partial nephrectomy. *Urology* 2012;79(4):e49–50 Epub 2011 Oct 19. PMID: 22014963. doi:10.1016/j.urology.2011.08.056.
- [13] Nishikawa T, Oka T, Shioyama W, Kashimoto K, Yasui T, Oboshi M, et al. Fracture of a retrievable inferior vena cava

filter placed for cancer-associated thrombosis in a patient with malignant lymphoma. *Intern Med* 2020;59(5):673–6 Epub 2019 Nov 18. PMID: 31735791; PMCID: PMC7086331. doi:[10.2169/internalmedicine.3671-19](https://doi.org/10.2169/internalmedicine.3671-19).

[14] Mehanni S, Higley M, Schenning RC. Expectoration of an inferior vena cava filter strut. *BMJ Case Rep* 2016 2016:bcr2016218159 PMID: 28011891; PMCID: PMC5237790. doi:[10.1136/bcr-2016-218159](https://doi.org/10.1136/bcr-2016-218159).