

# Arthroscopically Assisted Surgical Decompression and Fibular Strut Grafting for Proximal Humerus Avascular Necrosis: Surgical Technique



Kevin O'Keefe, B.S., Joseph J. King, M.D., Kevin W. Farmer, M.D., and Thomas W. Wright, M.D.

**Abstract:** Avascular necrosis is a relatively common entity that affects the proximal humerus and can lead to substantial morbidity. It often occurs in younger patients for whom the traditional treatment of shoulder arthroplasty is not optimal. Fibular strut grafting to prevent humeral head collapse has been described as a viable treatment option. However, it is technically challenging to direct the fibular strut graft into the center of the bony infarct, where it will be most effective. This paper describes a technique of arthroscopically assisted fibular strut grafting for avascular necrosis of the humerus. This is a minimally invasive technique with low morbidity and an accurate way of placing the graft into the infarcted segment.

In approximately 7% of patients with avascular necrosis (AVN), the proximal humerus is involved and is often bilateral.<sup>1</sup> Although the exact pathophysiology is unknown, atraumatic proximal humeral osteonecrosis has many associated etiologies, including systemic corticosteroid use, alcoholism, sickle cell disease, inflammatory diseases, dysbarism, and coagulation disorders; it also can be idiopathic.<sup>2,3</sup>

Treatment of proximal humeral AVN in the young and symptomatic patient is especially difficult. Conservative treatment is optional; however, a high rate of natural progression to humeral head collapse has been reported.<sup>4-7</sup> Surgical options include arthroscopic

debridement,<sup>3</sup> proximal humeral decompression,<sup>1,8-12</sup> vascularized bone grafting,<sup>13,14</sup> proximal humeral decompression with allograft,<sup>15,16</sup> shoulder resurfacing,<sup>17-21</sup> shoulder hemiarthroplasty,<sup>1,4,22-26</sup> and total shoulder arthroplasty.<sup>1,22-24,26,27</sup> Because of the significant amount of bony involvement, fixation of shoulder resurfacing implants may be inadequate and theoretically can lead to implant loosening. The use of stems in shoulder arthroplasty helps with the fixation problems of shoulder resurfacing; however, more bone resection is required for the use of stems. Shoulder arthroplasty in these young patients is not optimal due to the possible need for a revision in the future secondary to glenoid wear. In addition, mixed clinical results have been reported with shoulder resurfacing and arthroplasty for AVN.<sup>1,2,11,18-20,23-29</sup>

The use of decompression for hip osteonecrosis has had some success, and this treatment option for AVN has been extrapolated to the proximal humerus. Core decompression of the proximal humerus has had moderate success in improved function and pain relief with better results in earlier stages of AVN.<sup>8-10,12,29</sup> The goals of core decompression are to decrease intraosseous pressure and promote revascularization. Issues with decompression of the proximal humeral AVN include difficulties in targeting the lesion and significant weakening of the periarticular and cortical bone.<sup>8-11</sup>

Bone grafting can be added to decompression in an effort to provide stability and possibly a new blood supply when using vascularized autografts. Reports of

From the Department of Orthopaedics and Rehabilitation, University of Florida College of Medicine, Gainesville, Florida, U.S.A.

The authors report the following potential conflicts of interest or sources of funding: K.W.F. is a paid consultant for Exactech and Arthrex and receives royalties from Exactech. J.J.K. is a paid consultant for Exactech. T.W.W. is a paid consultant and receives royalties from Exactech and receives royalties from Wolters Kluwers Health—Lippincott Williams & Wilkins. Full ICMJE author disclosure forms are available for this article online, as [supplementary material](#).

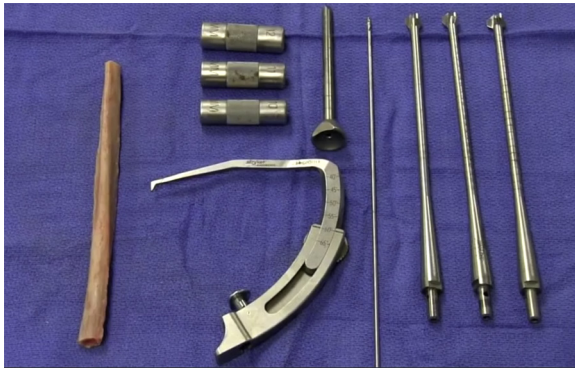
Received June 15, 2020; accepted October 25, 2020.

Address correspondence to Thomas W. Wright, M.D., Department of Orthopaedics and Rehabilitation, P. O. Box 112727, Gainesville, FL 32611-2727. E-mail: [wrightw@ortho.ufl.edu](mailto:wrightw@ortho.ufl.edu)

© 2020 by the Arthroscopy Association of North America. Published by Elsevier. This is an open access article under the CC BY-NC-ND license (<http://creativecommons.org/licenses/by-nc-nd/4.0/>).

2212-6287/201149

<https://doi.org/10.1016/j.eats.2020.10.060>



**Fig 1.** Fibular allograft (left), ACL tip-to-tip guide with guide pin sleeve and graft sizers (center), guide pin, and sequential reamers (right).

vascularized grafts for proximal humerus AVN are limited, and their use adds significant morbidity to the operation. The main issue with bone grafting is the fixation into the proximal humerus with hardware often used to hold the graft in place.<sup>13,14</sup>

We report on a method of proximal humeral decompression and placement of a fibular allograft to address the complex issues associated with this procedure. The addition of a press-fit fibular allograft helps prevent fracture or collapse around the decompression site due to weak proximal humeral bone and is stable because of the interference fit. In addition, this method of targeting the lesion theoretically increases the chance of healing the AVN defect.

### Indications

Proximal humeral decompression and bone grafting should be considered a treatment option for a young patient with localized AVN and pain. Because a significant number of proximal humeral AVN lesions

progress to collapse,<sup>4-7</sup> it has been the senior author's position to offer all young patients with proximal humeral AVN (Cruess stages I-IV) the option of arthroscopic-assisted allograft proximal humeral decompression and fibular strut grafting. This procedure is minimally invasive, has few complications, and has the potential to prevent further collapse in a young person.

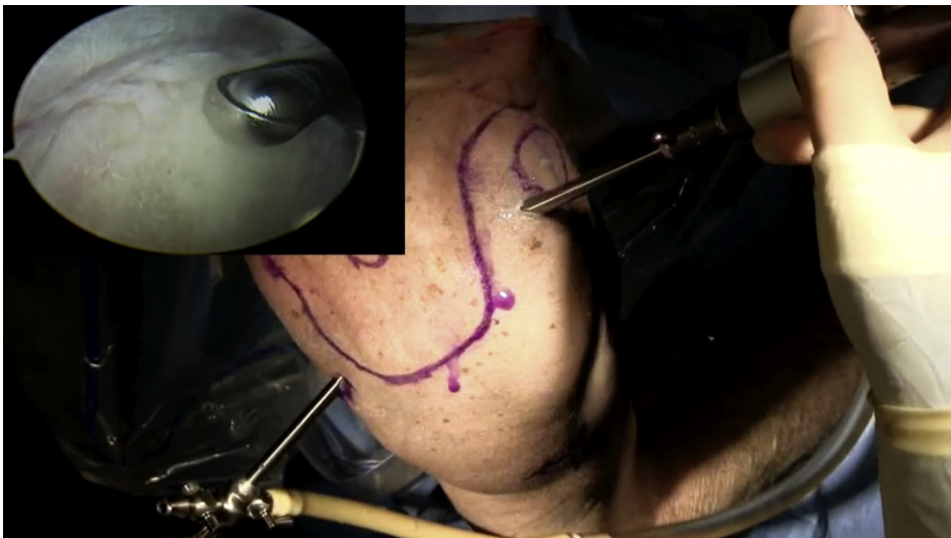### Contraindications

Proximal humeral decompression and bone grafting should not be performed in patients with an active infection. Relative contraindications exist for elderly patients (where an arthroplasty may give a more consistent result), patients with an irreparable rotator cuff tear, patients with extensive grade-IV chondral changes on the humerus, or patients with significant degeneration of the glenoid cartilage.

### Surgical Anatomy

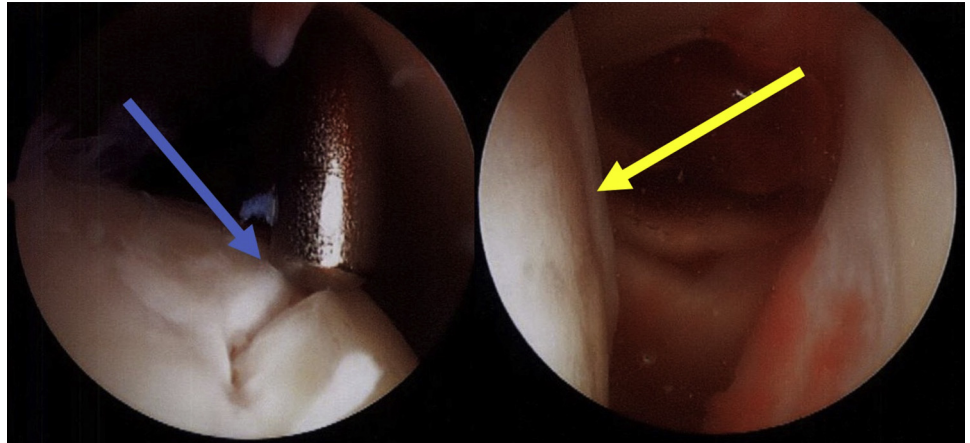
Along with the standard anterior and posterior arthroscopic portals, a mini-deltopectoral approach is used for access to the anterolateral proximal humerus metaphysis for allograft placement. Blunt dissection should be used to find the interval between the anterior head of the deltoid and the pectoralis major muscle. Our preference is to take the cephalic vein medially to avoid excessive tension with lateral retraction. Access to the anterolateral humerus should be obtained just lateral to the biceps tendon around the superior edge of the pectoralis major insertion. It is important to consider future surgical approaches, such as a standard deltopectoral approach, when performing the mini-deltopectoral approach.

The axillary nerve leaves the brachial plexus and passes posteriorly under the subscapularis inferior to



**Fig 2.** Intraoperative image of the right shoulder in the beach chair position showing portal placement with the arthroscope in the posterior portal and shaver in the anterior portal. The image also shows arthroscopic debridement of the glenohumeral joint viewed from the posterior portal.

**Fig 3.** Left image: Arthroscopic image in the left glenohumeral joint demonstrating the blunt probe over the cartilage fissure on the humeral head (blue arrow). Right image: Arthroscopic image in the left glenohumeral joint demonstrating a cartilage ridge on the humeral head (yellow arrow) in a patient with avascular necrosis. Both images are viewing from the posterior portal with the patient in the beach chair position.



the glenoid. It then courses around the humerus posteriorly to give off branches to the posterior deltoid and teres minor. The axillary nerve then wraps around the humerus laterally from a posterior direction approximately 5 cm distal to the top of the humeral head. The last branches of the axillary nerve are to the anterior deltoid; therefore, staying medial to the anterior deltoid will protect the axillary nerve.

The majority of the blood supply to the humeral head is from the anterior humeral circumflex artery, with a small contribution from the posterior humeral circumflex artery to the posteroinferior humeral head. The anterior humeral circumflex artery branches laterally off the axillary artery medial to the humerus in the third portion of the axillary artery. Once near the humerus, an ascending branch of the anterior humeral circumflex artery gives rise to the arcuate artery supplying the humeral head. The arcuate artery lies in the bone underlying the bicipital groove. By staying lateral to the biceps tendon with the dissection, there is

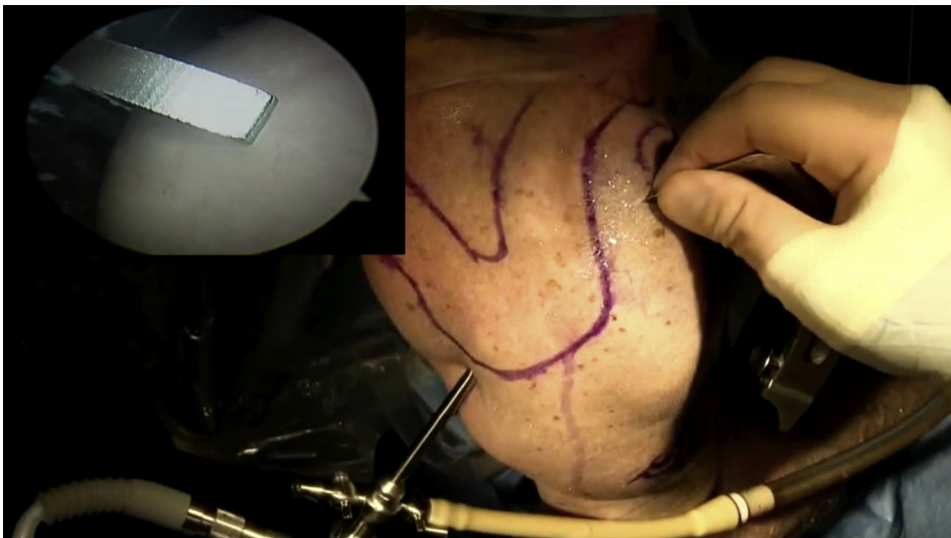
less chance of damage to the ascending branch of the anterior humeral circumflex artery and the arcuate artery.

### Equipment

This technique requires standard shoulder arthroscopy equipment; a transtibial anterior cruciate ligament (ACL) drill guide (tip-to-tip type), guide pin, and sequential reamers (Fig 1); and ACL graft sizer; and a small oscillating saw and rounded burr.

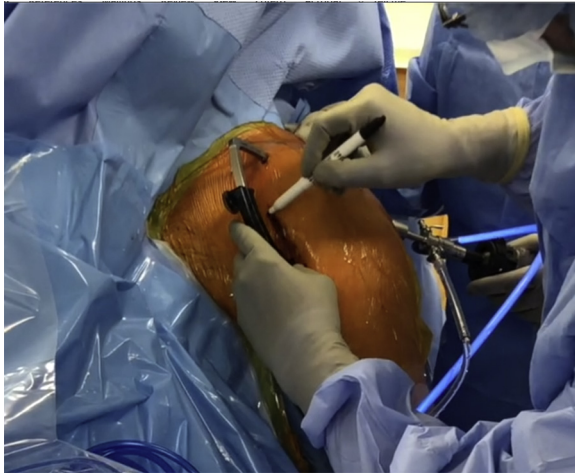
### Surgical Technique (With Video Illustration)

The procedure is performed with the patient under general anesthesia and an optional regional block and/or catheter placed in the preoperative holding area. The beach chair position with a hydraulic limb positioner is used. The patient is placed at the edge of the bed so that there is no metallic interference during shoulder fluoroscopy. The C-arm is brought in from above the patient's head. It is important to confirm that adequate



**Fig 4.** Intraoperative arthroscopic image of the ACL guide being placed in the anterior portal and in the center of AVN lesion. Of note, this image is from a demonstration of the technique on a cadaver so there is no AVN to appreciate on the humeral head. This is a right shoulder in the beach chair position shown with the arthroscopic image viewing from the posterior portal. (ACL, anterior cruciate ligament; AVN, avascular necrosis.)

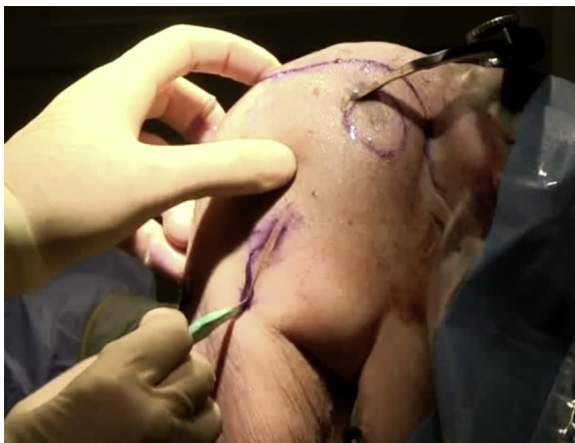



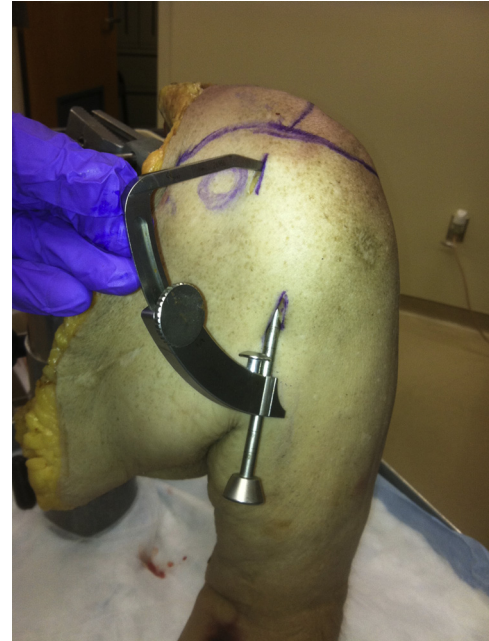**Fig 5.** Intraoperative image demonstrating the ACL guide in place being used as a guide for marking the deltopectoral interval. The patient's left shoulder is in the beach chair position. (ACL, anterior cruciate ligament.)

Grashey and axillary lateral fluoroscopic images can be obtained prior to draping. The shoulder and entire arm are sterilely prepped and draped in the standard way along with the Spider limb positioner. Appropriate antibiotics are given before incision.

A standard posterior arthroscopic portal is established with an incision made through skin only. A blunt trocar is introduced into the shoulder joint without joint insufflation. A 4.5-mm, 30° arthroscope is then introduced through this posterior portal. A second arthroscopic portal is established anteriorly through the rotator interval. The shoulder is fully evaluated arthroscopically in the standard fashion and all abnormalities are noted (Fig 2). A blunt probe is introduced to palpate the cartilage over the humeral head. The entire humeral head is evaluated for any surface topographic abnormalities, articular cartilage softening,



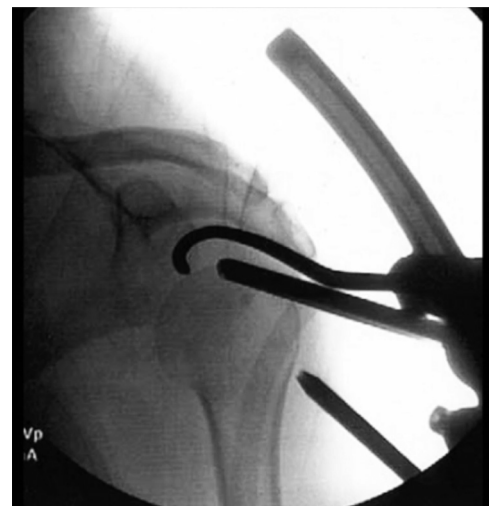**Fig 6.** Intraoperative image of the deltopectoral incision. The right shoulder is shown with the patient in the beach chair position.



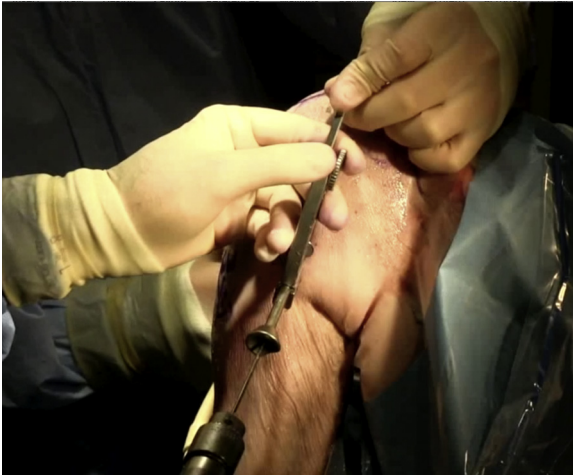**Fig 7.** Left shoulder of a cadaver in the beach chair position showing placement of ACL tip-to-tip guide and the mini-deltopectoral approach distally with the guide pin sleeve in place. (ACL, anterior cruciate ligament.)

or cartilage fissuring (Fig 3). The most profoundly affected area of the humeral head is usually easily identified as softening of the cartilage. With the probe on the suspected area, further confirmation can be obtained using fluoroscopy. This soft cartilage or even osteochondral fracture is not debrided.

The transtibial ACL guide (tip-to-tip type) is placed through the anterior portal (Fig 4, Video 1). Under direct arthroscopic visualization, the ACL guide is placed in the center of the humeral head AVN defect

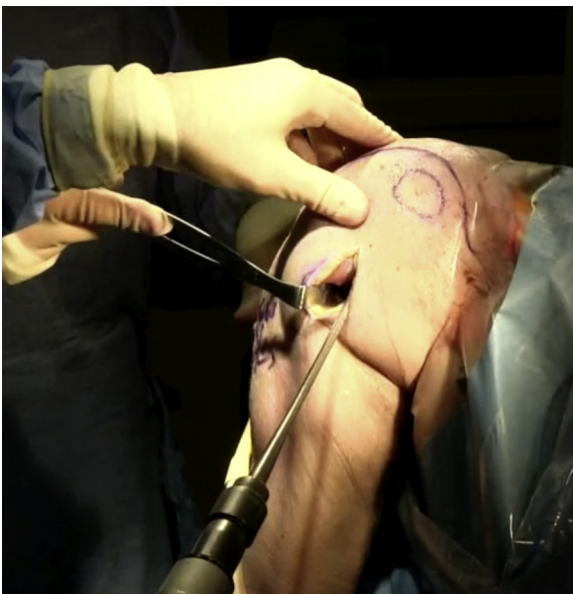

**Fig 8.** Intraoperative fluoroscopy of the left shoulder showing the ACL guide tip in the center of the lesion on the humeral head and guide pin sleeve on the humeral cortex anteriorly. (ACL, anterior cruciate ligament.)

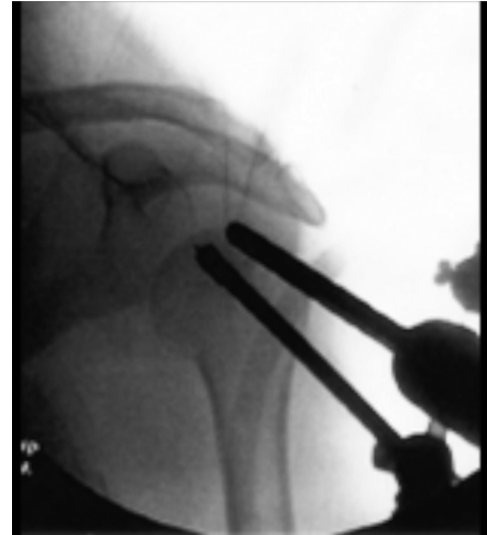

**Fig 9.** Intraoperative image of the right shoulder in the beach chair position depicting drilling of the guide pin using the ACL guide. (ACL, anterior cruciate ligament.)

(Fig 4). Using the ACL guide for reference, a 3-cm incision is made in-line with the distal deltopectoral interval (Figs 5 and 6). This interval is bluntly dissected enough to allow for placement of the guide against the anterolateral humerus (Figs 7 and 8). The guide should be just lateral to the biceps tendon and above the superior aspect of the pectoralis major insertion as described in the surgical anatomy section. A guide pin with a tissue protector is drilled through the anterolateral aspect of the proximal humerus into the humeral head up to the tip of the intra-articular guide without perforation of the subchondral bone (Fig 9). The position of the guide pin is confirmed fluoroscopically and then the length of the pin is measured. Ideal



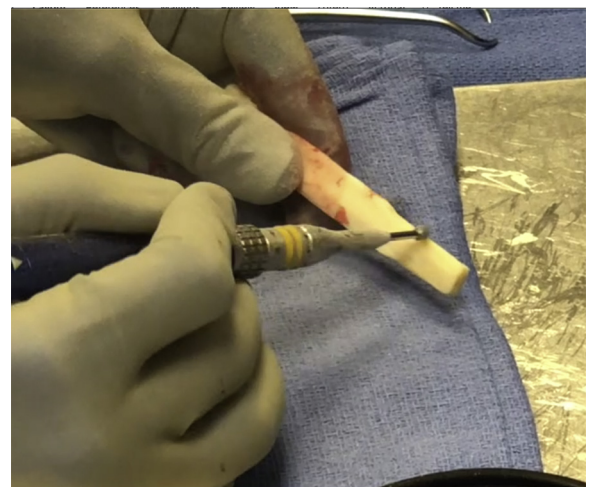
**Fig 10.** Intraoperative image of the right shoulder in the beach chair position depicting sequential reaming over the guide pin.



**Fig 11.** Intraoperative fluoroscopy of the left shoulder showing the reamer over the guide pin in place, taking care not to penetrate subchondral surface.

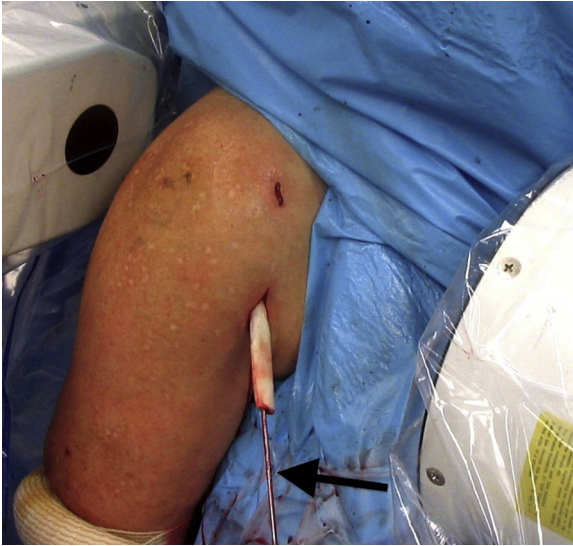placement of the guide pin should be in the middle of the AVN lesion and not through the subchondral bone. This is relatively easy using the ACL guide. Before the guide being employed, this was very difficult due to the very acute angle needed between the starting point of the guide pin and the humeral metadiaphysis.

At this point, the ACL guide is removed and sequential reaming is performed over the guide pin with soft-tissue protector sleeves until a tunnel of appropriate size is made to accommodate a fibular allograft (Fig 10). Care should be used to make sure that the subchondral surface is not penetrated during reaming (Fig 11). A fibular freeze-dried strut allograft (smallest diameter in the inventory) is obtained. The allograft is left long on purpose at this point. The



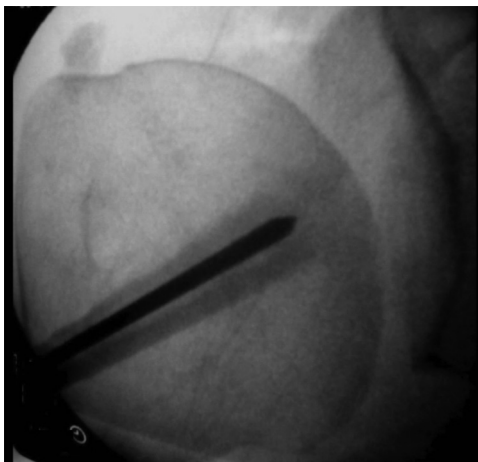
**Fig 12.** Intraoperative image showing preparation of the fibular strut allograft on the back table. The allograft is tapered to provide adequate press-fit fixation.



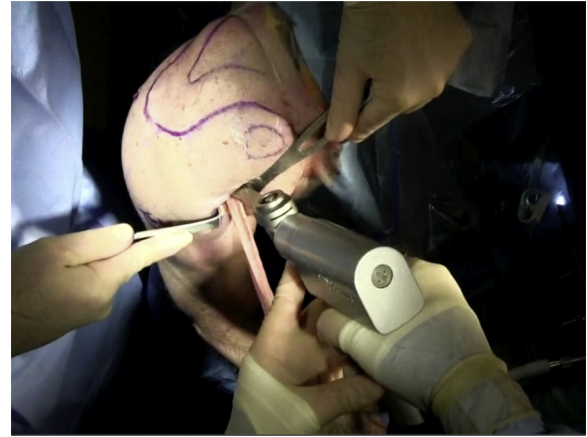

**Fig 13.** Intraoperative image of the right shoulder in the beach chair position showing the fibular strut placed over the guidepin (arrow).

smallest diameter end of the allograft is then tapered with a high-speed burr on the back table (Fig 12). The ACL graft sizers are used to note when the end of the graft is the appropriate diameter to pass through the tunnel. This diameter is contoured into the first 10 to 15 mm of the graft to be inserted and after that the diameter is slowly allowed to expand. The purpose of this is to provide a nice interference fit. The contoured fibular strut allograft is introduced over the guide pin into the humeral head (Fig 13). The graft is then gently tamped into place over the guide pin. The position of the graft is then confirmed fluoroscopically (Fig 14). The pin is removed and the graft is cut flush with the anterior lateral cortex with an oscillating saw (Fig 15). The bone edges are smoothed with a rounded burr.



**Fig 14.** Fluoroscopic image showing the fibular strut allograft placed over the guide pin to the subchondral bone of the right proximal humerus.

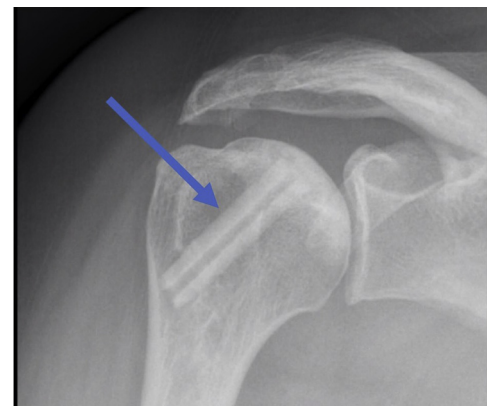

**Fig 15.** Intraoperative image of the right shoulder in the beach chair position demonstrating cutting of the allograft flush with the humeral cortex, taking care to protect the surrounding soft tissues using retractors.

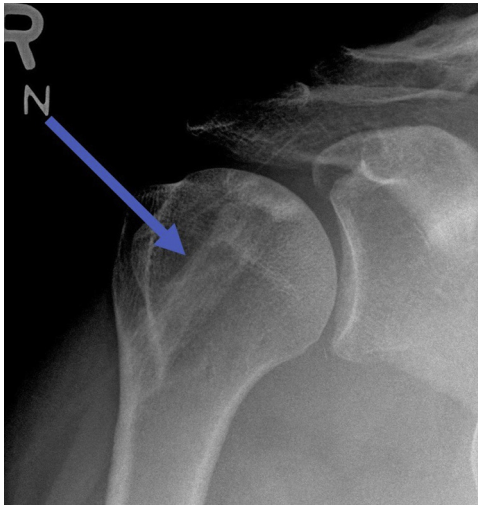The wound is irrigated with normal saline solution and bulb syringe with care taken to remove all bone shavings. Simple nylon sutures are used to close the arthroscopy portals. The distal deltopectoral incision is closed with subcutaneous VICRYL suture (Johnson & Johnson, New Brunswick, NJ), subcuticular MONOCRYL suture (Johnson & Johnson), and DERMABOND (Johnson & Johnson). Sterile dry dressings are placed.

#### Postoperative Management and Rehabilitation

The procedure is performed as outpatient. The patient's arm is placed in a sling postoperatively for 2 weeks. Strict nonweight-bearing precautions are advised for 6 weeks. Motion is generally easy to obtain. Passive range of motion and Codman exercises are started immediately. Active and active assist range of motion is begun between 2 and 4 weeks. Fig 16 shows radiographs of the allograft in the immediate postoperative period. Figs 17 and 18 show radiographs



**Fig 16.** Postoperative Grashey radiograph of the right shoulder showing the fibular strut allograft shortly postoperatively (blue arrow).



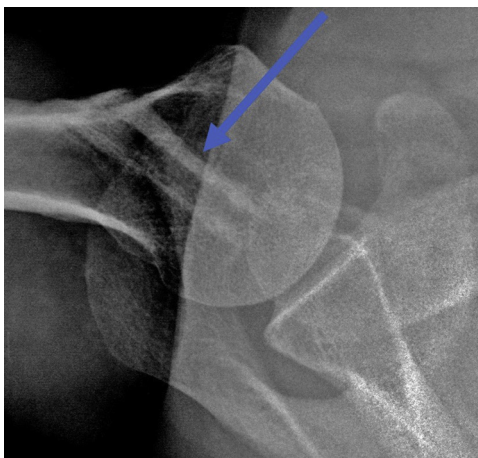
**Fig 17.** Postoperative Grashey radiograph of the right shoulder showing an incorporated fibular strut allograft at approximately 1.5 years (blue arrow).

obtained after allograft healing approximately 1.5 years after surgery.

**Complications**

Progression of osteonecrosis and/or the need for shoulder arthroplasty is the most concerning complication in this young patient population. This occurred in 21% of 14 shoulders at an average of 5 years in our experience.<sup>30</sup> Another complication is perforation of the subchondral bone, which can occur easily due to the soft bone around the osteonecrotic lesion. In our experience, this has not made a difference in clinical results; however, there is a theoretical risk of worsening pain and accelerated cartilage wear.

Infection is another possible surgical complication. If infection occurs acutely, removal of the graft is recommended. This also places the patient at further risk



**Fig 18.** Postoperative axillary lateral radiograph of the right shoulder showing an incorporated fibular strut allograft at approximately 1.5 years (blue arrow).

**Table 1.** Pearls/Pitfalls

Pearls	Pitfalls
<ul style="list-style-type: none"> <li>Positioning is key to help obtain appropriate fluoroscopic images, specifically with the proximal humerus hanging over the side of the operating table and the C-arm above the patient’s head.</li> <li>Blunt dissection and appropriate retraction with soft-tissue protectors are needed to avoid biceps tendon injury.</li> <li>Appropriate contouring of the fibular strut should be performed to provide enough interference for press-fit fixation and minimize allograft migration.</li> </ul>	<ul style="list-style-type: none"> <li>Care needs to be taken with guide pin placement and reaming to avoid breaching the subchondral bone.</li> <li>Appropriate contouring of the fibular strut should be performed so that fracture of the proximal humerus does not occur upon insertion.</li> <li>Cut the fibula flush with the anterior humeral cortex and rasp, rongeur, or burr down to prevent prominence.</li> </ul>

for shoulder infection with a subsequent procedure on the shoulder. Thus far, we have had no infections in our series. Because of this risk, strict sterile technique and perioperative antibiotics should be used, and we typically use topical antibiotics as well.

Rupture of the long head of the biceps tendon is another complication seen in this procedure. This can happen during passing of the reamers or the allograft, but it can also happen if the allograft is prominent with a sharp edge.

**Pearls and Pitfalls**

Patient positioning is key, i.e., using the beach chair position and placing the arm in an arm holder. Fluoroscopic images of the shoulder are obtained to ensure adequate visualization before draping by bringing the C-arm in above the patient’s head. Blunt dissection and appropriate retraction with soft-tissue retractors are needed to avoid biceps tendon injury using the mini-deltpectoral incision. Appropriate contouring of the fibular strut should be performed to provide enough interference for press-fit fixation and minimize the chance of allograft migration.

Regarding pitfalls, care needs to be taken with guide pin placement and reaming to avoid breaching the

**Table 2.** Advantages/Disadvantages

Advantages	Disadvantages
<ul style="list-style-type: none"> <li>Arthroscopic visualization enables appropriate placement of the fibular strut in the center of the lesion.</li> <li>Technique allows good support of the subchondral bone compared to only retrograde drilling.</li> <li>Press-fit fibular strut allograft fixation avoids metal implants.</li> </ul>	<ul style="list-style-type: none"> <li>Formal beach chair position needed to perform arthroscopy (vs the lazy beach chair position).</li> <li>Small open incision needed to place graft (vs the percutaneous approach with decompression only).</li> <li>Potential injury to the long head of the biceps tendon.</li> </ul>

subchondral bone. Appropriate contouring of the fibular strut should be performed so that fracture of the proximal humerus does not occur upon insertion. The fibula shoulder be cut flush with the anterior humeral cortex using a rasp, rongeur, or burr to prevent prominence. A summary of pearls and pitfalls can be found in Table 1.

### Advantages and Disadvantages

Advantages of this technique include arthroscopic visualization, enabling appropriate decompression and placement of the fibular strut in the center of the lesion. This technique allows good support of the subchondral bone compared to only retrograde drilling. In addition, press-fit fibular strut allograft fixation avoids metal implants. Disadvantages include the formal beach chair position needed to perform arthroscopy (versus the lazy beach chair position for isolated decompression). A small open incision is needed to place the graft (vs the percutaneous approach with decompression only). In addition, there is potential for injury to the long head of the biceps tendon. A summary of the advantages and disadvantages can be found in Table 2.

### References

- Mont MA, Payman RK, Laporte DM, Petri M, Jones LC, Hungerford DS. Atraumatic osteonecrosis of the humeral head. *J Rheumatol* 2000;27:1766-1773.
- Harreld KL, Marker DR, Wiesler ER, Shafiq B, Mont MA. Osteonecrosis of the humeral head. *J Am Acad Orthop Surg* 2009;17:345-355.
- Hasan SS, Romeo AA. Nontraumatic osteonecrosis of the humeral head. *J Shoulder Elbow Surg* 2002;11:281-298.
- Cruess R. Steroid-induced avascular necrosis of the head of the humerus. Natural history and management. *J Bone Joint Surg Br* 1976;58:313-317.
- L'Insalata JC, Pagnani MJ, Warren RF, Dines DM. Humeral head osteonecrosis: Clinical course and radiographic predictors of outcome. *J Shoulder Elbow Surg* 1996;5:355-361.
- Hernigou P, Flouzat-Lachaniette C-H, Roussignol X, Poignard A. The natural progression of shoulder osteonecrosis related to corticosteroid treatment. *Clin Orthop Rel Res* 2010;468:1809-1816.
- Poignard A, Flouzat-Lachaniette C-H, Amzallag J, Galacteros F, Hernigou P. The natural progression of symptomatic humeral head osteonecrosis in adults with sickle cell disease. *J Bone Joint Surg Am* 2012;94:156-162.
- LaPorte DM, Mont MA, Mohan V, Pierre-Jacques H, Jones LC, Hungerford DS. Osteonecrosis of the humeral head treated by core decompression. *Clin Orthop Rel Res* 1998;355:254-260.
- Harreld KL, Marulanda GA, Ulrich SD, Marker DR, Seyler TM, Mont MA. Small-diameter percutaneous decompression for osteonecrosis of the shoulder. *Am J Orthop (Belle Mead NJ)* 2009;38:348-354.
- Kircher J, Patzer T, Ziskoven C, Bittersohl B, Hedtmann A, Krauspe R. Arthroscopically assisted retrograde drilling of the humeral head with a guiding device. *Knee Surg Sports Traumatol Arthrosc* 2015;23:1442-1446.
- Kennon JC, Smith JP, Crosby LA. Core decompression and arthroplasty outcomes for atraumatic osteonecrosis of the humeral head. *J Shoulder Elbow Surg* 2016;25:1442-1448.
- Steffensmeier AM, Kirkham K, Wiemann JM. Core decompression with synthetic grafting as a joint preservation strategy in humeral avascular necrosis due to sickle cell anemia: A case report. *J Orthop Case Rep* 2016;6:62-64.
- Kawamura K, Kawate K, Yajima H, Kobata Y, Takakura Y. Vascularized scapular grafting for treatment of osteonecrosis of the humeral head. *J Reconstr Microsurg* 2008;24:559-564.
- Inoue K, Suenaga N, Oizumi N, Tanaka Y, Minami A. A vascularized scapular graft for juvenile osteonecrosis of the humeral head. *J Shoulder Elbow Surg* 2012;21:e9-e13.
- Brannon JK. Thorough debridement of the humeral head for osteonecrosis. *Orthopedics* 2011;34:56-56.
- Miyazaki AN, Silva LA, Sella GdV, Checchia CS, Simionato MC, Checchia SL. Articular reconstruction of the humeral head with autogenous allograft in the treatment of the osteonecrosis. *Rev Bras Ortop* 2018;53:113-117.
- Raiss P, Kasten P, Baumann F, Moser M, Rickert M, Loew M. Treatment of osteonecrosis of the humeral head with cementless surface replacement arthroplasty. *J Bone Joint Surg Am* 2009;91:340-349.
- Uribe JW, Botto-van Bemden A. Partial humeral head resurfacing for osteonecrosis. *J Shoulder Elbow Surg* 2009;18:711-716.
- Ranalletta M, Bertona A, Tanoira I, Rossi L, Bongiovanni S, Maignón G. Results of partial resurfacing of humeral head in patients with avascular necrosis. *Rev Esp Cir Ortop Traumatol* 2019;63:29-34.
- Soudy K, Szymanski C, Lalanne C, et al. Results and limitations of humeral head resurfacing: 105 cases at a mean follow-up of 5 years. *Orthop Traumatol Surg Res* 2017;103:415-420.
- Sweet SJ, Takara T, Ho L, Tibone JE. Primary partial humeral head resurfacing: Outcomes with the HemiCAP implant. *Am J Sports Med* 2015;43:579-587.
- Hattrup SJ, Cofield RH. Osteonecrosis of the humeral head: Results of replacement. *J Shoulder Elbow Surg* 2000;9:177-182.
- Parsch D, Lehner B, Loew M. Shoulder arthroplasty in nontraumatic osteonecrosis of the humeral head. *J Shoulder Elbow Surg* 2003;12:226-230.
- Mansat P, Huser L, Mansat M, Bellumore Y, Rongièrès M, Bonneville P. Shoulder arthroplasty for atraumatic avascular necrosis of the humeral head: Nineteen shoulders followed up for a mean of seven years. *J Shoulder Elbow Surg* 2005;14:114-120.
- Smith RG, Sperling JW, Cofield RH, Hattrup SJ, Schleck CD. Shoulder hemiarthroplasty for steroid-associated osteonecrosis. *J Shoulder Elbow Surg* 2008;17:685-688.



26. Schoch BS, Barlow JD, Schleck C, Cofield RH, Sperling JW. Shoulder arthroplasty for atraumatic osteonecrosis of the humeral head. *J Shoulder Elbow Surg* 2016;25:238-245.
27. Orfaly RM, Rockwood CA Jr, Esenyel CZ, Wirth MA. Shoulder arthroplasty in cases with avascular necrosis of the humeral head. *J Shoulder Elbow Surg* 2007;16: S27-S32.
28. Burrus MT, Cancienne JM, Boatright JD, Yang S, Brockmeier SF, Werner BC. Shoulder arthroplasty for humeral head avascular necrosis is associated with increased postoperative complications. *HSS J* 2018;14:2-8.
29. Franceschi F, Franceschetti E, Paciotti M, et al. Surgical management of osteonecrosis of the humeral head: A systematic review. *Knee Surg Sports Traumatol Arthrosc* 2017;25:3270-3278.
30. Galloway M, Horodyski M, Wright T. Arthroscopically assisted fibular strut allograft for treatment of osteonecrosis of proximal humerus. *J Surg Orthop Adv* 2013;22: 277-282.