


CASE REPORT

Hearing loss, cleft palate, and congenital hip dysplasia in female carriers of an intragenic deletion of *AMMECR1*

Saskia Koene¹  | Jeroen Knijnenburg¹ | Mariette J. V. Hoffer¹ |
Fleur Zwanenburg² | Monique C. Haak² | Heiko Locher³ |
Edward S. A. van Beelen³ | Gijs W. E. Santen¹ | Liselotte J. C. Rotteveel³

¹Department of Clinical Genetics, Leiden University Medical Centre, Leiden, Netherlands

²Department of Obstetrics and Gynaecology, Leiden University Medical Centre, Leiden, Netherlands

³Department of Otorhinolaryngology, Head&Neck surgery, Leiden University Medical Centre, Leiden, Netherlands

Correspondence

Saskia Koene, Department of Clinical Genetics, Leiden University Medical Centre, Albinusdreef 2, 2333 ZA, Leiden, Netherlands.
Email: s.koene@lumc.nl

Abstract

Previously, mutations in the *AMMECR1* gene have been described in six males with developmental delay, sensorineural hearing loss (SNHL) and/or congenital abnormalities, including fetal nuchal edema, fetal pericardial effusion, talipes, congenital hip dysplasia, elliptocytosis and cleft palate. In this report, we present three female relatives of a male fetus with an intragenic deletion in this X-linked gene. All three women reported hearing loss and one was born with a soft cleft palate and hip dysplasia. The audiograms showed mild to moderate SNHL with a variable pattern of the affected frequencies. Immunohistochemical analysis of fetal cochlea was performed confirming the expression of *AMMECR1* in the human inner ear. Since hearing loss, cleft palate and congenital hip dysplasia were reported before in male *AMMECR1* point mutation carriers and *AMMECR1* is expressed in fetal inner ear, we suggest that female carriers may display a partial phenotype in this X-linked condition.

KEYWORDS

AMMECR1, congenital abnormalities, sensorineural hearing loss, X-linked inheritance

1 | INTRODUCTION

Deletions of the Xq22.3-Xq23 region, including both *AMMECR1* and *COL4A5*, are described as part of Alport syndrome with intellectual disability (mental retardation), midface hypoplasia, and elliptocytosis (*AMME*) (Vitelli et al., 2000). Until now, 10 male patients with a deletion including *AMMECR1* have been described (Lu et al., 2021).

Although *AMMECR1* and some of its functions in mice have been known since 1999 (Vitelli et al., 1999), the first mutations in the gene in humans have not been reported until recently (Andreoletti et al., 2017). In 2017, single missense mutations in *AMMECR1* were described in two half-brothers with early speech and language delay, infantile hypotonia, hearing loss, nephrocalcinosis and midface

hypoplasia with submucosal cleft and bifid uvula (Andreoletti et al., 2017) and in two males with elliptocytosis, midface hypoplasia, short stature, and hearing loss (Basel-Vanagaite et al., 2017).

In this short report, we present signs and symptoms of three carrier female relatives of a male fetus with an intragenic hemizygous deletion in *AMMECR1* suggesting that a partial phenotype may be present in females.

2 | CASES

A woman, pregnant with dichorionic twins, was referred to our department of prenatal diagnostics because of an increased nuchal

This is an open access article under the terms of the Creative Commons Attribution-NonCommercial-NoDerivs License, which permits use and distribution in any medium, provided the original work is properly cited, the use is non-commercial and no modifications or adaptations are made.

© 2022 The Authors. *American Journal of Medical Genetics Part A* published by Wiley Periodicals LLC.

translucency of fetus B (Index III-2). At a gestational age of 16 weeks, bilateral talipes, pericardial effusion, cardiomegaly, and mild tricuspid insufficiency was noted. Using SNP array, an intragenic deletion of *AMMECR1* on Xq23.1 was found. This hemizygous in-frame deletion encompassed exon 4 of the *AMMECR1* gene. He was part of a dizygotic twin pregnancy; the other fetus (Patient III-1) did not show any abnormalities at the ultrasound scan or at genetic investigation.

Three out of four reported point mutations to date were point mutations (one missense, two nonsense) in exon 4 of the *AMMECR1* gene. Since talipes, pericardial effusion and cardiac anomalies have been described in patients with a missense mutation in *AMMECR1* (Andreoletti et al., 2017; Basel-Vanagaite et al., 2017; Moysés-Oliveira et al., 2018), it is very likely that the intragenic deletion of *AMMECR1* explains the phenotype of the fetus. Moreover, fetal blood from a cord puncture showed some elliptocytes and erythrocyte deformability was abnormal compared to healthy controls. However, since no age-matched controls were available to quantify the result, there is no definite diagnosis of hereditary elliptocytosis.

The index was selectively terminated at 19 weeks on request of the parents. This fetus retained in utero until the term delivery of the surviving cotwin and therefore, the overt maceration of the body tissue impeded postnatal clinical examination.

The index' mother (Figure 1; Patient II-1) has asymmetric mild to moderate sensorineural hearing loss (SNHL), for which a hearing aid was recently fitted on the worst hearing left ear. She had an episode of vestibular complaints in the past. Her pure tone audiogram (PTA) (Figure S1) showed a flat SNHL of 27 dB on the right ear and a midfrequency SNHL of 47 dB on the left ear. The index' maternal grandmother (Figure 1; Patient I-1) has worn hearing aids since the age of 40 years. Her PTA (Figure S3) showed a symmetric flat SNHL of 60 dB. The index' maternal aunt (Figure 1; Patient II-2) has

congenital hip dysplasia, hearing problems with recurrent middle ear infections as a child and has had corrective surgery for a cleft of the soft palate. Her PTA (Figure S2) showed an asymmetric SNHL, mainly of the low frequencies.

Patients I-1 and II-2 did not report vestibular complaints. Hearing loss or congenital abnormalities did not occur in any other family member. No short stature, microsomia or midface hypoplasia was observed in I-1 and II-1. Although some mild hypotelorism was observed in II-2, we could not assess the presence of midface hypoplasia since she was not able to come to the clinic for full dysmorphological examination.

Patients I-1, II-1, and II-2 were all hemizygous female carriers of the intragenic deletion of *AMMECR1*. In Patient I-1, no alternative genetic explanation for the hearing loss was found on next generation sequencing analysis (hearing impairment gene panel DG 2.18 Radboudumc [206 genes; not including *AMMECR1*]).

In the asymptomatic daughter and sister of Patient I-1 (II-3 and I-2) the *AMMECR1* deletion was not detected. The brother and the nephew of Patient I-1 (I-4 and II-6) were phenotypically normal.

3 | METHODS AND RESULTS OF CLINICAL GENETIC TESTING AND IMMUNOHISTOCHEMICAL ANALYSIS FOR *AMMECR1* EXPRESSION IN FETAL COCHLEA

3.1 | Array

The Affymetrix CytoScanHD SNP array showed an intragenic hemizygous deletion of 23 kb (24 probes), containing exon 4 of the *AMMECR1* gene (NM_015365.2) (coordinates of estimated minimally deleted region: chrX: 109,496,686–109,520,211 bp [build GRCh37]);

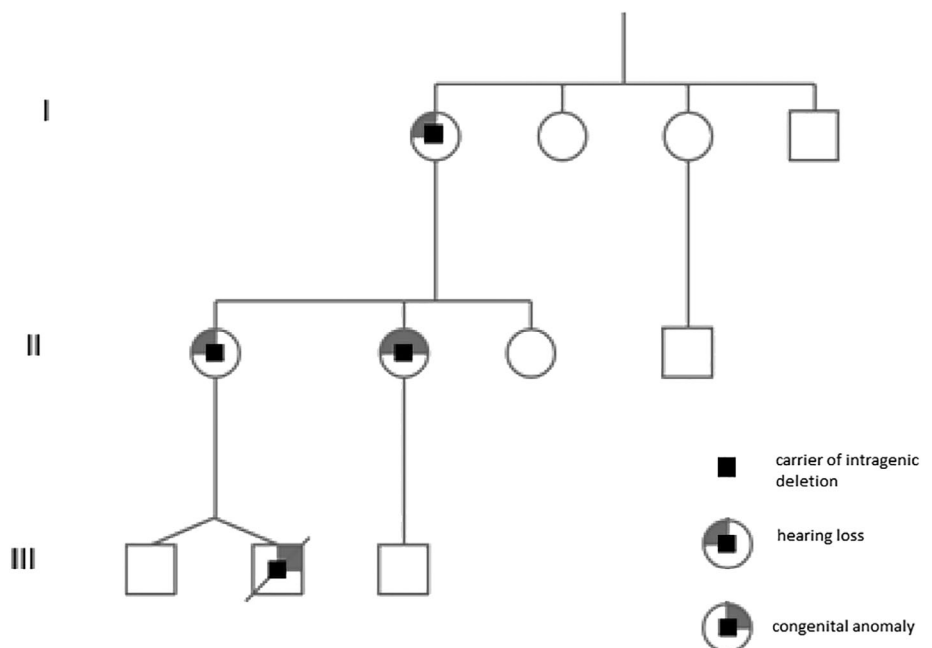


FIGURE 1 Three generations pedigree of this family showing hearing loss in all female carriers

TABLE 1 Phenotypic features of the index patient and his female relatives and of known AMMECR1 point mutation carriers in literature

| Tables | (Male) index | Mother | Maternal aunt | Grandmother | Basel-Vanagaite et al. proband | Basel-Vanagaite et al. maternal uncle | Andreoletti et al. proband II(1) | Andreoletti et al. proband II(2) | Andreoletti et al. proband I(2) | Moyses-Oliveira P2 | Moyses-Oliveira P3 |
|----------------------------|--------------|--------|---------------|-------------|--------------------------------|---------------------------------------|----------------------------------|----------------------------------|---------------------------------|--------------------|--------------------|
| Gender | M | F | F | F | M | M | M | M | F | M | M |
| Talipes | x | | | | | | x | | | | |
| Fetal pericardial effusion | x | | | | x | | | | | | |
| Tricuspid insufficiency | x | | | | | | | | | | |
| Fetal nuchal edema | x | | | | | | x | | | | |
| Cleft palate | | | x | | x | | x | x | | | |
| Hearing loss | | x | x | x | | x | x | | | x | x |
| Congenital hip dysplasia | | | x | | | | | x | | | |

Abbreviations: NM, not mentioned; x, present.

see also Figure S5. Subsequent testing in family members showed three female carriers of the deletion, as depicted in Figure 1.

3.2 | X-inactivation

X-inactivation was assessed by determining the methylation status of the CAG repeat in the androgen receptor gene on the X chromosome (Kubota et al., 1999). *AMMECR1* usually does not escape X chromosome inactivation (Cotton et al., 2015).

X-inactivation patterns in peripheral blood showed skewing of 90:10 in Patient II-2; borderline skewing of 80:20 in Patient II-1 and random skewing of 60:40 in Patient I-1.

3.3 | Human fetal inner ear immunohistochemistry

Use of human embryonic and fetal specimens was in accordance with Dutch legislation (Fetal Tissue Act, 2001) and the WMA Declaration of Helsinki guidelines. Ethical approval was obtained in our institute (protocol registration number B18.044). Human fetal inner ears were collected after elective termination of pregnancy by vacuum aspiration. Fetal age (in weeks, W), defined as the duration since fertilization, was determined by obstetric ultrasonography prior to termination. Tissue was obtained at the developmental stages W13 ($n = 1$) and W17 ($n = 1$). Inner ears were fixed in 4% paraformaldehyde, decalcified and embedded in paraffin as previously described (van Beelen et al., 2020). Sections (5 μm) were cut using a HM 355S rotary microtome (Thermo Fisher Diagnostics). Sections were deparaffinized in xylene and rehydrated, followed by standard immunohistochemistry procedures (Locher et al., 2013). Sections were incubated overnight at +4°C with a polyclonal rabbit anti-*AMMECR1* antibody (1:50; #201552-T10; Sino Biological). Next, sections were incubated with a secondary AF488 donkey anti-rabbit antibody (1:1000; #A-21206; Invitrogen) for 1 h at room temperature. Nuclei were stained with DAPI. Negative controls were carried out by matching isotype controls and omitting primary antibodies. Positive controls were carried out by staining sections of known positive human tissue samples. At least three separate immunostaining experiments for each fetal stage were performed.

The immunohistochemistry shows expression of *AMMECR1* in the human fetal inner ear (Figure S4). At Day 13, membranal expression of *AMMECR1* is seen in most developing epithelial cells. At Day 17, expression of *AMMECR1* is confined to the apical cells of Reissner's membrane, Kölliker's Organ, and the outer sulcus cells, suggesting a temporal gradient in expression.

4 | DISCUSSION

In most cases of known *AMMECR1* point mutation carriers with SNHL reported in the literature and summarized in Table 1, the SNHL was detected during childhood and the affected frequencies varied from

flat to high frequency hearing loss. The severity of the hearing loss also varied and possible progression was observed in some cases. In the present study, an age-related progression could be present but data are insufficient for conclusions.

In this short report, we present a family in which female relatives of a male fetus with an *AMMECR1* gene disruption have mild clinical features consistent with the male phenotype. Although partial phenotypes in female carriers of X-linked disorders are not rare (Juchniewicz et al., 2018; Stembalska et al., 2016), a partial phenotype has not been reported for changes in the *AMMECR1* gene before. Unilateral SNHL was also reported in the mother of two boys with a large deletion including not only *AMMECR1*, but also X-linked Alport genes *COL4A5* and the X-linked deafness gene *COL4A6* (Jonsson et al., 1998). Because of the combination with hematuria in this individual and her sons, it is hard to differentiate between the role of *AMMECR1* and the deletion of *COL4A5/COL4A6* as a cause of SNHL in this patient.

The first sign of the *AMMECR1* deficiency in the male fetus was increased nuchal translucency. This was reported before by Andreoletti et al. (2017). Pericardial effusion (Basel-Vanagaite et al., 2017) and talipes (Andreoletti et al., 2017) were also reported before.

Although the prevalence of hearing loss, cleft palate and congenital hip dysplasia is not extremely low in the general population, all of the features reported by the female carriers in this family were reported before in male point mutation carriers (Table 1). Therefore, we suggest that female carriers may show a partial phenotype. The expression of *AMMECR1* in the human fetal inner ear (Figure S4) and the nonrandom X-inactivation in the most severely affected female support this hypothesis.

Because of the possible reproductive consequences, we suggest to study *AMMECR1* mutations and intragenic deletions in larger cohorts of patients with (mild) SNHL and/or cleft palate.

ACKNOWLEDGMENT

The authors thank the patients for their participation in our study. The patients gave informed consent for the publication of their medical details in this study.

CONFLICT OF INTEREST

The authors have no conflicts of interest.

AUTHOR CONTRIBUTIONS

Saskia Koene: Writing manuscript. **Jeroen Knijnenburg:** DNA-analysis and interpretation, correction of manuscript. **Mariette J. V. Hoffer:** DNA-analysis and interpretation, correction of manuscript. **Fleur Zwanenburg:** Correction of manuscript. **Monique C. Haak:** Correction of manuscript. **Heiko Locher:** Generation of fetal cochlea data, correction of manuscript. **Edward S. A. van Beelen:** Generation of fetal cochlea data, correction of manuscript. **Gijs W. E. Santen:** First interpretation of genetic information; correction of manuscript. **Liselotte J. C. Rotteveel:** Interpretation of tone audiograms; corrections of manuscript.

DATA AVAILABILITY STATEMENT

There is no data to share.

ORCID

Saskia Koene  <https://orcid.org/0000-0002-9876-744X>

REFERENCES

- Andreoletti, G., Seaby, E. G., Dewing, J. M., O'Kelly, I., Lachlan, K., Gilbert, R. D., & Ennis, S. (2017). AMMECR1: A single point mutation causes developmental delay, midface hypoplasia and elliptocytosis. *Journal of Medical Genetics*, *54*(4), 269–277.
- Basel-Vanagaite, L., Pillar, N., Isakov, O., Smirin-Yosef, P., Lagovsky, I., Orenstein, N., Salmon-Divon, M., Tamary, H., Zaft, T., Bazak, L., Meyerovitch, J., Pelli, T., Botchan, S., Farberov, L., Weissglas-Volkov, D., & Shomron, N. (2017). X-linked elliptocytosis with impaired growth is related to mutated AMMECR1. *Gene*, *606*, 47–52.
- Cotton, A. M., Price, E. M., Jones, M. J., Balaton, B. P., Kobor, M. S., & Brown, C. J. (2015). Landscape of DNA methylation on the X chromosome reflects CpG density, functional chromatin state and X-chromosome inactivation. *Human Molecular Genetics*, *24*(6), 1528–1539.
- Jonsson, J. J., Renieri, A., Gallagher, P. G., Kashtan, C. E., Cherniske, E. M., Bruttini, M., Piccini, M., Vitelli, F., Ballabio, A., & Pober, B. R. (1998). Alport syndrome, mental retardation, midface hypoplasia, and elliptocytosis: A new X linked contiguous gene deletion syndrome? *Journal of Medical Genetics*, *35*(4), 273–278.
- Juchniewicz, P., Kloska, A., Tylki-Szymańska, A., Jakóbkiewicz-Banecka, J., Węgrzyn, G., Moskot, M., Gabig-Cimińska, M., & Piotrowska, E. (2018). Female Fabry disease patients and X-chromosome inactivation. *Gene*, *641*, 259–264.
- Kubota, T., Nonoyama, S., Tonoki, H., Masuno, M., Imaizumi, K., Kojima, M., Wakui, K., Shimadzu, M., & Fukushima, Y. (1999). A new assay for the analysis of X-chromosome inactivation based on methylation-specific PCR. *Human Genetics*, *104*(1), 49–55.
- Locher, H., Frijns, J. H. M., van Iperen, L., de Groot, J. C. M. J., Huisman, M. A., & de Sousa Lopes, S. M. C. (2013). Neurosensory development and cell fate determination in the human cochlea. *Neural Development*, *8*, 20.
- Lu, Q., Zhang, F.-Z., Lv, J.-H., & Tang, L.-F. (2021). Clinical features in patients with Xq23 microdeletion: A case report and literature review (Xq23 microdeletions). *Journal of Clinical Research in Pediatric Endocrinology*, *XX*, xx–xx.
- Moyés-Oliveira, M., Giannuzzi, G., Fish, R. J., Rosenfeld, J. A., Petit, F., de Fatima Soares, M., Kulikowski, L. D., Di-Battista, A., Zamariolli, M., Xia, F., Liehr, T., Kosyakova, N., Carvalheira, G., Parker, M., Seaby, E. G., Ennis, S., Gilbert, R. D., Hagelstrom, R. T., Cremona, M. L., ... Raymond, A. (2018). Inactivation of AMMECR1 is associated with growth, bone, and heart alterations. *Human Mutation*, *39*(2), 281–291.
- Stembalska, A., Łączmańska, I., Gil, J., & Pesz, K. A. (2016). Fragile X syndrome in females—A familial case report and review of the literature. *Developmental Period Medicine*, *20*(2), 99–104.
- van Beelen, E. S. A., van der Valk, W. H., de Groot, J. C. M. J., Hensen, E. F., Locher, H., & van Benthem, P. P. G. (2020). Migration and fate of vestibular melanocytes during the development of the human inner ear. *Developmental Neurobiology*, *80*, 411–432.
- Vitelli, F., Meloni, I., Fineschi, S., Favara, F., Tiziana Storlazzi, C., Rocchi, M., & Renieri, A. (2000). Identification and characterization of mouse orthologs of the AMMECR1 and FACL4 genes deleted in AMME syndrome: Orthology of Xq22.3 and MmuXF1-F3. *Cytogenetics and Cell Genetics*, *88*(3–4), 259–263.
- Vitelli, F., Piccini, M., Caroli, F., Franco, B., Malandrini, A., Pober, B., Jonsson, J., Sorrentino, V., & Renieri, A. (1999). Identification and characterization of a highly conserved protein absent in the Alport syndrome (a), mental retardation (M), midface hypoplasia (M), and elliptocytosis (E) contiguous gene deletion syndrome (AMME). *Genomics*, *55*(3), 335–340.

SUPPORTING INFORMATION

Additional supporting information may be found in the online version of the article at the publisher's website.

How to cite this article: Koene, S., Knijnenburg, J., Hoffer, M. J. V., Zwanenburg, F., Haak, M. C., Locher, H., van Beelen, E. S. A., Santen, G. W. E., & Rotteveel, L. J. C. (2022). Hearing loss, cleft palate, and congenital hip dysplasia in female carriers of an intragenic deletion of AMMECR1. *American Journal of Medical Genetics Part A*, *188A*:1578–1582. <https://doi.org/10.1002/ajmg.a.62669>