

Pathological findings of clinically suspected myocarditis temporally associated with COVID-19 vaccination

Masayoshi Yamamoto*, Kazuko Tajiri, Syogo Ayuzawa, and Masaki Ieda

Department of Cardiology, Faculty of Medicine, University of Tsukuba, Tsukuba, Japan

Received 20 December 2021; revised 21 April 2022; accepted 22 April 2022; online publish-ahead-of-print 15 May 2022

Reports on the pathological findings of patients with myocarditis after coronavirus disease 2019 (COVID-19) vaccination are limited. We present a case series of four patients with clinically suspected myocarditis temporally associated with COVID-19 vaccination who underwent endomyocardial biopsy with no evidence of viral genomes in tissue specimens. Two patients had fulminant myocarditis with marked inflammatory cell infiltration comprised mostly of CD8+ T-cells and macrophages, and the other two had suspected myocarditis based on the biochemical evidence of myocardial injury and ST changes on an electrocardiogram. However, they did not meet the histological criteria of myocarditis. Immunosuppressive therapy effectively reduced myocardial damage, and all four patients had improved clinical courses. Temporal association does not prove causation, and it cannot be excluded that the two biopsy-proven cases reported are simply a random association of a naturally occurring virus-negative immune-mediated lymphocytic myocarditis occurring after vaccination.

Keywords COVID-19 • Vaccine • Myocarditis • Pathology • Biopsy

Introduction

There is increasing evidence that myocarditis may be a rare complication of the coronavirus disease 2019 (COVID-19) messenger RNA (mRNA) vaccination. However, reports on the pathological findings of patients with myocarditis after COVID-19 vaccination are limited, and temporal association does not prove causation. We herein report four cases of suspected myocarditis temporally associated with COVID-19 vaccination and present detailed histological analyses and clinical courses (Table 1). All patients did not have a history of previous COVID-19 infection. They underwent polymerase chain reaction (PCR) tests twice on admission and on the third day of admission. All tests were negative. We performed multi-viral real-time PCR, which could detect 178 human viral genomes, including severe acute respiratory syndrome coronavirus 2, by extracting the nucleic acid from myocardial tissue. No viral genomes were detected in any case.

The study complies with the Declaration of Helsinki. Our institution's ethical committee has approved the protocol, and informed consent was obtained from all patients.

Case reports

Case 1

A 41-year-old man developed chest pain, myalgia, and fever 19 days after receiving the second dose of the mRNA COVID-19 vaccine (mRNA-1273 Moderna). On the 24th day after vaccination, the patient visited the hospital because of dyspnoea. He tested negative for COVID-19 by PCR. Cardiac troponin T (15.000 [reference range, 0–0.100] ng/ml) and creatine kinase (2987 IU/L) levels were elevated, and echocardiography demonstrated severe left ventricular dysfunction (left ventricular ejection fraction, 15%). After admission, the patient developed cardiogenic shock, and Impella CP and veno-arterial extracorporeal membrane oxygenation were initiated. Coronary angiography revealed no coronary artery disease. Simultaneously, an endomyocardial specimen was obtained from the right ventricular septum, which demonstrated marked inflammation comprised mostly of lymphocytes, as well as mild eosinophilic infiltrates. Immunostaining revealed the marked infiltration of CD8+ T-lymphocytes and macrophages, with a small number of CD4+ T-lymphocytes

*Corresponding author. Department of Cardiology, Faculty of Clinical Medicine, University of Tsukuba, 1-1-1 Tennodai, Tsukuba 305-8575, Japan. Tel: +81 298 533143, Fax: +81 298 533227, Email: yamamotomasayoshiyama@ybb.ne.jp

Table 1 Patient characteristics and clinical course

	Case 1	Case 2	Case 3	Case 4
Sex	Male	Female	Male	Male
Age, years	41	18	18	18
Temperature, °C	38.0	37.0	36.4	37.0
Blood pressure, mmHg	93/71	91/69	101/44	108/72
Heart rate, bpm	121	118	70	106
Pre-hospital symptom	Fever/chest pain/myalgia	Fever/chest pain/fatigue	Fever/chest pain	Fever/chest pain
Coexisting illness	No	No	No	No
Prior COVID-19 history/COVID-19 polymerase chain reaction	No/negative (Moderna 2nd)	No/negative (Pfizer, 1st)	No/negative (Moderna, 2nd)	No/negative (Moderna, 2nd)
Vaccine type	19 days	9 days	2 days	3 days
Time between last vaccination and symptom onset	24 days	14 days	3 days	3 days
Time between last vaccination and hospitalization	25 days and 101 days	14 days and 23 days	4 days	7 days
Time between last vaccination and biopsy	79 days	21 days	13 days	11 days
Hospitalization duration				
Laboratory				
Peak CK/CK-MB (IU/L)	2087/236	521/32	762/72	415/32
White blood cell count (on admission), / μ l	8200	8300	7900	8100
Eosinophil count (on admission), / μ l	107	50	103	0
CRP (on admission), mg/dl	8.09	3.61	2.51	2.91
BNP (on admission), pg/ml	349.6	361.7	62.5	15.5
BNP (at discharge), pg/ml	104.1	100.9	12.8	0.9
Troponin T (on admission), ng/ml	15.000	3.090	1.300	0.515
Troponin T (at discharge), ng/ml	0.034	0.036	0.035	0.032
LVEF (on admission), %	15	27	46	62
LVEF (at discharge), %	50	63	71	57
LV diastolic diameter, mm	64	44	54	43
Other findings	Mild pericardial effusion LV apical thrombus	Mild pericardial effusion	NA	NA
Treatment				
MCS	Impella, ECMO	Intra-aortic balloon pumping	No	No
Anti-inflammatory treatment	Methylprednisolone (1 g/day) prednisolone (50 mg/day)	Methylprednisolone (1 g/day) prednisolone (30 mg/day)	Methylprednisolone (1 g/day) prednisolone (50 mg/day) colchicine (1 mg/day)	Prednisolone (20 mg/day) NSAIDs colchicine (1 mg/day)
Other	Bisoprolol/ spironolactone Enalapril/amiodarone	Bisoprolol/ spironolactone	No	No

BNP, B-type natriuretic peptide; CK, creatine kinase; CRP, C-reactive protein; LV, left ventricular; LVEF, left ventricular ejection fraction; MCS, mechanical circulatory support; NA, not available; NSAID, non-steroidal anti-inflammatory drug; CK, creatine kinase; ECMO, extracorporeal membrane oxygenation.

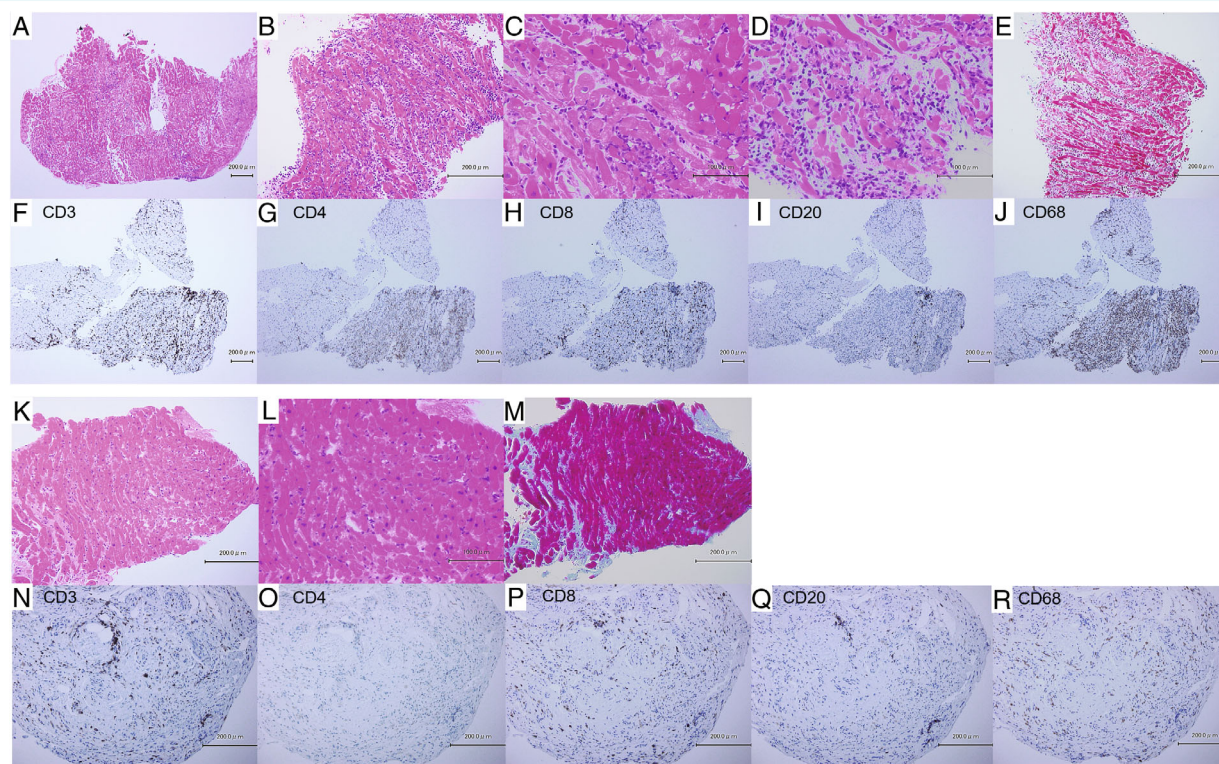


Figure 1 Case 1 presenting endomyocardial biopsy. Specimen obtained at 25 days (A–J) and at 101 days (K–R) after the second vaccination. The first endomyocardial biopsy specimen (A–J) shows severe lymphocytic myocarditis predominantly composed of cytotoxic T-cells (CD8+) and macrophages (CD68+) admixed with B-cells (CD20+) and a few eosinophils. The second biopsy specimen (K–R) shows a residual mild infiltration of lymphocytes. Immunostaining shows the infiltration of a small number of cytotoxic T-cells and B-cells. The macrophages almost disappeared.

and few B-lymphocytes (Figure 1A–J). After 3 days of intravenous methylprednisolone (1 g/day), cardiac troponin T and creatine kinase levels markedly decreased. The patient was haemodynamically stable and was weaned from mechanical circulatory support. After intravenous methylprednisolone, he started receiving oral prednisolone at a dose of 50 mg/day. Eventually, left ventricular ejection fraction improved to 50%, and his condition was stable. A second endomyocardial specimen was obtained to monitor myocarditis after discontinuing immunosuppressive therapy 101 days after vaccination, which revealed a residual, mild infiltration of lymphocytes. Immunostaining demonstrated the infiltration of a small number of CD8+ T-lymphocytes and B-lymphocytes, which was not observed in the previous specimen (Figure 1K–R).

Case 2

An 18-year-old woman developed fever, chest pain, and fatigue 9 days after receiving the first dose of the mRNA COVID-19 vaccine (BNT162b2 mRNA Pfizer-BioNTech). She visited the hospital on the 14th day after receiving the first dose. Cardiac troponin T (3.090 [reference range, 0–0.100] ng/ml) and creatine kinase levels (521 IU/L) were elevated. She tested negative for

COVID-19 by PCR testing. Echocardiography revealed severe left ventricular dysfunction (left ventricular ejection fraction, 27%). Due to cardiogenic shock, intra-aortic balloon pumping was introduced. Coronary angiography revealed no coronary artery disease. Simultaneously, an endomyocardial specimen was obtained from the right ventricular septum, which demonstrated marked inflammation mostly containing lymphocytes. Immunostaining revealed the marked infiltration of CD8+ T-lymphocytes, macrophages, a few CD4+ T-lymphocytes, B-lymphocytes, and eosinophils (Figure 2A–J). After 3 days of intravenous methylprednisolone, cardiac troponin T and creatine kinase levels markedly decreased, and her haemodynamic status stabilized. Left ventricular ejection fraction improved to 40%, and she was weaned from intra-aortic balloon pumping. After intravenous methylprednisolone, she received oral prednisolone (30 mg/day). A second endomyocardial specimen was obtained (23 days after vaccination), which revealed a mild infiltration of lymphocytes and replacement fibrosis. Immunostaining demonstrated the infiltration of CD8+ lymphocytes and a small number of B-lymphocytes, which was not observed in the previous specimen. Meanwhile, macrophages almost disappeared (Figure 2K–T). Left ventricular ejection fraction improved to 63%, and she was discharged. Myocarditis did not recur, even after 3 months of discontinuing the immunosuppressive therapy.

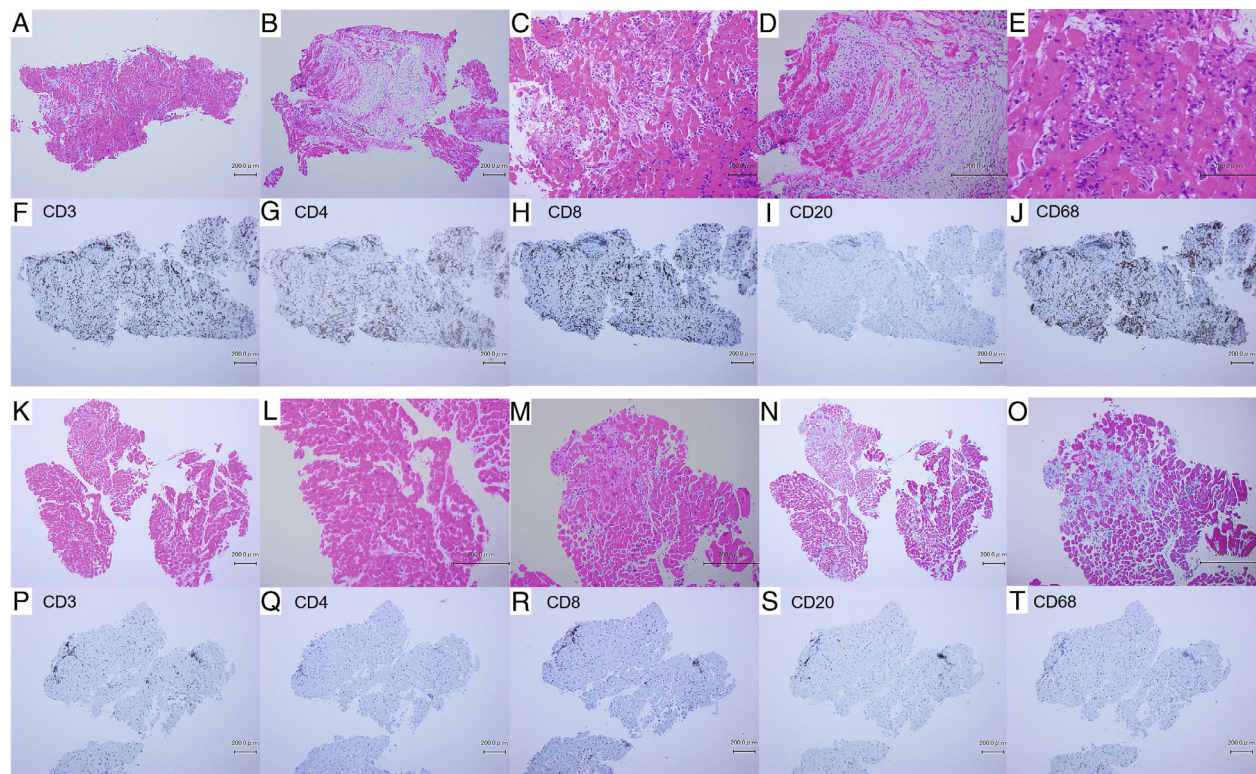


Figure 2 Case 2 presenting endomyocardial biopsy. Specimen obtained at 14 days (A–J) and at 23 days (K–T) after the first vaccination. The first endomyocardial biopsy specimen (A–J) shows severe lymphocytic myocarditis predominantly composed of cytotoxic T-cells (CD8+) and macrophages (CD68+). Few B-cells (CD20+) and eosinophils are observed. The second biopsy specimen (K–T) shows the infiltration of cytotoxic T-cells and a small number of B-cells. The macrophages almost disappeared.

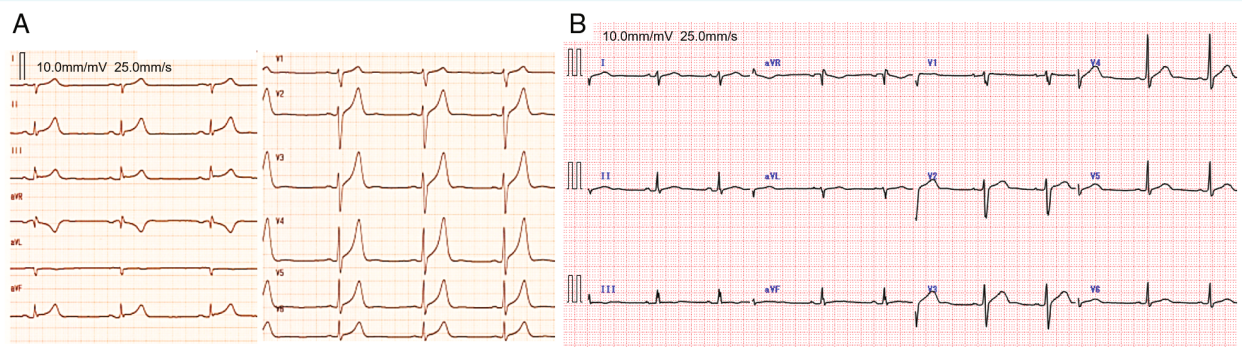


Figure 3 Case 3 presenting electrocardiographic findings. Electrocardiography at admission (A) demonstrated a mildly diffuse ST-segment and T-wave elevation. After 3 days from initiation of methylprednisolone treatment, electrocardiographic findings were normalized (B).

Case 3

An 18-year-old man presented to the hospital with fever and chest pain 3 days after receiving the second dose of the mRNA COVID-19 vaccine (mRNA-1273 Moderna). Electrocardiography demonstrated mildly diffuse ST-segment elevation, in addition to elevated cardiac troponin T (1.300 [reference range, 0–0.100] ng/ml) and creatine kinase levels (762 IU/L) (Figure 3). The patient

tested negative for COVID-19 by PCR testing. Echocardiography revealed mild left ventricular dysfunction (left ventricular ejection fraction, 46%). An endomyocardial specimen was obtained from the right ventricular septum. It revealed trivial lymphocytic infiltration but did not meet the histological criteria for myocarditis, although cardiomyocyte damage and perivascular and interstitial fibrosis were observed (Figure 4). Coronary angiography revealed no coronary artery disease. The patient was treated with

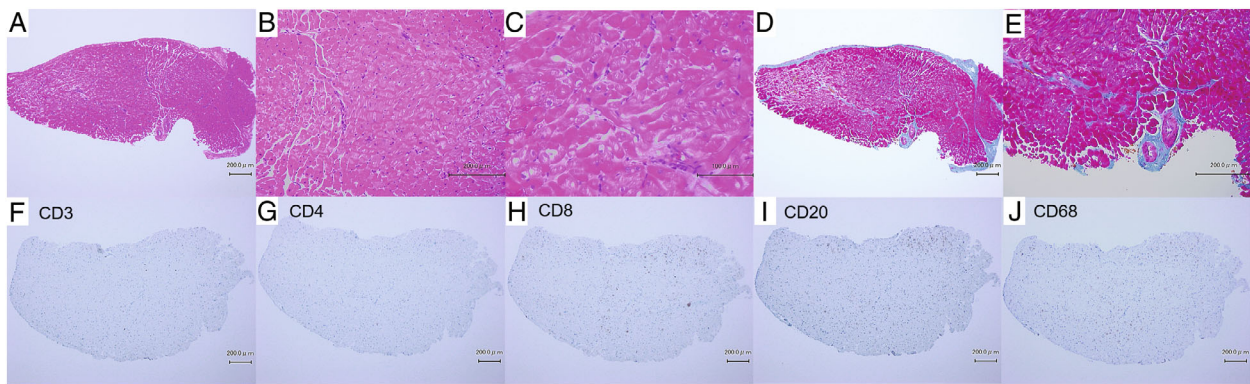


Figure 4 Case 3 presenting endomyocardial biopsy 4 days after the second vaccination. Inflammatory cell infiltration is trivial (a few cytotoxic T-cells and macrophages), but obvious cardiomyocyte damage (loss of nuclei and mild vacuolar degeneration) and perivascular and interstitial fibrosis are observed.

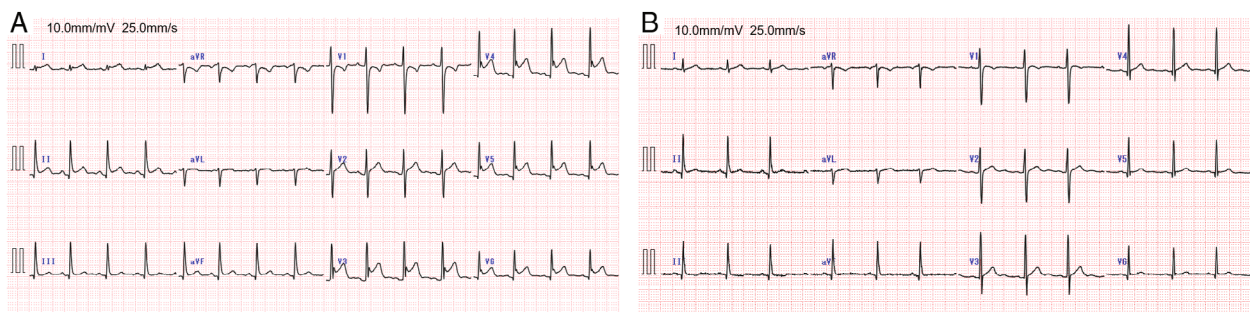


Figure 5 Case 4 presenting electrocardiographic finding. Electrocardiography at admission (A) demonstrated marked diffuse ST-segment elevation. After 2 days from initiation of prednisolone treatment, electrocardiographic findings were almost normalized (B).

intravenous methylprednisolone, followed by oral prednisolone (30 mg/day). Cardiac troponin T levels remained elevated while oral prednisolone was being tapered. Furthermore, the patient had chest pain associated with breathing and was suspected of having pericarditis. Therefore, colchicine was added to reduce the risk of recurrent pericarditis. Thereafter, cardiac troponin T levels decreased and normalized immediately. Left ventricular ejection fraction improved to 71%, and he was discharged.

Case 4

An 18-year-old man presented to the hospital with fever and chest pain 3 days after receiving the second dose of the mRNA COVID-19 vaccine (mRNA-1273 Moderna). He tested negative for COVID-19 by PCR testing. Electrocardiography demonstrated a marked diffuse elevation of the ST-segment, along with mildly elevated cardiac troponin T (0.515 [reference range, 0–0.100] ng/ml) and creatine kinase levels (412 IU/L) (Figure 5). Echocardiography revealed normal cardiac function. Since the patient had chest pain associated with breathing and was suspected of pericarditis, we prescribed non-steroidal anti-inflammatory drugs to relieve symptoms and colchicine to reduce the risk of recurrent pericarditis.

Cardiac troponin T and creatine kinase levels remained mildly elevated; thus, oral methylprednisolone (20 mg/day) was added the day after hospitalization. Consequently, cardiac troponin T and creatine kinase levels normalized immediately. An endomyocardial specimen was obtained from the right ventricular septum 3 days after initiating methylprednisolone. Lymphocytic infiltration was trivial and did not meet the histological criteria of myocarditis, but cardiomyocyte damage, interstitial oedema, and perivascular and interstitial fibrosis were observed. Immunostaining demonstrated a few CD8+ T-lymphocytes (Figure 6). Coronary angiography revealed no coronary artery disease. His condition became stable, and he was discharged.

Discussion

We present a case series of four patients suspected of acute myocarditis temporally associated with COVID-19 vaccination who underwent endomyocardial biopsy. Our report lacks information on cardiac magnetic resonance imaging but provides detailed pathological findings. COVID-19 vaccine-associated myocarditis is pathologically identified as lymphocytic myocarditis. Moreover,

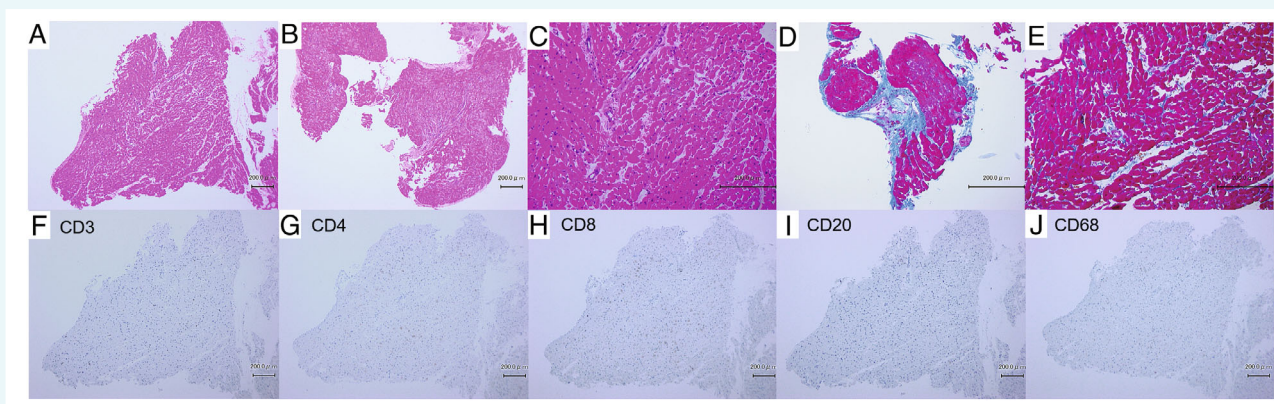


Figure 6 Case 4 presenting endomyocardial biopsy 7 days after the second vaccination. Inflammatory cell infiltration is trivial (a few cytotoxic T-cells), but cardiomyocyte damage, interstitial oedema, and perivascular and interstitial fibrosis are observed.

immunohistochemical staining demonstrated inflammatory infiltrates composed predominantly of CD8+ T-cells, macrophages, a few eosinophils, and rarely B-cells and CD4+ T-cells in fulminant myocarditis. These pathological findings were similar to those of a previous report on fulminant myocarditis occurring after receiving the mRNA COVID-19 vaccine.¹

The differential diagnosis of myocarditis varies, including viral myocarditis and myocarditis due to non-viral infections, drug reactions, and immune causes. In this study, we performed a multi-viral real-time PCR test capable of detecting 178 human viral genomes, including severe acute respiratory syndrome coronavirus 2 and myocarditis-inducing viruses, such as enteroviruses, adenovirus, parvoviruses, influenza virus, cytomegalovirus, and herpes virus, by extracting the nucleic acid from specimens.² No viral genome was detected in any case; therefore, we considered that viral myocarditis could be excluded. A PCR test conducted on endomyocardial biopsy tissue contributes to the diagnosis of viral myocarditis or cardiomyopathy.³ To our knowledge, this study is the first to demonstrate biopsy-proven myocarditis temporally associated with COVID-19 vaccination, with the exclusion of a viral aetiology on biopsy tissue, using a PCR test. This approach to exclude viral myocarditis is effective, especially in cases with a late onset following vaccination.

Typically, the onset of COVID-19 vaccine-associated myocarditis was reported to be within a few days after the second dose.^{4,5} The pathological findings in cases 3 and 4 indicated that inflammatory cell infiltration was mild and did not meet the histological definition of myocarditis.⁶ In case 4, the oral administration of prednisolone was initiated before myocardial biopsy, which may have affected inflammatory cell infiltration. However, obvious cardiomyocyte damage and interstitial and perivascular fibrosis were observed. We suspected these cases to be of myocarditis based on the acute onset of chest pain, biochemical evidence of myocardial injury, and ST changes on an electrocardiogram. The fact that cases 3 and 4 did not meet histological criteria of myocarditis may also reflect sampling bias.

A previous study reported that the occurrence of myocarditis in vaccinated individuals does not necessarily imply that the

vaccine alone was the cause; however, a previous viral infection may have triggered an autoimmune response persisting after viral clearance or acceleration of subclinical autoimmune myocarditis by a non-specific adjuvant effect of vaccination on the immune system.^{7,8} In our cases, the viral genome was not detected in the myocardial tissue; however, subclinical myocarditis or myocardial damage might have existed before vaccination. Further studies are needed to explore the potential mechanisms of vaccine-associated myocarditis, as well as the patient's immunological and genetic background, which could induce an excessive autoimmune response and vulnerability to vaccination.

On the contrary, the two cases that required mechanical circulatory support developed symptoms 19 and 9 days from the last dose, respectively, and both had severe inflammatory cell infiltration and severe cardiac dysfunction. It has been reported that another peak onset of myocarditis occurs a few weeks after the second dose.^{4,5} The mechanism and severity of myocarditis temporally associated with COVID-19 vaccination may differ based on how many days have passed since vaccination. However, it cannot be excluded that myocarditis particularly occurring weeks after the second dose is simply unrelated to the vaccine, reflecting naturally occurring immune-mediated myocarditis.

In two cases, myocardial biopsies were performed for the second time to confirm the healing of myocarditis in case 1 and monitor the patient's response to immunosuppressive therapy in case 2. In case 2, the rapid improvement in inflammation may suggest that immunosuppressive therapy was effective. In all four cases, myocardial enzyme levels markedly decreased after initiating immunosuppressive therapy. Immunosuppressive therapy is contraindicated in patients with viral myocarditis, whereas it is safe and effective in patients with biopsy-proven virus-negative myocarditis, as shown in these cases. Therefore, endomyocardial biopsy, including viral work-up on tissues, should be performed to reach a diagnosis of certainty, that is, an aetiological diagnosis and start aetiology-driven therapy in suspected myocarditis cases temporally associated with COVID-19 vaccination.^{6,7,9,10} Although inflammation markedly improved in case 1, mild inflammation was confirmed approximately 3 months after the second dose. There

is no other evidence demonstrating the recurrence of myocarditis; however, residual inflammatory cells suggested that autoimmune myocarditis may continue and require close long-term follow-up.

Prednisolone was tapered and discontinued in all cases, but no evident recurrence of myocarditis was observed. It is necessary to establish a biopsy-proven diagnosis and complete viral work-up in patients with clinically suspected myocarditis temporally associated with COVID-19 vaccination. Since temporal association does not prove causation, it cannot be excluded that the two biopsy-proven cases of myocarditis reported here are simply a random association of a naturally occurring virus-negative immune-mediated lymphocytic myocarditis occurring after vaccination, which responded to steroid treatment, as other forms of virus-negative immune-mediated myocarditis.

Acknowledgements

We would like to thank Dr. Harutaka Katano and Dr. Tadaki Suzuki of the National Institute of Infectious Diseases for their assistance with this study.

Conflict of interest: none declared.

References

1. Verma AK, Lavine KJ, Lin CY. Myocarditis after Covid-19 mRNA vaccination. *N Engl J Med.* 2021;**385**:1332–4.
2. Katano H, Kano M, Nakamura T, Kanno T, Asanuma H, Sata T. A novel real-time PCR system for simultaneous detection of human viruses in clinical samples from patients with uncertain diagnoses. *J Med Virol.* 2011;**83**:322–30.
3. Caforio AL, Calabrese F, Angelini A, Tona F, Vinci A, Bottaro S, et al. A prospective study of biopsy-proven myocarditis: prognostic relevance of clinical and aetiopathogenetic features at diagnosis. *Eur Heart J.* 2007;**28**:1326–33.
4. Witberg G, Barda N, Hoss S, Richter I, Wiessman M, Aviv Y, et al. Myocarditis after Covid-19 vaccination in a large health care organization. *N Engl J Med.* 2021;**385**:2132–9.
5. Mevorach D, Anis E, Cedar N, Bromberg M, Haas EJ, Nadir E, et al. Myocarditis after BNT162b2 mRNA vaccine against Covid-19 in Israel. *N Engl J Med.* 2021;**385**:2140–9.
6. Caforio AL, Pankuweit S, Arbustini E, Basso C, Gimeno-Blanes J, Felix SB, et al.; European Society of Cardiology Working Group on Myocardial and Pericardial Diseases. Current state of knowledge on aetiology, diagnosis, management, and therapy of myocarditis: a position statement of the European Society of Cardiology Working Group on Myocardial and Pericardial Diseases. *Eur Heart J.* 2013;**34**:2648a–2648d.
7. Caforio ALP. Receipt of mRNA vaccine against Covid-19 and myocarditis. *N Engl J Med.* 2021;**235**:2189–90.
8. Caforio ALP, Baritussio A, Basso C, Marcolongo R. Clinically suspected and biopsy-proven myocarditis temporally associated with SARS-CoV-2 infection. *Annu Rev Med.* 2021;**27**:149–66.
9. McDonagh TA, Metra M, Adamo M, Gardner RS, Baumback A, Böhm M, et al. 2021 ESC Guidelines for the diagnosis and treatment of acute and chronic heart failure: developed by the Task Force for the diagnosis and treatment of acute and chronic heart failure of the European Society of Cardiology (ESC). With the special contribution of the Heart Failure Association (HFA) of the ESC. *Eur J Heart Fail.* 2022;**24**:4–131.
10. Seferovic PM, Tsutsui H, McNamara DM, Ristić AD, Basso C, Bozkurt B, et al. Heart Failure Association of the ESC, Heart Failure Society of America and Japanese Heart Failure Society position statement on endomyocardial biopsy. *Eur J Heart Fail.* 2021;**23**:854–71.