

ECHO EDUCATION

CRITICAL CARE ECHO ROUNDS

Echo in cardiac arrest

**Andreas Zafiropoulos MA BMBCh MRCP FRCA, Kaleab Asress MA BMBCh MRCP^{1,2},
Simon Redwood MD FRCP FACC FSCAI³, Stuart Gillon MBChB MRCP FFICM⁴ and
David Walker MRCP FRCA FFICM^{5,6}**

Anaesthetics and Intensive Care, St Bartholomew's Hospital, London, UK

¹Cardiology, St Thomas' Hospital, London, UK

²King's Health Partners, London, UK

³King's College London, St Thomas' Hospital, London, UK

⁴Intensive Care, King's College Hospital, London, UK

⁵Anaesthesia and Critical Care Medicine, University College Hospital, London, UK

⁶University College, London, UK

Correspondence
should be addressed
to A Zafiropoulos
Email
ajzafiropoulos@gmail.com

Abstract

Management of medical cardiac arrest is challenging. The internationally agreed approach is highly protocolised with therapy and diagnosis occurring in parallel. Early identification of the precipitating cause increases the likelihood of favourable outcome. Echocardiography provides an invaluable diagnostic tool in this context. Acquisition of echo images can be challenging in cardiac arrest and should occur in a way that minimises disruption to cardiopulmonary resuscitation (CPR). In this article, the reversible causes of cardiac arrest are reviewed with associated echocardiography findings.

Case:

A 71-year-old patient underwent right upper lobectomy for lung adenocarcinoma. On the 2nd post-operative day, he developed respiratory failure with rising oxygen requirement and right middle and lower lobe collapse and consolidation on chest X-ray. He was commenced on high-flow oxygen therapy and antibiotics. His condition continued to deteriorate and on the 3rd post-operative day he was intubated and mechanically ventilated. Six hours after intubation, he became suddenly hypotensive with a blood pressure of 50 systolic and then lost cardiac output. ECG monitoring showed pulseless electrical activity. CPR was commenced and return of circulation occurred after injection of 1 mg of adrenaline. Focused echocardiography was performed, which demonstrated signs of massive pulmonary embolism. Thrombolytic therapy with tissue plasminogen activator was given and his condition stabilised.

Introduction

Cardiac arrest is defined as the absence of a centrally palpable pulse and no respiratory effort in an unresponsive patient (1). Immediate management of medical cardiac arrest should proceed in a protocolised fashion in line with current UK Resuscitation Council guidance (1). Cardiopulmonary resuscitation (CPR) is commenced and the cardiac rhythm is assessed.

There are four rhythms associated with cardiac arrest, which are divided into 'shockable', which may be

managed with defibrillation, and 'non-shockable', categories, in which defibrillation carries no benefit. Ventricular fibrillation and pulseless ventricular tachycardia fall into the 'shockable' category and are associated with relatively good outcomes. Pulseless electrical activity (PEA) (electrical activity on the ECG with no palpable pulse) and asystole (absence of electrical activity) fall into the non-shockable category and management is focused on high-quality CPR and i.v. adrenaline boluses.

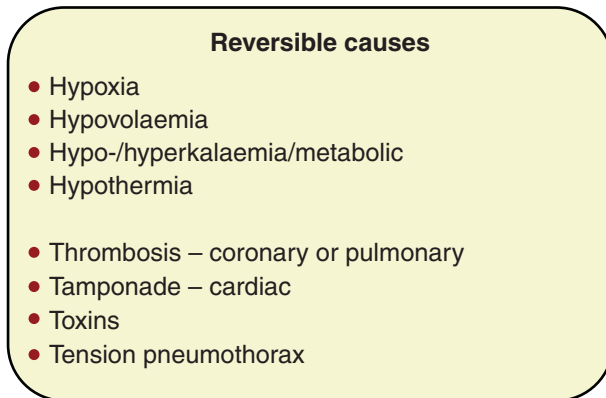


Figure 1

Four H's and four T's mnemonic. Reproduced with the kind permission of the Resuscitation Council (UK) (Deakin C, Nolan J, Perkins G & Lockey A 2010 UK Resuscitation Council 2010 guidelines. Available at: www.resus.org.uk/pages/guide.htm. Accessed 17th May 2014).

In parallel to resuscitation, attempts should be made to elucidate the cause of the arrest and treat it. The widely used 'four H's and four T's' mnemonic (Fig. 1) can be used to guide the diagnostic process. Focused echocardiography is invaluable in confirming or excluding many of these reversible causes. It is also useful in the time which immediately precedes and follows cardiac arrest. Early and rapid identification of the precipitating cause during this period will assist in stabilisation of the the patient, and may prevent progression to cardiac arrest in the first place.

The practicalities of echocardiography in cardiac arrest

The cardiac arrest environment is busy, with multiple personnel undertaking several time critical tasks simultaneously. Current ALS guidelines prioritise chest compressions and, where appropriate, timely defibrillation. The cardiac arrest team leader is responsible for coordinating the team and ensuring compliance with accepted guidelines.

Performing echocardiography in the cardiac arrest setting is challenging. The International Liaison Committee on Resuscitation and the UK Resuscitation Council recommend the requirement of significant training to effectively undertake it. The operators must be aware of the importance of uninterrupted chest compressions during CPR. The 10-s pulse check is a useful time window during which focused echocardiography can be performed. At this point, chest compressions cease whilst central pulses are sought and the underlying electrical activity is analysed. Given the brevity of this opportunity, forward planning is essential. Depth and gain settings must be pre-optimised. The subcostal window often yields the most useful views with the least interruption to CPR. However, in experienced hands, other views can be sought (parasternal and apical) and echocardiography can be performed with compressions ongoing. The findings of focused echocardiography should be communicated to the team leader.

Focused Echo Evaluation in Life support (FEEL), is a training programme available to clinicians who wish to practice echocardiography in the cardiac arrest setting. As well as ensuring a basic competence level, the FEEL protocol provides an algorithm, whereby a 'quick look' echocardiography view can be obtained during the 10-s pulse check, minimising the disruption to CPR (2, 3). FEEL courses teaching the FEEL protocol are now administered by the UK Resuscitation Council and endorsed by the British Society of Echocardiography.

Hypovolaemia

Inadequate circulating volume is among the commonest causes of PEA cardiac arrest (4). In some cases, for example, major external haemorrhage, identifying hypovolaemia is easy. In other cases, volume loss is occult and co-exists with other pathologies, making the situation more complex. Both static and dynamic echocardiographic measures can be used for the assessment of hypovolaemia

Table 1 Echocardiographic signs of hypovolaemia.

Parameter	Static/dynamic	Finding suggestive of hypovolaemia	Pitfalls
LV cavity size and function	Dynamic	Small, hyperkinetic with end-systolic cavity obliteration	Inotropic support, severe valvular regurgitation, left ventricular hypertrophy
LV end-diastolic area	Static	5.5 cm ² /m ² BSA	As above
IVC size and inspiratory collapse	Dynamic	> 10 mm collapse on inspiration	Spontaneously breathing patients in sinus rhythm only
IVC size and expiratory collapse	Dynamic	Variable	Intubated and mechanically ventilated. Sinus rhythm only

LV, left ventricle; BSA, body surface area; IVC, inferior vena cava.

Table 2 Echocardiographic indices of fluid responsiveness.

Parameter	Static/ dynamic	Finding suggestive of fluid respon- siveness	Pitfalls
SVC collapsibility index	Dynamic	> 36%	Fully mechanically ventilated. Sinus rhythm
IVC distensibility index	Dynamic	> 18%	Fully mechanically ventilated. Sinus rhythm
LV ejection fraction	Dynamic	LVOT Vmax variation > 12% LVOT VTI variation > 18%	Fully mechanically ventilated. Sinus rhythm

SVC, superior vena cava; IVC, inferior vena cava; LV, left ventricle; LVOT, left ventricular outflow tract; VTI, velocity-time integral.

and these are summarised in Table 1 (5, 6, 7, 8, 9, 10). Static measures will be easier to obtain, particularly in the cardiac arrest and peri-arrest settings, but are more prone to error and misinterpretation. Care should be taken to ensure that the patient fulfills the criteria for the measurement being used (11).

Other echocardiographic indices have been validated to predict fluid responsiveness and these are summarised in Table 2 (12). Fluid-responsive patients will react to the infusion of i.v. fluid with an increase in stroke volume and cardiac output, according to the Frank–Starling mechanism (13). Fluid responsiveness may be seen in both hypovolaemic and euvoalaemic patients. The prediction of fluid responsiveness requires the use of dynamic indices based on heart–lung interactions, which are difficult or impossible to obtain in the cardiac arrest setting. These have been discussed in detail in a previous ‘Critical Care Echo Round’ (26). Finally, it should be emphasised that echocardiography is a useful adjunct, but not a substitute for clinical judgement. Basic, essential fluid resuscitation should not be withheld on the basis of echocardiography findings alone.

Tension pneumothorax

A 5.4% of major trauma patients were found to have tension pneumothorax in one pre-hospital study (14) and post-mortem examinations suggest that tension pneumothorax may be an occult cause of death in intensive care (15). Diagnosis is largely clinical and can be challenging. The classical signs of mediastinal deviation, absent breath sounds and cardiovascular

collapse may be late and variably present (16). Ultrasound is not a substitute for clinical judgement but can be a useful adjunct to confirm or exclude the diagnosis. It has a higher sensitivity than conventional chest X-ray for the detection of pneumothorax. In one study, ultrasound showed a sensitivity of 95% for detection of pneumothorax in intensive care unit patients (17).

Both the phased-array echo probe and the standard curvilinear probe can be used to evaluate the pneumothorax lung. Scanning is performed along a line following the rib space from the mid-clavicular line anteriorly to the mid axillary line posteriorly. Demonstration of the ‘seashore sign’, ‘A-lines’, ‘B-lines’ and the ‘lung pulse’ confirms the apposition of the visceral and parietal pleura and excludes pneumothorax in the area being visualised (Figs 2, 3, 4 and 5). A-lines are horizontal reflection artefacts generated by the pleural layers. B-lines extend radially from the pleura and when present, confirm

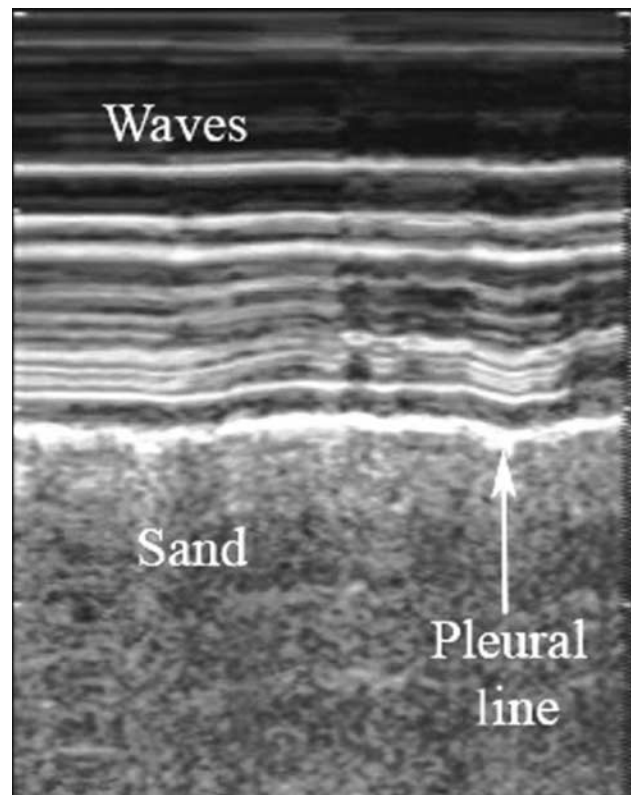


Figure 2 Seashore sign in M-mode. The pleural line divides the image in half. The motionless portion above the image creates horizontal lines (waves). The moving lung below creates a granular pattern (sand). This image is licensed under CC BY-NC-SA 3.0, and reproduced from Husain LF, Hagopian L, Wayman D, Baker WE & Carmody KA 2012 Sonographic diagnosis of pneumothorax. *Journal of Emergencies, Trauma, and Shock* 5 76–81. doi:10.4103/0974-2700.93116

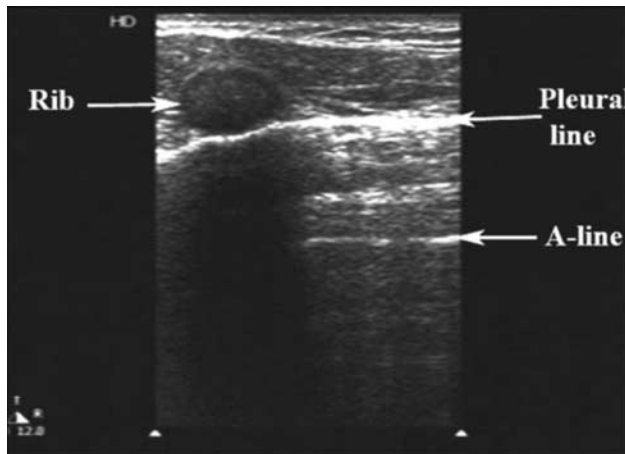


Figure 3

A-lines, a type of reverberation artifact, are horizontal regularly spaced lines originating from the bright white pleural line. Their presence excludes pneumothorax in the sector. This image is licensed under [CC BY-NC-SA 3.0](#), and reproduced from Husain LF, Hagopian L, Wayman D, Baker WE & Carmody KA 2012 Sonographic diagnosis of pneumothorax. *Journal of Emergencies, Trauma, and Shock* 5 76–81. doi:10.4103/0974-2700.93116

that the visceral and parietal layers are in contact with one another. Conversely, if a pneumothorax is present, the ‘lung point’ may be demonstrated at the junction between normal lung and pneumothorax (Fig. 6) (18). A diagnostic algorithm has now been developed incorporating these signs (Fig. 7).

Pulmonary embolism

Pulmonary embolism (PE) is well recognised as a potentially reversible cause of cardiac arrest. In a retrospective study of 1246 cardiac arrest victims presenting to a tertiary hospital in Vienna, PE was found as the cause of death in 4.8%. Echocardiography was used to confirm the diagnosis of PE in 40% of these cases (19). The British Thoracic Society recommends the use of echocardiography in the risk stratification of patients with PE, and as a diagnostic tool in haemodynamically unstable patients (20). The reported sensitivity of echocardiography in the diagnosis of PE of any severity is ~60% (21). Therefore, absence of echocardiographic criteria cannot be used to rule out PE in all patients concerned. In patients presenting with shock or cardiovascular instability, however, echocardiography is more useful. The absence of signs of right ventricular (RV) overload or dysfunction effectively excludes PE as a cause (21). Conversely, if signs of RV dysfunction are present in a patient with haemodynamic instability and clinical probability of PE, aggressive treatment is indicated and this approach results in acceptable 30-day outcome (22).

During massive PE causing cardiac arrest, it is likely that at least two-thirds of the pulmonary vascular bed is obstructed (11). Sudden increase in afterload results in dilation of the right ventricle. This may be detectable as an increase in RV diameter >30 mm in the parasternal long-axis view or as an increase in the area of the RV as compared with the left ventricle (LV) to >90% in the apical four-chamber view. High RV systolic pressures will cause flattening of the inter-ventricular septum (D-shaped septum) and paradoxical movement. Backwards pressure will cause an increase in size and a decrease in respiratory variation of the inferior vena cava in the subcostal view. Occasionally, clot may be visible in the RV, the RV outflow tract or the pulmonary arteries.

Cardiac tamponade

Cardiac tamponade is a life-threatening clinical syndrome caused by an increase in pericardial pressure, most commonly due to fluid, that impairs the ability of the heart to fill and pump. As intra-pericardial pressure rises and begins to exceed right heart pressure, parts of the cardiac chambers collapse during the cardiac cycle. Clinical signs typically appear before the left heart is affected.

It is a clinical diagnosis based on tachycardia (>100 beats/min), hypotension (<100 mmHg systolic), pulsus paradoxus (>10 mmHg drop in blood pressure on inspiration), and neck vein distention with elevated jugular venous pressure (23). The differential diagnosis is extensive, and the clinical presentation can be challenging

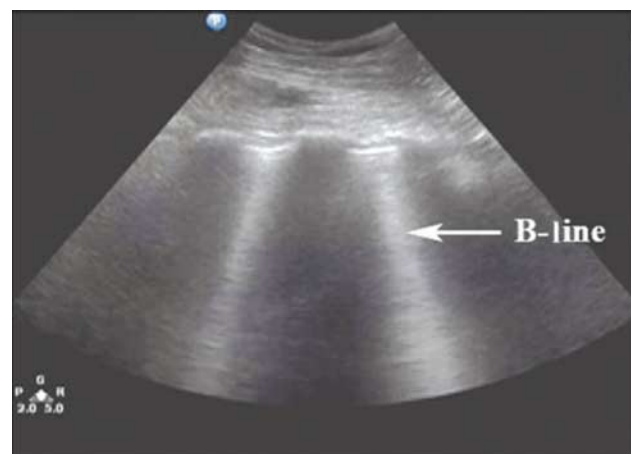


Figure 4

B-lines are seen originating from the pleural line and extending to the edge of the screen. They confirm apposition of the pleura and exclude pneumothorax. This image is licensed under [CC BY-NC-SA 3.0](#), and reproduced from Husain LF, Hagopian L, Wayman D, Baker WE & Carmody KA 2012 Sonographic diagnosis of pneumothorax. *Journal of Emergencies, Trauma, and Shock* 5 76–81. doi:10.4103/0974-2700.93116

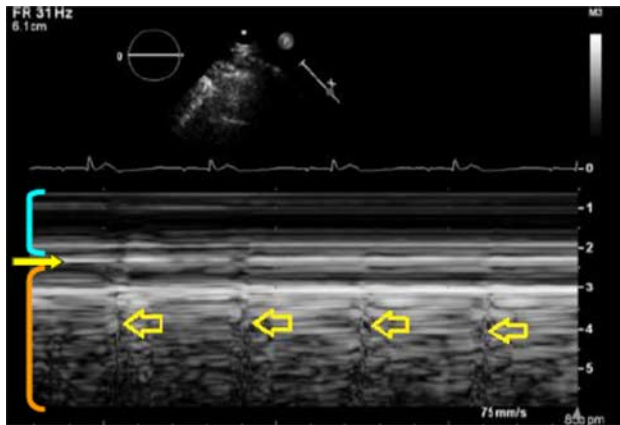


Figure 5
M-mode scanning of normal lung during a breath hold. The lung pulse is seen as a small movement synchronous with the heartbeat (arrows). Reproduced with the kind permission of the Resuscitation Council (UK) (Deakin C, Nolan J, Perkins G & Lockey A 2010 UK Resuscitation Council 2010 guidelines. Available at: www.resus.org.uk/pages/guide.htm. Accessed 17th May 2014).

to interpret in some cases (24). It should be noted that in trauma patients presenting with PEA and absence of hypovolaemia or tension pneumothorax, cardiac tamponade is the most common cause (25).

Echocardiography is the diagnostic method of choice in suspected cardiac tamponade and should be performed without delay. The most common finding is that of a pericardial effusion. The size of the effusion can be misleading, as it is the rate of accumulation of fluid that determines the clinical course. If pericardial fluid accumulates quickly, even small volumes (<250 ml) may cause tamponade. A more slowly accumulating effusion may reach a volume of as much as 1.5 l before significant elevation of pericardial pressure takes place.

The earliest 2D echocardiography finding is that the chamber with the lowest pressure, the right atrium, begins to collapse during ventricular diastole. As tamponade develops, the proportion of diastole during which the atrium is collapsed becomes greater and greater. As the pressure rises further, parts of the right ventricle start to collapse in diastole as well – firstly the RV outflow tract, and then the right ventricle itself.

Tamponade also causes exaggerated respiratory variations in right and left ventricular inflow patterns which can be measured with Doppler. In the normal state in a spontaneously breathing patient, mitral inflow velocities are slightly lower in inspiration than expiration and tricuspid inflow velocities are *vice versa*. This phenomenon is exaggerated in tamponade such that a respiratory variation

in the peak mitral or tricuspid inflow velocity (E-wave) of >25% supports the diagnosis. Unsurprisingly, respiratory variation of inflow velocity is tracked by corresponding variation in right and left ventricular volumes. This too can be demonstrated echocardiographically by M-mode scanning in the parasternal views. It is important to note that the respiratory variations described apply to spontaneously breathing patients. During invasive ventilation, intra-thoracic pressure rises in inspiration not expiration. The situation may be further complicated if the patient is taking some spontaneous breaths and also being given mandatory breaths by the ventilator.

Myocardial ischaemia

Myocardial ischaemia resulting in cardiac arrest most commonly results from acute ST-elevation myocardial infarction (STEMI). This results from plaque rupture and acute occlusion of one of the three main epicardial coronary arteries. Cardiac arrest from a non-STEMI can also occur. Ventricular arrhythmias can precipitate global myocardial ischaemia arising from an unsustainable rhythm disturbance, either from intrinsic cardiac pathology or electrolyte disturbances. Although STEMI is often heralded by typical symptoms and ECG findings, these are not always present in unexplained cardiac arrest. The echo findings suggestive of an acute myocardial infarction are significant regional wall motion abnormalities. Ischaemia of the left anterior descending artery

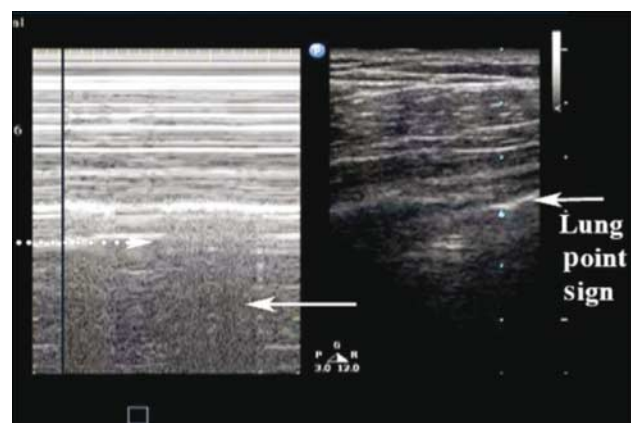


Figure 6
Lung point sign (M-mode). Alternating seashore sign with absence of lung movement at the point where the lung edge moves in and out of the scan area with respiration. Diagnostic of pneumothorax. This image is licensed under CC BY-NC-SA 3.0, and reproduced from Husain LF, Hagopian L, Wayman D, Baker WE & Carmody KA 2012 Sonographic diagnosis of pneumothorax. *Journal of Emergencies, Trauma, and Shock* 5 76–81. doi:10.4103/0974-2700.93116

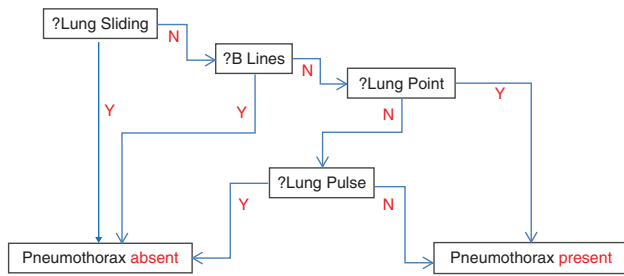


Figure 7

Algorithm for the diagnosis of pneumothorax with ultrasound. Reproduced with the kind permission of the Resuscitation Council (UK) (Deakin C, Nolan J, Perkins G & Lockey A 2010 UK Resuscitation Council 2010 guidelines. Available at: www.resus.org.uk/pages/guide.htm. Accessed 17th May 2014).

will cause abnormal motion in the LV septum, apex and anterior wall. Ischaemia in the circumflex artery will cause abnormal motion in the lateral and inferior walls. Ischaemia in the right coronary artery most commonly affects the inferior and inferolateral (also known as posterior) walls and the basal part of the septum. It should be noted that coronary artery anatomy, in particular the right coronary, is variable and the above is a broad outline only. These regions may have reduced thickening (hypokinesia), or may not be moving at all (akinetic). Findings consistent with previous ischaemia or infarction include thinned myocardial segments and aneurysmal areas, which may have associated mural thrombus.

Complications of myocardial infarction can also result in cardiovascular instability and cardiac arrest. Mitral valve papillary muscles may rupture resulting in severe mitral insufficiency. This is well demonstrated in parasternal and apical views. Ventricular septal defect may occur following infarction of the septum, often from a proximal left anterior descending artery lesion. The resulting left-to-right shunt can be seen on colour-flow Doppler.

Frequently, problems in other organ systems will cause cardiac dysfunction as well. This is particularly common in the peri-arrest and cardiac arrest settings. Septic shock, intracranial hypertension and electrolyte disturbances can all affect the ability of the heart to fill and pump. Aortic pathology such as type A aortic dissection can extend backwards to affect the ostia of the coronary arteries and the aortic valve. In this case, echocardiography may demonstrate both the intra-cardiac and the aortic pathology.

Conclusion

Bedside echocardiography in the context of cardiac arrest, and the surrounding period, is an invaluable tool to

rapidly assess myocardial structure and function, pulmonary pathology and fluid status. With appropriate training and availability of scanning hardware in the emergency setting, the common causes described in this article can be evaluated within the confines of the peri-arrest period. Though it is no replacement for formal imaging, the techniques highlighted here can rapidly provide many of the answers required to resuscitate and stabilise a patient with the potential to improve their outcome.

Declaration of interest

The authors declare that there is no conflict of interest that could be perceived as prejudicing the impartiality of the research reported.

Funding

This research did not receive any specific grant from any funding agency in the public, commercial or not-for-profit sector.

References

- Deakin C, Nolan J, Perkins G & Lockey A 2010 UK Resuscitation Council 2010 guidelines. Available at: www.resus.org.uk/pages/guide.htm. Accessed 17th May 2014.
- FEEL UK. Available at: www.FEEL-UK.com. Accessed 17th May 2014.
- Breitkreutz R, Walcher F & Seeger F 2007 Focused echocardiographic evaluation in resuscitation management: concept of an advanced life support-conformed algorithm. *Critical Care Medicine* **35** S150–S161. (doi:10.1097/01.CCM.0000260626.23848.FC)
- Hughes S & McQuillan PJ 1998 Sequential recall of causes of electromechanical dissociation (EMD). *Resuscitation* **37** 51. (doi:10.1016/S0300-9572(98)00028-8)
- Leung J & Levine E 1994 Left ventricular end-systolic cavity obliteration as an estimate of intraoperative hypovolaemia. *Anesthesiology* **81** 1102–1109. (doi:10.1097/0000542-199411000-00003)
- Bernardin G & Mazerolles M 2004 Les critères hémodynamiques statiques prédictifs de l'efficacité d'un remplissage vasculaire [Static haemodynamic criteria predictive of fluid responsiveness]. *Réanimation* **13** 288–298. (doi:10.1016/j.reaurg.2004.03.007)
- Kircher B, Himelman R & Schiller N 1990 Noninvasive estimation of right atrial pressure from the inspiratory collapse of the inferior vena cava. *American Journal of Cardiology* **66** 493–496. (doi:10.1016/0002-9149(90)90711-9)
- Lyon M, Blaivas M & Branman M 2005 Sonographic measurement of the inferior vena cava as a marker of blood loss. *American Journal of Emergency Medicine* **23** 45–50. (doi:10.1016/j.ajem.2004.01.004)
- Jue J, Chung W & Schiller N 1992 Does inferior vena cava size predict right atrial pressure in patients receiving mechanical ventilation? *Journal of the American Society of Echocardiography* **5** 613–619. (doi:10.1016/S0894-7317(14)80327-1)
- Lichtenstein D & Jardin F 1994 Appréciation non invasive de la pression veineuse centrale par la mesure échographique du calibre de la veine cave inférieure en réanimation [Non-invasive measurement of the central venous pressure using echocardiographic assessment of the inferior vena cava diameter during resuscitation]. *Réanimation Urgences* **3** 79–82. (doi:10.1016/S1164-6756(05)80777-7)
- Price S, Uddin S & Quinn T 2010 Echocardiography in cardiac arrest. *Current Opinion in Critical Care* **16** 211–215. (doi:10.1097/MCC.0b013e3283399d4c)

- 12 Michard F & Teboul J-L 2002 Predicting fluid responsiveness in ICU patients: a critical analysis of the evidence. *Chest* **121** 2000–2008. (doi:10.1378/chest.121.6.2000)
- 13 Starling EH & Visscher MB 1926 The regulation of the energy output of the heart. *Journal of Physiology* **62** 243–261.
- 14 Coats TJ, Wilson AW & Xeropotamous N 1995 Pre-hospital management of patients with severe thoracic injury. *Injury* **2** 581–585. (doi:10.1016/0020-1383(95)00107-K)
- 15 Saltet JF 1979 Pneumothorax. *Lancet* **1** 671. (doi:10.1016/S0140-6736(79)91114-0)
- 16 Leigh-Smith S & Harris T 2005 Tension pneumothorax – time for a re-think? *Emergency Medicine Journal* **22** 8–16. (doi:10.1136/emj.2003.010421)
- 17 Lichtenstein DA & Menu Y 1995 A bedside ultrasound sign ruling out pneumothorax in the critically ill. Lung sliding. *Chest* **108** 1345–1348. (doi:10.1378/chest.108.5.1345)
- 18 Husain LF, Hagopian L, Wayman D, Baker WE & Carmody KA 2012 Sonographic diagnosis of pneumothorax. *Journal of Emergencies, Trauma, and Shock* **5** 76–81. (doi:10.4103/0974-2700.93116)
- 19 Kurkciyan I, Meron G, Sterz F, Janata K, Domanovits H, Holzer M, Berzlanovich A, Bankl HC & Laggner AN 2000 Pulmonary embolism as cause of cardiac arrest: presentation and outcome. *Archives of Internal Medicine* **160** 1529–1535. (doi:10.1001/archinte.160.10.1529)
- 20 British Thoracic Society Standards of Care Committee Pulmonary Embolism Guideline Development Group 2003 British Thoracic Society guidelines for the management of suspected acute pulmonary embolism. *Thorax* **58** 470–484. (doi:10.1136/thorax.58.6.470)
- 21 Torbicki A, Perrier A, Konstantinides S, Agnelli G, Galiè N, Pruszczyk P, Bengel F, Brady AJ, Ferreira D, Janssens U *et al.* 2008 Guidelines on the diagnosis and management of acute pulmonary embolism: the Task Force for the diagnosis and management of acute pulmonary embolism of the European Society of Cardiology (ESC). *European Heart Journal* **29** 2276–2315. (doi:10.1093/eurheartj/ehn310)
- 22 Kucher M, Luder CM, Dornhofer T, Windecker S, Meier B & Hess OM 2003 Novel management strategy for patients with suspected pulmonary embolism. *European Heart Journal* **24** 366–376. (doi:10.1016/S0195-668X(02)00476-1)
- 23 Maisch B, Seferović PM, Ristić AD, Erbel R, Rienmüller R, Adler Y, Tomkowski WZ, Thiene G, Yacoub MH, Priori SG *et al.* 2004 Guidelines on the diagnosis and management of pericardial diseases executive summary: the Task Force on the diagnosis and management of pericardial diseases of the European Society of Cardiology. *European Heart Journal* **5** 587–610. (doi:10.1016/j.ehj.2004.02.002)
- 24 Spodick DH 2003 Acute cardiac tamponade. *New England Journal of Medicine* **349** 684–690. (doi:10.1056/NEJMra022643)
- 25 2005 American Heart Association Guidelines for Cardiopulmonary Resuscitation and Emergency Cardiovascular Care 2005 Part 10.7: Cardiac arrest associated with trauma. *Circulation* **112** (suppl 24) IV-146–IV-149. (doi:10.1161/CIRCULATIONAHA.105.166569)
- 26 Roshdy A, Francisco N, Rendon A, Gillon S & Walker D 2014 CRITICAL CARE ECHO ROUNDS: Haemodynamic instability. *Echo Research and Practice* **1** D1–D8. (doi:10.1530/ERP-14-0008)

Received in final form 23 August 2014

Accepted 9 October 2014