

Received:
01 September 2021

Revised:
27 October 2021

Accepted:
08 November 2021

© 2022 The Authors. Published by the British Institute of Radiology under the terms of the Creative Commons Attribution 4.0 Unported License <http://creativecommons.org/licenses/by/4.0/>, which permits unrestricted use, distribution and reproduction in any medium, provided the original author and source are credited.

Cite this article as:

Lombardi G, Spimpolo A, Berti S, Campi C, Anglani MG, Simeone R, et al. PET/MR in recurrent glioblastoma patients treated with regorafenib: [¹⁸F]FET and DWI-ADC for response assessment and survival prediction. *Br J Radiol* 2021; **95**: 20211018.

FULL PAPER

PET/MR in recurrent glioblastoma patients treated with regorafenib: [¹⁸F]FET and DWI-ADC for response assessment and survival prediction

¹GIUSEPPE LOMBARDI, ²ALESSANDRO SPIMPOLO, ²SARA BERTI, ³CRISTINA CAMPI, ⁴MARIA GIULIA ANGLANI, ²ROSSELLA SIMEONE, ²LAURA EVANGELISTA, ⁴FRANCESCO CAUSIN, ⁵GIOVANNI ZORZI, ⁶GIANCARLO GORGONI, ¹MARIO CACCESE, ¹MARTA PADOVAN, ¹VITTORINA ZAGONEL and ²DIEGO CECCHIN

¹Department of Oncology, Oncology 1, Veneto Institute of Oncology – IRCCS, Padua, Italy

²Nuclear Medicine Unit, Department of Medicine - DIMED, Padua University Hospital, Padua, Italy

³Department of Mathematics, University of Genoa, Genoa, Italy

⁴Neuroradiology Unit, Azienda Ospedaliera di Padova, Padua, Italy

⁵Department of Neurosciences (DNS), University of Padua, Padua, Italy

⁶Radiopharmacy, Sacro Cuore Don Calabria Hospital, Negrar, Verona, Italy

Address correspondence to: Prof Diego Cecchin

E-mail: diego.cecchin@unipd.it

The authors Giuseppe Lombardi and Alessandro Spimpolo contributed equally to the work.

Objective: The use of regorafenib in recurrent glioblastoma patients has been recently approved by the Italian Medicines Agency (AIFA) and added to the National Comprehensive Cancer Network (NCCN) 2020 guidelines as a preferred regimen. Given its complex effects at the molecular level, the most appropriate imaging tools to assess early response to treatment is still a matter of debate. Diffusion-weighted imaging and O-(2-¹⁸F-fluoroethyl)-L-tyrosine positron emission tomography ([¹⁸F]FET PET) are promising methodologies providing additional information to the currently used RANO criteria. The aim of this study was to evaluate the variations in diffusion-weighted imaging/apparent diffusion coefficient (ADC) and [¹⁸F]FET PET-derived parameters in patients who underwent PET/MR at both baseline and after starting regorafenib.

Methods: We retrospectively reviewed 16 consecutive GBM patients who underwent [¹⁸F]FET PET/MR before and after two cycles of regorafenib. Patients were sorted into stable (SD) or progressive disease (PD) categories in accordance with RANO criteria. We were also able to analyze four SD patients who underwent a third PET/MR after another four cycles of regorafenib. [¹⁸F]FET uptake greater than 1.6 times the mean background activity was used to define an area to be superimposed on an ADC

map at baseline and after treatment. Several metrics were then derived and compared. Log-rank test was applied for overall survival analysis.

Results: Percentage difference in FET volumes correlates with the corresponding percentage difference in ADC ($R = 0.54$). Patients with a twofold increase in FET after regorafenib showed a significantly higher increase in ADC pathological volume than the remaining subjects ($p = 0.0023$). Kaplan-Meier analysis, performed to compare the performance in overall survival prediction, revealed that the percentage variations of FET- and ADC-derived metrics performed at least as well as RANO criteria ($p = 0.02$, $p = 0.024$ and $p = 0.04$ respectively) and in some cases even better. TBR Max and TBR mean are not able to accurately predict overall survival.

Conclusion In recurrent glioblastoma patients treated with regorafenib, [¹⁸F]FET and ADC metrics, are able to predict overall survival and being obtained from completely different measures as compared to RANO, could serve as semi-quantitative independent biomarkers of response to treatment.

Advances in knowledge Simultaneous evaluation of [¹⁸F]FET and ADC metrics using PET/MR allows an early and reliable identification of response to treatment and predict overall survival.

INTRODUCTION

Glioblastoma multiforme (GBM), the most common primary malignant brain tumor in adults, still carries a

dismal prognosis, with a median overall survival of less than 24 months, even after maximal safe resection, concomitant chemoradiotherapy and adjuvant temozolomide.¹⁻³ In the

setting of disease relapse, the use of regorafenib has been recently approved by the Italian Medicines Agency (AIFA) and added to the new National Comprehensive Cancer Network (NCCN) 2020 guidelines as a preferred regimen, based on promising results from a multicenter Phase II trial (REGOMA) comparing this new drug with the standard lomustine regimen.⁴ Regorafenib is an orally available multi kinase inhibitor with several molecular targets involved in angiogenesis (VEGFR1-3 and TIE2), oncogenesis (KIT, RET, RAF1, and BRAF) and maintenance of the tumoral microenvironment (PDGFR and FGFR).⁵⁻⁷ Given the complexity of its effects at the molecular level, the choice of the most appropriate imaging parameters to be used with patients treated with regorafenib is still a matter of debate. Currently, the recommendations of the Response Assessment in Neuro-Oncology (RANO) Study Group are widely used in both clinical practice and research settings and were also implemented in the REGOMA trial.^{4,8} The RANO criteria are based on measurement of areas of contrast-enhancement on post-gadolinium T_1 weighted sequences and of non-enhancing disease captured on T_2 weighted/fluid attenuated inversion recovery (FLAIR) images. This approach, however, has already been shown to have several limitations and shortcomings in patients treated with anti angiogenic drugs, such as bevacizumab, given the normalization of vascular permeability and the related decrease in contrast enhancement induced by these agents.⁸⁻¹⁰ In fact, up to 40% of patients treated with bevacizumab show seemingly stable contrast-enhancing disease with an increase in T_2 weighted/FLAIR signal abnormalities, indicating disease progression.¹¹ Moreover, the lack of a quantifiable measure of non-enhancing disease progression, and the confounding effect of radiation therapy, ischemic injury, and post-operative changes on FLAIR images further complicate the issue.

Diffusion-weighted imaging (DWI) is a promising methodology that could improve the assessment of treatment response in GBM, thereby extending the existing RANO criteria.¹² It is based on measuring the Brownian motion of water molecules and the various constraints that hamper this physical phenomenon in live tissues. Moreover, DWI-derived apparent diffusion coefficient (ADC) maps offer quantitative information related to tumor cellularity and have already been used in glioma patients to detect the presence of neoplastic tissue in the peritumoral edema.^{13,14} Since necrosis, ischemia and inflammation are known to influence water diffusion, heterogeneous ADC values are usually evident in tumoral areas, especially after treatment.^{15,16} Consequently, the mean ADC values of one area can fail to depict the spatial heterogeneity of brain tumors, although histogram analysis has already been successfully used as a possible workaround.^{16,17}

O-(2-¹⁸F-fluoroethyl)-L-tyrosine (¹⁸F-FET), an amino acid tracer used in positron emission tomography (PET), is another important tool routinely used for therapy assessment during anti-angiogenic treatment.^{18,19} Even though several studies have already demonstrated the additional value of amino acid PET over conventional MR-based assessment in this setting,^{20,21} the interplay between ADC and [¹⁸F]FET PET in patients treated with regorafenib has been explored so far only in a small case series comprising five cases.²²

The aim of this study was to evaluate the variations in DWI/ADC- and [¹⁸F]FET PET-derived parameters in recurrent patients undergoing PET/MR both at baseline and after beginning regorafenib. Furthermore, we analyzed the performance in survival prediction of RANO criteria compared to DWI/ADC- and [¹⁸F]FET PET-derived parameters.

METHODS AND MATERIALS

This was a single-center, retrospective, observational study conducted in accordance with the Declaration of Helsinki and after formal approval by our local Ethics Committee (protocol number: AOP1673 - 4831/AO/20). All patients gave written informed consent before undergoing the [¹⁸F]FET PET/MR, including access to their data for research purposes.

Patient selection

Among 52 patients treated with regorafenib, we retrospectively selected 16 consecutive recurrent GBM patients who underwent [¹⁸F]FET PET/MR from May 2019 to October 2020 at the Nuclear Medicine Unit of Padua University Hospital before and after two cycles of regorafenib; 4/16 patients were followed up with a third PET/MR; all of the patients were treated at the Veneto Institute of Oncology-IRCCS in Padua. Excluded Patients were those who underwent [¹⁸F]FET PET/MR but lacked one of the following inclusion criteria:

- (1) Histologically confirmed glioblastoma.
- (2) Radiologically and/or histologically confirmed disease relapse after conventional treatment according to RANO criteria (maximal safe resection followed by chemoradiotherapy).
- (3) Acquisition of baseline [¹⁸F]FET PET/MR no sooner than 1 week before starting regorafenib.
- (4) Acquisition of a second [¹⁸F]FET PET/MR no later than 2 weeks after two cycles of regorafenib.
- (5) No treatment changes between baseline and post-regorafenib [¹⁸F]FET PET/MR.

Image acquisition and reconstruction

All [¹⁸F]FET PET/MR images were acquired with a 3 T Biograph integrated PET/MR scanner (Siemens Healthcare, Germany) at the Nuclear Medicine Unit of Padua University Hospital, Italy. Following the most recent recommendations by the European Association of Nuclear Medicine, all study patients were required to fast for a minimum of 4 h before the intravenous administration of approximately 250 MBq of ¹⁸F-FET. Dynamic PET data were acquired from the time of tracer administration to 50 min post-injection,²³ while at the same time a standardized MR protocol was performed. The latter included: 1 mm isotropic 3D T_1 weighted magnetization-prepared rapid acquisition gradient echo (MPRAGE) (TR 2400 ms, TE 3.24 ms, slice thickness 1 mm, matrix size 256 × 256, FOV 256 × 256 mm) before and after contrast enhancement, 3D isovolumetric FLAIR (TR 5000 ms, TE 394 ms, TI 1800 ms, slice thickness 1 mm, matrix size 256 × 256, FOV 250 × 250 mm) and RESOLVE[®] sequence (Siemens Healthcare, Germany) (TR 5,000 ms, TE1 72 ms, TE2 122 ms, voxel size 1.56 × 1.56 × 3.12 mm), a high-resolution DWI sequence based on a readout-segmented echoplanar imaging (EPI) strategy.²⁴ ADC images were calculated from acquired DWI images with a b-value of 1000 s/mm² and 0 s/mm². The contrast medium used

with all patients was gadobutrol 0.1 mmol/Kg (Gadovist[®], Bayer Inc., Mississauga, Ontario).

A reconstruction of single frame PET images obtained at 20–40 min after tracer injection was used for the present study as suggested by EANM guidelines. Although kinetic analysis (in particular, the analysis of the time to peak of tracer uptake) could be predictive of response to treatment,²⁵ the analysis of the 50 min dynamic curve pattern is beyond the scope of the present paper that aims at comparing static PET indexes with RANO criteria. Standard corrections for decay, scatter and dead time were performed. A clinical UTE sequence (Siemens Healthcare, Germany) was included in the MR protocol (because more advanced AC methods are limited to a research setting and not directly applicable to a standard clinical setting) and used for attenuation correction of PET. The quality of the derived UTE map was visually assessed in all patients. The PET data were reconstructed using a 3D ordered subset expectation maximization algorithm with 8 iterations, 21 subsets and a 3 mm Gaussian filter, from which PET images with a 256×256 matrix size (voxel size = $2.32 \times 2.32 \times 2.03$ mm) were derived.

Qualitative image analysis

One neuroradiologist and one nuclear medicine physician (with 7 and more than 10 years' experience in the field of neuro-oncology, respectively), blind to the patients clinical outcomes and the follow-up imaging, jointly reviewed all [¹⁸F]FET PET/MR images at both baseline and post-regorafenib. The MR portion of the study have been evaluated first (comparing baseline MR and post-regorafenib MR) blinded to PET results. In accordance with the latest Response Assessment Criteria for High-Grade Gliomas by the Response Assessment in Neuro-Oncology (RANO) Working Group,^{8,26} study patients were divided into the following response-assessment categories: Complete Response (CR), Partial Response (PR), Stable Disease (SD), Progressive Disease (PD).

In cases of assumed CR or PR at the post-regorafenib time point, a follow-up MR scan was performed at least 4 weeks later and reviewed for confirmation.

PD was defined (according to RANO) as the fulfillment of one or more of the following conditions:

- (1) $\geq 25\%$ increase in the sum of the products of the perpendicular diameters of the enhancing lesions compared with the smallest tumor measurement at baseline;
- (2) appearance of any new contrast-enhancing lesion;
- (3) significant increase in T2/FLAIR non-enhancing lesion.

Patients fell into the SD category if they did not meet the conditions for CR, PR, or PD, and were administered the same or a lower dose of corticosteroids.

Image data processing

The images were imported into PMOD (PMOD[®] Technologies LLC, Zurich, Switzerland) for volume of interest (VOI) delineation.

[¹⁸F]FET PET (FET), post-contrast 3D T_1 weighted MPRAGE (MDC) and ADC images were rigidly aligned to the pre-contrast 3D T_1 weighted MPRAGE (T_1).

The mean standardized uptake value of a crescent-shaped VOI (BG_{FET}), manually drawn in the hemisphere contralateral to the tumor, was used as the [¹⁸F]FET background.²⁷ The pathological FET volume ($FET_{vol/pat}$) was segmented through a 3D semiautomatic contouring process, excluding areas with an [¹⁸F]FET uptake less than 1.6 times the background mean activity. This threshold was based on an [¹⁸F]FET biopsy-controlled study, where it was proven to accurately differentiate between tumoral and non-tumoral tissue.²⁸ The chosen cut-off has been subsequently used successfully in a number of publications presenting histopathological confirmation and/or MR comparisons.^{29,30} The derived segmented volume was visually refined to exclude areas of non-specific [¹⁸F]FET spillover (major blood vessels, cranial bones, meninges etc.) using the aligned MDC images as the morphological reference.

$FET_{vol/pat}$ was then superimposed onto the ADC images (Figure 1) to obtain the corresponding ADC volume (ADC_{vol}). The details are as follows:

- (1) $FET_{vol/pat}$ was imported into the aligned ADC image.
- (2) Areas with non-specific high ADC values were subtracted (with the aim also to correct for anatomical distortions induced by metal implants and air filled cavities) from the original volume, pinpointing the ADC values in the cerebrospinal fluid of the lateral ventricles.
- (3) Areas of the original volume located outside the brain parenchyma were analogously subtracted.

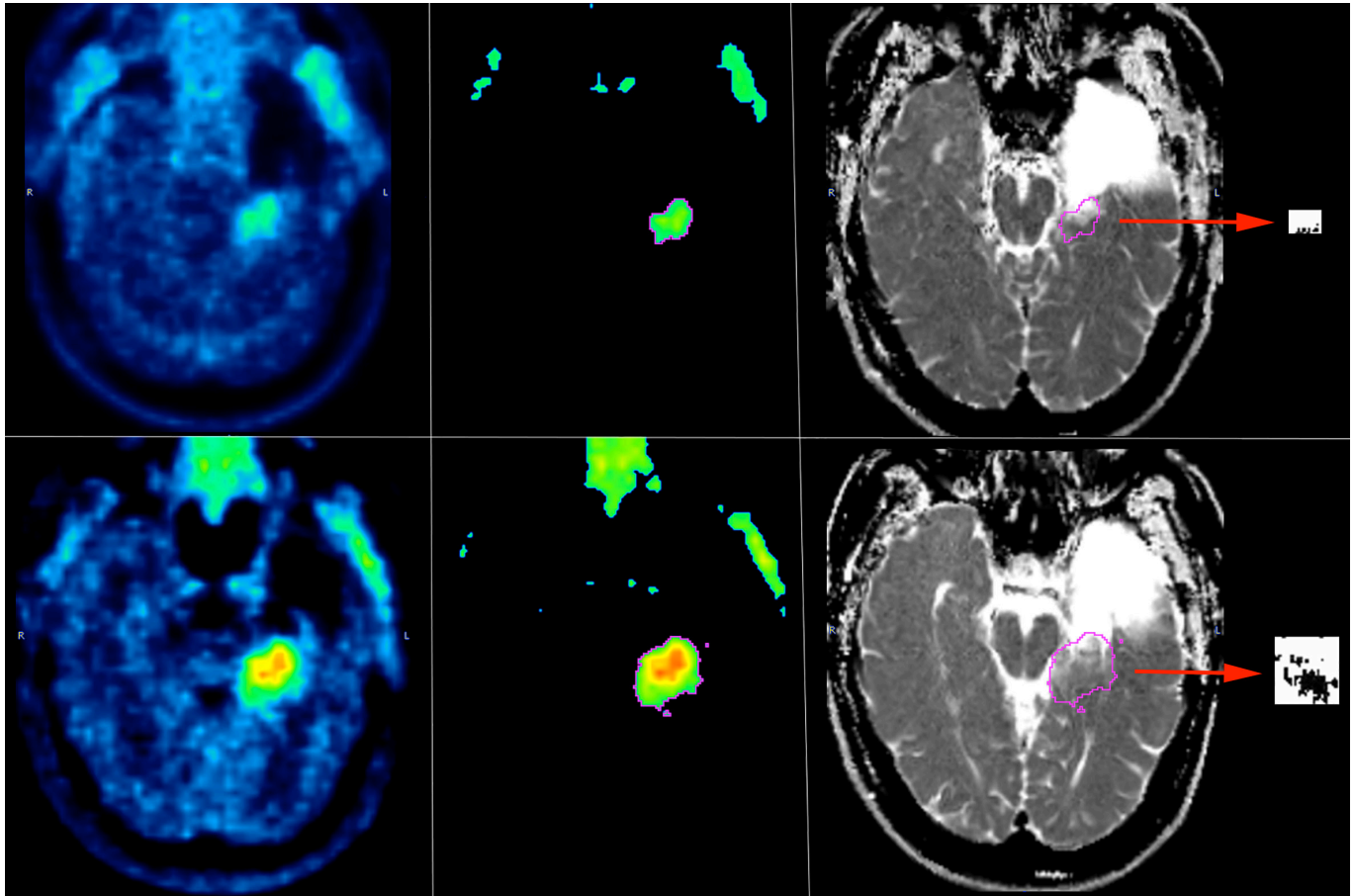
A standard spherical volume (radius = 5 mm) was then placed on the ADC images in the hemisphere contralateral to the tumor, carefully avoiding lateral ventricles and major vessels, in order to derive the mean ADC value of the normal brain parenchyma (BG_{ADC}). This method was chosen in view of the stability of the ADC values in the "healthy" brain parenchyma during treatment with antiangiogenic agents.¹² A qualitative assessment of the high resolution DWI and ADC derived maps was performed in every patient and revealed no significant distortions or misregistrations affecting the selected tumor area or background area.

The quality of alignment and segmentation was finally checked by an experienced nuclear medicine physician (with more than 10 years' experience in the field of neuro-oncology).

Data analysis

A pixel dump of $FET_{vol/pat}$, BG_{FET} , ADC_{vol} and BG_{ADC} was imported into the R software³¹ for further analyses. The mean ADC value of the BG_{ADC} was used as a threshold for ADC_{vol} . Only those pixels below the threshold were considered pathologic ($ADC_{vol/pat}$). The percentage differences in $ADC_{vol/pat}$ and $FET_{vol/pat}$ before and after regorafenib were calculated and compared ($\Delta ADC_{vol/pat} = ADC_{vol/pat}(T_1 - T_0)/T_0$ and $\Delta FET_{vol/pat} = FET_{vol/pat}(T_1 - T_0)/T_0$).

Figure 1. Overview of the methodology used to segment the pathological [¹⁸F]FET and ADC volumes in one of the study patients before (upper row) and after (lower row) treatment with regorafenib. Left: native [¹⁸F]FET PET images showing an area of pathological radiotracer uptake in the left mesial temporal lobe; center: the segmented pathological FET volume ($FET_{vol/pat}$) determined through a 3D semiautomatic contouring process and excluding areas with [¹⁸F]FET uptake less than 1.6 times the mean background activity; right: the pathological FET volume superimposed onto ADC images and (in boxes pointed by red arrows) the resulting pixels (black dots) with values below the mean ADC background. [¹⁸F]FET, O-(2-¹⁸F-fluoroethyl)-L-tyrosine; ADC, apparent diffusion coefficient.



Statistical analysis

All statistical analyses were performed using the R Software. The Shapiro–Wilk normality test was performed on the distribution of all the parameters. Where normal distributions could not be assumed, non-parametric tests were performed. The percentage changes in $ADC_{vol/pat}$ and $FET_{vol/pat}$ before and after regorafenib were plotted and the Pearson correlation coefficient (PCC) calculated, assuming a linear correlation between the two variables. The differences in the percentage changes in $FET_{vol/pat}$ and $ADC_{vol/pat}$ between the response groups determined according to RANO criteria⁸ were compared using the Wilcoxon signed-rank test for repeated measures. The significance level (α) was set at 0.05. Log-rank test was applied for overall survival analysis. A p -value < 0.05 was considered significant.

RESULTS

Patients

Our study population consisted of 15 IDH-wt and one glioblastoma NOS patients (6 females, 10 males, median age: 54.4 years, age range: 31–73 years). All the study patients had undergone

maximal safe resection, adjuvant chemoradiotherapy with temozolomide and subsequent maintenance temozolomide (from 1 to 12 cycles) before relapsing. The median time elapsed between radiotherapy and baseline [¹⁸F]FET PET/MR was 319 days. In one subject, re-irradiation was given in a single fraction about 4 weeks before starting regorafenib. Eight of the sixteen patients had been surgically retreated before being scheduled for regorafenib, and at least 19 days passed before the first [¹⁸F]FET PET/MR was performed. All the study patients received two cycles of regorafenib (160 mg per day; 3 weeks on, 1 week off) without treatment interruption. The characteristics of the population are summarized in Table 1.

[¹⁸F]FET PET/MR image analysis

After two cycles of regorafenib, 7/16 (44%) patients were observed to have SD, and the remaining 9/16 (56%) to have PD according to the RANO criteria (Table 2). The values of the [¹⁸F]FET PET/MR-derived parameters before and after treatment with regorafenib ($FET_{vol/pat}$, TBR_{mean} , TBR_{max} ,²³ $ADC_{vol/pat}$, and mean $ADC_{vol/pat}$) are listed in Table 2 and summarized in Table 3. Their

Table 1. Characteristics of the study population

Patient	Sex	Age	Histology	First treatment	Maintenance TMZ (cycles)	Second treatment before regorafenib	Latest surgery to first PET/MR (days)	Latest RT to first PET/MR (days)	First to second PET/MR (days)
1	M	40	GBM IDHwt	Surgery +RTCHT	6	Surgery	42	329	56
2	F	45	GBM IDHwt	Surgery +RTCHT	12		469	405	77
3	F	58	GBM IDHwt	Surgery +RTCHT	1	Surgery	62	1162	49
4	M	66	GBM IDHwt	Surgery +RTCHT	12		504	414	70
5	M	53	GBM IDHwt	Surgery +RTCHT	6		284	180	63
6	M	65	GBM IDHwt	Surgery +RTCHT	10		406	322	62
7	F	31	GBM IDHwt	Surgery +RTCHT	3		201	123	84
8	M	48	GBM IDHwt	Surgery +RTCHT	6	Surgery	41	858	70
9	F	39	GBM IDHwt	Surgery +RTCHT	6		363	312	56
10	F	48	GBM IDHwt	Surgery +RTCHT	8	Surgery	42	314	56
11	M	72	GBM IDHwt	Surgery +RTCHT	6	Surgery	55	333	56
12	M	60	GBM IDHwt	Surgery +RTCHT	2	Surgery	46	168	64
13	F	64	GBM IDHwt	Surgery +RTCHT	2		406	319	49
14	M	61	GBM IDHwt	Surgery +RTCHT	2	Surgery	19	183	56
15	M	48	GBM NOS	Surgery +RTCHT	12	Re-irradiation	3052	32	84
16	M	73	GBM IDHwt	Surgery +RTCHT	5	Surgery	36	239	48

GBM, glioblastoma; RTCHT, concomitant radio-chemotherapy; TMZ, temozolamide; wt, wildtype. The 15th subject underwent re-irradiation (20 Gy, 1fr, EBRT) before starting regorafenib.

Table 2. [¹⁸F]FET PET/MR parameters at baseline and after two cycles of regorafenib. FET_{vol/pat} and ADC_{vol/pat} are the pathological segmented FET and ADC volumes, expressed in mm³. TBR_{mean} (mean Tumor-to-Background Ratio) and TBR_{max} (maximum Tumor-to-Background Ratio) were calculated as the mean and maximum uptakes, respectively, of the FET-positive area normalized for the mean background uptake

PT	Baseline [18F]FET PET/MR					Post-Regorafenib [18F]FET PET/MR					
	FETvol/ pat	TBRmean	TBRmax	ADCvol/ pat	mean ADCvol/ pat	FETvol/ pat	TBRmean	TBRmax	ADCvol/ pat	mean ADCvol/ pat	RANO
1	4617	1.97	3.12	15	586.3	1,0370	1.99	3.28	384	604.7	PD
2	1,7322	2.07	3.50	913	563.0	1,3009	2.18	4.14	69	579.0	SD
3	3699	1.69	2.18	627	666.7	8578	1.78	2.55	1280	689.7	PD
4	9785	1.88	3.09	1252	645.5	1,6413	2.07	3.43	178	733.9	PD
5	1242	1.83	2.33	17	668.1	7137	2.11	3.67	290	687.1	SD
6	1,0710	1.79	3.42	631	657.9	2548	1.69	2.11	41	637.8	PD
7	1873	1.79	2.35	253	667.7	1486	1.82	2.39	335	646.3	SD
8	9052	1.79	2.47	240	383.2	1,1109	1.79	2.77	328	566.1	SD
9	6173	1.99	3.50	184	626.1	4007	1.87	2.77	359	558.4	SD
10	3941	1.87	3.25	266	606.7	8475	1.94	3.20	833	644.3	PD
11	2,2115	1.98	3.44	/	/	6,0399	2.19	3.40	2579	640.1	PD
12	3,9114	2.04	4.13	666	402.1	11,1268	2.14	4.37	1571	461.5	PD
13	3955	1.87	2.88	398	677.3	4964	1.89	2.78	823	675.4	SD
14	5,7593	2.20	4.29	/	/	3,9486	2.00	3.11	/	/	PD
15	1,0754	1.94	3.64	234	606.2	9,9238	2.35	4.64	2916	643.5	PD
16	2,4646	2.12	3.97	/	/	1,4428	1.98	3.17	717	586.4	SD

ADC, apparent diffusion coefficient; PD, Progressive Disease; SD, Stable Disease.

In two of the study subjects at baseline and in one post-regorafenib no pixels remained after ADC normalization. The RANO criteria were used to sort the patients into response categories.

Table 3. Means \pm standard deviations and ranges of the [^{18}F]FET PET/MR-derived parameters at baseline and after 2 cycles of regorafenib

Parameter	Baseline [^{18}F]FET PET/MR		Post-regorafenib [^{18}F]FET PET/MR	
	Mean \pm SD	Range	Mean \pm SD	Range
FET _{vol/pat}	14161 \pm 15387 mm ³	1242–57593 mm ³	25807 \pm 34548 mm ³	1486–111268 mm ³
TBR _{max}	3.22 \pm 0.65	2.18–4.29	3.24 \pm 0.70	2.11–4.64
TBR _{mean}	1.93 \pm 0.14	1.69–2.2	1.99 \pm 0.18	1.69–2.35
ADC _{vol/pat}	438 \pm 363 mm ³	15–1252 mm ³	847 \pm 887 mm ³	41–2916 mm ³
Mean ADC _{vol/pat}	597 \pm 97 * 10 ⁻⁶ mm ² /s	383–677 * 10 ⁻⁶ mm ² /s	624 \pm 67 * 10 ⁻⁶ mm ² /s	462–734 * 10 ⁻⁶ mm ² /s

ADC, apparent diffusion coefficient; FET, O-(2-¹⁸F-fluoroethyl)-L-tyrosine; TBR, Tumor-to-Background Ratio.

FET_{vol/pat} and ADC_{vol/pat} are the pathological segmented FET and ADC volumes, expressed in mm³; TBR_{mean} (mean Tumor-to-Background Ratio) and TBR_{max} (maximum Tumor-to-Background Ratio) were calculated as the mean and maximum uptakes, respectively, of the FET-positive area normalized for the mean background uptake; mean ADC_{vol/pat} is the mean ADC value in the ADC_{vol/pat} volume.

absolute and percentage variations after treatment are presented in Table 4. Although the absolute and percentage increases in FET_{vol/pat} were on average higher in PD than SD patients (21,605 mm³ and 168% vs -1160 mm³ and 70%), the differences between the two groups were not statistically significant ($p = 0.17$). Similarly, the average absolute and percentage increases in ADC pathological volume were also higher in PD than SD subjects (501 mm³ and 554% vs 33 mm³ and 297%), and also failed to reach statistical significance ($p = 0.53$). The percentage variations in mean ADC, FET_{vol/pat}, TBR_{max} and TBR_{mean} did not differ significantly between SD and PD patients (Tables 3 and 4, Figure 2). When the percentage difference in FET pathological volumes was plotted against the corresponding percentage difference in ADC pathological volumes, a linear regression model revealed a correlation between the two variables ($R = 0.54$) (Figure 3). We found no evident correlation between the percentage variation in mean ADC values and the corresponding percentage variation in FET_{vol/pat} ($R = 0.04$). Patients with at least a twofold increase in FET pathological volume (Figure 4)

after regorafenib showed a significantly higher increase in ADC pathological volume than the remaining subjects ($p = 0.0023$). In 2/9 subjects classified as progressive (according to RANO) after two cycles of regorafenib, the FET pathological volume decreased by 76 and 31%, respectively. Consistent with this, a decrease in the ADC pathological volume was observed in the former (-93%), while no residual pathological ADC areas could be detected in the latter. In contrast, in 3/7 patients classified as stable (according to RANO) after treatment, an increase in FET pathological volume (5895 mm³, 2057 mm³, and 1009 mm³, respectively) was observed; in the same patients, the ADC pathological volume increased at similar rates (273 mm³, 88 mm³, and 425 mm³).

The Kaplan–Meier analysis showed that the percentage variations of FET_{PAT/VOL}, ADC_{PAT/VOL} and RANO criteria were able to predict overall survival ($p = 0.02$, $p = 0.024$ and $p = 0.04$ respectively). TBR Max and TBR mean were not able to accurately predict overall survival.

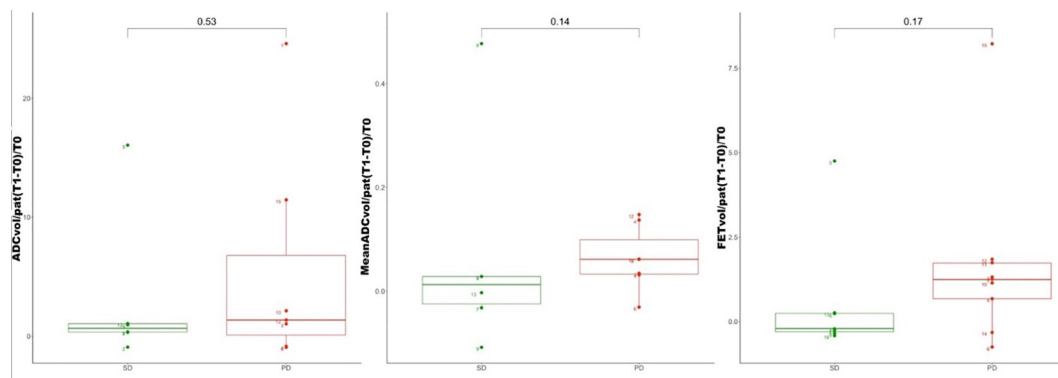
Table 4. Variations in the [^{18}F]FET PET/MR-derived parameters in the subjects grouped according to RANO response category

Parameter	SD		PD	
	Mean \pm standard deviation	Range	Mean \pm standard deviation	Range
$\Delta\text{FET}_{\text{pat/vol}}$	-1160 \pm 5138 mm ³	-10218–5895 mm ³	21605 \pm 36769 mm ³	-18107–88484 mm ³
$\Delta\text{FET}_{\text{pat/vol}}$ (%)	70 \pm 199%	-41–474 %	168 \pm 261%	-76–823 %
$\Delta\text{TBR}_{\text{max}}$	0.1 \pm 0.76	-0.8–1.34	-0.05 \pm 0.74	-1.31–1
$\Delta\text{TBR}_{\text{max}}$ (%)	5 \pm 29	-21–58	0 \pm 21	-38–27 %
$\Delta\text{TBR}_{\text{mean}}$	0.03 \pm 0.14	-0.14–0.28	0.09 \pm 0.18	-0.2–0.41
$\Delta\text{TBR}_{\text{mean}}$ (%)	1 \pm 8%	-6–15 %	5 \pm 9%	-9–21 %
$\Delta\text{ADC}_{\text{pat/vol}}$	33 \pm 448 mm ³	-844–425 mm ³	501 \pm 1200 mm ³	-1074–2682 mm ³
$\Delta\text{ADC}_{\text{pat/vol}}$ (%)	297 \pm 645%	-92–1606 %	554 \pm 940%	-94–2460 %
$\Delta\text{Mean ADC}_{\text{pat/vol}}$	21 \pm 85 * 10 ⁻⁶ mm ² /s	-67–182 * 10 ⁻⁶ mm ² /s	35 \pm 34 * 10 ⁻⁶ mm ² /s	-20–88 * 10 ⁻⁶ mm ² /s
$\Delta\text{Mean ADC}_{\text{pat/vol}}$ %	6 \pm 21%	-11–48 %	6 \pm 6%	-3–15 %

ADC, apparent diffusion coefficient; FET, O-(2-¹⁸F-fluoroethyl)-L-tyrosine; PD, Progressive Disease; SD, Stable Disease; TBR, Tumor-to-Background Ratio.

FET_{vol/pat} and ADC_{vol/pat} are the pathological segmented FET and ADC volumes; TBR_{mean} is the mean Tumor-to-Background Ratio and TBR_{max} is the maximum Tumor-to-Background Ratio; mean ADC_{vol/pat} is the mean ADC value in the ADC_{vol/pat} volume. RANO criteria were used to sort the patients into response categories.

Figure 2. Variations in the ADC-derived parameters after regorafenib in study patients sorted into response groups according to RANO criteria. Left, the variation in pathological ADC volume ($ADC_{vol/pat}$); center, the variation in the mean ADC values in the pathological ADC volume (mean $ADC_{vol/pat}$); right, the variation in pathological FET volume ($FET_{vol/pat}$); SD = Stable Disease; PD = Progressive Disease; T0 = First [¹⁸F]FET PET/MR; T1 = Second [¹⁸F]FET PET/MR; ADC, apparent diffusion coefficient.



DISCUSSION

One of the main findings to emerge from the present study was the correlation between the percentage changes in the pathological FET and ADC volumes in recurrent GBM patients treated with regorafenib at their first disease relapse. To our knowledge, this is the first work assessing the variation in the ADC signal in the FET-positive volume in patients undergoing [¹⁸F]FET PET/MR both at baseline and soon after beginning this new beneficial second-line therapy. The value of DWI-derived parameters in treatment monitoring of GBM patients has already been

extensively investigated,³²⁻³⁵ and many authors have suggested that the DWI methodology could play an important role in guiding response assessment, particularly when conventional contrast-enhanced and T₂ weighted/FLAIR sequences are less reliable. Although DWI sequences are routinely acquired as part of the standard MR protocol for brain tumor imaging, the most recent recommendations³⁶ only describe how diffusion-weighted images should be acquired and provide no guidance for clinically interpreting and quantifying the extent of the tumor for the purpose of response evaluation. Two major issues consequently

Figure 3. Scatter plots of the variation in pathological ADC volume ($ADC_{vol/pat}$) vs the corresponding pathological FET volume ($FET_{vol/pat}$) after two cycles of treatment with regorafenib. Red and green dots represent the patients presenting with PD and SD after regorafenib, respectively. The regression line is shown in blue, and the gray area represents the 95% confidence interval. ADC, apparent diffusion coefficient; SD, Stable Disease; PD, Progressive Disease; T0, First [¹⁸F]FET PET/MR; T1, Second [¹⁸F]FET PET/MR.

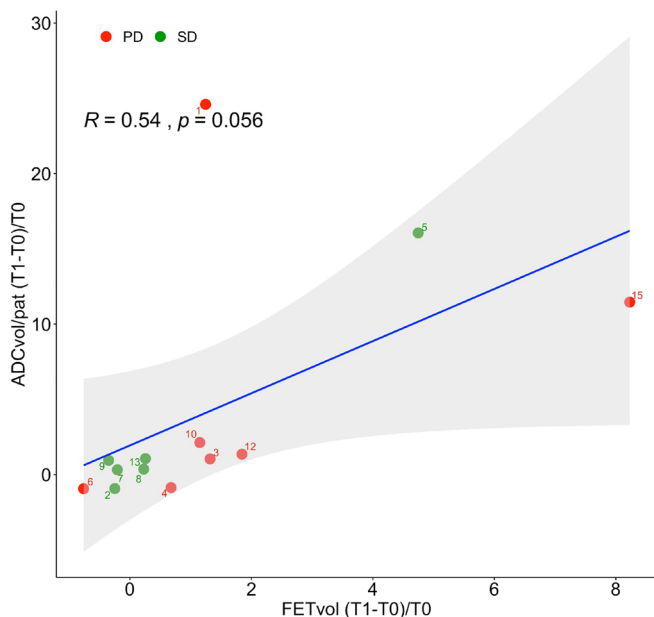
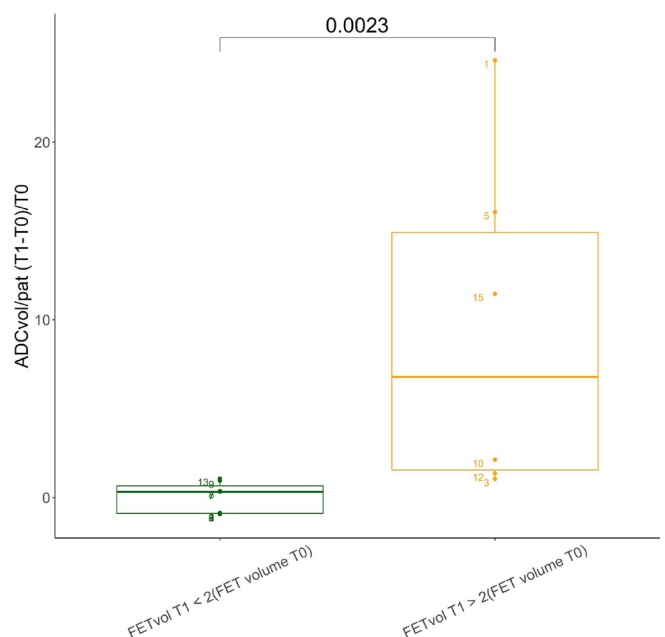


Figure 4. Box plots of the variation in the pathological ADC volume ($ADC_{vol/pat}$) after two cycles of regorafenib. Study patients were subdivided into two groups: one including patients with at least a duplication in $FET_{vol/pat}$ after treatment with regorafenib (in yellow), the other including subjects with a less than twofold increase in $FET_{vol/pat}$ (in green). ADC, apparent diffusion coefficient; T0, First [¹⁸F]FET PET/MR; T1, Second [¹⁸F]FET PET/MR



arise, the first regarding the strategy to identify the region on the DWI-ADC images to be analyzed, the second regarding the threshold for pathological ADC values. In most of the published studies, the tumor volume was outlined and the VOI constructed on contrast-enhanced T_1 weighted images, which were subsequently transferred to the corresponding DWI-ADC images. Buemi et al,³⁷ e.g. manually drew the VOIs encompassing the areas of tumor-related contrast enhancement, and T_2 weighted/FLAIR abnormalities were mapped onto the corresponding ADC images, thus deriving the CE-ADC and T2/FLAIR-ADC volumes, respectively. Histogram analysis and curve fitting using a two-mixture normal distribution model were carried out to calculate the mean ADC of the lowest ADC values in these areas (CE-ADC-L and T2/FLAIR-ADC-L).³⁷ Interestingly, only the mean ADC in CE-ADC-L turned out to be significantly predictive of progression-free survival and overall survival in GBM patients treated with bevacizumab and fotemustine. The predictive value of the low-ADC areas is confirmed by other published papers.^{38,39} Zeiner et al⁴⁰ calculated the ADC-ratio by measuring the minimum ADC values in the tumor and normalizing them by the ADC values of the contralateral, normal appearing brain tissue. In our study, instead, a standard VOI contralateral to the lesion was used to determine the appropriate threshold for the selection of pathological ADC values. This approach allowed for a more direct identification of the low ADC values in the defined VOIs, avoiding the need for complex mathematical models. However, the post-regorafenib variation in the mean ADC thus calculated did not significantly correlate with the corresponding change in FET-positive volume, nor with the RANO response categories. A possible explanation for this discrepancy may lie in the different methodological approaches used here and in the previously published studies.^{12,37-48} This highlights the

importance of future efforts towards standardizing the analysis of ADC maps before considering the inclusion of this methodology in the response assessment criteria.

It is important to note that the changes in neither the pathological FET volume nor the pathological ADC volume were significantly different in the stable and progressive patients as assessed by RANO criteria. RANO criteria are based mostly on changes in T2/FLAIR and contrast-enhanced areas, which are known to be affected by edema, inflammation, gliosis, and disruption of the blood-brain barrier. DWI, instead, is sensitive to microscopic water motion, resulting in relatively restricted diffusion in areas of tightly packed tumor cells. However, diffusion may be altered by causes other than increased cellularity in neoplastic tissue, and the diagnostic performance of this methodology is influenced by the choice of the appropriate DWI parameter to analyze.^{16,49,50} Moreover, the heterogeneity of the ADC signal may have translated into the wide variability we observed in the changes in the pathological ADC volume after regorafenib. This, in turn, may explain why a relatively high threshold of increase in FET pathological volume was needed to subdivide our population into groups with significantly different pathological ADC volumes.

In three cases which were classified, according to the RANO criteria, as stable (SD) after treatment with regorafenib, both the ADC and FET pathological volumes increased compared with the baseline examinations (patients #5, #8 in Figure 5, and #13). Information from subsequent follow-ups was available for two of these patients: a) patient #5 (interestingly, classified as SD by the RANO criteria) showed a slight increase in FET_{vol/pat} (and to a lesser extent also in ADC_{vol/pat}) at a PET/MR examination

Figure 5. Variations in the pathological FET volume (FET_{vol/pat}) and pathological ADC volume (ADC_{vol/pat}) between timepoints (TP1, TP2 and TP3 representing, respectively, the first baseline PET/MR before regorafenib, the second PET/MR after two cycles of regorafenib, and the third PET/MR after six cycles of regorafenib). ADC, apparent diffusion coefficient; FET, O-(2-18F-fluoroethyl)-L-tyrosine; PET, positron emission tomography; TP1, Timepoint 1; TP2, Timepoint 2; TP3 = Timepoint 3.

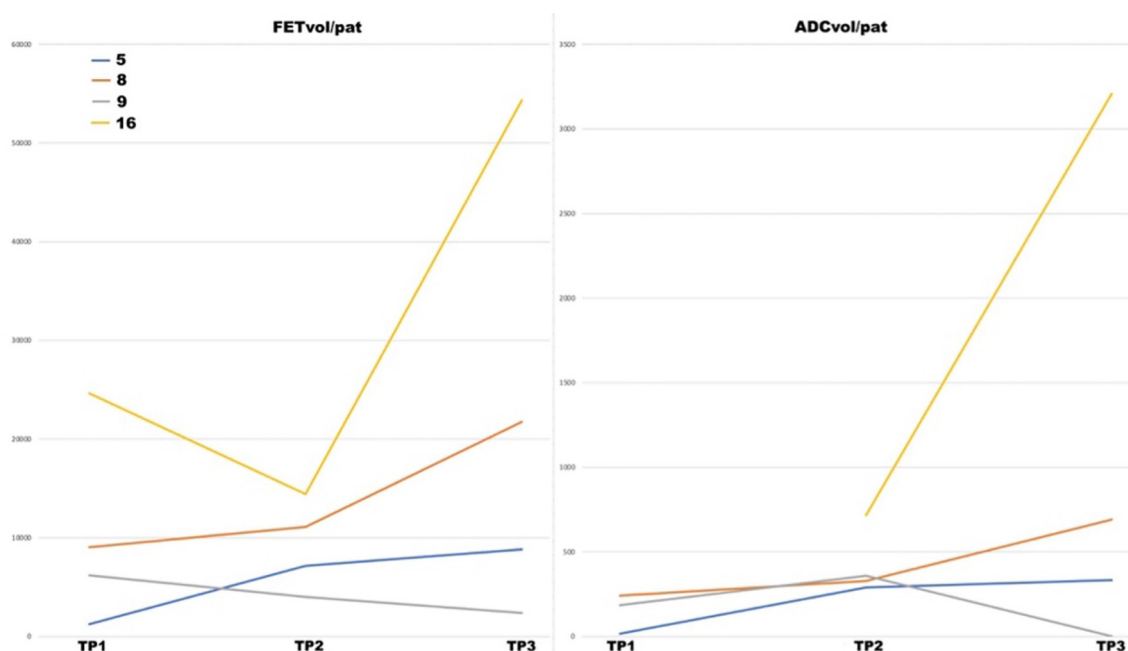
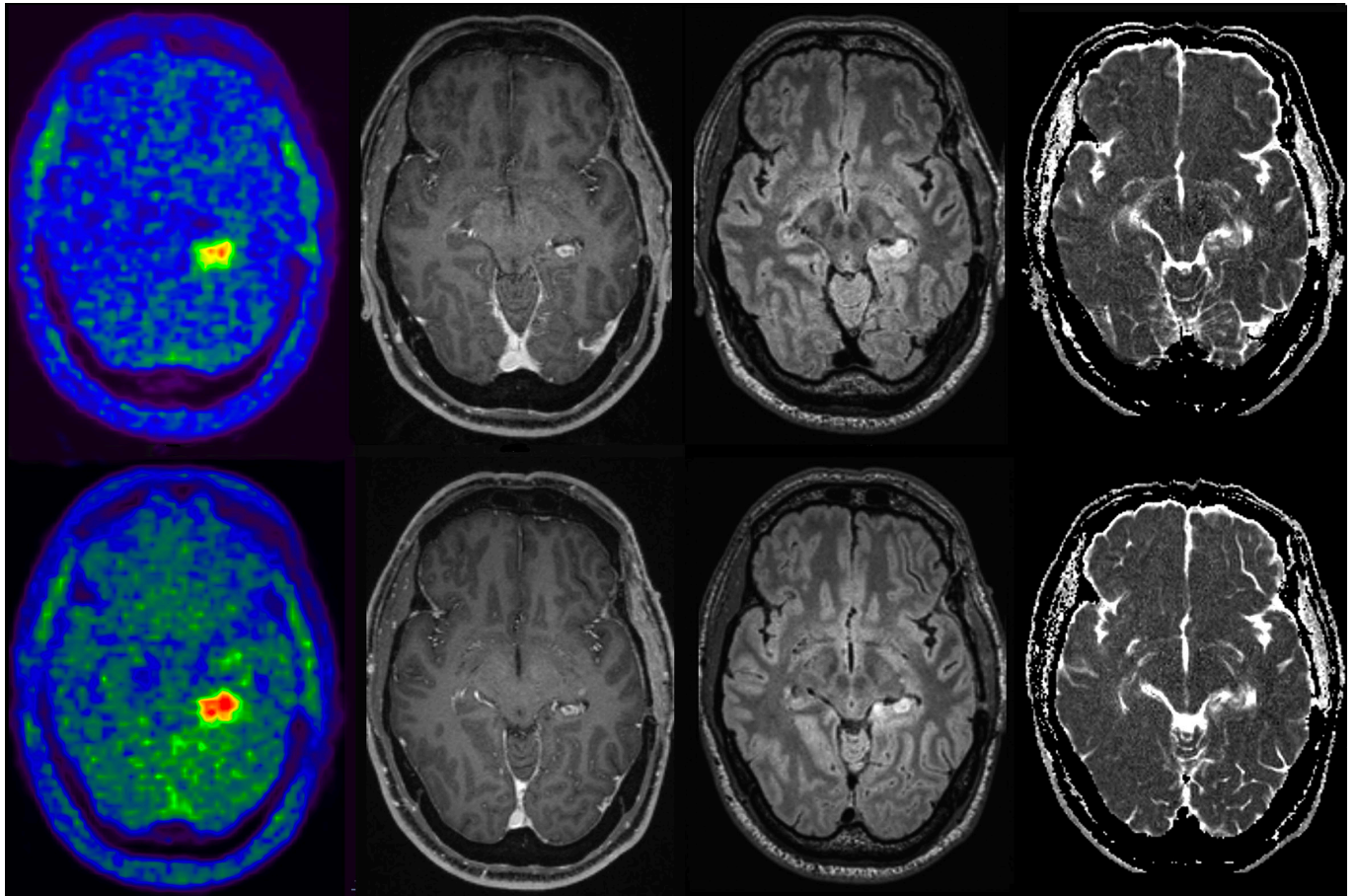


Figure 6. Axial [¹⁸F]FET PET/MR images before (upper row) and after (lower row) treatment with regorafenib in one of the study patients (#5). first column: [¹⁸F]FET PET; second column: post-contrast T₁ weighted; third column: FLAIR; fourth Column: ADC maps. The increase in [¹⁸F]FET uptake after treatment with regorafenib is evident in lower row first column compared with upper row even though no significant increases in the contrast-enhanced and FLAIR altered areas are visible. The analysis revealed an increase in the pathological ADC-volume after regorafenib, even though it was barely detectable qualitatively on the native images. ADC, apparent diffusion coefficient; FET, O-(2-18F-fluoroethyl)-L-tyrosine; FLAIR, fluid attenuated inversion recovery; PET, positron emission tomography.



(Figure 6) performed 2 months later (TP3 in Figure 5), and presented disease progression at an MR scan performed 4 months later; b) patient #8 showed a significant increase in $FET_{vol/pat}$ (and to a lesser extent also in $ADC_{vol/pat}$) at a subsequent PET/MR examination (TP3 in Figure 5), and was consistently considered progressive according to the RANO criteria. We were able to carry out a follow-up PET/MR in another two cases (patients #9 and #16, both SD at the PET/MR examination after two cycles of regorafenib): a) patient # presented minimal variations in $FET_{vol/pat}$ and $ADC_{vol/pat}$ after two cycles of regorafenib, and remained stable (presenting a decrease in $FET_{vol/pat}$ and $ADC_{vol/pat}$) at the follow-up PET/MR (TP3 in Figure 5); b) patient #16 showed a significant increase in $FET_{vol/pat}$ and $ADC_{vol/pat}$ between the PET/MR performed after two cycles of regorafenib (Figure 5) and the follow-up PET/MR, and was then considered progressive according to the RANO criteria.

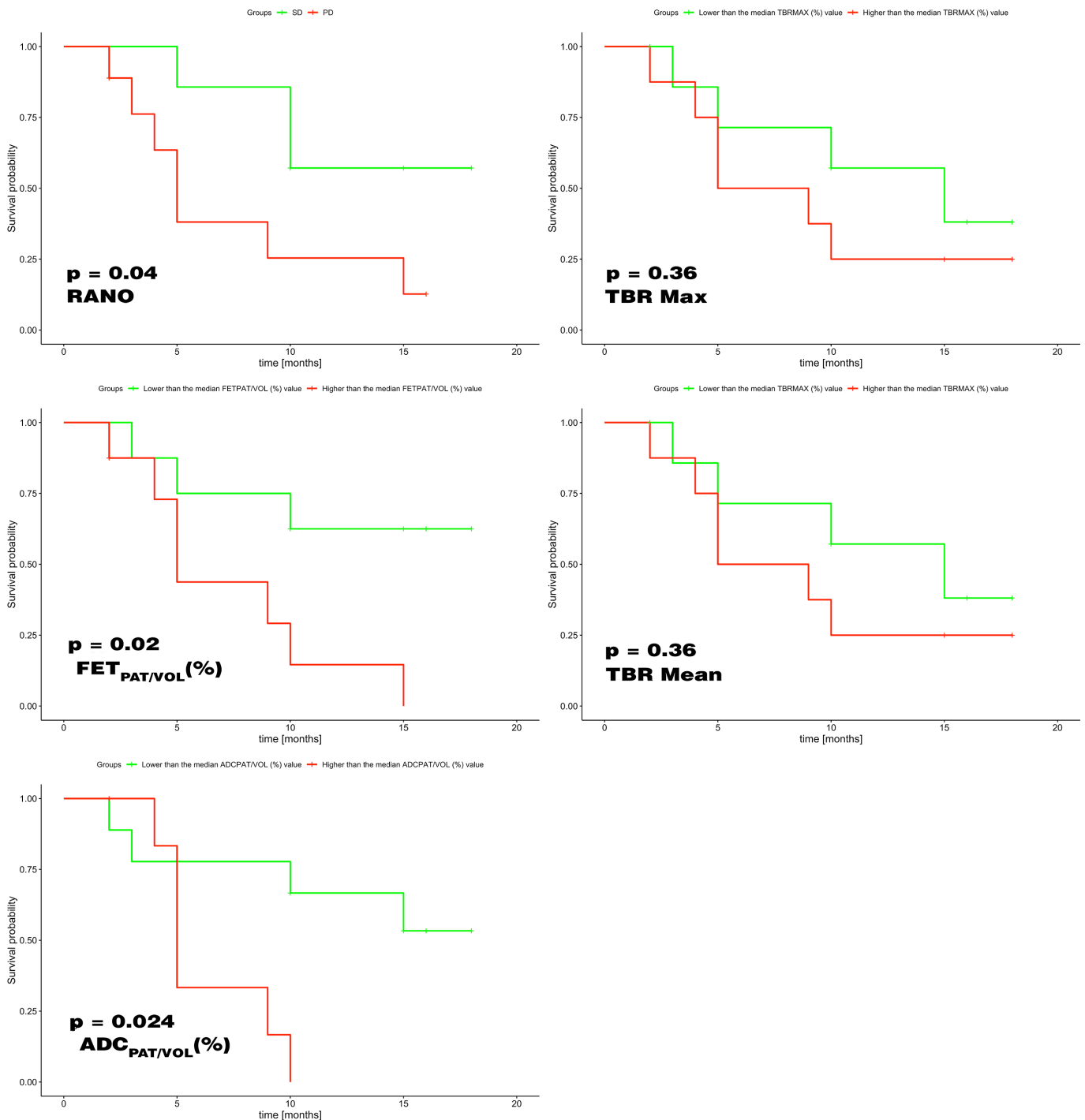
These four cases, although insufficient to draw definitive conclusions, seem to show consistent variations in FET and ADC pathological volumes in follow-up examinations performed after six

cycles of regorafenib, and seems to confirm the greater predictive value of these parameters compared with the standard RANO criteria. In fact, the variations in FET and ADC (in the PET/MR after two cycles of regorafenib) predicted the follow-up in two out of four cases wrongly classified by RANO (subjects #5 and #8 who were categorized as stable according to the RANO criteria).

Kaplan–Meier analysis (Figure 7), performed to compare the performance in overall survival prediction, revealed that the percentage variations of $FET_{PAT/VOL}$ and $ADC_{PAT/VOL}$ performed at least as well as RANO criteria ($p = 0.02$, $p = 0.024$ and $p = 0.04$ respectively) or even better. TBR Max and TBR mean on the other hand, frequently used at the first tumor occurrence, are not able to accurately predict overall survival.

Therefore, the so identified [¹⁸F]FET and ADC areas and values, which are correlated but were obtained from completely different measures, could serve as independent biomarkers of treatment response and could, at least, complement the RANO criteria especially in doubtful cases.

Figure 7. Kaplan-Meier analysis shows that the percentage variations of $FET_{PAT/VOL}$ and $ADC_{PAT/VOL}$ performed at least as well as RANO criteria or even better in terms of overall survival prediction (left column). TBR Max and TBR mean (right column) on the other hand are not able to accurately predict overall survival. ADC, apparent diffusion coefficient; FET, O-(2-18F-fluoroethyl)-L-tyrosine; TBR, Tumor-to-Background Ratio.



Our study has some limitations, including that regorafenib was introduced only recently:

- (1) It was retrospective in nature and included only a relatively (considering the actual infrequent use of the treatment) small number of patients.
- (2) The current RANO criteria were assumed as gold-standard.

Despite these limitations, we focused on a highly homogeneous patient population comprising GBM subjects at their first disease relapse, and all patients were treated with a recently approved chemotherapeutic agent (regorafenib). Moreover, all imaging studies were acquired at the same institution with an integrated PET/MR system and a standardized protocol.

CONCLUSIONS

In the present study, we have proposed a method to identify the pathological ADC volume based on the corresponding [¹⁸F]FET positive region in intrinsically co-registered [¹⁸F]FET PET/MR images. We found a correlation between the percentage changes in pathological FET and DWI-ADC volumes in glioblastoma patients treated with regorafenib at their first disease relapse. In 4/16 cases followed up with a third PET/MR, the results seemed encouraging compared to the RANO criteria.

Kaplan analysis showed that FET_{PAT/VOL} and ADC_{PAT/VOL} performed at least as well as RANO criteria in terms of overall survival prediction.

The [¹⁸F]FET and ADC metrics identified could, given they were correlated but obtained from completely different measures, serve as semi-quantitative independent biomarkers of response to regorafenib treatment.

CONTRIBUTORS

Conceptualization, A.S., G.L., S.B. and D.C.; methodology, A.S., S.B., C.C., M.G.A. and D.C.; software, S.B. and C.C.; formal analysis, C.C.; investigation, G.L., M.G.A., R.S., L.E., G.G., M.C. and M.P.; data curation, A.S., S.B., C.C. and D.C.; writing—original draft preparation, A.S., S.B. and D.C.; writing—review and editing, G.L., M.G.A., L.E., F.C., G.Z. and V.Z.; visualization, D.C., M.G.A.; supervision, G.L., V.Z. and D.C.; project administration, D.C. All authors read and agreed to the published version of the manuscript.

FUNDING

Open Access Funding provided by Università degli Studi di Padova within the CRUI-CARE Agreement.

PATIENT CONSENT

All patients gave written informed consent before undergoing the [¹⁸F]FET PET/MR, including access to their data for research purposes.

REFERENCES

- Rønning PA, Helseth E, Meling TR, Johannesen TB. A population-based study on the effect of temozolomide in the treatment of glioblastoma multiforme. *Neuro Oncol* 2012; **14**: 1178–84. doi: <https://doi.org/10.1093/neuonc/nos153>
- Kruchko C, Ostrom QT, Gittleman H, Barnholtz-Sloan JS. The CBTRUS story: providing accurate population-based statistics on brain and other central nervous system tumors for everyone. *Neuro Oncol* 2018; **20**: 295–8. doi: <https://doi.org/10.1093/neuonc/ny006>
- Stupp R, Mason WP, van den Bent MJ, Weller M, Fisher B, Taphoorn MJB, et al. Radiotherapy plus concomitant and adjuvant temozolomide for glioblastoma. *N Engl J Med* 2005; **352**: 987–96. doi: <https://doi.org/10.1056/NEJMoa043330>
- Lombardi G, De Salvo GL, Brandes AA, Eoli M, Rudà R, Faedi M, et al. Regorafenib compared with lomustine in patients with relapsed glioblastoma (REGOMA): a multicentre, open-label, randomised, controlled, phase 2 trial. *Lancet Oncol* 2019; **20**: 110–9. doi: [https://doi.org/10.1016/S1470-2045\(18\)30675-2](https://doi.org/10.1016/S1470-2045(18)30675-2)
- Abou-Elkacem L, Arns S, Brix G, Gremse F, Zopf D, Kiessling F, et al. Regorafenib inhibits growth, angiogenesis, and metastasis in a highly aggressive, orthotopic colon cancer model. *Mol Cancer Ther* 2013; **12**: 1322–31. doi: <https://doi.org/10.1158/1535-7163.MCT-12-1162>
- Wilhelm SM, Dumas J, Adnane L, Lynch M, Carter CA, Schütz G, et al. Regorafenib (BAY 73-4506): a new oral multikinase inhibitor of angiogenic, stromal and oncogenic receptor tyrosine kinases with potent preclinical antitumor activity. *Int J Cancer* 2011; **129**: 245–55. doi: <https://doi.org/10.1002/ijc.25864>
- Wilhelm SM, Carter C, Tang L, Wilkie D, McNabola A, Rong H, et al. BAY 43-9006 exhibits broad spectrum oral antitumor activity and targets the RAF/MEK/ERK pathway and receptor tyrosine kinases involved in tumor progression and angiogenesis. *Cancer Res* 2004; **64**: 7099–109. doi: <https://doi.org/10.1158/0008-5472.CAN-04-1443>
- Wen PY, Macdonald DR, Reardon DA, Cloughesy TF, Sorensen AG, Galanis E, et al. Updated response assessment criteria for high-grade gliomas: response assessment in neuro-oncology working group. *J Clin Oncol* 2010; **28**: 1963–72. doi: <https://doi.org/10.1200/JCO.2009.26.3541>
- Ellingson BM, Malkin MG, Rand SD, Connelly JM, Quinsey C, LaViolette PS, et al. Validation of functional diffusion maps (fDMs) as a biomarker for human glioma cellularity. *J Magn. Reson. Imaging* 2010; **31**: 538–48. doi: <https://doi.org/10.1002/jmri.22068>
- Wen PY, Cloughesy TF, Ellingson BM, Reardon DA, Fine HA, Abrey L, et al. Report of the jumpstarting brain tumor drug development coalition and FDA clinical trials neuroimaging endpoint workshop (January 30, 2014, Bethesda MD). *Neuro Oncol* 2014; **16**(Suppl 7): vii36–47. doi: <https://doi.org/10.1093/neuonc/nou226>
- Delgado-López PD, Riñones-Mena E, Corrales-García EM. Treatment-related changes in glioblastoma: a review on the controversies in response assessment criteria and the concepts of true progression, pseudoprogression, pseudoresponse and radionecrosis. *Clin Transl Oncol* 2018; **20**: 939–53. doi: <https://doi.org/10.1007/s12094-017-1816-x>
- Auer TA, Breit H-C, Marini F, Renovan M, Ringel F, Sommer CJ, et al. Evaluation of the apparent diffusion coefficient in patients with recurrent glioblastoma under treatment with bevacizumab with radiographic pseudoresponse. *J Neuroradiol* 2019; **46**: 36–43. doi: <https://doi.org/10.1016/j.neurad.2018.04.002>
- Provenzale JM, McGraw P, Mhatre P, Guo AC, Delong D. Peritumoral brain regions in gliomas and meningiomas: investigation with isotropic diffusion-weighted MR imaging and diffusion-tensor MR imaging. *Radiology* 2004; **232**: 451–60. doi: <https://doi.org/10.1148/radiol.2322030959>
- Yamasaki F, Kurisu K, Satoh K, Arita K, Sugiyama K, Ohtaki M, et al. Apparent diffusion coefficient of human brain tumors at MR imaging. *Radiology* 2005; **235**: 985–91. doi: <https://doi.org/10.1148/radiol.2353031338>
- Smith JS, Cha S, Mayo MC, McDermott MW, Parsa AT, Chang SM, et al. Serial diffusion-weighted magnetic resonance imaging in cases of glioma: distinguishing

- tumor recurrence from postresection injury. *J Neurosurg* 2005; **103**: 428–38. doi: <https://doi.org/10.3171/jns.2005.103.3.0428>
16. Huang RY, Neagu MR, Reardon DA, Wen PY, et al. Pitfalls in the neuroimaging of glioblastoma in the era of antiangiogenic and immuno/targeted therapy - detecting illusive disease, defining response. *Front Neurol* 2015; **6**(Suppl 4). doi: <https://doi.org/10.3389/fneur.2015.00033>
 17. Kondo M, Uchiyama Y. Apparent diffusion coefficient histogram analysis for prediction of prognosis in glioblastoma. *J Neuroradiol* 2018; **45**: 236–41. doi: <https://doi.org/10.1016/j.neurad.2017.11.011>
 18. Albert NL, Weller M, Suchorska B, Galldiks N, Soffietti R, Kim MM, et al. Response assessment in neuro-oncology Working group and European association for neuro-oncology recommendations for the clinical use of PET imaging in gliomas. *Neuro Oncol* 2016; **18**: 1199–208. doi: <https://doi.org/10.1093/neuonc/nov058>
 19. Stegmayr C, Oliveira D, Niemietz N, Willuweit A, Lohmann P, Galldiks N, et al. Influence of bevacizumab on blood-brain barrier permeability and O-(2-18F-Fluoroethyl)-L-tyrosine uptake in rat gliomas. *J Nucl Med* 2017; **58**: 700–5. doi: <https://doi.org/10.2967/jnumed.116.187047>
 20. Hutterer M, Nowosielski M, Putzer D, Waitz D, Tinkhauser G, Kostron H, et al. O-(2-18F-fluoroethyl)-L-tyrosine PET predicts failure of antiangiogenic treatment in patients with recurrent high-grade glioma. *J Nucl Med* 2011; **52**: 856–64. doi: <https://doi.org/10.2967/jnumed.110.086645>
 21. Galldiks N, Dunkl V, Ceccon G, Tscherpel C, Stoffels G, Law I, et al. Early treatment response evaluation using FET PET compared to MRI in glioblastoma patients at first progression treated with bevacizumab plus lomustine. *Eur J Nucl Med Mol Imaging* 2018; **45**: 2377–86. doi: <https://doi.org/10.1007/s00259-018-4082-4>
 22. Galldiks N, Werner J-M, Tscherpel C, Fink GR, Langen K-J. Imaging findings following regorafenib in malignant gliomas: FET PET adds valuable information to anatomical MRI. *Neurooncol Adv* 2019; **1**: vdz038. doi: <https://doi.org/10.1093/nojnl/vdz038>
 23. Law I, Albert NL, Arbizu J, Boellaard R, Drzezga A, Galldiks N, et al. Joint EANM/EANO/RANO practice guidelines/SNMMI procedure standards for imaging of gliomas using PET with radiolabelled amino acids and [¹⁸F]FDG: version 1.0. *Eur J Nucl Med Mol Imaging* 2019; **46**: 540–57. doi: <https://doi.org/10.1007/s00259-018-4207-9>
 24. Cohen-Adad J. High-Resolution DWI in brain and spinal cord with syngo resolve. *Siemens Magnetom - Clin Neurol* 2012; **510**: 16–23.
 25. Galldiks N, Rapp M, Stoffels G, Fink GR, Shah NJ, Coenen HH, et al. Response assessment of bevacizumab in patients with recurrent malignant glioma using [18F] Fluoroethyl-L-tyrosine PET in comparison to MRI. *Eur J Nucl Med Mol Imaging* 2013; **40**: 22–33. doi: <https://doi.org/10.1007/s00259-012-2251-4>
 26. Chukwueke UN, Wen PY. Use of the Response Assessment in Neuro-Oncology (RANO) criteria in clinical trials and clinical practice. *CNS Oncol* 2019; **8**: CNS28. doi: <https://doi.org/10.2217/cns-2018-0007>
 27. Unterrainer M, Vettermann F, Brendel M, Holzgreve A, Lifschitz M, Zähringer M, et al. Towards standardization of ¹⁸F-FET PET imaging: do we need a consistent method of background activity assessment? *EJNMMI Res* 2017; **7**: 48. doi: <https://doi.org/10.1186/s13550-017-0295-y>
 28. Pauleit D, Floeth F, Hamacher K, Riemenschneider MJ, Reifenberger G, Müller H-W, et al. O-(2-[18F]fluoroethyl)-L-tyrosine PET combined with MRI improves the diagnostic assessment of cerebral gliomas. *Brain* 2005; **128**(Pt 3): 678–87. doi: <https://doi.org/10.1093/brain/awh399>
 29. Song S, Cheng Y, Ma J, Wang L, Dong C, Wei Y, et al. Simultaneous FET-PET and contrast-enhanced MRI based on hybrid PET/MR improves delineation of tumor spatial biodistribution in gliomas: a biopsy validation study. *Eur J Nucl Med Mol Imaging* 2020; **47**: 1458–67. doi: <https://doi.org/10.1007/s00259-019-04656-2>
 30. Lohmann P, Stavrinou P, Lipke K, Bauer EK, Ceccon G, Werner J-M, et al. FET PET reveals considerable spatial differences in tumour burden compared to conventional MRI in newly diagnosed glioblastoma. *Eur J Nucl Med Mol Imaging* 2019; **46**: 591–602. doi: <https://doi.org/10.1007/s00259-018-4188-8>
 31. R Core Team. *R: A language and environment for statistical computing*. Vienna, Austria: R Foundation for Statistical Computing; 2017.
 32. Ellingson BM, Malkin MG, Rand SD, Connelly JM, Quinsey C, LaViolette PS, et al. Validation of functional diffusion maps (fDMs) as a biomarker for human glioma cellularity. *J Magn Reson Imaging* 2010; **31**: 538–48. doi: <https://doi.org/10.1002/jmri.22068>
 33. Sugahara T, Korogi Y, Kochi M, Ikushima I, Shigematu Y, Hirai T, et al. Usefulness of diffusion-weighted MRI with echo-planar technique in the evaluation of cellularity in gliomas. *J Magn Reson Imaging* 1999; **9**: 53–60. doi: [https://doi.org/10.1002/\(SICI\)1522-2586\(199901\)9:1<53::AID-JMRI7>3.0.CO;2-2](https://doi.org/10.1002/(SICI)1522-2586(199901)9:1<53::AID-JMRI7>3.0.CO;2-2)
 34. Chenevert TL, Stegman LD, Taylor JM, Robertson PL, Greenberg HS, Rehemtulla A, et al. Diffusion magnetic resonance imaging: an early surrogate marker of therapeutic efficacy in brain tumors. *J Natl Cancer Inst* 2000; **92**: 2029–36. doi: <https://doi.org/10.1093/jnci/92.24.2029>
 35. Padhani AR, Liu G, Koh DM, Chenevert TL, Thoeny HC, Takahara T, et al. Diffusion-weighted magnetic resonance imaging as a cancer biomarker: consensus and recommendations. *Neoplasia* 2009; **11**: 102–25. doi: <https://doi.org/10.1593/neo.81328>
 36. Ellingson BM, Bendszus M, Boxerman J, Barboriak D, Erickson BJ, Smits M, et al. Consensus recommendations for a standardized brain tumor imaging protocol in clinical trials. *Neuro Oncol* 2015; **17**: 1188–98. doi: <https://doi.org/10.1093/neuonc/nov095>
 37. Buemi F, Guzzardi G, Del Sette B, Sponghini AP, Matheoud R, Soligo E, et al. Apparent diffusion coefficient and tumor volume measurements help stratify progression-free survival of bevacizumab-treated patients with recurrent glioblastoma multiforme. *Neuroradiol J* 2019; **32**: 241–9. doi: <https://doi.org/10.1177/1971400919847184>
 38. Pope WB, Kim HJ, Huo J, Alger J, Brown MS, Gjertson D, et al. Recurrent glioblastoma multiforme: ADC histogram analysis predicts response to bevacizumab treatment. *Radiology* 2009; **252**: 182–9. doi: <https://doi.org/10.1148/radiol.2521081534>
 39. Pope WB, Lai A, Mehta R, Kim HJ, Qiao J, Young JR, et al. Apparent diffusion coefficient histogram analysis stratifies progression-free survival in newly diagnosed bevacizumab-treated glioblastoma. *AJNR Am J Neuroradiol* 2011; **32**: 882–9. doi: <https://doi.org/10.3174/ajnr.A2385>
 40. Pope WB, Qiao XJ, Kim HJ, Lai A, Nghiemphu P, Xue X, et al. Apparent diffusion coefficient histogram analysis stratifies progression-free and overall survival in patients with recurrent GBM treated with bevacizumab: a multi-center study. *J Neurooncol* 2012; **108**: 491–8. doi: <https://doi.org/10.1007/s11060-012-0847-y>
 41. Zeiner PS, Kinzig M, Divé I, Maurer GD, Filipki K, Harter PN, Martina K, Iris D, et al. Regorafenib CSF penetration, efficacy, and MRI patterns in recurrent malignant glioma patients. *J Clin Med* 2019; **8**: 2031. doi: <https://doi.org/10.3390/jcm8122031>
 42. Asao C, Korogi Y, Kitajima M, Hirai T, Baba Y, Makino K, et al. Diffusion-weighted imaging of radiation-induced brain injury

- for differentiation from tumor recurrence. *AJNR Am J Neuroradiol* 2005; **26**: 1455–60.
43. Chang PD, Chow DS, Yang PH, Filippi CG, Lignelli A. Predicting glioblastoma recurrence by early changes in the apparent diffusion coefficient value and signal intensity on FLAIR images. *AJR Am J Roentgenol* 2017; **208**: 57–65. doi: <https://doi.org/10.2214/AJR.16.16234>
44. Jain R, Scarpace LM, Ellika S, Torcuator R, Schultz LR, Hearshen D, et al. Imaging response criteria for recurrent gliomas treated with bevacizumab: role of diffusion weighted imaging as an imaging biomarker. *J Neurooncol* 2010; **96**: 423–31. doi: <https://doi.org/10.1007/s11060-009-9981-6>
45. Kondo M, Uchiyama Y. Apparent diffusion coefficient histogram analysis for prediction of prognosis in glioblastoma. *J Neuroradiol* 2018; **45**: 236–41. doi: <https://doi.org/10.1016/j.neurad.2017.11.011>
46. Kim BS, Kim ST, Kim JH, Seol HJ, Nam D-H, Shin HJ, et al. Apparent diffusion coefficient as a predictive biomarker for survival in patients with treatment-naive glioblastoma using quantitative multiparametric magnetic resonance profiling. *World Neurosurg* 2019; **122**: e812–20. doi: <https://doi.org/10.1016/j.wneu.2018.10.151>
47. LaViolette PS, Mickevicius NJ, Cochran EJ, Rand SD, Connelly J, Bovi JA, et al. Precise ex vivo histological validation of heightened cellularity and diffusion-restricted necrosis in regions of dark apparent diffusion coefficient in 7 cases of high-grade glioma. *Neuro Oncol* 2014; **16**: 1599–606. doi: <https://doi.org/10.1093/neuonc/nou142>
48. Mong S, Ellingson BM, Nghiemphu PL, Kim HJ, Mirsadraei L, Lai A, et al. Persistent diffusion-restricted lesions in bevacizumab-treated malignant gliomas are associated with improved survival compared with matched controls. *AJNR Am J Neuroradiol* 2012; **33**: 1763–70. doi: <https://doi.org/10.3174/ajnr.A3053>
49. Langen K-J, Galldiks N, Hattingen E, Shah NJ. Advances in neuro-oncology imaging. *Nat Rev Neurol* 2017; **13**: 279–89. doi: <https://doi.org/10.1038/nrneurol.2017.44>
50. Sundgren PC, Fan X, Weybright P, Welsh RC, Carlos RC, Petrou M, et al. Differentiation of recurrent brain tumor versus radiation injury using diffusion tensor imaging in patients with new contrast-enhancing lesions. *Magn Reson Imaging* 2006; **24**: 1131–42. doi: <https://doi.org/10.1016/j.mri.2006.07.008>