

Scientific Report

Penile hemangiosarcoma as a cause of stranguria in a dog: clinical presentation, imaging findings, treatment and outcome

Pierini, A.^{1*}; Picchi, C.¹; Pisani, G.¹; Binanti, D.²; Carli, A.¹;
Rossi, F.³ and Criscuolo, M. C.¹

¹Centro Veterinario Pisani-Carli-Chiodo Animalia, via Togliatti 8, 19034 Luni, SP, Italy; ²AbLab, Laboratorio di Analisi Veterinarie, via privata Massa Neri, 19038 Sarzana, SP, Italy; ³AniCura Clinica Veterinaria dell'Orologio, Via A. Gramsci, 1/5, 40037 Sasso Marconi, BO, Italy

*Correspondence: A. Pierini, Centro Veterinario Pisani-Carli-Chiodo Animalia, via Togliatti 8, 19034 Luni, SP, Italy. E-mail: pierini.aleccio2004@gmail.com



10.22099/IJVR.2024.48685.7113

(Received 25 Oct 2023; revised version 30 Apr 2024; accepted 30 Apr 2024)

This is an open access article under the CC BY-NC-ND license (<http://creativecommons.org/licenses/by-nc-nd/4.0/>)

Abstract

Background: Penile tumors are rare in dogs and only single case reports or small case series have been reported. **Case description:** An 11-year-old, cross-breed dog was presented for a two-week history of stranguria. At physical examination, a subcutaneous swelling of the penis was detected. Abdominal radiographs, ultrasonography, and CT showed a subcutaneous penile mass involving the penile urethra and *bulbus glandis* associated with marked lysis of the *os penis*. Histological features along with the neoplastic cell positivity to CD31 and FVIII immunohistochemical markers warranted a final diagnosis of penile hemangiosarcoma. **Findings/treatment and outcome:** The dog was treated with amputation of the penis, scrotal urethrostomy, and five adjuvant doses of doxorubicin along with thalidomide. Cutaneous and omental metastases were found 235 days after surgery. The dog was euthanized at 296 days due to bone and pulmonary metastasis. **Conclusion:** Penile hemangiosarcoma seems to share the same aggressive behavior with other hemangiosarcomas seen in other anatomical locations. Therefore, surgery and chemotherapy may improve survival time in dogs with penile hemangiosarcoma as well.

Key words: Doxorubicin, Neoplasm, Thalidomide

Introduction

Hemangiosarcoma (HSA) is a highly malignant tumor arising from vascular endothelium showing aggressive biological behavior and poor prognosis in dogs (Mullin and Clifford, 2020). The most common primary sites of HSA in dogs are the spleen, right atrium, and liver (Griffin *et al.*, 2021), followed by skin, pericardium, lung, kidney, oral cavity, muscle, bone, peritoneum, and retroperitoneum (Mullin and Clifford, 2020). Penile localization has been rarely reported in dogs (Marolf *et al.*, 2006; Burchell *et al.*, 2014; Fry *et al.*, 2014; Bolfer *et al.*, 2015) and the most commonly reported tumor in this localization is the squamous cell carcinoma, where only few case reports or small case series have been described (Mullin and Clifford, 2020). This report aimed to describe the clinical presentation, imaging findings, treatment, and outcome of a penile HSA in a dog.

Case description

An 11-year-old, neutered, 22-kg, cross-breed dog was presented for a two-week history of stranguria. The owner reported no history of trauma, uro-genital surgery, urinary tract infections or stones. Historically, the dog was monitored for a previous diagnosed myxomatous mitral valve disease. At physical examination, an 18 × 23 mm, subcutaneous, painless swelling with poorly defined margins on the ventral midline of the penis and a grade II heart murmur were detected.

Inguinal region lateral radiograph revealed diffused permeative lysis of the caudal two third of the *os penis*, associated with irregular, discontinuous periosteal reaction (Fig. 1A) surrounded with soft tissue swelling. The following ultrasonographic evaluation showed a 22 × 13 mm heterogeneous and ill-defined penile mass (Fig. 1B). Urethral catheterization confirmed a severe urethral stenosis with consequent inability to reach the urinary

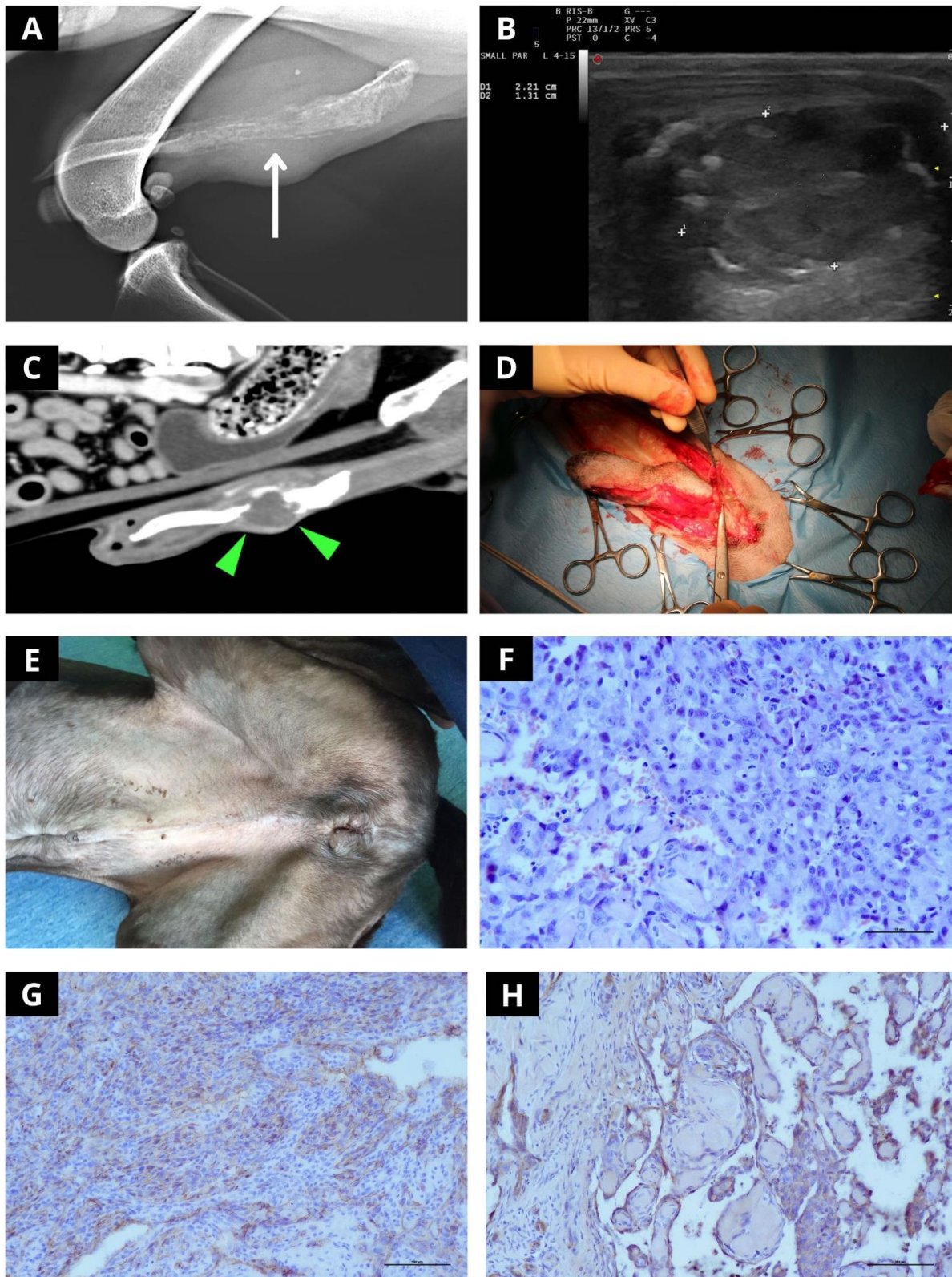


Fig. 1: Radiographic, ultrasonographic, surgical and pathological aspects of the penile HSA. (A) Lateral radiograph of the inguinal region revealed a soft tissue swelling and diffused lysis of the two-third caudal part of the *os penis* with an irregular and discontinuous periosteal reaction (arrow), (B) Penile ultrasound revealed a 22 × 13 mm heterogeneous and ill-defined penile mass, (C) CT scan, sagittal section through the penile bone (arrowheads), (D) Penile amputation appeared friable and hemorrhagic, (E) Scrotal urethrostomy 15 days after surgery, (F) Histology revealed a neoplasm composed of polygonal to spindle cells arranged in loose interlacing streams and bundles, and multiple blood-filled vascular channels (H&E, ×400), (G) Photomicrographs of the mass of the *os penis* (×200 magnification); neoplastic cells labelled with CD31 monoclonal antibody showing positive cytoplasmic granular labeling, and (H) Photomicrographs of the mass of the *os penis* (×200 magnification), neoplastic cells labelled with polyclonal Factor VIII antibody also showing positive cytoplasmic granular labelling on immunohistochemistry

bladder. Possible differential for such an osteolytic lesion included urethral tumors with bone invasion, primary osseous neoplasia, soft tissue tumors with bone involvement, or metastasis from an unknown primary tumor. Penile osteomyelitis was considered less probable because of the history and clinical presentation. Ultrasound-guided fine needle aspirations and cytological examination of the mass were performed, however, they were considered inadequate due to severe hemodiluted with no nucleated cells present on the slides.

A single right lateral thoracic radiograph showed unremarkable findings. Abdominal ultrasound revealed a normal-sized prostate with a 10.4×19 mm anechoic nodule at the left prostatic lobe compatible with a prostatic cyst, and diffuse thickening of the urinary bladder wall (4 mm), with maintained wall layer stratification. Differential diagnosis for bladder wall thickening included urinary bladder wall pseudo-thickening, less likely urinary bladder inflammation, infection, or diffuse neoplasia. A complete blood count and serum biochemical analysis were unremarkable. Further diagnostic procedures, such as endoscopic transurethral biopsy, transcutaneous biopsy, and CT scan were discussed with the owner. Concurrently, surgical options to allow the dog to restore the urinary outflow such as temporary/permanent percutaneous urinary bladder catheterization, temporary pre-scrotal urethral catheterization, permanent pre-scrotal urethrostomy, penile amputation and scrotal urethrostomy were discussed. Given the high risk of a penile tumor, the owner agreed to stage the dog through a whole-body CT scan before penile amputation and scrotal urethrostomy.

CT examination revealed a 25×18 mm penile expansive mass involving the penile urethra, *bulbus glandis*, and the proximal part of the *os penis* (Fig. 1C). The mass was hypoattenuating with mild peripheral enhancement and was associated with marked lysis of the *os penis* compatible with aggressive and osteolytic neoplasia. No other alterations were detected.

Findings/treatment and outcome

Penile amputation with scrotal urethrostomy was performed as previously described (Figs. 1D and E) (Burrow *et al.*, 2011).

Macroscopic evaluation revealed that the mass was friable and hemorrhagic. The patient recovered well and was discharged three days after surgery with E-collar and amoxicillin/clavulanic acid (12.5 mg/kg, every 12 h for 5 days). Hematuria was reported during hospitalization, with progressive improvement and complete resolution a few days after discharge.

Histological examination revealed an unencapsulated, poorly circumscribed, densely cellular neoplasm composed of pleomorphic, polygonal to spindle cells arranged in loose interlacing streams and bundles, and multiple blood-filled vascular channels. Neoplastic cells have indistinct borders, a small amount of eosinophilic fibrillar to vacuolated cytoplasm, and oval to elongated coarse nuclei. Severe anisocytosis and anisokaryosis

were observed. The mitotic figures ranged from 0 to 2 per high power field (Fig. 1F). Immunohistochemical staining showed that the neoplastic cells were positive for CD31 (Fig. 1G) and factor VIII (Fig. 1H). The final histopathological diagnosis was penile hemangiosarcoma.

Two weeks after surgery, the dog was diagnosed with multi-drug resistant *Escherichia coli* urinary bladder infection resolved after three days of enrofloxacin (5 mg/kg, q24h for 7 days).

Adjuvant chemotherapy with doxorubicin (30 mg/m² IV, q3wks, for five doses) and thalidomide (8 mg/kg, PO, q24h, with food at night) was started one month after surgery.

During treatment, the dog experienced self-limiting grade 2 thrombocytopenia, grade 1 neutropenia, decreased appetite, nausea, vomiting, and diarrhea (LeBlanc *et al.*, 2021).

Further clinical staging was performed using thoracic radiographs and abdominal ultrasounds on the day of the third and fifth doxorubicin administration and every 8 weeks thereafter for the first year (Nguyen *et al.*, 2015).

Two hundred and thirty-five days after surgery, the dog was followed up, and two cutaneous nodules were found. One of the nodules was 13×15 mm, mobile, ulcerated, and located in the proximal region of the right thigh. The second nodule was 22 mm in diameter, firm, and subcutaneous in the proximal region of the right quadriceps muscle (Fig. 2A). Both nodules were present for one month and were characterized by rapid growth according to the owner. Cytological examination showed proliferation of atypical mesenchymal cells, and cutaneous metastases of HSA were suspected (Fig. 2B). The thoracic radiographs were unremarkable. Abdominal ultrasound showed a 16×10 mm heterogeneous, hypochoic, ill-defined, omental mass suggestive of omental metastasis.

Thalidomide was discontinued because of disease progression, and a rescue chemotherapy protocol was proposed and declined by the owner.

On day 289, the dog was presented grade 3 lameness of the left hindlimb. Radiographic examination of the pelvis and thorax showed lysis of the femoral neck (Fig. 2C) and multiple pulmonary nodules (Fig. 2D) respectively, compatible with metastatic spread. Seven days later, 296 days after surgery, the dog was euthanized due to poor quality of life.

Discussion

Hemangiosarcomas in dogs are characterized by aggressive clinical behavior and poor prognosis, with median survival time ranging from 3 to 10 months after surgery and adjuvant doxorubicin-based chemotherapy. Primary dermal HSAs are curable with surgery alone, while deeper (subcutaneous and intramuscular) have been associated with a guarded prognosis with median survival times ranging from 172 to 1189 days (Bulakowski *et al.*, 2008; Shiu *et al.*, 2011). HSAs represent 3-8% of all bone tumors. A multi-institutional retrospective

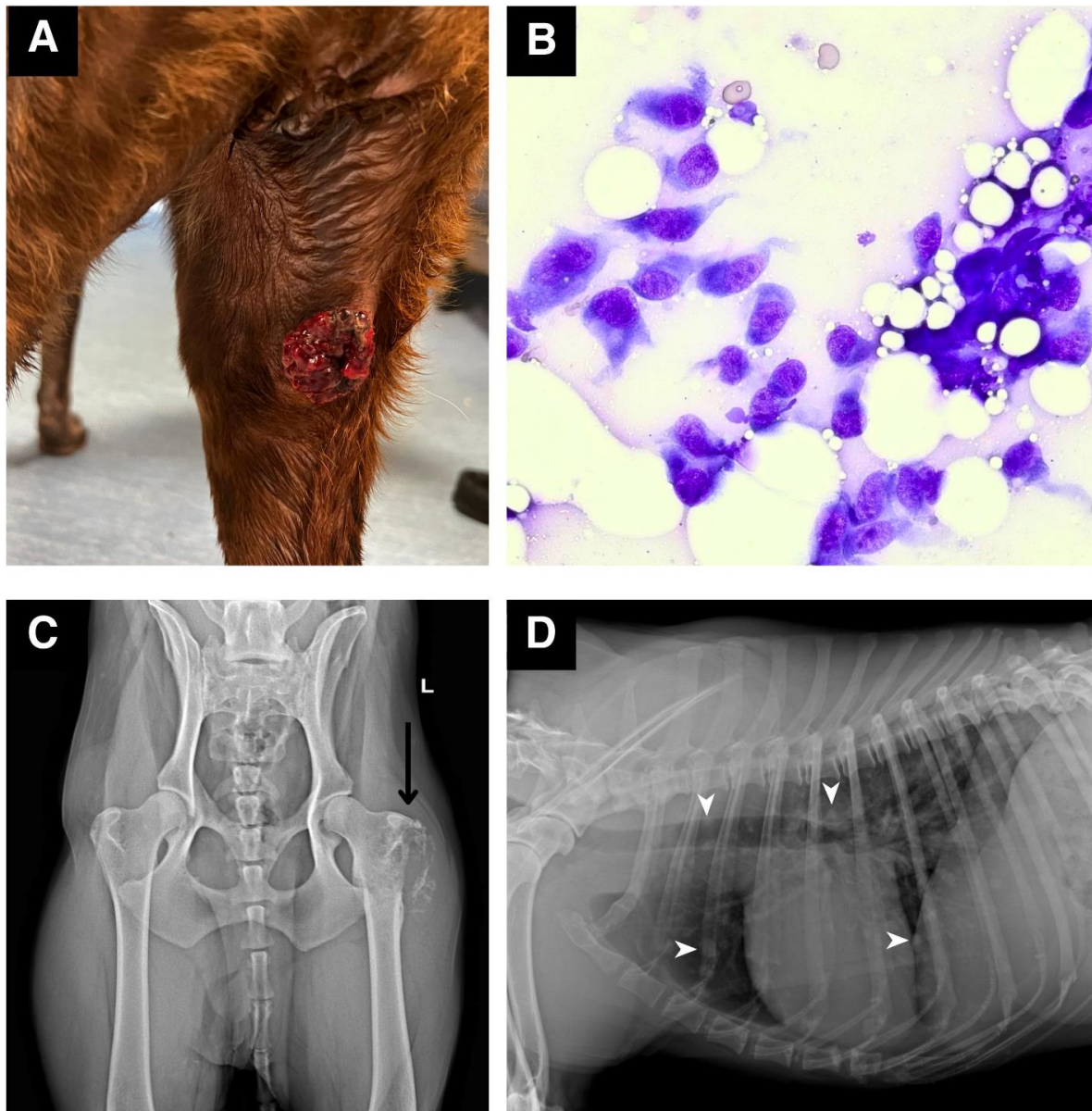


Fig. 2: Clinical, cytological, and radiographic aspects of penile HSA metastases. (A) One of the metastatic cutaneous nodules of HSA, where cytological sampling was performed, (B) Cytological examination representative atypical mesenchymal cells ($\times 400$), and (C-D) During the recheck (296 days after the penile amputation and scrotal urethrostomy) a ventrodorsal radiograph of the pelvic limb showed lysis of the femoral neck (C, arrow), and left lateral radiograph of thoracic revealed multiple pulmonary nodules (D, arrowheads)

study on forty-one primary appendicular HSAs reported a median survival time of 10 months and 1-year survival rate of 28% (Giuffruda *et al.*, 2018). Primary urethral HSAs are rare and are associated with aggressive behavior and short survival times (Mellanby *et al.*, 2004; Radhakrishnan, 2017).

Although penile HSA is the most common tumor of the *os penis* in dogs, it rarely occurs. To the authors' knowledge, this is the fifth reported case report of canine penile HSA (Marolf *et al.*, 2006; Burchell *et al.*, 2014; Fry *et al.*, 2014; Bolfer *et al.*, 2015).

Clinical presentation of dogs with penile HSA does not differ from that of dogs with other low urinary tract diseases, with stranguria being the most commonly reported. Moreover, concurrent urinary tract infections

have been commonly found and are frequently interpreted as the only cause of stranguria, thus delaying the diagnosis of neoplasia (Marolf *et al.*, 2006; Burchell *et al.*, 2014; Fry *et al.*, 2014; Bolfer *et al.*, 2015).

The treatment of choice for penile HSA includes excision of the primary tumor associated with adjuvant doxorubicin-based chemotherapy (Marolf *et al.*, 2006; Burchell *et al.*, 2014; Fry *et al.*, 2014; Bolfer *et al.*, 2015). In the present case, penile amputation and scrotal urethrostomy was well tolerated, and as expected, only mild postoperative hemorrhage and recurrent urinary tract infections occurred (Burrow *et al.*, 2011).

Post-splenectomy single-agent adjuvant thalidomide was associated with a median survival time of 172 days in dogs with splenic HSA (Bray *et al.*, 2018). In the pre-

sent case, thalidomide was combined with doxorubicin to maximize medical treatment. In the present case, thalidomide was administered at night along with food to increase drug absorption and prevent side effects (Pierini *et al.*, 2020).

Interestingly, no reports of dogs with penile HSA in the current literature, have shown locoregional or distant metastases at presentation, but they developed metastases 2, 5, and 20 months after, and died for tumor-related causes 8, 7, and 20 months after the initial diagnosis, respectively (Burchell *et al.*, 2014; Fry *et al.*, 2014; Bolfer *et al.*, 2015). Metastases most commonly occur in the lungs, retroperitoneum, and sublumbar lymph nodes (Fry *et al.*, 2014; Bolfer *et al.*, 2015). In the current study, metastases were found on the skin and omentum 235 days after diagnosis, and the dog was euthanized soon thereafter for bone and lung metastases.

Canine penile hemangiosarcoma seems to share the same aggressive behavior as other HSAs seen in anatomical locations other than the skin. As for other tumor locations, surgery and doxorubicin-based adjuvant chemotherapy may improve the survival time in dogs with penile HSA.

Acknowledgement

We thank A. Forlani for her writing assistance and contribution to this paper.

Conflict of interest

No conflicts of interest are declared.

References

- Bolfer, L; Schmit, JM; MacNeill, AL; Ragetly, CA; Bennett, RA and McMichael, M** (2015). Penile amputation and scrotal urethrostomy followed by chemotherapy in a dog with penile hemangiosarcoma. *J. Am. Anim. Hosp. Assoc.*, 51: 25-30.
- Bray, JP; Orbell, G; Cave, N and Munday, JS** (2018). Does thalidomide prolong survival in dogs with splenic haemangiosarcoma? *J. Small Anim. Pract.*, 59: 85-91.
- Bulakowski, EJ; Philibert, JC; Siegel, S; Clifford, CA; Ribson, R; Zivin, K and Cronin, KL** (2008). Intramuscular hemangiosarcoma. *J. Am. Vet. Med. Assoc.*, 233: 122-128.
- Burchell, RK; Kirberger, RM and Janse van Rensburg, DD** (2014). Haemangiosarcoma of the os penis in a dog: The most common neoplasm of the canine penis. *J. S. Afr. Vet. Assoc.*, 85: 1-4.
- Burrow, RD; Gregory, SP; Giejda, AA and White, RN** (2011). Penile amputation and scrotal urethrostomy in 18 dogs. *Vet. Rec.*, 169: 657.
- Fry, JK; Burney, D; Hottinger, H; Fabiani, M and Feagin, C** (2014). Pollakiuria and stranguria in a labrador retriever with penile HSA. *J. Am. Anim. Hosp. Assoc.*, 50: 141-147.
- Giuffrida, MA; Kamstock, DA; Selmic, LE; Pass, W; Szivek, A; Mison, MB; Boston, SE; Fox, LE; Robat, C; Grimes, JA; Maritato, KC and Bacon, NJ** (2018). Primary appendicular hemangiosarcoma and telangiectatic osteosarcoma in 70 dogs: A Veterinary Society of Surgical Oncology retrospective study. *Vet. Surg.*, 47: 774-783.
- Griffin, MA; Culp, WTN and Rebhun, RB** (2021). Canine and feline haemangiosarcoma. *Vet. Rec.*, 189: e585.
- LeBlanc, AK; Atherton, M; Bentley, RT; Boudreau, CE; Burton, JH; Curran, KM; Dow, S; Giuffrida, MA; Kelliher, HB; Mason, NJ; Oblak, M; Selmic, LE; Selting, KA; Singh, A; Vail, DM; Weishaar, KM; Berger, EP; Rossmeisl, JH and Mazcko, C** (2021). Veterinary Cooperative Oncology Group common terminology criteria for adverse events (VCOG-CTCAE v2) following investigational therapy in dogs and cats. *Vet. Comp. Oncol.*, 19: 311-352.
- Marolf, A; Specht, A; Thompson, M and Castleman, W** (2006). Imaging diagnosis: Penile hemangiosarcoma. *Vet. Radiol. Ultrasound.*, 47: 474-475.
- Mellanby, RJ; Chantrey, JC; Baines, EA; Ailsby, RL and Herrtage, ME** (2004). Urethral haemangiosarcoma in a boxer. *J. Small Anim. Pract.*, 45: 154-156.
- Mullin, C and Clifford, CA** (2020). Miscellaneous tumors. In: Vail, DM; Thamm, DH and Liptak, JM (Eds.), *Withrow & MacEwen's small animal clinical oncology*. (6th Edn.), Elsevier, Riverport Lane, St. Louis, Missouri. PP: 645-656.
- Nguyen, SM; Thamm, DH and Vail, DM** (2015). Response evaluation criteria for solid tumours in dogs (v1.0): A Veterinary Cooperative Oncology Group (VCOG) consensus document. *Vet. Comp. Oncol.*, 13: 176-183.
- Pierini, A; Sartini, I; Giorgi, M; Lebkowska-Wieruszewska, B; Lisowski, S; Poapolathep, A and Marchetti, V** (2020). Pharmacokinetics of thalidomide in dogs: can feeding affect it? A preliminary study. *J. Vet. Sci.*, 21: 1-11.
- Radhakrishnan, A** (2017). Urethral stenting for obstructive uropathy utilizing digital radiography for guidance: Feasibility and clinical outcome in 26 dogs. *J. Vet. Intern. Med.*, 31: 427-433.
- Shiu, KB; Flory, AB; Anderson, CL; Wypij, J; Saba, C; Wilson, H; Kurzman, I and Chun, R** (2011). Predictors of outcome in dogs with subcutaneous or intramuscular hemangiosarcoma. *J. Am. Vet. Med. Assoc.*, 238: 472-479.