

# The Effect of Vasopressin during Hysteroscopic Myomectomy in Patients with Submucosal Myoma: A Randomized Controlled Trial

## Abstract

**Background:** The aim was to assess the effect of vasopressin in reducing the time of surgery, amount of bleeding, and fluid deficit during hysteroscopic myomectomy of submucosal myoma from 2016 to 2018. **Materials and methods:** This study was conducted as a prospective, randomized, single-blinded clinical trial on the premenopausal women ranged from 18 to 62 years' old. A number of 80 patients were randomly assigned to each arm of the study according to random consecutive numbers. The control group ( $n = 40$ ) of patients underwent conventional hysteroscopic myomectomy without vasopressin and the case group ( $n = 40$ ) underwent hysteroscopic myomectomy with the injection of diluted vasopressin. Measured outcomes were time for myomectomy, fluid deficit, inflow volume, visual clarity, and postoperation hemoglobin level. **Results:** The mean time of myomectomy was 38.1 and 77.38 min in vasopressin and control groups, respectively ( $P < 0.001$ ). The mean inflow volume was 2800 and 4100 in vasopressin and control groups, respectively ( $P = 0.029$ ). The visual clarity score was 8.5 and 6.5 in the vasopressin and control groups, respectively ( $P < 0.001$ ). **Conclusions:** The injection of vasopressin during hysteroscopic myomectomy is effective in the management of fluid deficit, time of surgery, and improvement of visual clarity.

**Keywords:** *Hysteroscopy, leiomyoma, uterine, uterine myomectomy, vasopressin*

## Introduction

Uterine fibroma is the most prevalent type of benign tumor in the female reproductive system with the prevalence of 24%–40% among adult females.<sup>[1]</sup> About 10% of the myomas are submucosal, which can lead to symptoms such as bleeding, infertility, preterm labor, pain, and fetal malpresentation.<sup>[2]</sup> Hysteroscopic myomectomy is considered to be the most effective surgical method which increases the fertility rate and reduces the risk of menorrhagia.<sup>[3,4]</sup> The surgical challenge is the complete resection of the myoma in one session without further complications or relapsing symptoms.

The chance of complete resection relies on several confounding variables such as the location, type, and size of the submucosal myoma. If the size of myoma is larger than 3 cm, the chance of a secondary surgery increases.<sup>[5]</sup> Moreover, the volume deficit is another challenge in the complete resection of myoma. During the myomectomy, the open vessels of myoma mostly absorb the

fluid. Reduction in the amount of absorbed fluid will save more time for the surgeon for complete resection of the myoma.<sup>[6]</sup>

Vasopressin is a natural hormone that is secreted by the posterior lobe of the pituitary gland. Due to the vasoconstrictive effect of vasopressin on tissues, it has been used during abdominal and laparoscopic myomectomy.<sup>[7-9]</sup> However, studies on the use of vasopressin in hysteroscopic myomectomy are limited.

Some studies showed that the intracervical administration of vasopressin reduces the amount of blood loss and low-viscosity distension fluid absorbed due to its vasoconstrictive effect.<sup>[10,11]</sup> The management of blood loss during surgery reduces the operative time and improves the visual clarity.<sup>[12-14]</sup> The aim of the present study was to assess the effect of vasopressin in reducing the time of surgery, fluid deficit, visual clarity, and amount of bleeding.

## Materials and Methods

This was a multicenter (18–52 years of age, with balanced randomization [1:1]),

**How to cite this article:** Rouholamin S, Hashemi M, Haghshenas S. The effect of vasopressin during hysteroscopic myomectomy in patients with submucosal myoma: A randomized controlled trial. *Adv Biomed Res* 2021;10:22.

**Safoura  
Rouholamin,  
Maryam Hashemi,  
Sara Haghshenas**

*Department of Obstetrics and Gynecology, School of Medicine, Isfahan University of Medical Sciences, Isfahan, Iran.*

**Address for correspondence:**  
Dr. Maryam Hashemi,  
Department of Obstetrics and Gynecology, School of Medicine, Isfahan University of Medical Sciences, Isfahan, Iran.  
E-mail: maryam.hashemi88@gmail.com

**Received:** 01 April 2020  
**Revised:** 21 September 2020  
**Accepted:** 29 September 2020  
**Published:** 30 August 2021

Access this article online

Website: [www.advbiores.net](http://www.advbiores.net)

DOI: 10.4103/abr.abr\_70\_20

Quick Response Code:



This is an open access journal, and articles are distributed under the terms of the Creative Commons Attribution-NonCommercial-ShareAlike 4.0 License, which allows others to remix, tweak, and build upon the work non-commercially, as long as appropriate credit is given and the new creations are licensed under the identical terms.

For reprints contact: [WKHLRPMedknow\\_reprints@wolterskluwer.com](mailto:WKHLRPMedknow_reprints@wolterskluwer.com)

single-blind study took place at Alzahra and Beheshti hospitals, Isfahan University of medical science, Central Hospitals in Isfahan, Iran, from January 2016 to December 2018. Eligible participants were all adults aged 18 or over with symptomatic submucosal myoma confirmed by ultrasonography or diagnostic hysteroscopy who met the eligibility criteria for hysteroscopic myomectomy. This study is registered in the IRCT and the registration number is IRCT20120201008897N6, and it was also approved in the ethical group; its code of ethics is IR.MUI.REC.1396.3.113. To detect the sample size (standard deviation [SD] 0.9), with a two-sided 5% significance level and a power of 80%, a sample size of 20 patients per group was necessary, given an anticipated dropout rate of 10%. The minimum size for each group was assigned 22 patients. The inclusion criteria are the severity of the symptoms, for example, bleeding, infertility, preterm labor, pain, and fetal malpresentation that need surgery to remove the symptoms; moreover, the size, location, and grade of the myoma are important. The grade of submucosal myoma was determined by hysteroscopy using the Wamsteker grading system adopted by the European Society for Gynecological Endoscopy ranged from 0 to 2.<sup>[15]</sup> The size of myoma was between 1 and 5 cm, and they were located in the submucosal layer. The exclusion criteria included cardiovascular disease, migraine, seizure, asthma, multiple myomas, myoma larger than 5 cm and smaller than 1 cm, active pelvic infection, pregnancy, and type 3 myoma. Patients were randomly assigned to either vasopressin group or control group according to SPSS-22 (version 22; SPSS Inc., Chicago, Ill., USA). The determination of whether a patient would be treated by vasopressin or not was made by reference to a statistical series based on random sampling numbers drawn up for each two groups.

The operations were done in two different hospitals, carried out by one surgeon, and all the data were collected based on the prepared questionnaires. The physicians allocated to the intervention group were aware of the allocated arm outcome assessors but the data analyst and also the patients were kept blinded to the allocation. An informed consent form was filled for each patient.

At first, a number of 92 patients were assigned, but 12 patients did not meet the criteria. Finally, 80 participants enrolled in this study. The control group ( $n = 40$ ) of patients underwent conventional hysteroscopic myomectomy without vasopressin and the case group ( $n = 40$ ) underwent hysteroscopic myomectomy with injection of diluted vasopressin to submucosal myoma. The vasopressin used was from Exir company. The patients were given two pills of sublingual misoprostol 6 h before the surgery. The operation was performed under general anesthesia with a hysteroscopescope after the dilatation of the cervix to Hegar dilator 9 mm. All patients received prophylactic antibiotics. The uterus was distended with 3% glycine under a maximal pressure of 80 mmHg. The resections

were performed using monopolar-cutting loop. All resected specimens were sent separately for histologic examination.

In the vasopressin group, one vial (20 units) of vasopressin was diluted into 60 units of normal saline. 3 cc of vasopressin was injected in 3 points with the special needle for hysteroscopy. During injection, careful electrocardiographic monitoring was to detect arrhythmias. The blood sample was taken 4 h after the surgery to check the hemoglobin reduction and electrolyte imbalance. If volume deficit was more than 1 L during the surgery, the operation was stopped and the electrolytes were checked instantly. The outcomes included surgical time for myomectomy, volume of inflow fluid, fluid deficit, and visual analog scale assessment of visual clarity; the data were collected by the surgeon at the end of each intervention. All statistical analyses were conducted using IBM SPSS Statistics for Windows (Version 22.0 IBM Corp. Released 2013. Armonk, NY, USA). Categorical variables are reported as frequency (%) in each group and continuous variables are reported as mean SD or median and interquartile range for parametric and nonparametric variables, respectively.) Between group differences evaluated with *t*-test, Chi-square test, or fishers exact test as appropriate. Linear regression analysis was performed after adjustment for myoma size to assess the relationship. All tests were 2-tailed and  $P < 0.05$  was considered statistically significant. Complete resection of myoma was performed in all patients, and no further follow-up was carried out.

## Results

From February 2016 to November 2018, 92 patients were assessed for eligibility. Twelve patients were excluded from the study as a result of medical conditions or refusal to participate [Figure 1]. A total of 80 patients underwent surgery. About 56 patients had a history of NVD and 24 patients had cesarean section. The clinical characteristics and demographic data of patients are shown in Table 1. The two groups of patients were compatible in age, parity, NVD, the average size of myoma, type of myoma, the number of myomas, and involved surgeon. The mean age of patients was 31.3 and 23.61 in vasopressin and control groups, respectively. The size of myoma ranged from 1.5 to 5 cm in all of the patients. The mean time for the surgery was 61 min, ranging from 15 to 150 min.

The mean time of myomectomy was 38.1 and 77.38 min in vasopressin and control groups, respectively ( $P < 0.001$ ). The mean inflow volume was 2800 and 4100 in vasopressin and control groups, respectively ( $P = 0.029$ ). The level of hemoglobin before the surgery did not differ significantly between the two groups; moreover, no notable difference was seen in hemoglobin values after myomectomy ( $P = 0.041$ ). The visual clarity was scored by the involved surgeon based on a visual analog scale between 0 and 10. The visual clarity score was 8.5 and 6.5 in the vasopressin and control groups, respectively ( $P < 0.001$ ).

None of the patients reported complications after the surgery, and all of them were discharged within 24 h. Table 2 represents the operative results of hysteroscopic myomectomy in vasopressin and control groups.

### Discussion

This study was conducted on the premenopausal women ranged from 18 to 52 years' old. About 80 patients were randomly assigned to each arm of the study according to random consecutive numbers. The control group ( $n = 40$ ) of patients underwent conventional hysteroscopic myomectomy without vasopressin and the case group ( $n = 40$ ) underwent hysteroscopic myomectomy with the injection of diluted vasopressin. Measured outcomes were the time needed for myomectomy, fluid deficit, inflow volume, visual clarity, and postoperation hemoglobin

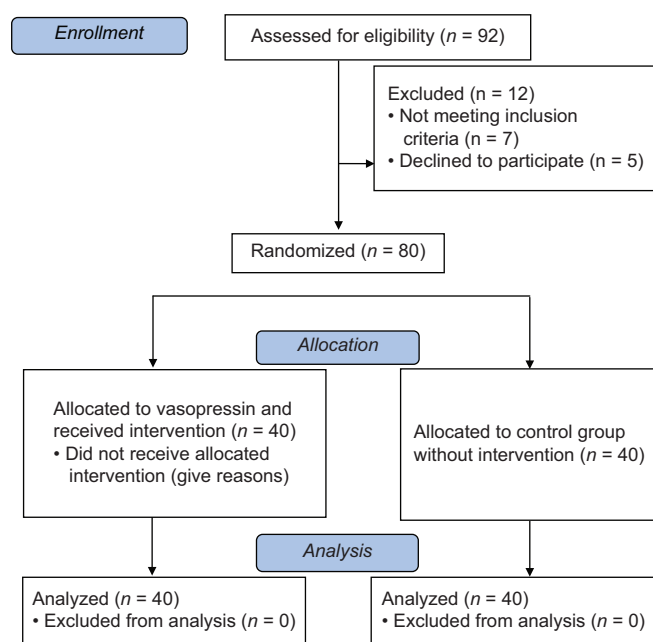


Figure 1: Flowchart showing participant recruitment

level. Submucosal myoma was seen in 25% of women in their reproductive ages.<sup>[1]</sup> Myomectomy is required in case of irregular menstruation or infertility. Myomectomy even in small myomas causes a 78% reduction in volume of bleeding in 6 months after the surgery.<sup>[2]</sup> The use of vasopressin in hysteroscopic myomectomy has been discussed. Vasopressin decreases the amount of blood loss and subsequently improves the visual clarity during the surgery leading to complete resection of myoma. The potential mechanism is constricted blood vessels.

In this study, there was a statistically significant difference between the time of surgery, volume deficit, and visual clarity between patients receiving vasopressin before surgery and control patients. Wong and Brun performed transcervical intralesional injection of vasopressin. In that study, there was not a meaningful correlation between the time of surgery and injection of vasopressin. Moreover, the fluid volume in vasopressin group was 5600 cc less than the placebo group. In the vasopressin group, the fluid deficit was nearly to zero and 95% of the vasopressin group had “minimal” bleeding compared with 36% in placebo.<sup>[14]</sup>

In the study done by Frederick *et al.*, myomectomy was performed after the intramyometrial injection of diluted vasopressin. The median blood loss was three times higher in the placebo group compared with the vasopressin group ( $P < 0.001$ ). Moreover, there was a significantly lower fall in hemoglobin level in the vasopressin group ( $P < 0.001$ ).<sup>[16]</sup> Corson *et al.* studied the effect of diluted vasopressin on intraoperative bleeding during hysteroscopic surgery. Diluted vasopressin (20 units of vasopressin in 50–100 cc of normal saline) or placebo was injected into the cervical stroma. Results revealed that among a total of 64 women, only 30% of patients in the vasopressin group were in the risk of volume deficit during the surgery.<sup>[10]</sup>

In another randomized controlled trial reported by Phillips *et al.*, intracervical injection of diluted (0.05 U/mL)

Table 1: Demographic data of patients

Characteristics	Vasopressin group (n=40)	Control group (n=40)	P
Age (years)	31.3	23.61	0.807
Number of myomas in ultrasonography	2.78	3.24	0.104
Preoperative Hb (g/dl)	11.60	11.8	0.041
Number of pregnancies	2	1.11	0.601

Hb: Hemoglobin

Table 2: Operative results of hysteroscopic myomectomy

Operative result	Vasopressin group (n=40)	Control group (n=40)	P
Time for myomectomy (min)	38.1	77.38	<0.001
Fluid deficit (ml)	64.23	285.12	<0.001
Inflow volume (ml)	2889.7	4718.5	0.029
Visual clarity (VAS score)	8.5	6.5	<0.001
Postoperative Hb (g/dl)	10.10	10.01	0.041

Hb: Hemoglobin, VAS: Visual Analog Scale

vasopressin was performed in 106 premenopausal women. Results indicated the notable effect of vasopressin in complete resection of myoma, blood loss, distention fluid extravasation, and operative time during hysteroscopy.<sup>[17]</sup> Canseco-Lima *et al.* reported two cases of office hysteroscopy myomectomy with vasopressin infiltration. They determined minimal blood loss, clear visual field, and complete resection of large myoma in one procedure.<sup>[12]</sup>

In another study, M Brigid *et al.* have concluded that during hysteroscopic myomectomy, injecting a diluted vasopressin solution into a submucosal myoma can provide the surgeon with more hemostasis and visualization in order to perform complete resection.<sup>[18]</sup>

Moreover, in the guideline released by the American College of Obstetricians and Gynecologists, it is indicated that the use of diluted vasopressin solution during hysteroscopic myomectomy has decreased intraoperative blood loss and fluid absorption in two randomized trials.

Ferguson *et al.* reported another case of complete large intracavity myomectomy with vasopressin injection.<sup>[13]</sup> The existing literature confirms that with both intracervical and intralesional injection of dilute vasopressin, surgeons will be able to manage the bleeding and loss of fluid during myomectomy which leads to complete resection of myoma in one session. Here, in this study, we performed all resections in one session. We injected vasopressin into the myoma. Most of the previous studies reported intracervical injection as the method of choice. The injection of vasopressin into the myoma will make it difficult to infiltrate the vascularization of myoma to induce local ischemia. In another randomized controlled trial reported by Phillips *et al.*, the intracervical injection of vasopressin might cause hypertension and bradycardia due to the possibility of injection into the uterine artery.

One meta-analysis reported by Dr. Samy *et al.* showed different conclusions. This study assessed the effectiveness of various pharmacological interventions, for example, oxytocin, ornipressin, bupivacaine plus epinephrine, misoprostol, and vasopressin for reducing blood loss during minimally invasive myomectomy and open surgery. For minimally invasive myomectomy, oxytocin and ornipressin and for open myomectomy, vasopressin plus misoprostol were effective in reducing blood loss.<sup>[19]</sup>

## Conclusions

Our results revealed that the injection of vasopressin during hysteroscopic myomectomy is effective in the management of fluid deficit, time of surgery, and improvement of visual clarity, although the visual clarity was assigned by the surgeon and it is not completely accurate. Moreover, we recognized that the injection of vasopressin into the myoma might be safer and more efficient compared with intracervical injections.

## Acknowledgments

The authors acknowledge the whole staff of the laparoscopic operation room and gynecologic ward in women's hospital.

## Financial support and sponsorship

Nil.

## Conflicts of interest

There are no conflicts of interest.

## References

1. Guo XC, Segars JH. The impact and management of fibroids for fertility: An evidence-based approach. *Obstet Gynecol Clin* 2012;39:521-33.
2. Roy KK, Singla S, Baruah J, Sharma JB, Kumar S, Singh N. Reproductive outcome following hysteroscopic myomectomy in patients with infertility and recurrent abortions. *Arch Gynecol Obstet* 2010;282:553-60.
3. Mettler L, Schollmeyer T, Tinelli A, Malvasi A, Alkatout I. Complications of uterine fibroids and their management, surgical management of fibroids, laparoscopy and hysteroscopy versus hysterectomy, haemorrhage, adhesions, and complications. *Obstet Gynecol Int* 2012;2012:791248.
4. Wong L, Brun JL. Myomectomy: Technique and current indications. *Minerva Ginecol* 2014;66:35-47.
5. American Association of Gynecologic Laparoscopists (AAGL): Advancing Minimally Invasive Gynecology Worldwide. AAGL practice report: Practice guidelines for the diagnosis and management of submucous leiomyomas. *J Minim Invasive Gynecol* 2012;19: 152.
6. AAGL Advancing Minimally Invasive Gynecology Worldwide, Munro MG, Storz K, Abbott JA, Falcone T, Jacobs VR, *et al.* AAGL practice report: Practice guidelines for the management of hysteroscopic distending media: (replaces hysteroscopic fluid monitoring guidelines. *J Am Assoc Gynecol Laparosc.* 2000;7:167-168.
7. Kongnyuy EJ, van Den Broek N, Wiysonge C. A systematic review of randomized controlled trials to reduce hemorrhage during myomectomy for uterine fibroids. *Int J Gynecol Obstet* 2008;100:4-9.
8. Ascher-Walsh CJ, Capes T, Smith J, Michels A. Cervical vasopressin compared with no premedication and blood loss during vaginal hysterectomy: A randomized controlled trial. *Obstet Gynecol* 2009;113:313-8.
9. Song T, Kim MK, Kim ML, Jung YW, Yun BS, Seong SJ. Use of vasopressin vs epinephrine to reduce haemorrhage during myomectomy: A randomized controlled trial. *Eur J Obstet Gynecol Reprod Biol* 2015;195:177-81.
10. Corson SL, Brooks PG, Serden SP, Batzer FR, Gocial B. Effects of vasopressin administration during hysteroscopic surgery. *J Reprod Med* 1994;39:419-23.
11. Overdijk LE, Rademaker BM, van Kesteren PJ, de Haan P, Riezebos RK, Haude OC. The HYSTER study: The effect of intracervically administered terlipressin versus placebo on the number of gaseous emboli and fluid extravasation during hysteroscopic surgery: Study protocol for a randomized controlled clinical trial. *Trials* 2018;19:107.
12. Canseco-Lima JM, Hernandez-Denis A, Audifred-Salomon J. Vasopressin myoma infiltration during hysteroscopic myomectomy. *J Minim Invasive Gynecol* 2015;22:S123.
13. Ferguson J, Rattray D, Thiel J, Weins L. Intraoperative

- vasopressin injection during hysteroscopic myomectomy. *Journal of Minimally Invasive Gynecology*. 2016;23 (7):S146.
14. Wong AS, Cheung CW, Yeung SW, Fan HL, Leung TY, Sahota DS. Transcervical intralesional vasopressin injection compared with placebo in hysteroscopic myomectomy: A randomized controlled trial. *Obstet Gynecol* 2014;124:897-903.
  15. Wamsteker K, Emanuel MH. Transcervical hysteroscopic resection of submucous fibroids for abnormal uterine bleeding: Results regarding the degree of intramural extension. *Obstet Gynecol*, 1993;82:736-40.
  16. Frederick J, Fletcher H, Simeon D, Mullings A, Hardie M. Intramyometrial vasopressin as a haemostatic agent during myomectomy. *Br J Obstet Gynaecol* 1994;101:435-7.
  17. Phillips DR, Nathanson HG, Milim SJ, Haselkorn JS, Khapra A, Ross PL. The effect of dilute vasopressin solution on blood loss during operative hysteroscopy: A randomized controlled trial. *Obstet Gynecol* 1996;88:761-6.
  18. Holloran-Schwartz MB, Harrison K, Gimpelson R. Direct injection of vasopressin during hysteroscopic myomectomy: A case report. *J Reprod Med* 2014;59:614-6.
  19. Samy A, Raslan AN, Talaat B, El Lithy A, El Sharkawy M, Sharaf MF, *et al.* Perioperative nonhormonal pharmacological interventions for bleeding reduction during open and minimally invasive myomectomy: A systematic review and network meta-analysis. *Fertil Steril* 2020;113:224-33.e6.