

Oral administration of sunitinib malate for long-term survival of a patient with multiple lung metastases from renal leiomyosarcoma

Xiaoyan Li
Hongjun Gao
Chuanhao Tang
Xiaoqing Liu

Department of Lung Cancer, Affiliated
Hospital of Academy of Military
Medical Sciences, Beijing, People's
Republic of China

Abstract: Sunitinib, an oral tyrosine kinase inhibitor, has been approved by the US Food and Drug Administration for the treatment of metastatic renal cell carcinoma and imatinib-refractory gastrointestinal stromal tumor. In non-gastrointestinal stromal tumor soft tissue sarcomas, the activity of this small-molecule drug has been rarely reported. Herein, we report a patient with lung metastases from renal leiomyosarcoma who responded favorably to sunitinib after the failure of conventional chemotherapy. Adverse effects of sunitinib, which include fatigue, hand-foot syndrome, and stomatitis were observed following its administration. Withdrawal of sunitinib led to progression of disease, and resuming use of sunitinib was still effective for multiple lung metastases. Sunitinib might be an effective treatment for renal leiomyosarcoma, especially when conventional chemotherapy fails.

Keywords: sunitinib, gastrointestinal stromal tumor, GIST, renal leiomyosarcoma

Introduction

Primary renal sarcomas in adults are rare, constituting from 0.8% to 2.7% of all renal tumors.¹ Amongst the renal sarcomas, leiomyosarcoma is the most common histological subtype, accounting for 50% to 60% of all cases.¹ Primary renal leiomyosarcomas occur at any age, with the incidence rate in females being slightly higher than that in males, especially in females in the fourth to sixth decades of life. Renal leiomyosarcoma, similar to leiomyosarcomas of bone and soft tissue, is highly aggressive and usually less sensitive to chemotherapy and radiotherapy. High-grade renal sarcoma often metastasizes, commonly to the lungs and brain. According to the National Comprehensive Cancer Network guidelines for management of bone and soft tissue sarcomas, first-line therapy for patients with relapsed renal leiomyosarcoma is ifosfamide and/or doxorubicin, and optional drugs for second-line therapy include paclitaxel, docetaxel, gemcitabine, vinorelbine, dacarbazine, mitomycin, temozolomide, pazopanib, and others.² However, successful treatment of multiple lung metastases from renal leiomyosarcoma is still challenging.

Sunitinib malate is an oral, multi-targeted tyrosine kinase inhibitor and acts on vascular endothelial growth factor receptors-1, -2, and -3, platelet-derived growth factor receptors α and β , c-Kit receptor kinases, Fms-like TK 3 receptor, and the receptor encoded by the RET proto-oncogene.³ Preclinical studies have shown that sunitinib possesses anti-angiogenic properties and broad-spectrum antitumor activities against a variety of solid tumors such as lung cancer, gastrointestinal stromal tumor, kidney cancer, liver cancer, breast cancer, and melanoma.^{4,5} After a multi-center, prospective

Correspondence: Xiaoqing Liu
Department of Lung Cancer, Affiliated
Hospital of Academy of Military Medical
Sciences, No 8 Dongdajie, Beijing 100071,
People's Republic of China
Tel +86 136 8118 7500
Fax +86 10 5112 8605
Email liuxq@medmail.com.cn

randomized study, sunitinib has been approved by the US FDA for the treatment of metastatic renal cell carcinoma and imatinib-refractory gastrointestinal stromal tumor (GIST).⁶ Although sunitinib has become a first- and second-line treatment for renal cell carcinoma, its efficacy and safety have not been thoroughly investigated. Herein, we report on an effective antitumor response to sunitinib malate in a 42-year-old female patient with lung metastases from renal leiomyosarcoma.

Case report

A 42-year-old female who complained of right abdominal pain was admitted to No 307 Hospital, Affiliated Hospital of the Academy of Military Medical Sciences, Beijing, People's Republic of China in April 2004. Abdominal computed tomography (CT) scan revealed a huge mass in the right kidney (size: 10.8 cm × 7.6 cm). The patient then underwent a radical surgical resection of the right kidney under general anesthesia on May 1, 2004. The postoperative pathology examination confirmed that the mass was renal leiomyosarcoma. The patient received interferon treatment for 3 months after surgery, and she was in a stable, tumor-free state during the follow-up period. In April 2009, the patient felt pain and discomfort on both sides of the chest for no obvious reasons. The chest CT scan on April 15, 2009 showed multiple pulmonary nodular lesions, and the patient was finally diagnosed with multiple lung metastases from renal leiomyosarcoma (Figure 1). In the subsequent two years, the patient received intensive chemotherapy,

including paclitaxel, carboplatin, docetaxel, ifosfamide, epirubicin, and others.

The patient began taking oral sunitinib malate at the dose of 37.5 mg/d after October 28, 2011. A chest CT scan 4 weeks later indicated a stable disease (SD) status with some lung lesions presenting vacuoles, according to the Response Evaluation Criteria in Solid Tumors (RECIST) (Figure 1B). No hematologic changes were found in the patient during the treatment with sunitinib. Toxic adverse effects of sunitinib malate, based on the Common Terminology Criteria for Adverse Events v3.0, were observed in this patient, including fatigue (grade 2), hand-foot syndrome (grade 3) (Figure 2A and B), and stomatitis (grade 2). For this reason, the dose of sunitinib malate was reduced to 25 mg/d, and the adverse reaction of hand-foot syndrome was alleviated. Unfortunately, this treatment led to a repeated, unstable hand-foot syndrome, which the patient could not tolerate at times. Therefore, the patient had to take oral sunitinib malate intermittently, and the longest withdrawal interval was 1.5 months (from July to August 2012). A chest CT scan on August 21, 2012 revealed progressive disease due to the withdrawal of sunitinib malate (Figure 1C). However, the patient was restored to a SD status just 1 month after she resumed sunitinib treatment (Figure 1D), indicating that sunitinib malate was still effective for the control of multiple lung metastases. The patient then continued oral sunitinib malate treatment at a dose of 25 mg/d on a 3-week on/1-week off regimen. The main adverse effects were hand-foot syndrome (grades 1–2), hypothyroidism (grade 1), and fatigue

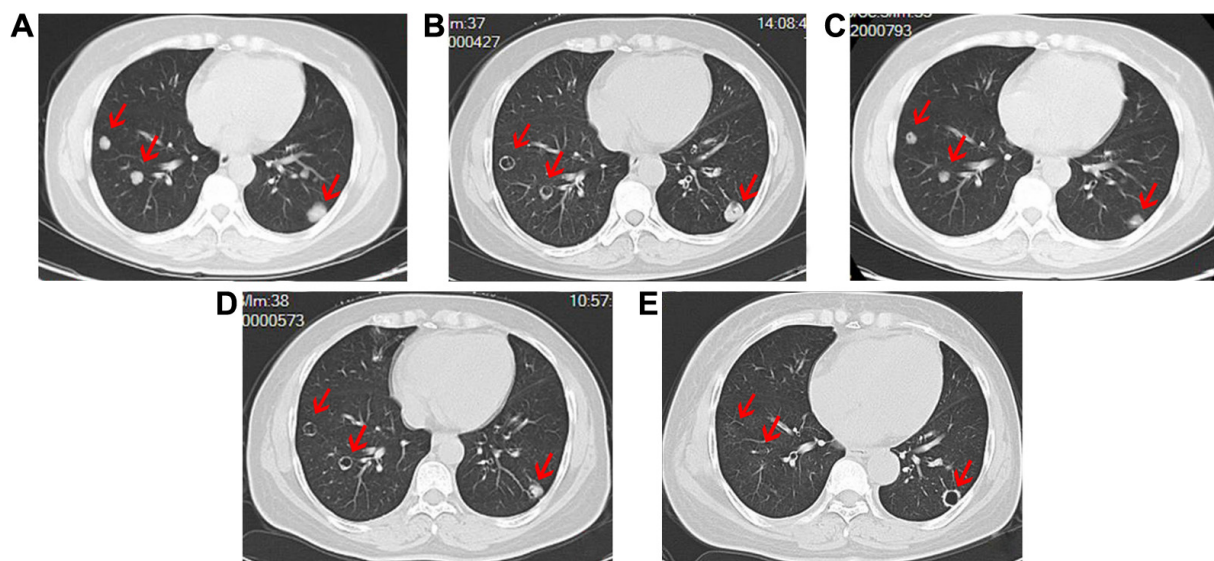


Figure 1 Computed tomography images of the chest of a patient with multiple lung metastases from renal leiomyosarcoma.

Notes: (A) Before sunitinib malate treatment; (B) 4 weeks after sunitinib malate treatment (37.5 mg/d); (C) 1 month after withdrawal of sunitinib malate due to severe adverse effects; (D) after resuming use of sunitinib malate at the dose of 25 mg/d; (E) 26 months after sunitinib malate treatment. Arrows indicate sites of lesions.

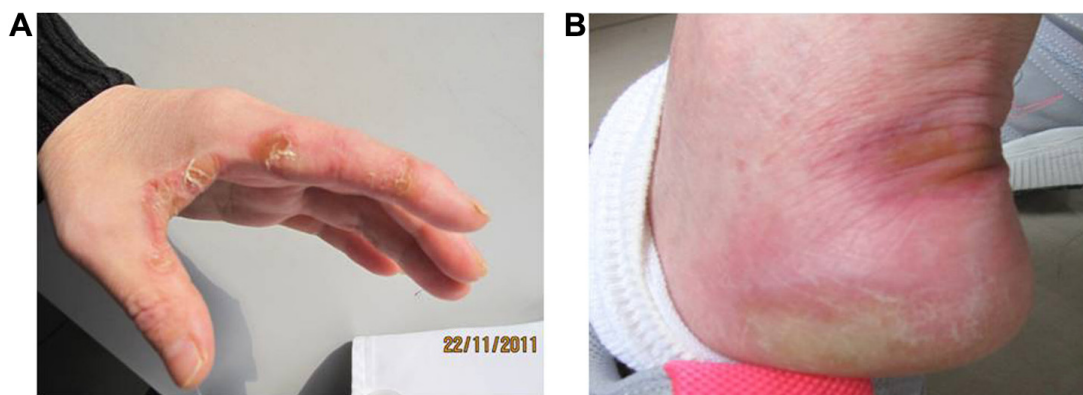


Figure 2 Adverse effects of sunitinib malate included hand-foot syndrome (grade 3).
Notes: (A) hand; (B) foot.

(grade 1). As of March 15, 2014, the patient has continually taken oral sunitinib malate for 26 months, and chest CT scans have indicated no progression of disease (Figure 1E). Written informed consent was obtained from the patient for this study.

Discussion

In non-GIST soft tissue sarcomas, sunitinib is now an experimental treatment, and there are few studies about the efficacy and safety of this small-molecule drug. Vigil et al⁷ reported 36 patients in a single center who were treated with sunitinib for soft tissue sarcomas, including leiomyosarcoma, liposarcoma, malignant fibrous histiocytoma, and fibrosarcoma. The results showed that 29 (80.6%) subjects exhibited a SD status for at least 12 weeks and one patient (2.78%) had a partial response, demonstrating acceptable tolerance to sunitinib in metastatic soft tissue sarcomas of different histologies. George et al⁸ reported a multi-center, stage II clinical study that was designed to evaluate the potential benefit of sunitinib in the treatment of advanced non-GIST soft tissue sarcomas. The primary end-point was efficacy defined by RECIST, and secondary end-points were SD at 16 and 24 weeks. Among 53 patients who received 37.5 mg/d of sunitinib, one patient achieved a confirmed partial response and ten patients achieved SD status for at least 16 weeks; no unexpected toxicities were observed. In the present study, the patient presented with an increasingly enlarged lung mass, even after repeated chemotherapy, and exhibited evidence of metastatic lung lesions originating from renal leiomyosarcoma. The patient took sunitinib at the initial dose of 37.5 mg/d, and the dose was gradually adjusted to 25 mg/d for maintenance. Eventually, this approach proved to be very successful, reaching SD for 26 months; the patient is still alive. Thus, among published reports, this case has achieved the longest progression-free survival in a patient

with multiple lung metastases from renal leiomyosarcoma, treated by sunitinib.

The fact that sunitinib is anti-angiogenic and targets many different receptors leads to many of its adverse effects. Fatigue is the most frequent adverse effect among patients treated with sunitinib, and it often appears in the second week of treatment.⁹ Dermatologic toxicities, mainly shown as hand-foot syndrome, occur in approximately 20% of patients using sunitinib.¹⁰ Commonly reported gastrointestinal reactions include diarrhea, nausea, vomiting, stomatitis, and mucositis. Hematologic toxicities include neutropenia (72%), anemia (71%), and thrombocytopenia (65%).¹⁰ In addition, hypertension, thrombosis, and bleeding are specific adverse reactions with sunitinib due to its action as an angiogenesis inhibitor.⁹

Toxicities observed in the patient in this study were consistent with other published sunitinib experiences, such as fatigue and hand-foot syndrome, and could be managed with dose-modulation. Due to these adverse events, sunitinib was discontinued for a period of time, which resulted in disease progression. Subsequently, the patient resumed taking oral sunitinib malate at the dose of 25 mg/d on a 3-week on/1-week off regimen that proved to be effective and was well-tolerated.

Thus far, the evaluation criteria for solid tumors that are widely used in clinical studies, such as the World Health Organization criteria or RECIST, do not accurately reflect the efficacy of anti-angiogenesis drugs. Usually, a decreased rate of change in the longest diameter is used for evaluating antitumor activity of treatments. In this study, we did not find a significant decrease in diameter of the metastatic pulmonary lesions, according to the RECIST criteria. However, it is worth noting that the lung metastatic lesions presented as regular, thin-walled, hollow cavities with lung markings,

exhibiting superior antitumor activities and effective anti-angiogenic effects by anti-angiogenic drugs. Therefore, more effective criteria for evaluation of anti-angiogenic drugs targeting tumor angiogenesis should be developed, for example, to measure CT values, calculate the area of lesions, and dynamically monitor blood flow signals of tumors.

To be noted, this study should be interpreted with caution for other oncologists when they assign this therapy for subsequent similar patients, since this study highlights the clinical validation of sunitinib in a single patient. Determining these findings with certainty, however, will require further investigation in the context of a larger, well-controlled clinical trial setting.

Conclusion

This case reminds us that the appropriate dose of sunitinib may provide long-term benefits for patients with multiple lung metastases from renal leiomyosarcoma, especially when conventional chemotherapy fails.

Disclosure

The authors report no conflicts of interest in this work.

References

1. Dhawan S, Chopra P, Dhawan S. Primary renal leiomyosarcoma: A diagnostic challenge. *Urol Ann.* 2012;4(1):48–50.
2. von Mehren M, Benjamin RS, Bui MM, et al. Soft tissue sarcoma, version 2.2012: featured updates to the NCCN guidelines. *J Natl Compr Canc Netw.* 2012;10(8):951–960.
3. Homet Moreno B, Garralda Cabanas E, Hitt R. Tyrosine kinase inhibitors in treating soft tissue sarcomas: sunitinib in non-GIST sarcomas. *Clin Transl Oncol.* 2010;12(7):468–472.
4. Gan HK, Seruga B, Knox JJ. Sunitinib in solid tumors. *Expert Opin Investig Drugs.* 2009;18(6):821–834.
5. Adams VR, Leggas M. Sunitinib malate for the treatment of metastatic renal cell carcinoma and gastrointestinal stromal tumors. *Clin Ther.* 2007;29(7):1338–1353.
6. Motzer RJ, Hutson TE, Tomczak P, et al. Sunitinib versus interferon alfa in metastatic renal-cell carcinoma. *N Engl J Med.* 2007;356(2):115–124.
7. Vigil CE, Chiappori AA, Williams CA, et al. Phase II study of sunitinib malate (SM) in subjects with metastatic and/or surgically unresectable non-GIST soft tissue sarcomas. *J Clin Oncol.* 2008;26(15S):10535.
8. George S, Merriam P, Maki RG, et al. Multicenter phase II trial of sunitinib in the treatment of nongastrointestinal stromal tumor sarcomas. *J Clin Oncol.* 2009;27(19):3154–3160.
9. Schwandt A, Wood LS, Rini B, Dreicer R. Management of side effects associated with sunitinib therapy for patients with renal cell carcinoma. *Oncotargets Ther.* 2009;2:51–61.
10. Nosov DA, Esteves B, Lipatov ON, et al. Antitumor activity and safety of tivozanib (AV-951) in a phase II randomized discontinuation trial in patients with renal cell carcinoma. *J Clin Oncol.* 2012;30(14):1678–1685.

OncoTargets and Therapy

Publish your work in this journal

OncoTargets and Therapy is an international, peer-reviewed, open access journal focusing on the pathological basis of all cancers, potential targets for therapy and treatment protocols employed to improve the management of cancer patients. The journal also focuses on the impact of management programs and new therapeutic agents and protocols on

Submit your manuscript here: <http://www.dovepress.com/oncotargets-and-therapy-journal>

patient perspectives such as quality of life, adherence and satisfaction. The manuscript management system is completely online and includes a very quick and fair peer-review system, which is all easy to use. Visit <http://www.dovepress.com/testimonials.php> to read real quotes from published authors.

Dovepress