

Demographic characteristic and analysis of pulmonary paragonimiasis in patients attending RIMS, Manipur

Haorongbam Sunanda, Bhavya Shivalingaiah, Tamar Paley, Wangkheimayum Asoka

Department of Respiratory Medicine, Regional Institute of Medical Sciences, Imphal, Manipur, India

ABSTRACT

Background: Human infection by the lung fluke *Paragonimus westermani* is widely distributed in Africa, Asia, and South America. Transmission of the parasite to humans primarily occurs through the consumption of raw or undercooked crabs. Clinical features of recently diagnosed pulmonary Paragonimiasis show that patients present with a variety of clinical and radiological findings, frequently mimics tuberculosis and lung cancer. **Methods:** Here in this study, we report a cross-sectional study of pulmonary paragonimiasis in our institute over a period of two year. **Results:** it was observed that out of eleven cases, prevalence of paragonimiasis was almost equal among both the genders, with a mean age of 38.1 ± 16.96 , affecting people from hills. Three patients were erroneously treated with antitubercular drugs without any relief. The association with eosinophilia in the peripheral blood and tissue[16] was seen in all the study subjects and majority patients had pleural fluid eosinophilia. Patients were diagnosed by serological test, Paragonimus ova in Sputum smear and Pleural fluid. All study subjects had excellent clinical responses to praziquantel given at dose of 25 mg/kg given orally 3 times daily for 3 consecutive days. **Conclusions:** There is a need to generate awareness among the clinicians and public regarding Paragonimiasis and to consider it in differential diagnosis of TB and carcinoma lung. Physicians should consider the possibility of paragonimiasis among patients who present with chest complaints with eosinophilia from the endemic regions.

KEY WORDS: Lung fluke, paragonimiasis, parasites

Address for correspondence: Dr. Bhavya Shivalingaiah, Department of Respiratory Medicine, Regional Institute of Medical Sciences, Imphal, Manipur, India. E-mail: Bhavya_gowda92@yahoo.co.in

INTRODUCTION

Human infection by the lung fluke *Paragonimus westermani* is endemic in parts of Africa, Asia, and South America. Transmission of the parasite to humans primarily occurs through the consumption of raw or undercooked crabs and cray fish.^[1] Patients present with a variety of clinical and radiological findings, frequently mimicking those of tuberculosis (TB) and lung cancer. The first indigenous case of human paragonimiasis, in India, was described by Singh *et al.*^[2] in 1981, in Manipur. Paragonimiasis cases have been detected every year in Manipur, but only a few have been reported.^[3]

Aim and objects

This study has been carried out with an aim to study the demographic characteristics of patients with pulmonary paragonimiasis to analyze their clinical features associated complications and discuss their optimal management.

MATERIALS AND METHODS

The study was an institutional based cross-sectional study conducted at the Department of Respiratory Medicine, Regional Institute of Medical Sciences, Imphal, Manipur, from January 2013 to December 2015. Eleven cases were detected from patients who were coming from different

This is an open access article distributed under the terms of the Creative Commons Attribution-NonCommercial-ShareAlike 3.0 License, which allows others to remix, tweak, and build upon the work non-commercially, as long as the author is credited and the new creations are licensed under the identical terms.

For reprints contact: reprints@medknow.com

How to cite this article: Sunanda H, Shivalingaiah B, Paley T, Asoka W. Demographic characteristic and analysis of pulmonary paragonimiasis in patients attending RIMS, Manipur. Lung India 2016;33:140-3.

Access this article online	
Quick Response Code: 	Website: www.lungindia.com
	DOI: 10.4103/0970-2113.177436

areas of Manipur and attending the outpatient department and/or were admitted in the indoor wards of the Department of Respiratory Medicine during the study period. Patient with recurrent respiratory symptoms such as cough, chest pain, breathlessness, hemoptysis, fever, pleural effusion, peripheral eosinophilia, and pleural fluid eosinophilia, who were above 18 years were included in this study, whereas those patients who were unwilling to participate or patients whose peripheral eosinophilic count and absolute eosinophilic count was found to be in normal limit were excluded from this study as suspicion of parasitic disease is aroused by the peripheral blood eosinophilia who resides or travelled to endemic area.^[4] Each individual enrolled in the study underwent a detailed history, clinical examination, and laboratory examination designed for the study. The study was approved by the Institutional Review Board, and all participants gave written informed consent.

In all the participating patients, routine blood investigations including absolute eosinophil count were carried out. Chest X-ray PA view, sputum for acid-fast *Bacilli* (AFB) smear and culture, sputum smear for *Paragonimus* eggs, and serological test for paragonimiasis (ELISA) were done. Diagnostic pleural tapping was done in the case of patients with pleural effusion, and fluid was sent for routine analysis including Gram stain, AFB smear and culture, and eggs for *Paragonimus*.

Statistical analysis was performed using SPSS Version 16 for windows, (SPSS Inc. Chicago, Illinois, United States of America). Data were expressed in Mean \pm standard deviation (SD). The $P < 0.05$ was considered significant.

RESULTS AND OBSERVATION

A total of 11 patients were diagnosed to have paragonimiasis during our study period.

Table 1 show, out of these 11 cases, 05 (45.5%) were males and 06 (54.5%) were females. Mean age (\pm SD) in years for cases was 38.1 (\pm 16.96), among them 7 were from hilly areas and 4 from the valley, and all cases had a history of fresh water crab intake either raw or pickled form.

Figure 1 shows different presentation of pulmonary paragonimiasis. All patients had respiratory symptoms.

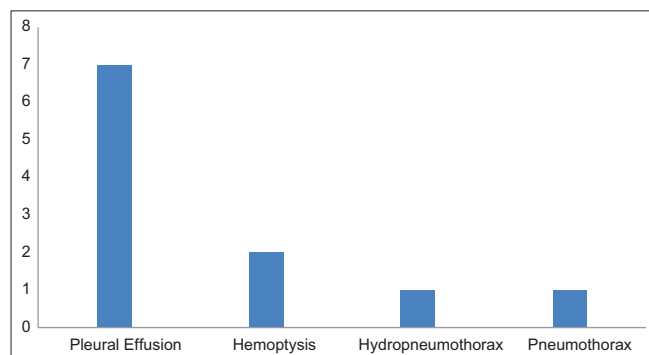


Figure 1: Presentation of paragonimiasis

Among respiratory symptoms maximum number (7 patients) were presented with unilateral pleural effusion followed by hemoptysis (2 patients). Patients also presented with complications such as hydropneumothorax and pneumothorax (1 each).

Figure 2 shows laboratory methods used to suspect and diagnose pulmonary paragonimiasis. All the eleven cases had peripheral eosinophilia and significantly higher absolute eosinophil count. In all the cases of effusion, pleural fluid eosinophil count was significantly high. Nine patients were diagnosed by a serological test for paragonimiasis. One patient had *Paragonimus* ova in sputum smear, [Figure 3] and one patient had *Paragonimus* eggs in pleural fluid.

TREATMENT AND OUTCOME

All patients received tablet Praziquantel in the dose of 25 mg/kg body weight, administered orally 3 times a day after meals for three consecutive days without any appreciable side effects and were followed up for 8–9 weeks and declared cured. Pleural fluid aspiration, intercostal chest tube drain for hydropneumothorax and pneumothorax, and symptomatic treatment were given as required.

DISCUSSION

Paragonimiasis is a zoonosis caused by adult trematode of *Paragonimus* genus. Humans are incidental hosts.^[5] *P. westermani*, *heterotremous*, and *Paragonimus skrjabini* are the principle species causing human infection in Southeast Asian countries. Of these, *P. westermani* is the most common and wide spread.^[6] In India, Manipur is

Table 1: Demographic features of cases and controls

Demographic characteristic	Values
Study population	11
Mean age in years (mean \pm SD)	38.1 \pm 16.96
Sex (male:female) (%)	05 (45.5):06 (54.5)
Hill settlers:plain settlers (%)	07 (63.6):04 (36.4)
Crab intake	11

SD: Standard deviation

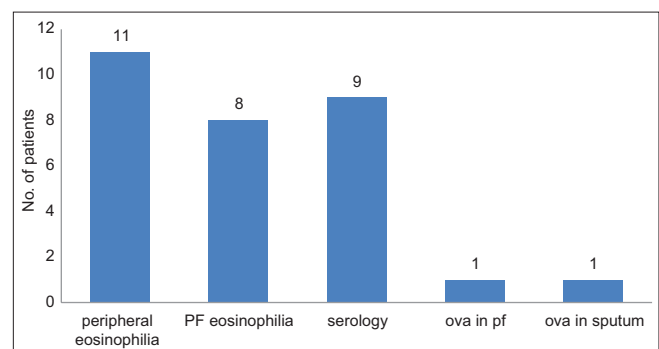


Figure 2: Laboratory methods used to diagnose pulmonary paragonimiasis

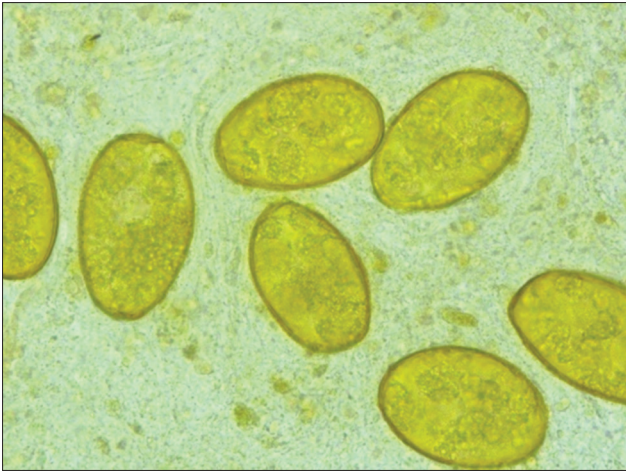


Figure 3: Eggs of *Paragonimus westermani* were found in wet mount sputum in one of the patients

one of those rare areas of the world where *Paragonimus heterotremous* is prevalent most. This species may be one of the important cause of paragonimiasis in animals and humans in Manipur.^[7]

Humans typically acquire the disease by ingesting raw or undercooked crabs or cray fish or by drinking water contaminated by them. As a result, the disease tends to occur in families because of common dietary exposure.^[8] Clinical features include cough, shortness of breath, hemoptysis, and chest pain. Radiologically, may be presented as consolidation, pleural effusion, and other nonspecific abnormalities. These pulmonary changes result from chronic inflammation in the areas surrounding the worms.^[9]

In this study, we have put in efforts to study demographic characteristics and analysis of paragonimiasis infection in Manipur. Patients from the endemic regions are presenting with chest complaints, chest X-ray changes in the form of consolidation, pleural effusion, and other nonspecific signs with eosinophilia were suspected to have paragonimiasis. It was noted that there is no much gender propensity for paragonimiasis which is contrary to a study done by Jeon *et al.*,^[10] who found pulmonary paragonimiasis is more common in males. This contrary can be explained by the fact that transmission is by ingestion of either raw or pickled^[11] crabs or cray fish and hence, both the genders are equally exposed.

In our study, the mean age of the affected population was 38.1 ± 16.96 , whereas Mukae *et al.* reported the mean age \pm SD to be 51.02 ± 12.02 .^[12] This difference may be due to more adventurous nature of local young population. We observed that prevalence was more common in patients from hilly areas than valleys which might be due to easy accessibility to fresh water crabs in streams.

Of note, three patients were erroneously treated with antitubercular drugs without any relief which is in line

with a study done in Korea.^[13] This error in diagnosis perhaps applies mostly to patients who have pleural effusion in addition to parenchymal disease. Therefore, a detailed clinical history of illness including dietary habit of consumption of crabs and laboratory investigation such as complete blood count, Absolute eosinophil count, sputum and pleural fluid examinations for eosinophils, *Paragonimus* eggs, and serodiagnosis are essentially important in all cases with respiratory symptoms in endemic areas and immigrants from endemic regions to avoid misdiagnosis.

All the study subjects had a history of crab intake and presented with respiratory symptoms such as chest pain, breathlessness, and cough with expectoration. Two patients presented with complications such as pneumothorax and hydropneumothorax, and seven patients had one sided pleural effusion. Flukes often penetrate the diaphragm and pleura; hence the pleural effusion, pneumothorax, and hydropneumothorax.^[9] A bronchial artery in the vicinity of the cyst undergoes hypertrophy and results in hemoptysis,^[8] which was observed in two patients in this study. These clinical features are similar to a study done in a tertiary referral center, Korea.^[14]

Another biologic characteristic of migrating worm infections, particularly in host tissues such as the lungs, is the association with eosinophilia in the peripheral blood and tissue,^[15] which was seen in all the study subjects and eight patients had pleural fluid eosinophilia. Nine patients were diagnosed by serological test, one patient had *Paragonimus* ova in sputum smear, and one patient had *Paragonimus* eggs in Pleural fluid. A study by Slemenda *et al.* stated if the clinical history is suspicious and eggs laden sputum cannot be demonstrated, the humoral immune response, which is considered supplementary tool, can be quantified through enzyme immunoassay^[16] and ELISA is found to be highly sensitive and specific for paragonimiasis.^[17]

Clinical features of recently diagnosed pulmonary paragonimiasis show that patients presented with a variety of clinical and radiological findings, frequently mimicking those of TB,^[18] parapneumonic effusion,^[19] and lung cancer.^[20] On the other, we need to rule out pulmonary koch, most common infection in our country and carcinoma lung which constitutes an important differential diagnosis of pulmonary paragonimiasis. Other rare cause of eosinophilia with chest symptoms includes round worm infestations,^[21] dirofilariasis,^[22] and hydatid cyst^[23] which has to be kept in mind in endemic areas.

All study subjects had excellent clinical responses to Praziquantal given at a dose of 25 mg/kg given orally 3 times daily for 3 consecutive days with improved symptoms and resolution of eosinophilia. It is in agreement with the earlier reports where cure rate is almost 100%, and very few cases with heavy infection needed a second course of treatment.^[24]

CONCLUSION

There is a need to generate awareness among the clinicians and public regarding paragonimiasis and to consider it in differential diagnosis of TB and carcinoma lung. This infestation paragonimiasis is easily avoidable. Public health education messages should warn people not to eat uncooked crab or cray fish. Physicians should consider the possibility of paragonimiasis among patients who present with chest complaints with eosinophilia from the endemic regions.

Financial support and sponsorship

Nil.

Conflicts of interest

There are no conflicts of interest.

REFERENCES

- Seaton A. Parasitic disease. In: Seaton A, Seaton D, Gordon LA, editors. *Crafton and Douglas's Respiratory Diseases*. 5th ed. France: Blackwell; 2012. p. 604-14.
- Singh YI, Singh NB, Devi SS, Singh YM, Razaque M. Pulmonary paragonimiasis in Manipur. *Indian J Chest Dis Allied Sci* 1982;24:304-6.
- Singh TN, Singh HR, Devi KS, Singh NB, Singh YI. Pulmonary paragonimiasis. *Indian J Chest Dis Allied Sci* 2004;46:225-7.
- Nutman TB. Evaluation and differential diagnosis of marked, persistent eosinophilia. *Immunol Allergy Clin North Am* 2007;27:529-49.
- McCarthy J, Nutman TB. Parasitic lung infection. In: Mason RJ, Broaddus VC, Martin TR, King TE, Schraufnagel DE, Murray JF, *et al.*, editors. *Murray and Nadel's Textbook of Respiratory Medicine*. 5th ed. Philadelphia: WB Saunders Company; 2005. p. 871-3.
- Guan XH, editor. *Paragonimiasis*. In: *Human Parasitology*. Beijing: People's Public Health Press; 2005. p. 109-13.
- Singh TS. Occurrence of the lung fluke, *Paragonimus heterotremus* in Manipur, India. *Chin Med Sci J* 2003;18:20-5.
- Fraser RS, Muller NL, Colman N, Pare PD. *Diagnosis of Diseases of Chest*. 4th ed. Philadelphia: WB Saunders Company; 1999. p. 1047-9.
- Hansel DM, Lynch DA, McAdams HP, Bankier AA. *Imaging of Diseases of the Chest*. 5th ed. Philadelphia: Mosby; 2010. p. 278-9.
- Jeon K, Koh WJ, Kim H, Kwon OJ, Kim TS, Lee KS, *et al.* Clinical Features of Recently Diagnosed Pulmonary Paragonimiasis in Korea. *Chest* 2005;128:1423-30.
- Mahmoud AA. Schistosomiasis and other trematode infections. In: Longo DL, Kasper DL, Jameson JL, Fauci AS, Hauser SL, Loscalzo J, editors. *Harrison's Principles of Internal Medicine*. 18th ed. New York: McGraw Hill; 2012. p. 1758-9.
- Mukae H, Taniguchi H, Matsumoto N, Iiboshi H, Ashitani J, Matsukura S, *et al.* Clinicoradiologic features of pleuropulmonary *Paragonimus westermani* on Kyusyu Island, Japan. *Chest* 2001;120:514-20.
- Song JU, Um SW, Koh WJ, Suh GY, Chung MP, Kim H, *et al.* Pulmonary paragonimiasis mimicking lung cancer in a tertiary referral centre in Korea. *Int J Tuberc Lung Dis* 2011;15:674-9.
- Kim HJ. Pneumothorax induced by pulmonary paragonimiasis: Two cases report. *Korean J Thorac Cardiovasc Surg* 2014;47:310-2.
- Fishman JA. Helminthic diseases of the lungs. In: Fishman AP, Elias JA, Fishman JA, Grippi MA, editors. *Fishman's Pulmonary Diseases and Disorders*. 14th ed. Philadelphia: McGraw Hill; 2008. p. 2425.
- Slemenda SB, Maddison SE, Jong EC, Moore DD. Diagnosis of paragonimiasis by immunoblot. *Am J Trop Med Hyg* 1988;39:469-71.
- Singh TS, Sugiyama H, Rangsiruji A. Paragonimus and paragonimiasis in India. *Indian J Med Res* 2012;136:192-204.
- Behera D. Parasitic lung diseases. In: Gupta ML, Sharma SR, Singh S, Behera D, editors. *NCCP Text Book of Respiratory Medicine*. 1st ed. New Delhi: Jaypee Brothers Medical Publishers; 2011. p. 165.
- Hwang KE, Song HY, Jung JW, Oh SJ, Yoon KH, Park DS, *et al.* Pleural fluid characteristics of pleuropulmonary paragonimiasis masquerading as pleural tuberculosis. *Korean J Intern Med* 2015;30:56-61.
- Tomita M, Matsuzaki Y, Nawa Y, Onitsuka T. Pulmonary paragonimiasis referred to the department of surgery. *Ann Thorac Cardiovasc Surg* 2000;6:295-8.
- Siddiqui AA, Berk SL. Diagnosis of *Strongyloides stercoralis* infection. *Clin Infect Dis* 2001;33:1040-7.
- Oshiro Y, Murayama S, Sunagawa U, Nakamoto A, Owan I, Kuba M, *et al.* Pulmonary dirofilariasis: Computed tomography findings and correlation with pathologic features. *J Comput Assist Tomogr* 2004;28:796-800.
- Gottstein B, Reichen J. Hydatid lung disease. In: Sharma OP, editor. *Lung Biology in Health and Disease: Tropical Lung Disease*. 2nd ed. New York: Taylor and Francis Group; 2006. p. 327-50.
- Keiser J, Utzinger J. Chemotherapy for major food-borne trematodes: A review. *Expert Opin Pharmacother* 2004;5:1711-26.