



Case report

COVID-19 acute respiratory distress syndrome: can iloprost have a role for the treatment?

Alida Filippini^{a,*}, Claudio Bnà^b, Raffaello Bellosta^c, Roberto Bazzani^a, Luca Luzzani^c, Matteo Alberto Pegorer^c, Matteo Zandalasini^d, Michela Baldon^d, Manuela Codazzi^e, Tony Sabatini^a

^a Department of Internal Medicine, Gastroenterology and Endoscopy. Poliambulanza Hospital Clinical Institute, Via Bissolati 57, 25124 Brescia, Italy

^b Department of Radiology. Poliambulanza Hospital Clinical Institute, Via Bissolati 57, 25124 Brescia, Italy

^c Department of Vascular Surgery. Poliambulanza Hospital Clinical Institute, Via Bissolati 57, 25124 Brescia, Italy

^d Department of Specialistic Rehabilitation. Poliambulanza Hospital Clinical Institute, Via Bissolati 57, 25124 Brescia, Italy

^e Department of Gastroenterology and Endoscopy. Poliambulanza Hospital Clinical Institute, Via Bissolati 57, 25124 Brescia, Italy



ARTICLE INFO

Keywords:

Iloprost

ARDS

COVID-19 infection

ABSTRACT

Pulmonary infection of 2019-nCoV can frequently induce acute respiratory distress syndrome (ARDS) with partial pressure of arterial oxygen/fraction of inspired oxygen ratio (pO₂/FiO₂) of less than 300 mmHg. Moreover, it can be complicated with cardiac injury or arrhythmia, microvascular and large-vessel thrombosis. We describe a case of a patient with COVID19-ARDS and concomitant critical ischemia of the limbs. Iloprost treatment, an analogue of a prostacyclin PGI₂, was started for residual left forefoot ischemia after surgical thromboembolectomy. Unexpectedly, we documented improvement of respiratory performance and lung high resolution computed tomography (HRCT) showed significant regression of the diffuse pulmonary ground-glass opacity. The hypothetical mechanism is that iloprost can enhance perfusion preferentially to well-ventilated lung regions, reduce pressures of peripheral pulmonary vessels and induce reduction of lung interstitial edema. In addition, iloprost antithrombotic effect, endothelial damage repairing and neo-angiogenesis activity could play a relevant role.

1. Introduction

Novel coronavirus 2019-nCoV infection cases are confirmed in multiple countries and can frequently induce severe acute respiratory syndrome with partial pressure of arterial oxygen/fraction of inspired oxygen ratio (pO₂/FiO₂) of less than 150 mmHg [1].

The chest Computer Tomography showed bilateral lung infiltrates with rapidly involving of more than 75% of the pulmonary parenchyma and are due to acute inflammation of pulmonary tissue and alveolar space. COVID-19 infection is frequently complicated with pulmonary embolism, arterial ischemia and venous thrombosis of limbs and myocarditis or arrhythmia. Some clinical study documented improvement of gas exchange in ARDS with inhaled iloprost [2–5].

This report describes the use of iloprost in the treatment of a patient with bilateral critical tibial arteries ischemia and COVID-19 ARDS, and

unexpectedly improvement of pulmonary performance.

1.1. Case report

A 66 years old caucasian male presented to our Emergency Department for bilateral lower limbs pain, numbness and cyanosis of left foot. Moreover the patient was complaining cough, fever and dyspnea for the last two weeks. Past medical history was silent. He did not smoke tobacco or use alcohol. The patient was in severe respiratory distress and vital signs were: temperature 38.6 °C, blood pressure 104/64 mm Hg, pulse 103 bpm, respiratory rate 30 breaths per minute and oxygen pulse oximetry 84% on room air. Lung examination revealed bilateral basal crackles. The arterial blood gas showed pH 7.48, pCO₂ 24 mmHg and pO₂ 53 mmHg, PaO₂/FiO₂ 250 mmHg, lactate 8.3 mmol/l.

Oxygen-therapy with Boussignac continuous positive airway

Abbreviations: ARDS, acute respiratory distress syndrome; pO₂, partial pressure of arterial oxygen; FiO₂, fraction of inspired oxygen; PEEP, positive end expiratory pressure; HRCT, high resolution computed tomography; SpO₂, oxygen peripheral saturation.

* Corresponding author.

E-mail address: alida.filippini@poliambulanza.it (A. Filippini).

<https://doi.org/10.1016/j.rmcr.2021.101358>

Received 19 December 2020; Received in revised form 6 January 2021; Accepted 27 January 2021

Available online 30 January 2021

2213-0071/© 2021 The Authors.

Published by Elsevier Ltd.

This is an open access article under the CC BY-NC-ND license

(<http://creativecommons.org/licenses/by-nc-nd/4.0/>).

pressure (BCPAP) was started, with PEEP of 10 cm/H₂O, FiO₂ 80%. Blood cell count, coagulation, hepatic and renal function tests were normal. Other blood tests showed elevated level of ferritin (860 µg/L), LDH (657 U/L), C-reactive protein (140 mg/L), D-dimer (>20000 ng/ml) and IL6 (36.5 pg/ml). Nasopharyngeal 2019-nCoV swab test by real-time reverse-transcriptase-polymerase-chain-reaction resulted positive.

Chest X-ray showed diffuse and bilateral interstitial opacity and infiltrates, suggestive for viral pneumonia, without mediastinal enlargement and pleural effusion.

CT pulmonary angiography (CPTA) scan was performed and excluded pulmonary embolism, the presence of thrombi in left atrium and in left auricle and a significant aortic atheromasia. The HRCT reconstructions images also confirmed multifocal, bilateral ground-glass opacity (predominant pattern), interlobular septal thickening and bilateral infiltrates, involving 50–75% of the lung parenchyma, without adenopathy and pleural effusion (Fig. 1 a-b).

A Echo-Doppler scan demonstrated occlusion of bilateral tibio-peroneal trunk and distal segment of anterior tibial artery.

The patient underwent surgical thromboembolectomy of both femoro-popliteal-tibial axis and finally angiography showed bilateral patency of femoro-popliteal posterior arteries but persistent thrombosis of left anterior tibial. Was given therapy with unfractionated heparin (APTT-ratio target 2.5 assay) and ceftriaxone 2 g/daily. Anti-Thrombin-III test, homocysteine level and antiphospholipid antibodies titers were normal.

Autoimmunity tests including antinuclear antibody test, anti-neutrophil cytoplasmic antibody, complement C3 –C4, were negative. Anatomopathological thrombus report described nonspecific inflammatory cells.

Transthoracic echocardiography documented: mild hypertrophy of the left ventricle with normal ejection fraction 70%, PAPs 22 mmHg, estimated PVC 3 mmHg, no significant valve disease.

On hospital day 3, for worsening of saturation values, was started supplemental oxygen to the continuous positive airway pressure system (helmet-CPAP) with PEEP 12 cm/H₂O, FIO₂ 60%, and oxygen pulse oximetry rised to 90%. The chest x-ray showed an increase in interstitial opacity and lung infiltrates. On clinical chest examination were present crackling rales up to the apical level.

He had absent pedal pulses on both sides, and a mild sensory loss on the left side, with cyanosis of the left foot and necrosis of the third and fourth toes, which corresponded to the grade of Rutherford class 5.

Therefore iloprost treatment was started at a dose of 50 mcg/daily by 0,5 ng/kg/min up to 2 ng/kg/min and warfarin (INR range 2–3).

The day after, SpO₂ rised to 99% and oxygen supplementation was switch to Venturi-mask FiO₂ 60% at 15 L/min, and after the iloprost infusion, FiO₂ was progressively reduced to 28% at 4 L/m. Blood-gas control documented PO₂/FiO₂ 266 mmHg. At the third day of treatment the bilateral lower-lobe rales were no longer present. The oxygen therapy was switched to nasal cannulas 2 L/min and then was

discontinued. Blood gas test showed pH 7.47, pCO₂ 41 mmHg and pO₂ 62 mmHg, sO₂ 94% PaO₂/FiO₂ 295 mmHg, lactate 1.5 mmol/l. There was a reduction value of PCR (28.5 mg/L), LDH (317 U per liter), D-dimer (1180 ng/ml), IL6 (13.7 pg/ml).

A control chest-HRCT showed a significant regression of the diffuse ground-glass with higher percentage of areated areas, and some bilateral consolidation with air-bronchogram and bronchiolectasis, more represented in peripheral areas of the lungs (Fig. 2 a-b).

Iloprost was continued for the critical ischemia, and after seven infusion remained slight cyanosis of the left foot.

2. Discussion

ARDS is frequently the clinical presentation of COVID-19 pneumonia infection. In our case, the patient showed the acute onset of respiratory failure, bilateral infiltrates on chest radiograph and CT, hypoxemia with PaO₂/FiO₂ ratio ≤200 mmHg. Clinical trials have focused on the role of ventilation strategies as invasive or noninvasive ventilation devices and prone positioning [1,6], surfactant [7], nitric oxide [8], antiviral, corticosteroids and antibiotic therapy. It's known that the immune response plays a profound role in COVID-19 infection and development of ARDS. The initial inflammatory alveolar process is induced by the binding of microbial products or cell injury-associated endogenous molecules to pattern recognition receptors. Alveolar macrophage and neutrophil extracellular traps are activated, leukocytes and erythrocytes are recruited in the sites of injury and partake in the production of bioactive mediators including protease, phospholipids, eicosanoids and proinflammatory-regulated cytokines that increase the inflammatory burden within the lung [6–8]. Increased permeability of the microvascular barrier results in the extravascular accumulation of protein-rich edema fluid into the alveolar space and, subsequently, hypoxemia due to impaired gas exchange.

Lungs autopsy of patient with COVID-19 infection revealed diffuse alveolar damage, hemorrhage and histiocytic desquamation, hyaline membrane development, interstitial edema and fibrin with alveolar macrophages accumulation and thrombi occluding small lung vessels [9].

In our case we used iloprost for the treatment of residual critical ischemia of limb and after the first infusion we documented improvement of respiratory performance. Iloprost is an analogue of epoprostenol, a prostacilin (PGI₂), mainly produced in the vascular endothelium, with numerous properties as inhibition of platelet aggregation, vasodilatation, antiinflammatory and protective effects on endothelial barrier dysfunction [10,11]. Iloprost is used in Buerger's disease, in forms of peripheral ischemia and Raynaud's phenomenon and for pulmonary arterial hypertension. In animal models, iloprost improves endothelial barrier function and reduces the signs of pulmonary edema, and the sequestration of leukocytes and platelets [10–12]. PGI₂ has been shown to have anti-inflammatory functions attributed to the cyclooxygenase-2

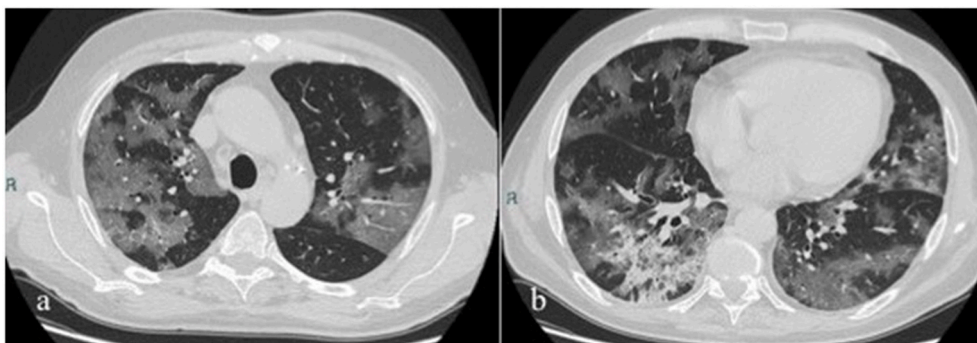


Fig. 1. a–b. HRCT chest images of patient with COVID-19 ARDS. The HRCT chest images shown multifocal, bilateral ground-glass opacity, interlobular septal thickening and bilateral infiltrates, involving 50–75% of the lung parenchyma, without adenopathy and pleural effusion.

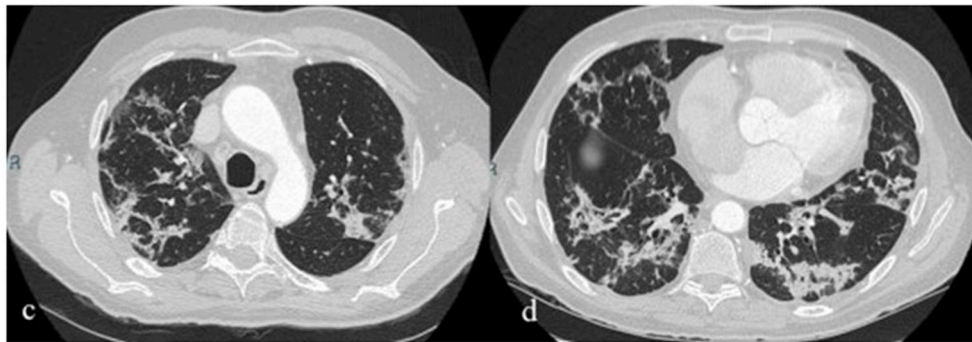


Fig. 2. c–d: HRC of the chest after three days of iloprost treatment. Control HRC of the chest show a significant regression of the diffuse ground-glass with higher percentage of aerated areas, and some bilateral consolidation with air-bronchogram and bronchiolectasis, more represented in peripheral areas of the lungs.

(COX-2) system [13–15] and the involvement of lipoxin A4 [16] and Ras-related protein 1 (RAP-1) [17]. The infusion of iloprost, in patients with systemic sclerosis reduces T cells in the peripheral blood, especially TNF α producing T cells, and some studies documented that iloprost reduces TNF α transcriptional activity and decreases TNF α mRNA stability so that it reduces both the amount of TNF α positive T cells and the secretion TNF α after an antigenic stimulus [18–20].

Yuanjue Z et al. showed in animal models that a single dose of iloprost prior to bleomycin injection significantly resulted in attenuated infiltration of inflammatory cells into the lung, reduced collagen deposition in pulmonary interstitium, a decreased production of pro-inflammatory and fibrotic cytokines such as TNF α , IL-6, and an increased release of antifibrotic mediators including IFN γ and chemokine CXCL10/IP-10 [21,22].

An application of inhaled iloprost is noted in the guidelines of the Association of the Scientific Medical Societies for the treatment of ARDS, and in inhalation injury-ARDS appears safe and was associated with a statistically significant improvement in oxygenation [2–5]. These effects could be due to the enhanced perfusion preferentially to well-ventilated lung regions with reduction of pulmonary pressures in peripheral vessels and interstitial inflammatory edema. Some limits of nebulized use are the compliance of patient and the determination of iloprost serum levels.

Moreover, the iloprost antithrombotic effect, endothelial damage repairing and neoangiogenic activity [2–5,11] could play a role in the thrombotic events COVID-19 correlated.

3. Conclusion

ARDS is the principal cause of death in COVID-19 infection and iloprost should be considered an additional treatment to mechanical ventilation. Additional studies are necessary to determine how inhaled or intravenous iloprost could improve pulmonary performance.

Conflict of interest disclosures

None reported.

Additional contributions

We have obtained [informed consent](#) from patient for the procedure and for their medical data to be used in a study.

Acknowledgments

Author's contributions F.A., B.C. and S.T. had full access to all the data in the study and takes responsibility for the integrity of the data and the accuracy of the data. F.A., B.R., L.L. participated in study conception. F.A., B.C., B.R., C.M., Z.M., B.R., P.M.A., B.M., L.L., performed data analysis and drafted and revised the paper. All authors approved the

final draft of the manuscript for publication.

References

- [1] M.A. Matthay, L.B. Ware, G.A. Zimmerman, The acute respiratory distress syndrome, *J. Clin. Invest.* 122 (8) (2012) 2731–2740.
- [2] H. Haerberle, S. Prohaska, P. Martus, et al., Therapeutic iloprost for the treatment of acute respiratory distress syndrome (ARDS) (th Thlo trial): a prospective, randomized, multicenter phase II study, *Trials* 21 (2020) 242.
- [3] A.S. Newsome, S. Sultana, B. Murray, et al., Effect of inhaled iloprost on gas exchange in inhalation injury, *Burns Open* 1 (Issue 2) (October 2017) 49–53.
- [4] A. Afshari, A. Bastholm Bille, M. Allingstrup, Aerosolized prostacyclins for acute respiratory distress syndrome (ARDS), *Cochrane Database Syst. Rev.* 7 (2017) CD007733.
- [5] E. Sawheny, A.L. Ellis, G.T. Kinasewitz, Iloprost improves gas exchange in patients with pulmonary hypertension and ARDS, *Chest* 144 (1) (2013) 55–62.
- [6] L. Gattinoni, E. Carlesso, P. Taccone, et al., Prone positioning improves survival in severe ARDS: a pathophysiologic review and individual patient meta-analysis, *Minerva Anestesiol.* 76 (6) (2010) 448–454.
- [7] A. Anzueto, R.P. Baughman, K.K. Guntupalli, et al., Aerosolized surfactant in adults with sepsis-induced acute respiratory distress syndrome. Exosurf acute respiratory distress syndrome sepsis study group, *N. Engl. J. Med.* 334 (1996) 1417–1421.
- [8] R.P. Dellinger, J.L. Zimmerman, R.W. Taylor, et al., Inhaled Nitric Oxide in ARDS Study Group. Effects of inhaled nitric oxide in patients with acute respiratory distress syndrome: results of a randomized phase II trial, *Crit. Care Med.* 26 (1998) 15–23.
- [9] L. Carsana, A. Sonzogni, A. Nasr, R.S. Rossi, et al., Pulmonary post-mortem findings in a series of COVID-19 cases from northern Italy: a two-centre descriptive study, *The Lancet Infectious disease* 20 (10) (2020) 1135–1140.
- [10] P. D'Amelio, Cristofaro Ma, L. D'Amico, et al., Iloprost modulates the immune response in systemic sclerosis, *BMC Immunol.* 11 (2010) 62.
- [11] A.A. Birukova, T. Wu, Y. Tian, et al., Iloprost improves endothelial barrier function in lipopolysaccharide-induced lung injury, *Eur. Respir. J.* 41 (1) (2013) 165–176.
- [12] C. Malmros, S. Blomquist, L. Martensson, et al., Iloprost attenuates trauma-related pulmonary sequestration of leucocytes and platelets, *Prostaglandins Leukot. Essent. Fatty Acids* 50 (4) (1994) 203–210.
- [13] W. Zhou, K. Hashimoto, K. Goleniewska, et al., Prostaglandin I2 analogs inhibit proinflammatory cytokine production and T cell stimulatory function of dendritic cells, *J. Immunol.* 178 (2007) 702–710.
- [14] K. Hashimoto, B.S. Graham, M.W. Geraci, et al., Signaling through the prostaglandin I2 receptor IP protects against respiratory syncytial virus-induced illness, *J. Virol.* 78 (2004) 10303–10309.
- [15] K. Nagao, H. Tanaka, M. Komai, et al., Role of prostaglandin I2 in airway remodeling induced by repeated allergen challenge in mice, *Am. J. Respir. Cell Mol. Biol.* 29 (2003) 314–320.
- [16] M. Scully, C. Gang, C. Condrion, et al., Protective role of cyclooxygenase (COX)-2 in experimental lung injury: evidence of a lipoxin A4-mediated effect, *J. Surg. Res.* 175 (1) (2012) 176–184.
- [17] A.A. Birukova, P. Fu, J. Xing, et al., Rap1 mediates protective effects of iloprost against ventilator-induced lung injury, *J. Appl. Physiol.* 107 (6) (1985) 1900–1910, 2009.
- [18] A. Jorres, H. Dinter, N. Topley, et al., Inhibition of tumour necrosis factor production in endotoxin-stimulated human mononuclear leukocytes by the prostacyclin analogue iloprost: cellular mechanisms, *Cytokine* 9 (1997) 119–125.
- [19] W. Zhou, K. Hashimoto, K. Goleniewska, et al., Prostaglandin I2 analogs inhibit proinflammatory cytokine production and T cell stimulatory function of dendritic cells, *J. Immunol.* 178 (2007) 702–710.

- [20] G. Murdaca, B.M. Colombo, F. Puppo, Anti-TNF-alpha inhibitors: a new therapeutic approach for inflammatory immune-mediated diseases: an update upon efficacy and adverse events, *Int. J. Immunopathol. Pharmacol.* 22 (2009) 557–565.
- [21] T. Kohyama, X. Liu, H.J. Kim, et al., Prostacyclin analogs inhibit fibroblast migration, *Am. J. Physiol.* 283 (2) (2002) L428–L432.
- [22] Yuanjue Zhu, Yong Liu, Weixun Zhou, et al., A prostacyclin analogue, iloprost, protects from bleomycin-induced pulmonary fibrosis in mice, *Respir. Res.* 11 (2010) 34.