



## CASE REPORT

# Rapid and Severe Idiopathic Aseptic Necrosis of the Contralateral Femoral Head after Unilateral Total Hip Arthroplasty

Qihang Su, PhD , Yi Zhang, MD, Yuanzhen Zhang, MD, Bin'an Zhao, MD, Heng'an Ge, PhD, Peng Wu, MD, PhD, Jun Li, PhD, Biao Cheng, MD, PhD 

*Department of Orthopedics, Shanghai Tenth People's Hospital, School of Medicine, Tongji University, Shanghai, China*

**Background:** Osteonecrosis of the femoral head (ONFH) is a multifactorial disease, and agnogenic ONFH, otherwise known as idiopathic ONFH, is rare in clinic. Idiopathic ONFH that exhibits severe necrosis and progresses extremely rapidly is called rapidly destructive hip disease (RDHD). RDHD greatly affects patients but is rarely reported in clinical practice and literature.

**Case Presentation:** In this study, a 64-year-old male patient with complete collapse and necrosis of the right femoral head complicated with severe bone destruction at 10 months after left total hip arthroplasty (THA) was reported. The period from the intact structure of the right femoral head to the first discovery of its complete collapse, according to imaging results, was 7 months. The duration from the occurrence of symptoms in the right hip joint to the first discovery of complete collapse and necrosis of the femoral head was only 5 months. At present, the cause has not been determined based on medical history, symptoms, signs, imaging evaluation results, laboratory examination results, and pathological examination results, though it has been identified as severe idiopathic aseptic necrosis of the femoral head with rapid progression, or RDHD. Finally, right THA was performed, and a good outcome was observed in the patient at present.

**Conclusions:** As a rare hip joint disease, RDHD greatly influences the normal life of patients. RDHD of the contralateral side after unilateral THA is even scarcer. Left THA may be one of the important factors accelerating the necrosis of the right femoral head. Hopefully, with this case report, more attention will be paid to the contralateral hip joint in patients undergoing unilateral THA by clinicians and rehabilitation physicians, and a clinical reference will be provided for the research on RDHD.

**Key words:** Osteonecrosis of the femoral head; Radiological features; Rapidly destructive hip disease; Total hip arthroplasty

## Introduction

Osteonecrosis of the femoral head (ONFH), a nonspecific disease resulting from various factors,<sup>1</sup> may lead to pain, obstructed hip joint movement, and even astasia in patients, eventually requiring total hip arthroplasty (THA).<sup>2</sup> ONFH is caused by a variety of factors, including trauma, destruction of blood supply, hormones, alcohols, drugs,

osteoporosis, and destruction of tumors or microorganisms (including bacteria and Mycobacterium tuberculosis).<sup>3</sup> The most common ONFH is degenerative aseptic ONFH in elderly patients.<sup>4</sup> In most cases, however, ONFH will not subside spontaneously, but will eventually progress to advanced collapse of the femoral head, severely affecting the normal life and even endangering lives of patients.<sup>5</sup> For this

**Address for correspondence** Peng Wu, MD, PhD, Jun Li, PhD and Biao Cheng, MD, PhD, Department of Orthopedics, Shanghai Tenth People's Hospital, School of Medicine, Tongji University, No.301 Yanchang Middle Road, Shanghai 200072, China, Tel: +8615618337279 (P. W.), +8615221957706 (J. L.) and +8613681973702 (B. C.); Fax: 021-65982875 (B. C.); Email: [dr\\_wupengtj@163.com](mailto:dr_wupengtj@163.com) (P. W.), Email: [lijunspine@163.com](mailto:lijunspine@163.com) (J. L.) Email: [dr\\_chengbiao@163.com](mailto:dr_chengbiao@163.com) (B. C.)

Qihang Su, Yi Zhang and Yuanzhen Zhang contributed equally to this work.

Received 10 January 2022; accepted 10 April 2022

reason, hip replacement is one of the most effective approaches commonly used for ONFH in elderly patients.<sup>6</sup>

In most cases, a long-term inducing factor triggers the evolution of degenerative or hormone and drug-induced ONFH from the early to advanced stage, including advanced age, long-term heavy weight-bearing, long-term alcohol abuse, and medical history like long-term use of hormones.<sup>7,8</sup> Clinically, the rapid progression of ONFH in patients is mostly caused by factors such as trauma, tumor, or infection.<sup>9,10</sup> The literature indicates that agnogenic ONFH can be found in some patients, sometimes called idiopathic ONFH.<sup>11–14</sup> In this study, a case of idiopathic aseptic necrosis of the right femoral head after left THA was reported. Interestingly, the patient suffered severe necrosis and collapse of the right femoral head, with almost disappeared normal structure of the femoral head and extremely rapid progression after receiving left THA due to aseptic ONFH. The period before the collapse of the right femoral head to the first discovery of its complete collapse was 7 months according to imaging results, while that from the occurrence of symptoms (pain and limitation of motion) in the right hip joint to the first discovery of the complete collapse and necrosis the femoral head on images was only 5 months. The cause was not determined based on preoperative, intraoperative, and postoperative examinations results, so it was diagnosed as idiopathic aseptic ONFH. This case was the severest idiopathic ONFH with the most rapid progression encountered by our clinical team, and also the first case of rapidly destructive hip disease (RDHD) discovered by our team.<sup>15</sup> RDHD is defined as a greater than 2 mm/year rate of joint space narrowing, i.e. loss of more than 50% of the joint space within 1 year.<sup>15</sup> By reporting this case, we hope that clinicians will place more emphasis on the progression of the contralateral ONFH after unilateral THA, thus perfecting the preoperative and postoperative evaluations, rehabilitation guidance, and early interventions. In addition, this case report offers a clinical reference for researchers to investigate the biomechanical changes of the hip joint after unilateral or bilateral THA.

## Case Report

### Left THA

In November of 2020, a 64-year-old male patient with a body mass index (BMI) of 25.06 kg/m<sup>2</sup> was admitted to the hospital due to having experienced pain in the left hip joint and limitation of motion for over 4 months. The patient developed pain without obvious causes in the left hip joint that obstructed bending and flexion of the hip joint and received no treatment. The pain was not severe at that time, but symptoms worsened when walking and navigating stairs. Subsequently, the symptoms of pain, obstructed bending, and flexion of the hip joint were gradually aggravated, without obvious left lower limb numbness or short deformity. The X-ray conventional radiograph (CR) of the left hip joint suggested degenerative changes in the left hip joint and

flattened left femoral head. Conservative treatment was not working. According to physical examination results, there was mild claudication, pain when moving the left hip, no obvious swelling, 0°–80° flexion, 0°–20° abduction, obviously restricted internal rotation, and no obvious deformity in the left lower limb. Additionally, no obvious abnormality was found in the right lower limb. The diagnosis was aseptic necrosis of the left femoral head. After completing the preoperative assessment, conventional left THA was conducted smoothly, and the patient was discharged from the hospital following the recovery period.

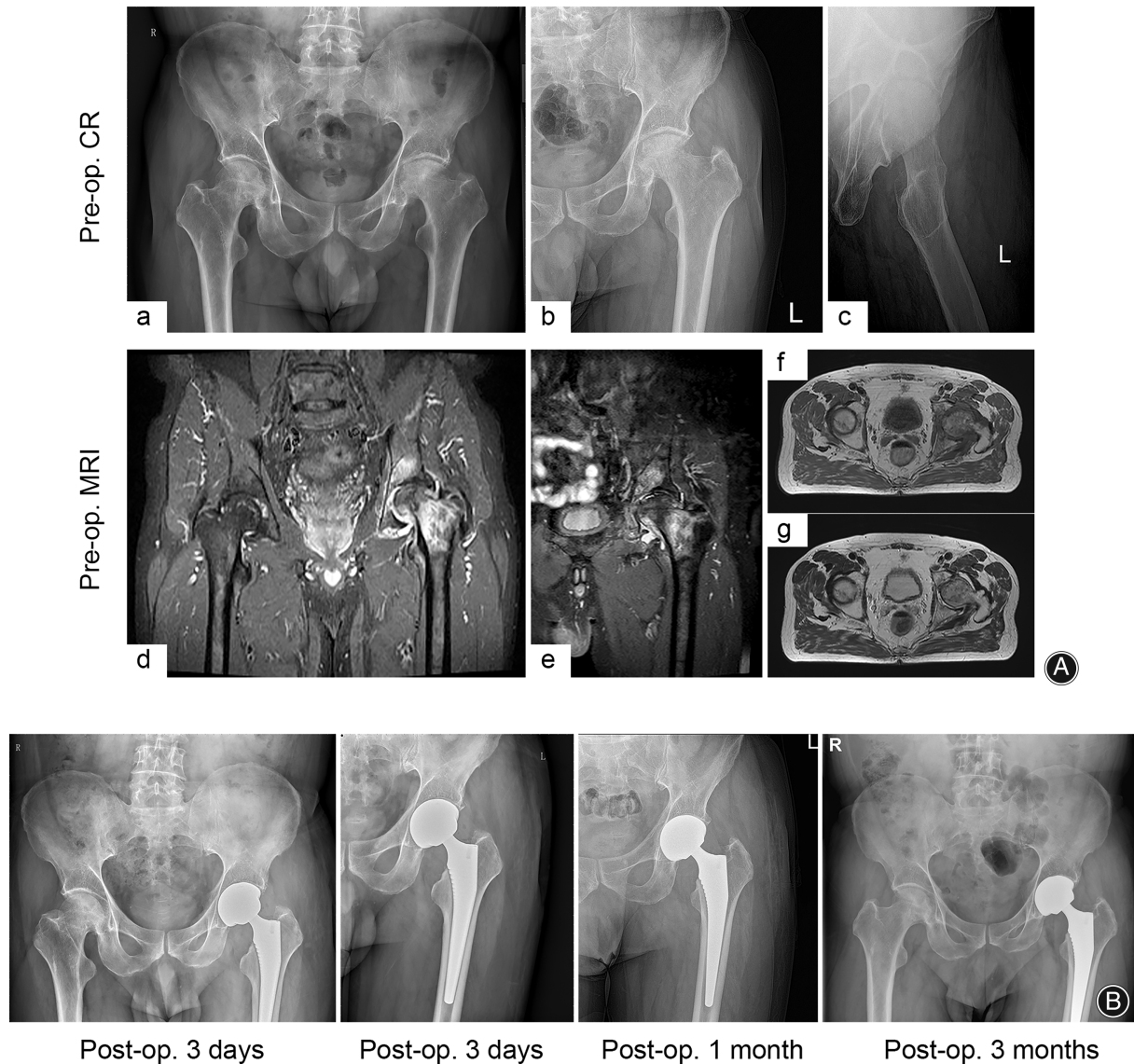
CR and magnetic resonance imaging (MRI) results of his bilateral hip joints before THA are shown in Figure 1A. It was observed that the left femoral head was flattened, with rough and uneven articular surface. In addition, irregular spot-like and linear low-intensity foci were observed in the bone under the articular surface, along with edema in the left femoral neck and the intertrochanteric bone marrow, obvious bone hyperplasia at the upper edge of the left acetabulum, typical degenerative changes in the left hip joint, and signs of aseptic necrosis of the left femoral head. There were no obvious signs of degenerative changes in the right femoral head. The CR of the left hip (Figure 1B) demonstrated that at 3 days, 1 and 3 months after left THA, the left hip prosthesis was staying in a good position, and no obvious abnormalities like bone destruction and secondary fracture were found.

### Progression of Right Hip Joint Disease

The patient reported that after 5 months post-left THA, there were pains without obvious causes in the right hip joint, which became worse during activities and was relieved after rest, and slightly obstructed bending and flexion of the hip joint, with mild claudication. He received conservative treatment on his own and did not see a doctor. The symptoms of right hip joint pain and limitation of motion gradually worsened.

At nearly 10 months after left THA, the patient was hospitalized again due to walking difficulties and astasia. Physical examination results indicated movement-related pain, slight swelling, obvious tenderness in the right hip joint, limited joint motion, short and external rotation deformities, and intact sensation in the distal right lower limb. The sensation of the left lower limb was normal after THA. The patient denied any history of trauma, diabetes, tumors, venereal diseases, tuberculosis, long-term hormone use, and long-term alcoholism.

The CR of the right hip showed structure defects in the right femoral head, acceptable morphology of the femoral neck and proximal bone, multiple bone dense shadows in fossa acetabuli, an upward shifted right femur, and swollen surrounding soft tissues (Figure 2A). According to the results of computed tomography (CT) and MRI of the right hip (Figure 2B,C), most of the right femoral head had bone loss and destruction, with residual spots of bone signal shadow, while the articular surface was not evident from the image.

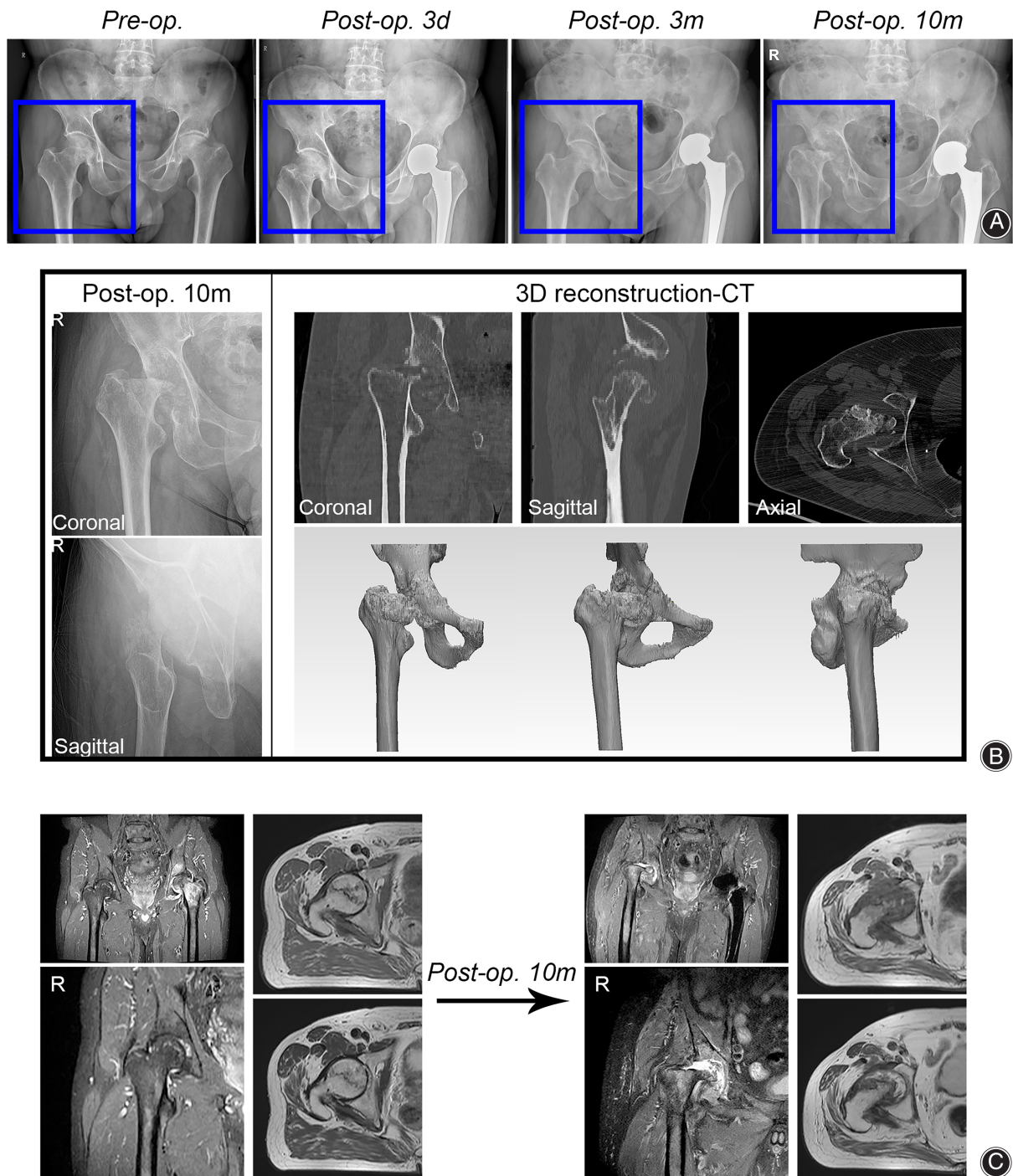


**Fig. 1** Imaging results before and after left THA. (A) Conventional X-ray CR and MRI images of the left hip joint before left THA: there were degenerative changes in the left hip joint, necrosis of the left femoral head, rough articular surface, uneven surface, and edema in the left femoral neck and the femoral intertrochanteric bone marrow, as well as unclear signs of degeneration of the right femoral head. (B) Conventional X-ray CR images of the left femoral head reexamined at 3 days, 1 and 3 months after left THA: the position of hip prosthesis was satisfactory, and there were no obvious signs of abnormal complications. (a) CR images of the pelvic before surgery, (b) antero-posterior CR images of the left hip joint before surgery, (c) lateral CR images of the left hip joint before surgery, (d) MRI images of the pelvic before surgery, (e) antero-posterior MRI images of the left hip joint before surgery, (f) axial MRI-T1 image of the left hip joint before surgery, and (g) axial MRI-T2 image of the left hip joint before surgery

Bone loss and destruction were found in the partial acetabular articular surface cortex and subcortical bone, and there were massive irregular bone fragments in the joint area, with unclear edges and disappearances of joint space.

No obvious abnormalities were detected in preoperative routine blood tests (Table 1). The patient's tumor index (blood) results revealed that CA153 (35.60 U/mL, normal value: <26.4 U/mL), cytokeratin-19-fragment (4.76 ng/mL,

normal value: <3.3 ng/mL), and neuron-specific enolase (21.20 ng/mL, normal value: <16.3 ng/mL) levels were slightly elevated. However, his whole-body single-photon emission computed tomography (SPECT)/CT showed no clear signs of malignancy or necrosis of the right femoral head (Figure 3). Moreover, no obvious abnormalities were found in chest CT and color Doppler ultrasound (liver, gallbladder, pancreas, spleen, and kidney). Hence, these abnormal tumor indicators



**Fig. 2** Changes in images of the right hip joint after left THA. (A) Conventional X-ray CR images of the pelvis before and at 3 days, 3 and 10 months after left THA: the mild degeneration of the right femoral head progressed into complete necrosis and collapse within 7 months. (B) CT three-dimensional reconstruction images of the right hip joint: the normal structure of the right femoral head completely disappeared (at 10 months after left THA). (C) MRI images of the right hip joint: most of the right femoral head had bone destruction and loss, bone destruction in the femoral neck and upward displaced proximal femur were observed, and the normal structure of the joint disappeared (at 10 months after left THA)

**TABLE 1 Preoperative routine blood tests**

Indicators	Value	Normal value
Erythrocyte sedimentation rate (mm/h)	13.00	0.00–15.00
International normalized ratio	0.79	0.80–1.30
Albumin (g/L)	41.50	40.00–55.00
Hemoglobin (g/L)	149.00	130.00–175.00
Blood platelet ( $10^9/L$ )	272.00	125.00–350.00
White blood cell ( $10^9/L$ )	5.22	3.50–9.50
Red blood cell ( $10^{12}/L$ )	4.61	4.30–5.80
Monocyte ( $10^9/L$ )	0.86	1.10–3.20
Monocyte ratio (%)	9.00	3.00–10.00
Lymphocyte ( $10^9/L$ )	0.47	0.10–0.60
Lymphocyte ratio (%)	16.50	20.00–50.00
Neutrophil ( $10^9/L$ )	3.85	1.80–6.30
Neutrophil ratio (%)	73.70	40.00–75.00

had little reference value at present. The patient also had negative blood tuberculosis antibodies, a negative result in the tuberculosis infection T cell spot test (T-SPOT), and no obvious abnormalities in blood calcium, blood phosphorus, blood alkaline phosphatase, urine phosphorus, vitamin D, vitamin D2, and vitamin D3 tests.

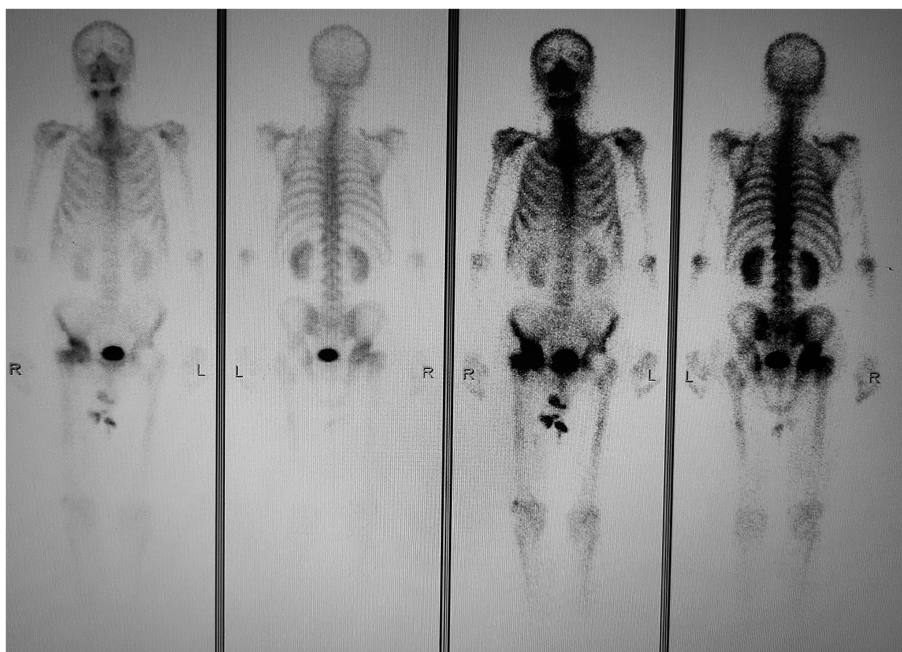Conventional right THA was conducted after completing relevant preoperative evaluations. It was discovered during surgery that there were structural defects in the femoral head, irregular femoral head tissues, multiple small bone fragments, and a hyperplastic acetabular rim. However, the acetabular bottom remained intact with acceptable bone hardness and no obvious signs of infection or tumor tissue hyperplasia in the joint cavity. The hip joint prosthesis was implanted successfully with routine procedure.

The CR results of the right hip joint at the first day and 1 month after the operation showed that the position of hip prosthesis was satisfactory, and that there were no abnormal signs such as secondary fractures or further bone destruction (Figure 4A). The full-length CR films of both lower limbs showed that both lower limbs almost had the same length, with good position of line of gravity of lower limbs (Figure 4B). Intraoperatively, we took the right femoral head tissue and joint fluid for bacterial, fungal, and tuberculosis culture tests and the results were negative.

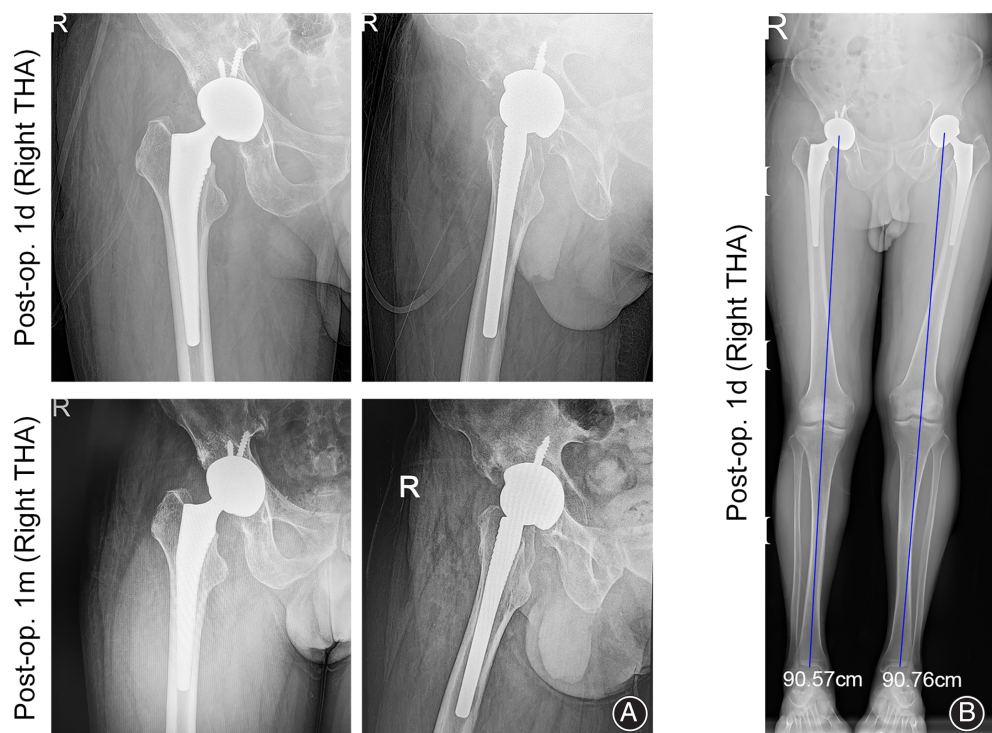
According to hematoxylin–eosin (HE) staining results for paraffin slices of the right femoral head tissues, the articular cartilage was almost completely gone, and the surface was rough and damaged, with extensive fibrovascular tissue proliferation and reactive bone formation (Figure 5A). Massive trabecular bones were also destroyed (Figure 5B). The immunohistochemical results (Figure 5C) suggested ck-p (–), s100 (–), h3f3a (–), h3f3b (–), kp1 (+), satb2 (small amount+), p63 (–), and ki-67 (20%+).

### Discussion

Generally, it is believed that ONFH will gradually deteriorate naturally if no intervention is taken.<sup>16,17</sup> Some studies have reported that if no intervention is taken after the first discovery of ONFH signs, some cases of ONFH have improved, and some have neither progression nor tendency to improve; however, most of these cases are for asymptomatic or early ONFH.<sup>18–20</sup> Therefore, for symptomatic ONFH seriously affecting the normal functional activities of patients, interventions should be carried out in time, among which hip replacement is currently the most effective and common therapeutic option.<sup>7,21</sup>



**Fig. 3** SPECT/CT images: no clear signs of malignancy, and necrosis of the right femoral head were found (at 10 months after left THA)



**Fig. 4** Conventional X-ray CR images of the right hip reexamined after right THA. (A) CR images of the right hip at the first day and 1 month after right THA: the position of hip prosthesis was satisfactory, and there were no abnormal signs such as secondary fractures and further bone destruction. (B) Full-length CR images of both lower limbs reexamined at the first day after right THA: both lower limbs had the moderate length, with good position of line of gravity of lower limbs

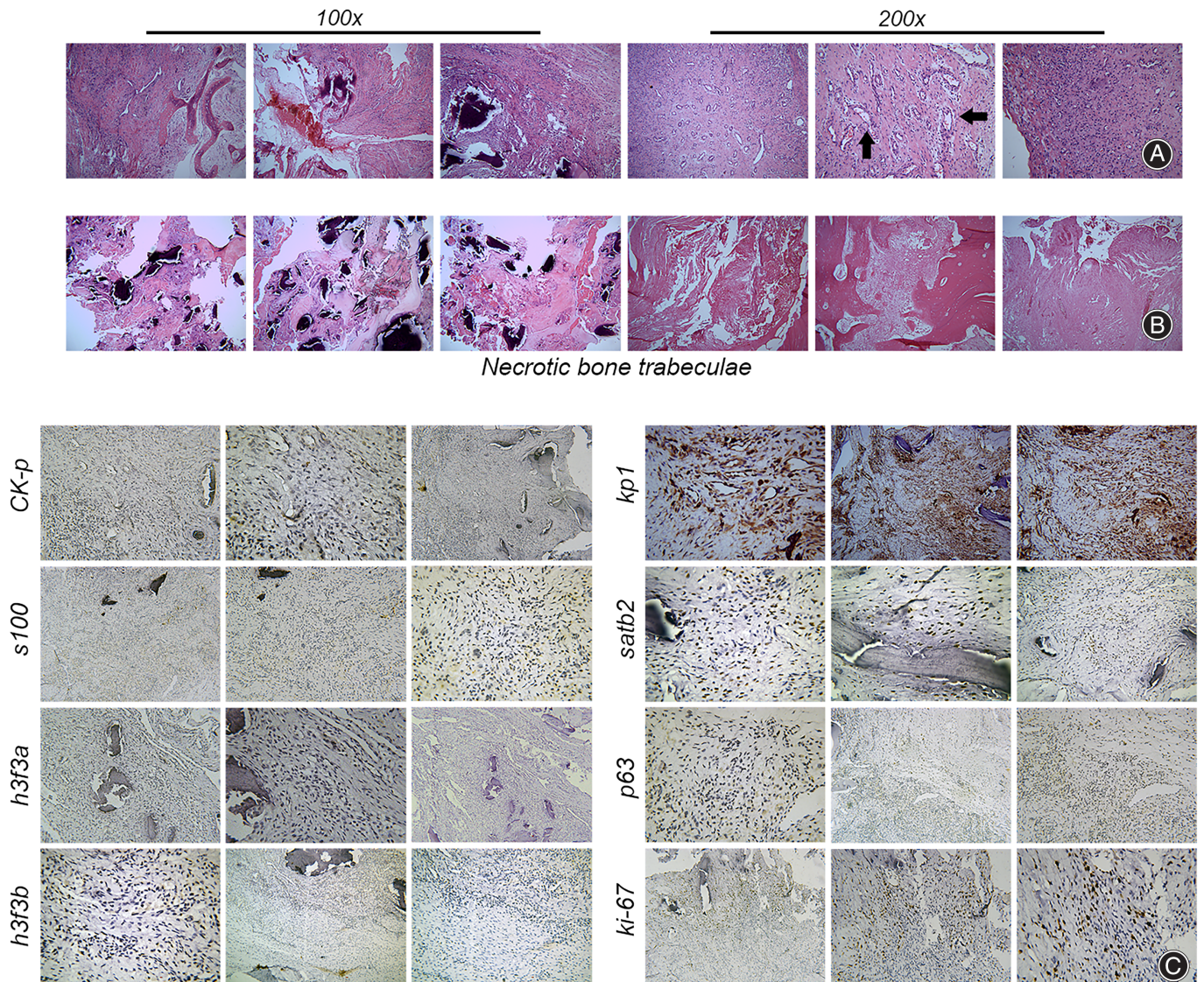
In terms of this case, when the patient first saw a doctor, the symptoms of left hip joint pain and limitation of motion were very obvious and severely affected normal life, and typical signs of necrosis of the left femoral head were shown on images. In fact, the patient had received conservative treatment (i.e. oral administration of analgesics, reduction of activities, and external application of pain-relieving creams) provided by himself for over 4 months before seeing a doctor. During this period, he did not go to the hospital for relevant examinations and treatments. This is also the reason why many ONFH patients have a severe condition upon first visit, because of a lack of early intervention and reasonable rehabilitation guidance. For this reason, a detailed preoperative evaluation was conducted on the patient, after which conventional left THA was performed. Following left THA, the pain of the patient was relieved and functional activities were recovered.

During the follow-up before left THA and at 3 months after left THA, the CR images of the right hip joint showed normal structure of the right femoral head, with no bone destruction and only signs of mild degeneration. However, at more than 5 months after left THA, the symptoms of right hip joint pain and limitation of motion began. Because the patient did not go to the hospital in time, there was no imaging evidence suggesting the collapse of the right femoral head. However, our clinical team still thought that the collapse of the right femoral head started more than 5 months after left THA. The time from the occurrence of ONFH in the right side to first discovery of complete collapse in the right femoral head (over 10 months after left THA) on

images was only 5 months. Severe bone destruction and absorption of the right femoral head to this degree in such a short period of time was very rare. ONFH with rapid progression and high degree of destruction is commonly caused by hormone injection or local tumor erosion.<sup>22,23</sup> As a result, the patient was re-admitted to the hospital due to right ONFH.

Based on the above medical history data and examination results, common causes were ruled out, including trauma, long-term use of hormones or alcohols, tumors, tuberculosis, bacterial and fungal infections, and osteoporosis. At present, the cause of rapid necrosis of the right femoral head has not been found, so this case has been temporarily considered idiopathic aseptic ONFH. Idiopathic aseptic ONFH with such rapid progression and such severe destruction is also very rare, and relevant literature and clinical reports on this topic is extremely scarce.

Such an agnogenic and rapidly progressive hip joint destructive disease is called RDHD, a rare disease with unknown pathogenesis.<sup>24</sup> RDHD is mainly characterized by pathological features such as unilateral hip joint rapid destruction, subchondral bone ischemia, and cell necrosis.<sup>15,25,26</sup> There are very few clinical and literature reports on RDHD, and the research on its pathogenesis remains unclear, so RDHD is often ignored by clinicians. However, it is currently believed that RDHD is mainly treated by surgery,<sup>27</sup> which, different from tumor/microbial erosion-induced ONFH, requires no additional special adjuvant therapies, such as tumor resection or anti-infection treatment. Therefore, for this case, conventional right THA was carried



**Fig. 5** Histopathological examination results of the right femoral head. (A) HE staining results: almost disappeared articular cartilage, rough and damaged surface, extensive fibrovascular tissue proliferation (black arrow), and reactive bone formation. (B) Destruction of massive trabecular bones. (C) Immunohistochemical results: ck-p (-), s100 (-), h3f3a (-), h3f3b (-), kp1 (+), satb2 (small amount+), p63 (-), and ki-67 (20%+)

out. The follow-up results after operation uncovered that the patient had resumed functional activities of the hip joint. In this study, the case was described as “severe idiopathic aseptic necrosis of the femoral head with rapid progression” instead of RDHD. There are two reasons for this description. Firstly, it was believed that this case is also a type of RDHD. Secondly, it was believed by our team that the name RDHD was too general, as tumor erosion-induced ONFH is also a hip joint disease with rapid destruction, so young physicians or researchers in other professional fields would misunderstand this name. Hence, in this study, this case was diagnosed as severe idiopathic aseptic necrosis of the femoral head with rapid progression.

As for this case, it is currently speculated by our team that left THA may be one of the important factors accelerating the necrosis of the right femoral head. Following left THA, the patient’s center of gravity may shift to the right when walking. In particular, in the postoperative rehabilitation stage, the patient would try to avoid weight bearing on the left lower limb due to the pain of the surgical incision or changes in proprioception and psychological effects of the patient. As a result, the right lower limb naturally bore more stress. A study showed that the increase in stress may facilitate the progression of ONFH.<sup>28</sup> For this reason, it was speculated that changes in stress, such as changes in walking posture or pelvic tilt, may be one of the factors inducing or

promoting RDHD. For patients undergoing unilateral THA, more attention should be paid to the contralateral hip joint by clinicians or rehabilitation physicians. For instance, clinicians or rehabilitation physicians should advise patients on correct walking posture after THA, muscle strength training, and pay more attention to CR of the pelvis instead of the unilateral hip joint during follow-ups.

In practice, RDHD is difficult to prevent and predict due to its unclear etiology and pathogenesis and extremely rapid progression. Currently, the most effective prevention strategies include enhancing follow-up, actively seeking medical attention, perfecting examinations, and reducing disease incentives, which requires close communication and cooperation among patients, clinicians, and rehabilitation physicians. In terms of this case, long-term regular follow-up was essential, during which the rehabilitation exercise and disease development of the patient needed special attention. For disease development, emphasis was put on bilateral hip joint conditions (functional activities, prosthesis position, and whether there are related complications like further bone destruction or local tumors) and systemic basic diseases (whether there are occult tumor foci, occult endocrine disorders, and underlying diseases such as occult congenital bone metabolism disorders). The subsequent progression of this case will be further followed up.

However, the study has some limitations: (1) the case is rare, so we were unable to analyze the epidemiology and etiology of this disease; (2) only one case is reported in this study, and it is not clear whether the relevant radiological

and clinical features are universal, so it is not possible to investigate the specific pathological mechanisms and features of this disease; (3) one of the unique features of this case is that RDHD developed in the contralateral hip after total hip replacement, but it is uncertain whether THA is a factor in the pathogenesis of RDHD.

### Conclusion

A case of severe idiopathic aseptic necrosis of the right femoral head with rapid progression after left THA, also known as RDHD, was reported in this study. Due to the scarcity of RDHD itself, not to mention contralateral RDHD after unilateral THA, this case was reported, hoping that clinicians and rehabilitation physicians will place more emphasis on the contralateral hip joint after unilateral THA, and a clinical reference will be provided for the research on RDHD.

### Conflicts of Interest

The authors declared no potential conflicts of interest with respect to the research, authorship, and/or publication of this article.

### Funding Information

This work was supported by the National Natural Science Foundation of China (Grant No.81972095); the Innovation Action Plan of Science and Technology Commission of Shanghai Municipality of China (Grant No.20S31901400, 19441901700, 19441901701, 19441901702).

### References

- Sodhi N, Acuna A, Etcheson J, Mohamed N, Davila I, Ehirobo JO, et al. Management of osteonecrosis of the femoral head. *Bone Joint J.* 2020;102-B(7\_Supple\_B):122–8.
- Sultan AA, Mohamed N, Samuel LT, Chughtai M, Sodhi N, Krebs VE, et al. Classification systems of hip osteonecrosis: an updated review. *Int Orthop.* 2019; 43(5):1089–95.
- Cohen-Rosenblum A, Cui Q. Osteonecrosis of the femoral head. *Orthop Clin North Am.* 2019;50(2):139–49.
- Tan Y, He H, Wan Z, Qin J, Wen Y, Pan Z, et al. Study on the outcome of patients with aseptic femoral head necrosis treated with percutaneous multiple small-diameter drilling core decompression: a retrospective cohort study based on magnetic resonance imaging and equivalent sphere model analysis. *J Orthop Surg Res.* 2020;15(1):264.
- Pepke W, Kasten P, Beckmann NA, Janicki P, Egermann M. Core decompression and autologous bone marrow concentrate for treatment of femoral head osteonecrosis: a randomized prospective study. *Orthop Rev (Pavia).* 2016;8(1):6162.
- Kaneko S, Takegami Y, Seki T, Fukushima W, Sakai T, Ando W, et al. Surgery trends for osteonecrosis of the femoral head: a fifteen-year multi-centre study in Japan. *Int Orthop.* 2020;44(4):761–9.
- Mont MA, Salem HS, Piuze NS, Goodman SB, Jones LC. Nontraumatic osteonecrosis of the femoral head: where do we stand today?: a 5-year update. *J Bone Joint Surg Am.* 2020;102(12):1084–99.
- Wu X, Geng C, Sun W, Tan M. Incidence and risk factors of osteonecrosis of femoral head in multiple myeloma patients undergoing dexamethasone-based regimens. *Biomed Res Int.* 2020;2020:7126982.
- Liu Q, He HB, Zeng H, Yuan YH, Long F, Tian J, et al. Modified trapdoor procedures by surgical dislocation approach to treat chondroblastoma of the femoral head. *Bone Joint J.* 2019;101-B(6):732–8.
- Dawson LK, Nussey F, Oliver TB, Marks RC, Leonard RC. Osteonecrosis of the femoral head following adjuvant chemotherapy for breast cancer. *Breast.* 2001;10(5):447–9.
- Zeng J, Zeng Y, Wu Y, Liu Y, Xie H, Shen B. Acetabular anatomical parameters in patients with idiopathic osteonecrosis of the femoral head. *J Arthroplasty.* 2020;35(2):331–4.
- Castro FP Jr, Harris MB. Differences in age, laterality, and Steinberg stage at initial presentation in patients with steroid-induced, alcohol-induced, and idiopathic femoral head osteonecrosis. *J Arthroplasty.* 1999;14(6): 672–6.
- Lespasio MJ, Sodhi N, Mont MA. Osteonecrosis of the hip: a primer. *Perm J.* 2019;23:18–100.
- Zhao DW, Yu M, Hu K, Wang W, Yang L, Wang BJ, et al. Prevalence of nontraumatic osteonecrosis of the femoral head and its associated risk factors in the Chinese population: results from a nationally representative survey. *Chin Med J (Engl).* 2015;128(21):2843–50.
- Bock GW, Garcia A, Weisman MH, Major PA, Lyttle D, Haghighi P, et al. Rapidly destructive hip disease: clinical and imaging abnormalities. *Radiology.* 1993;186(2):461–6.
- Nozawa M, Matsuda K, Maezawa K, Kim S, Maeda K, Ikegami T, et al. Rapid resolution of femoral head osteonecrosis after rotational acetabular osteotomy. *J Orthop Traumatol.* 2008;9(4):221–4.
- Hernigou P, Bachir D, Galacteros F. The natural history of symptomatic osteonecrosis in adults with sickle-cell disease. *J Bone Joint Surg Am.* 2003; 85(3):500–4.
- Kopecky KK, Braunstein EM, Brandt KD, Filo RS, Leapman SB, Capello WN, et al. Apparent avascular necrosis of the hip: appearance and spontaneous resolution of MR findings in renal allograft recipients. *Radiology.* 1991;179(2): 523–7.
- Mulliken BD, Renfrew DL, Brand RA, Whitten CG. Prevalence of previously undetected osteonecrosis of the femoral head in renal transplant recipients. *Radiology.* 1994;192(3):831–4.
- Jergesen HE, Khan AS. The natural history of untreated asymptomatic hips in patients who have non-traumatic osteonecrosis. *J Bone Joint Surg Am.* 1997; 79(3):359–63.
- Mutlu T, Daşar U, Bicimoglu A. Does THA improve social status among Turkish women with developmental dysplasia of the hip? *Clin Orthop Relat Res.* 2018;476(9):1696–703.
- Yamamoto T, Schneider R, Iwamoto Y, Bullough PG. Rapid destruction of the femoral head after a single intraarticular injection of corticosteroid into the hip



joint [published correction appears in *J Rheumatol*. 2006 Oct;33(10):2101]. *J Rheumatol*. 2006;33(8):1701–4.

- 23.** Seitz S, Zustin J, Amling M, R  ther W, Niemeier A. Massive accumulation of osteoclastic giant cells in rapid destructive hip disease. *J Orthop Res*. 2014; 32(5):702–8.
- 24.** Okike K, King RK, Merchant JC, Toney EA, Lee GY, Yoon HC. Rapidly destructive hip disease following intra-articular corticosteroid injection of the hip. *J Bone Joint Surg Am*. 2021;103(22):2070–9.
- 25.** Batra S, Batra M, McMurtrie A, Sinha AK. Rapidly destructive osteoarthritis of the hip joint: a case series. *J Orthop Surg Res*. 2008;3:3.

**26.** Matsunaga F, DeVita RR, Young PC. Rapidly destructive osteoarthritis of the hip. *Intern Emerg Med*. 2021;16(2):497–9.

- 27.** Pivec R, Johnson AJ, Mont MA. Results of total hip arthroplasty in patients who have rapidly progressive hip disease: a systematic review of the literature. *Expert Rev Med Devices*. 2012;9(3):257–62.
- 28.** Wen P, Zhang Y, Hao L, Yue J, Wang J, Wang T, et al. The effect of the necrotic area on the biomechanics of the femoral head - a finite element study. *BMC Musculoskelet Disord*. 2020;21(1):211.