

Case Report

Hemangiopericytoma of the cervical spine

Raghvendra V. Ramdasi, Trimurti D. Nadkarni, Naina A. Goel¹

Departments of Neurosurgery and ¹Neuropathology, King Edward Memorial Hospital, Seth G. S. Medical College, Parel, Mumbai, Maharashtra, India

Corresponding author: Prof. Trimurti D. Nadkarni, Department of Neurosurgery, King Edward Memorial Hospital, Seth G. S. Medical College, Parel - 400 012, Mumbai, Maharashtra, India. E-mail: tdnadkarni@hotmail.com

Journal of Craniovertebral Junction and Spine 2014, 5:21

Abstract

A 28-year-old male presented with neck pain and dysesthesias in the right upper limb. On examination, he had a firm, well-defined midline posterior cervical mass discernible on palpation at the mid-cervical level. He had no neurological deficit. Neuroradiology revealed a variegated enhancing cervical mass arising from C3 lamina. The mass extended into the right extradural space eroding the C3 lamina and posteriorly into the intermuscular plane. The tumor was excised totally. Histopathology of the tumor showed features of hemangiopericytoma (HPC). The patient underwent postoperative radiotherapy. Primary osseous spinal HPC are rare malignant extra-axial tumors that tend to recur and metastasize. Only two cases of primary osseous HPC have been reported earlier to involve the cervical spine. The clinical presentation and management of the present case with a review of the literature is presented.

Key words: Extradural, hemangiopericytoma, osseous, spinal

INTRODUCTION

Hemangiopericytoma (HPC) is a tumor of soft tissues and skeletal system. It is very rarely found in the central nervous system (CNS) constituting 1% of all CNS tumors. An intraspinal involvement of these tumors is rare. These tumors commonly arise from the dura and are located in the extradural compartment.^[1,2] The present case is a rare case of primary osseous HPC arising from cervical lamina and spreading intraspinally with an extradural component as well as an intermuscular extension.

CASE REPORT

A 28-years-old male presented with a history of neck pain associated with dysaesthesia in the right upper limb for 3 years.

The neurological examination of the patient was normal. A local examination of the nape of the neck revealed a single ovoid swelling at the mid-cervical level having a smooth surface, well demarcated margins and firm consistency. The mass was nontender and adherent to the underlying structures. Plain radiograph of the cervical spine showed destruction of the C3 lamina and erosion of the adjacent C2 and C4 laminae by an osteolytic mass [Figure 1]. There was no evidence of calcifications within the mass or presence of new bone formation. The vertebral bodies were normal, maintaining normal cervical lordosis. Computed tomography scan of the cervical spine revealed a hyperdense well-defined soft tissue mass that had eroded the right half of C3 lamina [Figure 2]. The mass extended into the extradural spinal canal and in the adjacent muscles. Magnetic resonance imaging of the cervical spine confirmed the variegated expansible lesion to arise from the C3 lamina, which enhanced on contrast administration. The mass was well-defined, had a bosselated surface and did not infiltrate into the adjacent muscles. Multiple flow voids were noted [Figure 3]. The posterior dura appeared intact and mild cord compression was noted. A hyperintense cord signal was noted at the level of cord compression [Figure 4]. The tumor was excised through a midline cervical incision. At surgery, well-defined, discrete mass with a bosselated surface was encountered. The tumor was firm, fleshy and moderately vascular. A rapid tumoral decompression

Access this article online	
Quick Response Code:	Website: www.jcvjs.com
	DOI: 10.4103/0974-8237.139209

was performed. After excising the extra spinal component of the tumor, normal dura was defined by performing C2 and C4 laminectomies. The residual left half of C3 lamina was excised. The extradural component of the tumor was noted on the right side. This portion was excised and was noted not to be adherent to the dura. There was a blood loss of 1 L which was adequately replaced intraoperatively. The patient made an uneventful postoperative recovery. There was a complete resolution of his neck pain and right upper-limb dysesthesia. Histopathological examination of the tumor revealed the lesion to be HPC [Figures 5 and 6]. The patient received adjuvant external beam radiotherapy (RT). The patient was asymptomatic at follow-up at 1-year. Postoperative radiology showed a complete excision of the cervical HPC.

DISCUSSION

Hemangiopericytomas usually occur in the subcutaneous soft tissue and skeletal system and rarely in the CNS. Meningeal

HPC constitute 2-4% of all meningeal tumors and 1% of all CNS tumors.^[1] After the first description by Stout and Murray in 1942, approximately 106 cases of spinal HPC have been reported. Of these 34 cases were located in the cervical spine.^[1,2]

Primary spinal HPC are divided into intradural and extradural lesions. The intradural lesions are either intra- or extramedullary. The extradural lesions are further classified as either dural based or primary osseous.^[1-3] In the present case, the tumor was an extradural lesion of the primary osseous variety. Spinal HPCs are significantly less common than intracranial meningeal HPCs. The spinal osseous metastases of cranial HPC are named secondary osseous HPC.

Our literature search has yielded 34 cases of cervical HPCs. Of these 14 cases were intradural, and 20 cases were extradural. Of the 14 intradural tumors, 2 patients had intramedullary and 12 harbored intradural extramedullary tumors. Of the 20 extradural tumors, 18 were intraspinal dural based and 2 tumors were primary osseous.^[1-4] The present case report is the third case of a primary osseous cervical HPC.

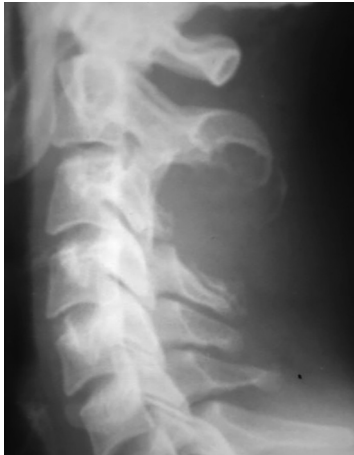

Figure 1: Plain radiograph of the cervical spine showing destruction of the C3 lamina and erosion of the adjacent C2 and C4 lamina by an osteolytic mass

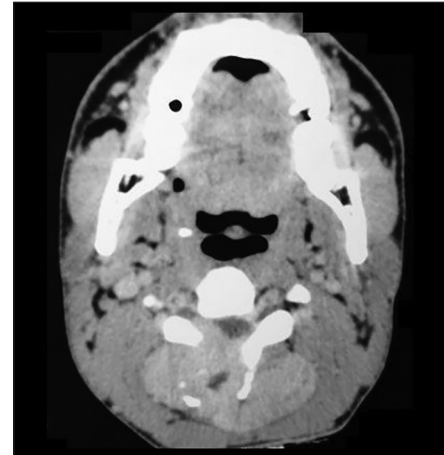


Figure 2: Axial view of computed tomography scan of the cervical spine revealing a hyperdense well-defined soft tissue mass eroding the right half of C3 lamina

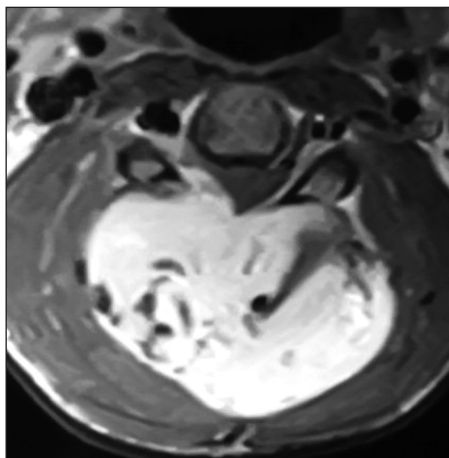


Figure 3: Postcontrast T1-weighted axial magnetic resonance image showing the well-defined enhancing mass extending into both intra- and extra-spinal compartments. Multiple flow voids are noted

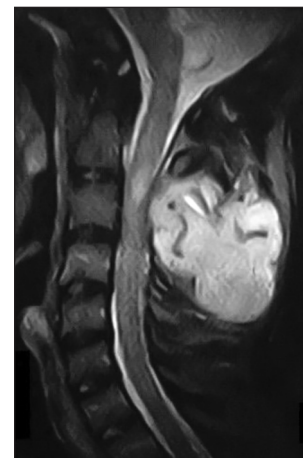


Figure 4: Postcontrast sagittal magnetic resonance image showing the cervical tumor to cause epidural compression, and a hyperintense signal is noted in the cervical cord

Spinal HPCs most commonly occur as extradural dural based lesions. Both intradural and extradural dural based HPCs are most common in the cervical spine and present with neural deficits.^[1-3] In contrast, primary osseous HPCs mostly affect the lumbosacral spine and have paravertebral extensions, but do not present with neurological deficit. Most commonly these lesions present with pain.^[2] Thirteen of all reported spinal HPC were primary osseous [Table 1]. Out of these only two were located in cervical spine.^[1,2] Thus, the present case is only the third cervical primary osseous HPC reported in the literature.

Contrary to the popular belief that HPC is a neoplasm arising from capillary pericytes, World Health Organization in 1990 classified them to be “mesenchymal nonmeningothelial” tumor and recently as fibroblastic without evidence of pericytic differentiation.^[4] It is classified as grade II tumor and considered

anaplastic grade III if the tumor contains infiltrative margins, high cellularity, nuclear pleomorphism, areas of tumor necrosis, and increased mitotic index (>4 mitoses/10 × high-powered field).^[2] The present case, the tumor, was of grade II.

Surgery remains the treatment of choice for these tumors.^[1-4] Many studies describe that complete *en bloc* resection improves recurrence free rate and prolongs survival.^[2,3] However, in the largest series published by Liu *et al.* there was no benefit demonstrated from complete resection.^[1] The surgeon should be prepared for a substantial amount of bleeding during tumor excision because of high vascularity of HPCs. Preoperative embolization can be used to reduce the operative blood loss, which can enhance the chance of gross total resection.^[4]

In most series, adjuvant RT has proven to be effective however adjuvant chemotherapy has shown no benefit.^[1-3] We subjected our patient to RT.

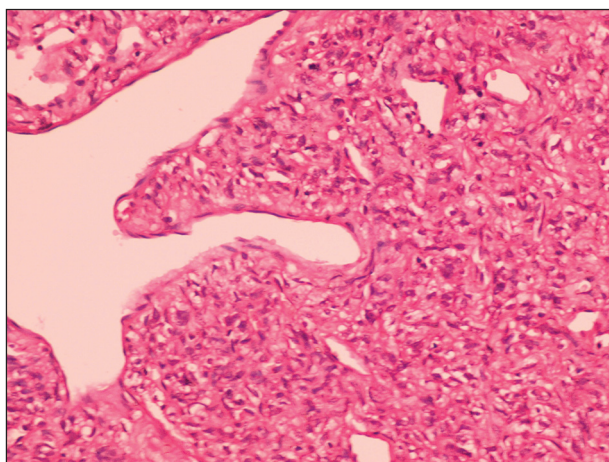


Figure 5: Photomicrograph of the tumor showing a hemangiopericytoma consisting of a diffuse sheet-like arrangement of round to oval epithelioid cells with ill-defined cell borders. The cells contain a moderate amount of cytoplasm and small round to oval hyperchromatic nuclei. Scattered dilated branching staghorn like and a thin slit like blood vessels are also seen (H and E, x400)

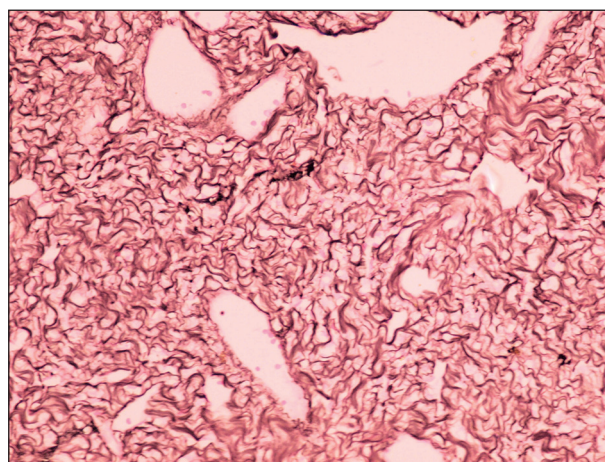


Figure 6: Photomicrograph of immunohistochemistry of the tumor showing immunoreactivity for reticulin stain characteristic of hemangiopericytoma (Reticulin, x400)

Table 1: Cases of primary osseous spinal hemangiopericytoma reported in the literature

Author/year/references	Age/sex	Location	Adjuvant therapy	Follow-up, years	Recurrence, years
Gerner <i>et al.</i> (1974) ^[5]	62/male	L5	RT	—	—
Wold <i>et al.</i> (1982) ^[6]	42/female	Sacrum	RT	1.5	Died
	62/female	Sacrum	—	—	Died
	33/female	Sacrum	—	31	Died
	37/female	Sacrum	RT	5	Died
Tang <i>et al.</i> (1988) ^[7]	19/male	L2	Chemotherapy + RT	4	3
Nakashima <i>et al.</i> (2012) ^[8]	51/female	C3-C4	—	9	4
Liu <i>et al.</i> (2013) ^[1]	53/male	T3-T5	Stereotactic radiosurgery	8.8	4.4
	56/female	C2-C4	RT	10.8	5
	14/male	L2	RT	4	2, metastasis to posterior cranial fossa
	73/female	T9-T10	RT	22	20
	44/male	L5-S1	RT	4.5	4
	50/male	T11-T12	RT	None	5.5
Present case	28/male	C3-C4	RT	1	None

C: Cervical, T: Thoracic, L: Lumbar, S: Sacral, RT: Radiotherapy

The length of survival of spinal HPC depends on the site, size and grade of the tumor. Poorer prognosis is associated with tumors larger than 6 cm, higher histological grade of the tumor and extradural locations. The incidence of recurrence for spinal HPC ranges from 48% to 88% and the incidence of metastasis is 17%.^[3] The prognosis of spinal HPC is worse than their cranial counterparts.^[1] Intradural spinal HPC and dural based HPC have a better prognosis than primary osseous lesions.^[3,4]

CONCLUSION

A primary osseous HPC of the cervical spine is rare. Such a lesion should be considered in the differential diagnosis of midline posterior neck swelling. Complete surgical removal and adjuvant RT is the treatment of choice for these tumors.

REFERENCES

1. Liu HG, Yang AC, Chen N, Yang J, Qiu XG, Zhang JG. Hemangiopericytomas in the spine: Clinical features, classification, treatment, and long-term follow-up in 26 patients. *Neurosurgery* 2013;72:16-24.

2. Cole CD, Schmidt MH. Hemangiopericytomas of the spine: Case report and review of the literature. *Rare Tumors* 2009;1:e43.
3. Zhao Y, Zhao JZ. Clinical and pathological characteristics of primary intraspinal hemangiopericytoma and choice of treatment. *Chin Med J (Engl)* 2007;120:115-9.
4. Drazin D, Shweikeh F, Bannykh S, Johnson JP. Hemangiopericytoma invading the craniocervical junction: First reported case and review of the literature. *J Craniovertebr Junction Spine* 2013;4:32-4.
5. Gerner RE, Moore GE, Pickren JW. Hemangiopericytoma. *Ann Surg* 1974;179:128-32.
6. Wold LE, Unni KK, Cooper KL, Sim FH, Dahlin DC. Hemangiopericytoma of bone. *Am J Surg Pathol* 1982;6:53-8.
7. Tang JS, Gold RH, Mirra JM, Eckardt J. Hemangiopericytoma of bone. *Cancer* 1988; 62:848-59.
8. Nakashima H, Imagama S, Sakai Y, Nakamura H, Katayama Y, Ito Z, et al. Dumbbell-type hemangiopericytoma in the cervical spine: a case report and review. *J Orthop Sci* 2013;18:849-55.

How to cite this article: Ramdasi RV, Nadkarni TD, Goel NA. Hemangiopericytoma of the cervical spine. *J Craniovertebr Junction Spine* 2014;5:95-8.

Source of Support: Nil, **Conflict of Interest:** None declared.

Author Help: Reference checking facility

The manuscript system (www.journalonweb.com) allows the authors to check and verify the accuracy and style of references. The tool checks the references with PubMed as per a predefined style. Authors are encouraged to use this facility, before submitting articles to the journal.

- The style as well as bibliographic elements should be 100% accurate, to help get the references verified from the system. Even a single spelling error or addition of issue number/month of publication will lead to an error when verifying the reference.
- Example of a correct style
Sheahan P, O'leary G, Lee G, Fitzgibbon J. Cystic cervical metastases: Incidence and diagnosis using fine needle aspiration biopsy. *Otolaryngol Head Neck Surg* 2002;127:294-8.
- Only the references from journals indexed in PubMed will be checked.
- Enter each reference in new line, without a serial number.
- Add up to a maximum of 15 references at a time.
- If the reference is correct for its bibliographic elements and punctuations, it will be shown as CORRECT and a link to the correct article in PubMed will be given.
- If any of the bibliographic elements are missing, incorrect or extra (such as issue number), it will be shown as INCORRECT and link to possible articles in PubMed will be given.