

Acute immunoallergic hepatitis due to allopurinol use

 Carolyn Brooks¹,  Lucie Calderon²,  Marina Mosunjac³,  Emad Qayed²

¹Department of Internal Medicine, Emory University School of Medicine, Atlanta, USA; ²Division of Digestive Diseases, Department of Internal Medicine, Emory University School of Medicine, Atlanta, USA; ³Department of Pathology, Emory University School of Medicine, Atlanta, USA

Abstract

Acute immunoallergic hepatitis presents as acute liver injury, often accompanied by nonspecific findings of fever, rash, and abdominal pain, and is often induced by drug ingestion. Allopurinol has been implicated in multiple cases of acute immunoallergic hepatitis. We present the case of a young East Asian male with gout who experienced acute immunoallergic hepatitis, complicated by DRESS syndrome with a severe cutaneous reaction, as a result of allopurinol intake. The patient was positive for the HLA-B58*01 gene, a significant risk factor for developing allopurinol-induced liver injury. The patient's liver injury and skin reaction improved with the administration of IV methylprednisolone, followed by a course of oral prednisone. Our case prompts clinicians to prescribe allopurinol with caution in certain high-risk populations and emphasizes the importance of administering corticosteroids early in such a presentation to avoid long-term liver damage.

Keywords: Drug-induced liver injury; liver biopsy; liver function tests.

Introduction

Drug-induced liver injury (DILI) is one of the most common causes of acute liver failure, particularly in the developed world.^[1] The pattern of liver injury associated with DILI can be either hepatocellular or cholestatic, and the symptoms and degree of liver injury can range in severity among culprit drugs and individual patients. Acute immunoallergic hepatitis is a type of DILI characterized by hepatocellular injury mediated through a hypersensitivity reaction. It is marked by a range of manifestations, including a variable degree of skin rash, fever, lymphadenopathy, facial edema, myalgias, arthralgias, eosinophilia, and atypical lymphocytosis.^[2,3] Allopurinol use has been linked to multiple cases of acute immunoallergic hepatitis.^[2,4–10]

Allopurinol is a xanthine oxidase inhibitor used for long-term gout management, and its metabolite, oxypurinol, is known to trigger a cytotoxic T-cell response and is thought to be the cause of allopurinol-mediated hypersensitivity.^[11] Chronic allopurinol therapy for gout has been associated with transient liver enzyme abnormalities in 2–6%

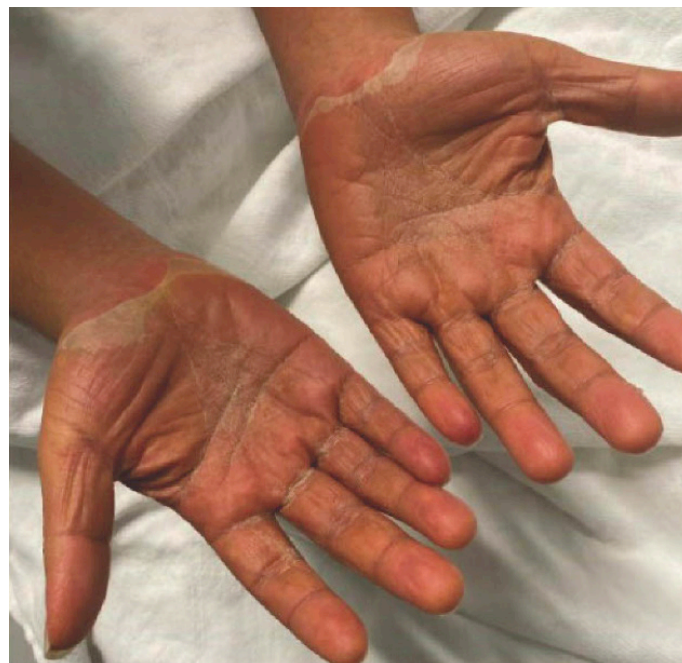

Figure 1. Desquamating rash of palms on day 2 of presentation.

of patients, which typically resolve spontaneously.^[3] Rarely, allopurinol may induce more severe immunoallergic hepatitis that is often linked with drug reaction with eosinophilia and systemic symptoms (DRESS). Indeed, in one study of DILI, 67% of all allopurinol-induced DILI cases were associated with DRESS.^[12]

DRESS can have up to a 10% mortality rate, regardless of the culprit drug.^[13] Therefore, identifying patients with this DILI-DRESS phenotype promptly upon admission, discontinuing the offending medication, and initiating steroid management are imperative to achieve good outcomes.

Case Report

A 21-year-old Vietnamese male with no significant past medical history developed a gout flare and was started on colchicine and allopurinol as an outpatient. This patient had no prior history of liver disease, no IV drug use history, and no history of alcohol consumption. He completed a 3-day course of colchicine, and his gout flare resolved. He continued taking allopurinol 100 mg daily. After six weeks of allopurinol therapy, he noticed reddening of his skin, which worsened over the course of one week to a desquamating diffuse rash involving the face, back, arms, and hands (Fig. 1). He soon developed fevers and tachycardia as well as the acute edematous macular rash, and he presented to the emergency room for evaluation.

How to cite this article: Brooks C, Calderon L, Mosunjac M, Qayed E. Acute immunoallergic hepatitis due to allopurinol use. *Hepatology Forum* 2025; 6(2):65–68.

Received: July 23, 2024; **Revised:** November 14, 2024; **Accepted:** December 02, 2024; **Available online:** January 14, 2025

Corresponding author: Carolyn Brooks; Department of Internal Medicine, Faculty of Medicine, Emory University Atlanta, USA

Phone: +1 713 855 1737; **e-mail:** cgbroo2@emory.edu



OPEN ACCESS
This work is licensed under a Creative Commons Attribution-NonCommercial 4.0 International License.

Hepatology Forum - Available online at www.hepatologyforum.org

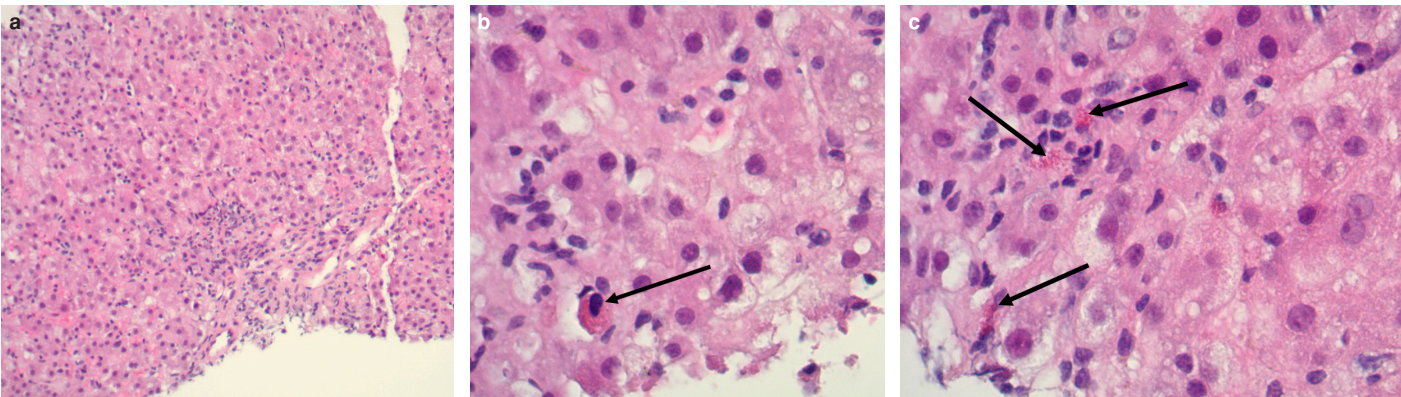


Figure 2. (a) 100x view of hematoxylin and eosin stain of tissue from transjugular liver biopsy. (b) 400x view of H+E stain, with black arrow indicating acidophilic body. (c) 400x view of H+E stain, with black arrow indicating eosinophils.

On admission, his mental status was intact, with no concerns for encephalopathy. His heart rate was 106 bpm on admission but improved to 98 bpm shortly after presenting to the emergency room. He was afebrile at 37.2 °C, and his blood pressure was 139/86. His physical exam was notable for facial edema, anterior cervical lymphadenopathy, diffuse jaundice, abdominal distention, and palpable hepatosplenomegaly with no abdominal tenderness and no fluid wave, as well as a desquamating rash on his face, back, and palms. He had no chest pain, shortness of breath, or cough, no changes in urine output, and no bloody diarrhea.

His admission labs were notable for elevated liver enzymes and hyperbilirubinemia: aspartate transaminase (AST) was 376 units/L, and alanine transaminase (ALT) was 502 units/L; alkaline phosphatase was 243 units/L. Based on these values, the R factor for liver injury was 4.1, indicating a mixed pattern of liver injury, with both hepatocellular and cholestatic damage. His total bilirubin was 3.1 mg/dL, and direct bilirubin was 2.0 mg/dL. His international normalized ratio (INR) was elevated to 1.4, and platelets were normal at 251K/ μ L. The white blood cell count was normal at 7.9K/ μ L, and his absolute eosinophil count was zero. Allopurinol was stopped immediately upon admission.

Right upper quadrant ultrasound on day 1 of admission demonstrated an enlarged liver measuring 20 cm, with patent vasculature and no other abnormal hepatic findings. On magnetic resonance cholangiopancreatography (MRCP) conducted on day 3, the patient’s liver was still enlarged at 17 cm in the mid-clavicular line, with diffuse periportal edema and enhancement suggestive of acute hepatitis. MRCP also demonstrated splenomegaly, measuring up to 16 cm in length, and marked gallbladder wall thickening and edema that completely effaced the gallbladder lumen. These findings were consistent with acalculous cholecystitis, likely secondary to adjacent hepatic inflammation.

On day 5 of admission, a transjugular liver biopsy was performed, demonstrating a hepatitic pattern of liver injury with mixed inflammatory infiltrate and intracellular cholestasis, marked by eosinophils and acidophil bodies (Fig. 2). Per the pathology report, these findings were all consistent with medication-induced liver injury, most likely DRESS. Steroids had not been initiated at the time of this biopsy. Liver enzymes peaked on day 6, with ALT and AST levels both exceeding 1300 units/L. Total bilirubin was 18.4 mg/dL, and direct bilirubin was 14.6 mg/dL (Table 1). On day 6, intravenous methylprednisolone was started at a dose of 40 mg daily. After two days of IV methylprednisolone, he was transitioned to prednisone 40 mg daily.

Table 1. Trends of liver function tests and other relevant laboratory studies

Lab value (normal range)	Day 1	Day 7	Day 50
AST (10–42 units/L)	376	1355	22
ALT (17–63 units/L)	502	1528	20
Alk phos (38–126 units/L)	243	177	63
T bili (0.3–1.6 mg/dL)	3.1	18.7	1.3
D bili (0.1–0.4 mg/dL)	2.0	14.6	0.3
WBC (3.8–10.7 K/mcL)	7.9	8.6	8.9
Hemoglobin (13.2–17.7 gm/dL)	14.2	14.0	15.1
Platelets (148–362 K/mcL)	251	179	354
INR (0.9–1.0)	1.4	2.0	1.1
Creatinine (0.7–1.2 mg/dL)	0.8	0.8	0.8
Uric acid (3.4–7.0 mg/dL)	7.8	No further trend	

AST: Aspartate transaminase; ALT: Alanine transaminase; INR: International normalized ratio

Other notable labs during his admission included negative hepatitis serologies, negative anti-smooth muscle antibody, and negative anti-mitochondrial antibody. Given the negative smooth muscle antibody, suspicion for autoimmune hepatitis was low, and no ANA or serum IgG levels were collected during this admission. His HLA-B*58.01 genetic test was positive. He was cleared for discharge on day 12 of admission. He was discharged on 40 mg prednisone daily, which he was instructed to continue until follow-up with the GI clinic.

He followed up with the dermatology clinic 20 days after discharge, and his skin findings had completely resolved. He was then seen in the GI clinic 35 days after discharge. At this follow-up, his liver enzymes and bilirubin levels had returned to normal (Table 1). He was still taking 40 mg prednisone daily. At this visit, he was prescribed a 30-day prednisone taper: 10 days at 30 mg, followed by 20 mg for the next 10 days, and 10 mg for the final 10 days. Altogether, the total duration of steroid use was 77 days: 2 days of IV methylprednisolone and 75 days of oral prednisone. The total time required for liver enzyme recovery was 50 days (Table 1).

At his follow-up six months after his initial liver injury, he had been off all steroids for more than three months. His liver enzymes were still normal, and he denied any concerning symptoms. Since stopping

allopurinol, the patient had no gout flares, and he had not been on any other medication for gout. He was never restarted on colchicine during the follow-up period and was not started on febuxostat as an alternative uric acid-lowering agent.

Discussion

This case represents an example of an allopurinol-induced immunoallergic reaction involving fever, acute hepatitis, and DRESS. Since allopurinol was first used for the treatment of gout in the late 1960s, there have been multiple documented cases of hypersensitivity reactions attributed to allopurinol in the literature, with most patients developing fever, skin rash, and liver and/or renal failure.^[4–6] The onset of systemic symptoms after the initiation of allopurinol ranges widely in reported cases, from two weeks to three months.^[7,8] In rare cases, the sequelae of allopurinol-induced hypersensitivity proved lethal, ranging from cardiac arrest due to DRESS syndrome to fatal liver necrosis. Thus, it is important that providers remain hypervigilant for this possible syndrome, even when patients' lab findings or symptoms do not align perfectly with expectations.^[9,10] Notably, the patient described in our case never had eosinophilia, as one might expect in DRESS, but this may not be necessary to characterize the DILI-DRESS phenotype. In one recent study of DILI associated with DRESS, 15% of patients with DRESS did not have eosinophilia.^[12]

Furthermore, the pathology results from the transjugular liver biopsy were all consistent with DRESS resulting from allopurinol use. Hematoxylin and eosin-stained sections demonstrated hepatic parenchyma with a hepatocellular pattern of injury and scattered acidophil bodies. Additionally, extensive lobular and mixed inflammatory infiltrate and focal intracellular cholestasis were present. Special stains were used on the pathology sections: trichrome stain showed no significant fibrosis, periodic acid-Schiff stain demonstrated no intracytoplasmic hyaline globules, and iron stain demonstrated patchy iron deposits in reticuloendothelial cells. Altogether, the results were consistent with medication-induced liver injury from allopurinol. In other cases of allopurinol hepatotoxicity, liver pathology sections have similarly demonstrated eosinophilia, intracellular cholestasis, and mixed hepatic inflammatory infiltrate.^[3]

This patient was also taking colchicine for the first three days of his treatment with allopurinol, but it is less likely that colchicine was the causative agent in his drug-induced liver injury. The Roussel Uclaf Causality Assessment Method (RUCAM), a scoring system used to determine the likelihood that hepatic injury is due to a specific medication, was applied to assess the contributions of both allopurinol and colchicine to this patient's liver injury.^[14] The RUCAM grade for allopurinol was 7, while the grade for colchicine was 3. A score of 3–5 indicates a drug is a “possible” contributor to liver injury, while a score of 6–8 indicates a “probable” contributor.^[14]

There are very few reports of colchicine-induced hepatotoxicity in the literature. Documented cases have associated histopathologic findings characteristic of colchicine's mechanism, which disrupts mitotic activity and cellular function.^[15] In colchicine-induced liver toxicity, histologic staining would reveal enlarged nuclei, multiple mitotic figures, and cellular edema. In contrast, allopurinol hepatotoxicity is characterized by eosinophilia, intracellular cholestasis, and/or acute granulomatous changes.^[3,16]

The exact mechanism by which allopurinol causes DILI, DRESS, or any acute immunoallergic reaction is not fully understood. However, it is suspected that a cell-mediated immune reaction (type IV hypersensitivity) to oxypurinol, the metabolite of allopurinol, is responsible.^[13]

It has been clearly established that allopurinol-associated DRESS with acute liver injury is closely linked to HLA-B58.01 positivity, particularly in Asian populations.^[17] Other HLA allele mutations linked with allopurinol liver toxicity include HLA-A33.03 and HLA-C03.02.^[8] Patients carrying the HLA-B58.01 allele have been found to have an 80-fold increase in risk of developing severe cutaneous adverse reactions to allopurinol.^[7] In one case-controlled study conducted in China, 100% of patients with allopurinol-induced hypersensitivity reactions were HLA-B58.01 positive, compared with 15% of allopurinol-tolerant patients and 20% of healthy controls.^[18] This strong correlation between HLA-B58.01 positivity and an immunoallergic reaction to allopurinol has also been observed in other Southeast Asian populations, as well as in African-Americans.^[19,20]

Management of allopurinol-induced liver injury primarily involves discontinuation of allopurinol and supportive care. While the use of glucocorticoids in DRESS has not been definitively evaluated in randomized trials, consensus supports the administration of steroids in DRESS with acute end-organ injury.^[21] To reduce the risk of allopurinol-induced liver injury, some studies suggest that providers should consider testing, if available, for HLA-B58.01 in patients belonging to high-risk ethnic groups before initiating gout maintenance therapy.^[22] Currently, the American College of Rheumatology conditionally recommends testing for HLA-B58.01 mutations in individuals of Southeast Asian descent and in African-Americans.^[23] For those who test positive, febuxostat may be initiated instead of allopurinol as an alternative urate-lowering therapy, although it can also be associated with hypersensitivity reactions.^[23,24] More investigation is warranted into alternative options for gout maintenance therapy in patients who have experienced allopurinol-induced acute immunoallergic hepatitis or who are at high risk of having that reaction.

Conclusion

Allopurinol-induced drug-induced liver injury can be associated with immunoallergic hepatitis in conjunction with DRESS, especially in individuals positive for the HLA-B*58.01 allele, as in the patient described above. In such cases of allopurinol-associated DILI with DRESS, it is imperative that allopurinol be stopped immediately and steroids initiated to avoid morbid progression of liver injury or severe cutaneous reactions.

Author Contributions: Concept – CB, EQ, LC; Design – CB, EQ, LC; Supervision – CB, EQ, LC; Data Collection and/or Processing – MM; Analysis and/or Interpretation – CB, EQ, MM; Literature Search – CB; Writing – CB; Critical Reviews – CB, EQ, LC.

Conflict of Interest: The authors have no conflict of interest to declare.

Informed Consent: Written informed consent was obtained from the patient for the publication of the case report and the accompanying images.

Use of AI for Writing Assistance: Not declared.

Financial Disclosure: The authors declared that this study has received no financial support.

Peer-review: Externally peer-reviewed.

References

1. Chalasani NP, Maddur H, Russo MW, Wong RJ, Reddy KR; Practice Parameters Committee of the American College of Gastroenterology. ACG Clinical Guideline: Diagnosis and management of idiosyncratic drug-induced liver injury. *Am J Gastroenterol* 2021;116(5):878–898. [CrossRef]

2. Stamp LK, Barclay ML. How to prevent allopurinol hypersensitivity reactions? *Rheumatology (Oxford)* 2018;57(Suppl 1):i35-i41. [\[CrossRef\]](#)
3. LiverTox: Clinical and Research Information on Drug-Induced Liver Injury. Bethesda (MD): National Institute of Diabetes and Digestive and Kidney Diseases; 2012.
4. Boyer TD, Sun N, Reynolds TB. Allopurinol-hypersensitivity vasculitis and liver damage. *West J Med.* 1977;126(2):143-147.
5. Al-Kawas FH, Seeff LB, Berendson RA, Zimmerman HJ, Ishak KG. Allopurinol hepatotoxicity. Report of two cases and review of the literature. *Ann Intern Med* 1981;95(5):588-590. [\[CrossRef\]](#)
6. Liu Q, Zhao S, Chen W. Clinical features, treatment outcomes and prognostic factors of allopurinol-induced DRESS in 52 patients. *J Clin Pharm Ther* 2022;47(9):1368-1378. [\[CrossRef\]](#)
7. Yoon JY, Min SY, Park JY, Hong SG, Park SJ, Paik SY, Park YM. [A case of allopurinol-induced granulomatous hepatitis with ductopenia and cholestasis]. *Korean J Hepatol* 2008;14(1):97-101. [Korean] [\[CrossRef\]](#)
8. Yaylacı S, Demir MV, Temiz T, Tamer A, Uslan MI. Allopurinol-induced DRESS syndrome. *Indian J Pharmacol* 2012;44(3):412-414. [\[CrossRef\]](#)
9. Pereira S, Almeida J, Silva AO, Quintas M, Candeias O, Freitas F. Necrose hepática fatal por alopurinol [Fatal liver necrosis due to allopurinol]. *Acta Med Port* 1998;11(12):1141-1144. [Portuguese]
10. Choi HG, Byun J, Moon CH, Yoon JH, Yang KY, Park SC, Han CJ. Allopurinol-induced DRESS syndrome mimicking biliary obstruction. *Clin Mol Hepatol* 2014;20(1):71-75. [\[CrossRef\]](#)
11. Richette P, Doherty M, Pascual E, Barskova V, Becce F, Castañeda-Sanabria J, et al. 2016 updated EULAR evidence-based recommendations for the management of gout. *Ann Rheum Dis* 2017;76(1):29-42. [\[CrossRef\]](#)
12. Medina-Cáliz I, Sanabria-Cabrera J, Villanueva-Paz M, Aukštikalnė L, Stephens C, Robles-Díaz M, et al. Characterization of drug-induced liver injury associated with drug reaction with eosinophilia and systemic symptoms in two prospective DILI registries. *Arch Toxicol* 2024;98(1):303-325. [\[CrossRef\]](#)
13. Cho YT, Yang CW, Chu CY. Drug reaction with eosinophilia and systemic symptoms (DRESS): An interplay among drugs, viruses, and immune system. *Int J Mol Sci* 2017;18(6):1243. [\[CrossRef\]](#)
14. LiverTox: Clinical and Research Information on Drug-Induced Liver Injury [Internet]. Bethesda (MD): National Institute of Diabetes and Digestive and Kidney Diseases; 2012-.
15. Abbott CE, Xu R, Sigal SH. Colchicine-Induced Hepatotoxicity. *ACG Case Rep J* 2017;4:e120. [\[CrossRef\]](#)
16. Stemmerman GN, Hayashi T. Colchicine intoxication: A reappraisal of its pathology based on a study of three fatal cases. *Human Pathol* 1971;2:321-332. [\[CrossRef\]](#)
17. Wong CS, Yeung CK, Chan CY, Yap DY, Tang SC, Cheung BM, et al. HLA-B*58:01 screening to prevent allopurinol-induced severe cutaneous adverse reactions in Chinese patients with chronic kidney disease. *Arch Dermatol Res* 2022;314(7):651-659. [\[CrossRef\]](#)
18. Ha Pham TT, Tran QB, Chu CH, Nga Do TQ, Nguyen HA, Nguyen DV, et al. Allopurinol-induced severe cutaneous adverse reactions in Vietnamese: the role of HLA alleles and other risk factors. *Pharmacogenomics* 2022;23(5):303-313. [\[CrossRef\]](#)
19. Fontana RJ, Li YJ, Phillips E, Saeed N, Barnhart H, Kleiner D, et al; Drug Induced Liver Injury Network. Allopurinol hepatotoxicity is associated with human leukocyte antigen Class I alleles. *Liver Int* 2021;41(8):1884-1893. [\[CrossRef\]](#)
20. Kridin K, Brüggem MC, Walsh S, Bensaid B, Ranki A, Oppel E, et al. Management and treatment outcome of DRESS patients in Europe: An international multicentre retrospective study of 141 cases. *J Eur Acad Dermatol Venereol* 2023;37(4):753-762. [\[CrossRef\]](#)
21. Lien YH, Logan JL. Cross-reactions between allopurinol and febuxostat. *Am J Med* 2017;130(2):e67-e68. [\[CrossRef\]](#)
22. FitzGerald JD, Dalbeth N, Mikuls T, Brignardello-Petersen R, Brignardello-Petersen R, Guyatt G, Abeles AM, et al. 2020 American College of Rheumatology Guideline for the Management of Gout. *Arthritis Care Res (Hoboken)* 2020;72(6):744-760. [\[CrossRef\]](#)
23. Singh JA, Cleveland JD. Hypersensitivity reactions with allopurinol and febuxostat: a study using the Medicare claims data. *Ann Rheum Dis* 2020;79(4):529-535. [\[CrossRef\]](#)