

Rapid prototyping technology for cranioplasty: A case series

Ashish Thakur, Dushyant Chauhan, M. Viswambaran, R. K. Yadav, Dhruv Sharma

Department of Prosthodontics and Crown and Bridge, Army Dental Centre R and R, New Delhi, India

Abstract

Cranial vault defects may be acquired or congenital in origin. Rehabilitation of these patients often poses challenge to the operating team and prosthodontist. Polymethylmethacrylate is a commonly used alloplastic graft material which is used for the fabrication of cranial prosthesis. Nowadays, with the advancement in the bioengineering, custom-made template and cranial prosthesis can be made by rapid prototyping technology (RPT) by patient three-dimensional (3D) computed tomography (CT) scan images. This series of two cases explained two different techniques for the rehabilitation of the patient with frontotemporoparietal cranial defect. Case 1 had a history of cerebrovascular accident, followed by decompression craniotomy which led to frontotemporoparietal defect of the left side. This defect area was associated with the cerebrospinal fluid accumulation which made delineation of underlying bony margins difficult and interfered with conventional impression procedures. Case 2 had a road traffic accident which led to intracerebral hemorrhage followed by decompression craniotomy which resulted in frontotemporoparietal defect of the right side. The patient had a poor neuromuscular control which impedes with the upright posture of the head during impression making of the defect area. Therefore, these cases were planned to rehabilitate by RPT. In these techniques, the prosthesis was made using custom-made skull template produced by RPT, using the data of 3D-CT scan images. This technique resulted in the prosthesis with good esthetics and better fit of the prosthesis. The contours of the prosthesis were replicated in the same manner as compared to the contralateral side. RPT is an additive manufacturing technology which is now used in the field of dentistry too. This technique is easy to use; fabricate prosthesis with high precision is less time-consuming and has fewer chances of error.

Keywords: Cranial prosthesis, cranioplasty, fused deposition modeling, standard tessellation language format, three-dimensional printing

Address for correspondence: Dr. Ashish Thakur, Department of Prosthodontics and Crown and Bridge, Army Dental Centre R and R, Delhi Cantt, New Delhi - 110 010, India.

E-mail: ashishthakurprosthodont@gmail.com

Received: 09th September, 2018, **Accepted:** 14th February, 2019

INTRODUCTION

Cranioplasty is defined as the surgical repair of acquired or congenital cranial defects. The objective of cranioplasty includes protection of brain, reconstruction of lost anatomical part, and esthetics. There are many indications of

cranioplasty such as trauma, decompressive craniectomies, tumors, complications of previous cranioplasties, and congenital deformities.

Rehabilitation of patients with cranial defects requires a multidisciplinary approach, and such patients often pose

Access this article online	
Quick Response Code:	Website: www.j-ips.org
	DOI: 10.4103/jips.jips_295_18

This is an open access journal, and articles are distributed under the terms of the Creative Commons Attribution-NonCommercial-ShareAlike 4.0 License, which allows others to remix, tweak, and build upon the work non-commercially, as long as appropriate credit is given and the new creations are licensed under the identical terms.

For reprints contact: reprints@medknow.com

How to cite this article: Thakur A, Chauhan D, Viswambaran M, Yadav RK, Sharma D. Rapid prototyping technology for cranioplasty: A case series. J Indian Prosthodont Soc 2019;19:184-9.

a challenge to the operating team and prosthodontist. There are several materials available for cranioplasty, out of which polymethylmethacrylate (PMMA) is one of the most commonly used alloplastic graft materials.^[1]

With the advances in bioengineering, rapid prototyping technology (RPT) has evolved and finds its place in cranioplasty also. RPT was originally developed and used in the automobile industry for the fabrication of prototype of new model. Nowadays, RPT is in clinical use for the fabrication of custom templates, skull templates, and direct prosthesis fabrication.^[2,3] RPT is an additive manufacturing technique which is also known as three-dimensional (3D) printing. Methodologies of 3D printing which are commonly used in dentistry are fused deposition modeling (FDM), selective laser sintering (SLS), stereolithography, and polyjet polymerization. In this technique, resin materials such as nylon, acrylonitrile, acrylonitrile butadiene styrene (ABS), and polylactic acid are added in layers and subsequently cured by ultraviolet (UV) light to form a complete model.

This series of two cases explains two different techniques for the rehabilitation of the patient with frontotemporoparietal cranial defect using RPT. In both cases, decompression craniotomy was performed which leads to defect. Poor neuromuscular control in both cases impedes with the upright posture of the head during conventional impression procedure-made RPT an ideal technique for their rehabilitation. In Case 1, prosthesis was made on a skull template, while in Case 2, direct prototype of the prosthesis was printed using the data of 3D-computed tomography (CT) scan images.

CASE REPORTS

Case 1

A 50-year-old male reported to the Department of Prosthodontics for rehabilitation of cranial defect. A detailed history revealed that the patient had cerebrovascular accident 8 months back. Cranial decompression was planned which led to frontotemporoparietal defect of 10 cm × 15 cm in dimension. Gradually, cerebrospinal fluid (CSF) was accumulated in the defect leading to a diffuse swelling over the temporoparietal region. This diffuse accumulation of CSF made delineation of underlying bony margins difficult and led to inaccurate impression of the defected area. Hence, multidisciplinary approach was planned which involved the role of a neurosurgeon, oral and maxillofacial surgeon, and prosthodontist for cranioplasty with simultaneous CSF drain.

Preparation of skull template

A preoperative CT scan of the patient was made with each slice size of 1 mm × 1 mm [Figure 1a]. Standard tessellation language (STL) images were created from CT scan images with the help of software [Figure 1b]. Then, these STL format images were transferred to the 3D printer. FDM method of RPT was used in both cases as discussed here. In this technique, resin material of acrylonitrile was pulled from pool of resin tank and laid down on the printer platform with the help of an extruder mounted on the printer in layers and cured subsequently by UV light. This extruder can move in 3D axis to form the skull template according to the STL format image [Figure 2a]. The skull template was hollow, so for the fabrication of wax pattern of defect area, a tentative base of paper and aluminum foil was made followed by plaster of paris (POP) (Kaldent, Kalabhai, Karskarson Pvt. Ltd.) base [Figure 2b] over it which acted as a firm base for the wax pattern fabrication [Figure 3a]. This base was made to maintain depth of 3–4 mm for the wax pattern which was carved manually according to the contours of contralateral side. The wax pattern was then made of modeling wax (Y-Dent No 2 Modeling wax, MDM Corp, India) maintaining uniform thickness of 3 mm. Trying of wax pattern was not required in this case as skull template was an exact replica of the skull defect area with no magnification. Hence, direct final prosthesis was made with high precision and accuracy on the skull template in the absence of the patient.

Polymethylmethacrylate cranial prosthesis fabrication

Wax pattern was kept on the skull template till flasking. Before flasking, wax pattern margins were again readapted with a hot wax instrument over the template. All conventional laboratory procedures such as flasking [Figure 3b], dewaxing, packing of the mold in clear heat-cured PMMA (DPI-Heat Cure, Dental Products of India Ltd., India), and curing were performed to transform wax pattern into a biocompatible PMMA prosthesis cured by long curing cycle. In this cycle, the prosthesis was

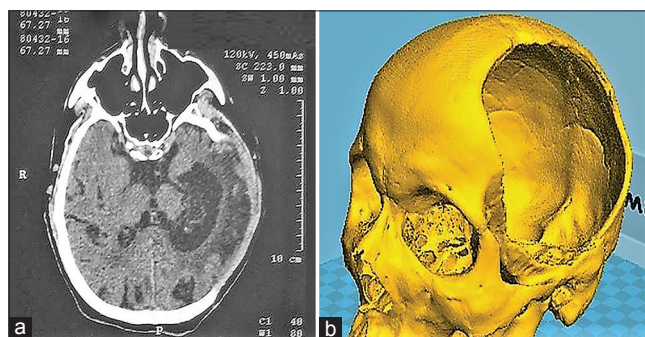


Figure 1: (a) Preoperative computed tomography scan, (b) standard tessellation language images

processed at 74°C water bath for 8 h followed by increasing temperature to 100°C for 1 h. After completion of cycle, flask was cooled slowly to room temperature. In this, flask was removed from the water and bench, cooled for 30 min followed by immersion in tap water for 15 min. Then, the prosthesis was deflasked and prepared for insertion. After finishing and polishing of the prosthesis, numerous holes were made of 1 mm diameter at a distance of 1.5–2 mm apart [Figure 3c]. These perforations prevent the development of an epidural hematoma, permit escape of underlying fluid, and its absorption by the lymphatics and allow for in growth of fibrous connective tissue. The holes also provide a mean for securing prosthesis to underlying bone. Then, prosthesis was immersed in distilled water at 37°C for 24 h to leach out any residual monomer followed by immersion in 2% glutaraldehyde (Cidex OPA, Johnson and Johnson, USA) for 48 h for sterilization.

Surgical placement of the prosthesis

Surgical procedure was carried out under general anesthesia. The planned incision was marked over healthy tissue away from the area of reconstruction. The cutaneous incision was opened in segments and dissection was performed to delineate margins of entire defect. The fit of the margins of the cranial prosthesis was checked and found to be accurate. Then, prosthesis was fixed firmly to the desired area by miniplate fixation. Closure was then performed in layers using vicryl to close the underlying tissues, and finally, the skin was sutured. A drain was placed and removed after 3 days. Postoperative care of surgical site was given to the patient and follow-up appointments were scheduled weekly for 4 weeks to check for postoperative complications. The patient was advised to avoid direct impact on the site of cranioplasty and to maintain the hygiene around the surgical site. On comparison with preoperative view [Figure 4a], patient showed excellent esthetics at the end of 2 weeks postoperatively [Figure 4b].

Case 2

A 45-year-old reported to the department for the correction of cranial defect. A detailed history revealed that the patient had road traffic accident 1 year back which led to cranial defect of the right side of 10 cm × 12 cm in dimension. Glasgow Coma Scale score of the patient was 7, and due to poor neuromuscular control, head position of the patient was not stable which led to impression of defect area difficult. Hence, the patient was planned to rehabilitate using RPT.

Preparation of defect template

In this case, along with the skull template as discussed in the previous case, a template for defect area was also printed

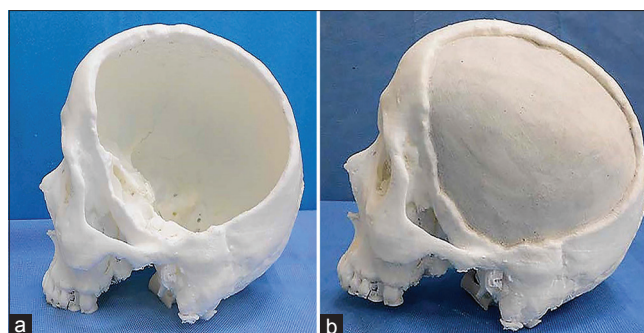


Figure 2: (a) Skull template, (b) template with plaster of paris base

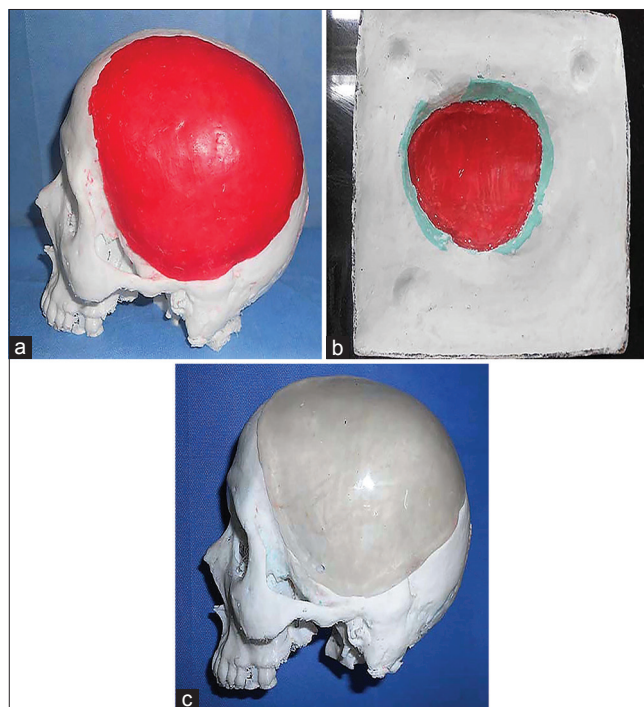


Figure 3: (a) Wax-up, (b) laboratory procedure, (c) finished prosthesis

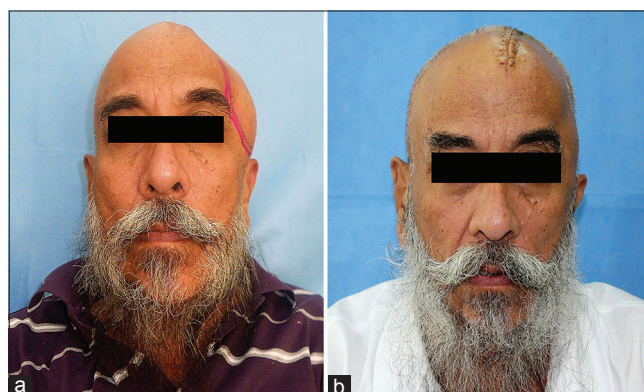

Figure 4: (a) Preoperative, (b) postoperative

[Figure 5a]. In this technique, mirroring of the normal contralateral side was done. Then, the defect area which was digitally reconstructed in the designing software and reconstructed design was printed using RPT [Figure 5b].

After printing, the accuracy of the reconstructed template was checked on the 3D-printed skull [Figure 5c], and minor corrections were done using wax (Y-Dent No 2 Modeling wax, MDM Corp, India).

After this, the reconstructed template was directly flaked in POP (Kaldent, Kalabhai, Karskarson Pvt. Ltd.), dewaxed, and packed with clear heat-cured PMMA resin (DPI-Heat Cure, Dental Products of India Ltd, India) cured using long curing cycle [Figure 6a and b]. Rest, the same procedures were followed as described in the previous case. Postoperative care of surgical site was given to the patient, and follow-up appointments were scheduled weekly for 4 weeks to check for postoperative complications. The patient was advised to avoid direct impact on the site of cranioplasty and to maintain the hygiene around the surgical site. The patient showed excellent esthetics at the end of 2 weeks [Figure 7a and b].

DISCUSSION

Cranioplasty is defined as the surgical repair of acquired defects or congenital deformities of the cranium using biocompatible material. Trauma is one of the most common acquired causes leading to cranioplasty. The main aim of the cranioplasty is to provide protection to the intracranial component and improvement of disfigured esthetics.^[4]

History of cranioplasty starts from 7000 BC. Many materials were used over these years for cranioplasty. These are divided as autografts, allografts, and xenografts. The patient existing cranial bone flap is the most commonly used autograft. Allografts were also used as an alternative to autografts in which cartilage of cadaveric origin was used in initial days. Xenografts were also used in the past for cranioplasty. However, these grafts are not used nowadays apart from autografts.^[5]

Nowadays, synthetic graft materials known as alloplasts are available. Alloplasts are divided as metallic and nonmetallic alloplasts. Metal grafts include aluminum, gold, silver, tantalum, stainless steel, and titanium. On the other hand, nonmetallic alloplasts include celluloids, PMMA, hydroxyapatite, polyethylene, chorale, ceramic, cortoss, carbon-fiber-reinforced-polymer, and recently introduced polyether ether ketone which are used in orthopedics as an implant material.^[6]

PMMA was first used during World War II and the most common allograft used in cranioplasty.^[7] Main advantages of PMMA over metallic alloplast are easy to shape, inert, nonmagnetic, lightweight, and economical.^[8,9]

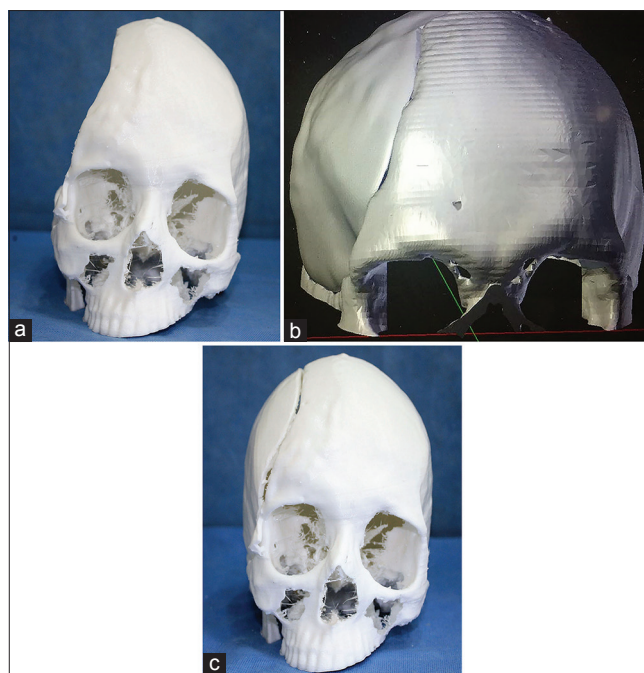


Figure 5: (a) Skull template, (b) digitally reconstructed defect area, (c) skull template with reconstructed area

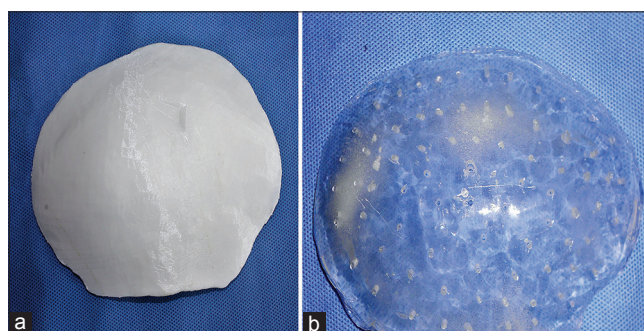


Figure 6: (a) Reconstructed template, (b) finished prosthesis

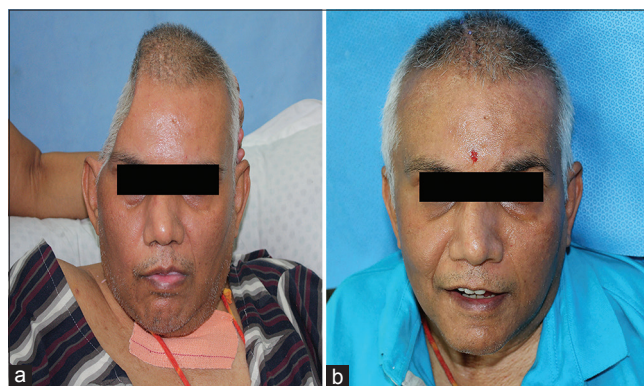

Figure 7: (a) Preoperative, (b) postoperative

Conventional technique is usually used for rehabilitation of cranial defects which is an extensive procedure and includes clinical and laboratory steps. But its application is limited in cases where precise delineation of underlying bony margins is difficult as it may compromise fit of prosthesis.

In recent times, 3D printing gives a promising solution in treating patients of larger defects with precision. Some principles of RPT which are commonly used in dentistry are SLS, FDM, stereolithography, and polyjet photopolymerization.^[10-12] RPT has shown promising results in maxillofacial reconstruction, orthognathic surgeries, craniosynostosis, maxillofacial tumor surgeries, and cranioplasties.

The skull template was made in both cases which was made using FDM for the fabrication of prosthesis. This additive technology utilizes the addition of resin materials such as nylon and acrylonitrile in layer-wise manner to complete formation of template. However, advantages of RPT over conventional technique are as follows: (a) impression of cranium is not required, (b) no wastage of material, (c) superior esthetics, (d) accurate prosthesis in terms of fit and dimensions of defect, (e) less time consuming, and (f) less intraoperative time.^[13] Out of two techniques, in Case 1, skull template was used, on which wax pattern was made, but in Case 2, the defect area was digitally reconstructed and designed part was printed separately along with the skull template. Less intraoperative corrections were required in Case 2 as a uniform thickness of prosthesis was ensured which was designed digitally as compared to the first case as prosthesis was carved manually, and readaptation of wax pattern is required before flasking. Furthermore, no wax pattern was used in Case 2, and hence, manufacturing errors associated with distortion of wax pattern was avoided. Less time is required for the fabrication of prosthesis in Case 2 as fewer number of steps were involved as compared to the previous case. Main strengths of these techniques are as follows: (a) it utilizes RPT which is a digital and additive technique for the fabrication of skull template with high accuracy and precision, (b) fewer chances of incorporation of errors, (c) fewer steps are involved in fabrication hence less time consuming, and (d) no wastage of material as this is an additive manufacturing technique as compared to CAD/CAM. Whereas, limitations are (a) this technique is costly and requires a specialized setup with trained personnel for the designing and printing of models and (b) biocompatible 3D printable alloplastic materials are not available except for titanium. The informed consent was obtained from both the patients for publication.

Takeaway lessons

- a. RPT is a new technique which can be used for the fabrication of models with high accuracy and precision
- b. RPT provides fabrication of prosthesis which requires less intraoperative corrections and less intraoperative time

- c. Provide prosthesis which yields excellent esthetics postoperatively
- d. Fewer chances of errors as fewer steps are involved as compared to conventional techniques.

CONCLUSION

RPT is the advanced and predictive method of fabrication of prosthesis for rehabilitating patients with large cranial defects. Accuracy, safe, no wastage of material, and superior esthetics are few major advantages of this technique. Infection is the most feared complication of allograft implants; however, PMMA is biocompatible and most widely used. The integration of latest and superior technology with the biocompatible material results in the fabrication of prosthesis which is safe and has yielded excellent results.

Declaration of patient consent

The authors certify that they have obtained all appropriate patient consent forms. In the form, the patient has given his consent for his images and other clinical information to be reported in the journal. The patient understand that name and initials will not be published and due efforts will be made to conceal identity, but anonymity cannot be guaranteed.

Financial support and sponsorship

Nil.

Conflicts of interest

There are no conflicts of interest.

REFERENCES

1. Caro-Osorio E, De la Garza-Ramos R, Martínez-Sánchez SR, Olazarán-Salinas F. Cranioplasty with polymethylmethacrylate prostheses fabricated by hand using original bone flaps: Technical note and surgical outcomes. *Surg Neurol Int* 2013;4:136.
2. Parthiban JK, Abirami O, Murugan AM, Radhakrishnan R. Custom cranioplasty using rapid prototyping technology. *Neurol India* 2004;52:520.
3. D'Urso PS, Earwaker WJ, Barker TM, Redmond MJ, Thompson RG, Effenev DJ, *et al.* Custom cranioplasty using stereolithography and acrylic. *Br J Plast Surg* 2000;53:200-4.
4. Arun Kumar KV, Singla NK, Gowda ME, Kumar D, Legha VS. Current concepts in restoring acquired cranial defects. *J Indian Prosthodont Soc* 2014;14:14-7.
5. Aydin S, Kucukyuruk B, Abuzayed B, Aydin S, Sanus GZ. Cranioplasty: Review of materials and techniques. *J Neurosci Rural Pract* 2011;2:162-7.
6. Joseph TM, Ravichandran R, Harshakumar K, Lylajam S. Prosthetic rehabilitation in neurosurgical cranioplasty. *J Indian Prosthodont Soc* 2018;18:76-81.
7. Zoltan B, Gabor T, Istvan H. Substitution of skull defects with methyl methacrylate. *Magy traumatol Orthop Helyreallito Seb* 1976;19:259-68.
8. Van Gool AV. Performed polymethyl methacrylate cranioplasties. *J Maxillofac Surg* 1985;13:2-8.
9. Goyal S, Goyal MK. Restoration of large cranial defect for cranioplasty

- with alloplastic cranial implant material: A case report. *J Indian Prosthodont Soc* 2014;14:191-4.
10. Groth C, Kravitz ND, Jones PE, Graham JW, Redmond WR. Three-dimensional printing technology. *J Clin Orthod* 2014;48:475-85.
 11. van Putten MC Jr., Yamada S. Alloplastic cranial implants made from computed tomographic scan-generated casts. *J Prosthet Dent* 1992;68:103-8.
 12. Gupta L, Aparna I, Balakrishnan D, Deenadayalan L, Hegde P, Agarwal P, *et al.* Cranioplasty with custom made alloplastic prosthetic implant: A case report. *World J Clin Cases* 2014;2:482-7.
 13. Tack P, Victor J, Gemmel P, Annemans L 3D-printing techniques in a medical setting: A systematic literature review. *Biomed Eng Online* 2016;15:115.