

Lymphovascular invasion in testicular germ cell tumors: clinicopathological correlates

Ofer Yossepowitch, Yaron Ehrlich, Marc Lubin, Raanan Tal, Miriam Konichezsky, Jack Baniel

Institute of Urology and Department of Pathology (MK), Rabin Medical Center, Beilinson Campus, Petach Tikva, and Sackler Faculty of Medicine, Tel Aviv University, Tel Aviv, Israel

Article history

Submitted: June 17, 2013

Accepted: Aug. 20, 2013

Correspondence

Ofer Yossepowitch
Institute of Urology
Rabin Medical Center,
Beilinson Campus
Petach Tikva 49100, Israel
phone: +972 3 937 6553
oferyoss@netvision.net.il

Introduction. We assessed clinical–pathological correlates of lymphovascular invasion in testicular germ–cell tumors.

Material and methods. Archived pathology specimens from 145 patients treated by radical orchiectomy for testicular germ cell tumors at our institution in 1995–2006 were reanalyzed by a dedicated urologic pathologist, and the corresponding medical records were reviewed. The association of lymphovascular invasion with clinical and pathological parameters was tested using stepwise logistic regression analysis.

Results. Lymphovascular invasion was identified in 38 (26%) patients and was associated with younger age, testicular pain at presentation, elevated serum tumor markers, nonseminoma histology, and advanced clinical stage. Orchalgia was indicated as the impetus for referral in 67 (46%) patients and characterized as a dull aching sensation, persistent or intermittent in nature. Among the 98 men diagnosed with clinical stage I, those presenting with testicular pain had a 1.8X–higher likelihood of lymphovascular invasion than those without pain (95% CI 1.13–14.9, $p = 0.02$), and patients with elevated serum tumor markers had an 8.5–fold increased probability of lymphovascular invasion than those presenting with normal tumor markers (CI 1.1–54.2, $p = 0.05$). Among men with nonseminoma histology, elevated tumor markers was the strongest predictor of lymphovascular invasion in both univariate and multivariate analyses (OR 5.05, 95% CI 1.16–21.8, $p = 0.03$).

Conclusion. Providing pathologists with information on pre–orchiectomy tumor marker levels and, possibly, testicular pain at presentation may increase their vigilance in searching for lymphovascular invasion, potentially improving their diagnostic accuracy. Whether it may also translate into improved oncological outcomes needs further evaluation.

Key Words: testis cancer ◊ germ cell tumors ◊ lymphovascular invasion ◊ risk factors staging

INTRODUCTION

For men diagnosed with clinical stage I testicular cancer, invasion of tumor cells into blood and lymphatic vessels is the strongest predictor of occult metastasis [1, 2]. Patients with clinical stage I nonseminomatous germ–cell tumor (NSGCT) and lymphovascular invasion (LVI) face a 3–year risk of relapse of approximately 50%. This decreases to 10–20% if LVI is absent [2, 3]. National and international guidelines recommend that LVI is used for risk–adapted management of patients in this setting [4, 5]. In fact, testicular cancer is the only malignancy in urologic

oncology that integrates LVI into the TNM staging system as an independent adverse prognosticator, upstaging the T category from T1 (LVI absent) to T2 (LVI present) in an otherwise organ confined tumor. While information on LVI is a uniformly acknowledged as essential to patient counseling, its recognition by pathologists has been hampered by interobserver variability. Several studies have demonstrated discordance between pathologists in interpreting the presence of LVI at the morphologic level, highlighting the value of a central pathology review for this purpose [6–9]. In one report, for example, 54 of 414 specimens were observed to have LVI by the local pathologist, while

Table 1. Clinical–pathological characteristics in 145 men with testicular germ cell tumors stratified by vascular invasion status

Parameter	Vascular Invasion (n = 38)	No Vascular Invasion (n = 107)	P value
Age at orchiectomy (yrs.), mean \pm SE	31.9 \pm 1.6	35.5 \pm 1	0.03
Testicular pain at presentation (%)			
Yes	23 (61)	44 (41)	0.03
No	15 (39)	63 (59)	
Duration of symptoms*			
<1 month	4	14	0.44
1–2 months	11	16	
2–6 months	6	8	
6–12 months	2	3	
>1 year	–	3	
Serum tumor markers			
Elevated	28 (74)	47 (44)	0.002
Normal	10 (26)	60 (56)	
Histology			
Seminoma	11 (29)	71 (66)	<0.001
Non–seminoma	27 (71)	36 (33)	
Clinical stage			
Stage I	19 (50)	79 (74)	0.007
Stage II–III	19 (50)	28 (26)	
Tumor necrosis			
Negative	14 (37)	60 (56)	0.1
Focal	16 (42)	28 (26)	
Diffused	8 (11)	19 (18)	
Carcinoma <i>in situ</i>			
Present	26 (68)	71 (66)	0.81
Absent	12 (32)	36 (34)	
Multifocality			
Yes	9 (24)	39 (36)	0.15
No	29 (76)	68 (64)	
Tumor size (cm), mean \pm SE	4.31 \pm 0.31	4.56 \pm 0.24	0.28

*Includes the 67 patients who presented with testicular pain

central pathology review of the same cohort recognized LVI in 179 specimens [8]. Theoretically, any recognized clinical or pathological element associated with the presence of LVI might increase the vigilance of pathologists searching for this finding and potentially improve their overall diagnostic accuracy. With this in mind we sought to assess clinicopathological correlates of LVI in men with testicular germ cell tumors.

METHODS

The study cohort was comprised of 145 patients with testicular germ cell tumors who underwent radical orchiectomy at a tertiary university–affiliated medical center in 1995 to 2006. All orchiectomy specimens were processed and analyzed at our institution and only patients for whom complete clinical information was available were included. After obtaining approval from our institutional ethics committee, a single dedicated uropathologist (MK) reanalyzed the

archived tumor tissue of each patient as well as sections of the healthy uninvolved parenchyma. In 21 cases, additional sections from the paraffin blocks were obtained during the review process.

Clinical and pathological characteristics were retrieved from a retrospectively assembled database and categorized in accordance with standard classification systems. Vascular invasion was defined by one of the two following morphologic criteria: i) tumor cells clearly adherent to a vessel wall or ii) tumor cells filling a space lined by flat endothelial cells, which contains concomitant red blood cells (Figure 1); in the absence of red blood cells, lymphatic invasion was determined. We used the term lymphovascular invasion generically to include the presence of either vascular or lymphatic invasion. Tumor diameter was defined as the largest dimension measured by the pathologist prior to specimen fixation. Multifocality was defined as neoplastic germ cells scattered within normal–appearing testicular parenchyma outside the index mass [10].

For statistical analysis we used Stata version 10.1 (Stata Corporation, College Station, TX). Clinical and pathological data are reported using descriptive statistics. Associations between LVI and the various clinical and pathological parameters were tested using the chi-squared test for categorical variables and the Wilcoxon rank-sum test for continuous variables. Backward stepwise logistic regression analysis was used for multivariate analysis including all predictors found significant on univariate analysis. All statistical tests were two-sided; $p < 0.05$ was considered significant.

RESULTS

Clinical and pathological characteristics of the study cohort are provided in Table 1. Overall, LVI was detected in 38 (26%) men. Patients with LVI were characterized by younger age ($p = 0.03$), testicular pain at presentation (61% in those with *vs.* 41% in those without LVI, $p = 0.03$), elevated preorchectomy se-

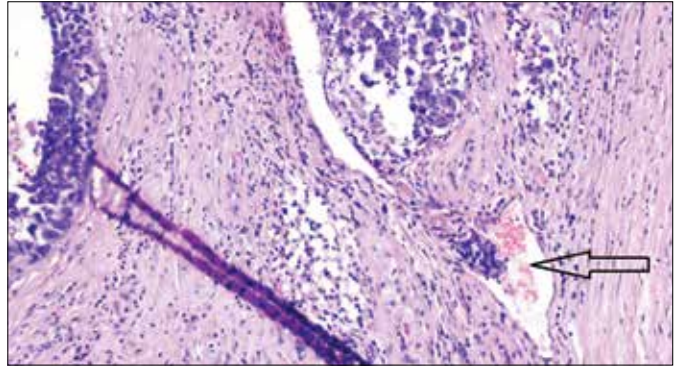


Figure 1. Lymphovascular invasion in nonseminomatous testicular germ cell tumor (H&E, original magnification $\times 100$). Arrow indicates intraluminal cancer cells adjacent to red blood cells.

rum tumor markers ($p = 0.002$), nonseminoma histology ($p < 0.001$), and advanced clinical stage ($p = 0.007$). Orchalgia was reported in 67 (46%) patients

Table 2. Clinical-pathological characteristics in 63 men with nonseminomatous germ cell tumors stratified by vascular invasion status

Parameter	Vascular Invasion (n = 27)	No Vascular Invasion (n = 36)	P value
Age at orchiectomy (yrs.), mean \pm SE	29 \pm 1.7	30 \pm 1.3	0.08
Testicular pain at presentation (%)			
Yes	17 (63)	15 (42)	0.05
No	10 (37)	21 (58)	
Duration of symptoms*			
<1 month	6	17	0.08
1–2 months	10	11	
2–6 months	8	3	
6–12 months	3	3	
>1 year		2	
Serum tumor markers			
Elevated	22 (81)	25 (69)	0.04
Normal	5 (19)	11 (31)	
Clinical stage			
Stage I	10 (37)	25 (70)	0.01
Stage II–III	17 (63)	11 (30)	
Tumor necrosis			
Negative	9 (33)	18 (50)	0.09
Focal	14 (51)	9 (25)	
Diffused	4 (16)	9 (25)	
Carcinoma <i>in situ</i>			
Present	20 (74)	26 (72)	0.87
Absent	7 (26)	10 (28)	
Multifocality			
Yes	7 (26)	15 (41)	0.19
No	20 (74)	21 (59)	
Tumor size (cm), mean \pm SE	4.03 \pm 0.35	4.73 \pm 0.36	0.18
Tumor size (cm), mean \pm SE	4.31 \pm 0.31	4.56 \pm 0.24	0.28

*Includes the 32 patients who presented with testicular pain

Table 3. Predictors of LVI in 98 patients with clinical stage I testicular germ cell tumors

Univariate analysis		Multivariate analysis	
p Value	Odds Ratio (95% CI)	p Value	Odds Ratio (95% CI)
Age	0.15	0.95 (0.88, 1.05)	0.89
Pain at presentation (present vs. absent)	0.02	1.8 (1.13, 14.9)	0.92
Serum tumor markers (elevated vs. normal)	0.05	8.5 (1.1, 54.2)	0.05
Histology (nonseminoma vs. seminoma)	0.02	13.1 (2.5, 68)	0.01

as the impetus for referral and characterized as a dull aching sensation, either persistent or intermittent in nature. Pain at presentation was also associated with the presence of diffuse tumor necrosis (63% of men presenting with pain *vs.* 37% without pain, $p = 0.01$). However, there was no association between tumor necrosis and the finding of LVI. Similarly, tumor size, the presence of multifocality, and duration of symptoms were not associated with LVI (Table 1). Of the 63 men diagnosed with nonseminoma histology, 32 (50%) presented with testicular pain and 47 (74%) with elevated serum tumor markers (Table 2). In this subset of patients, pain at presentation, elevated tumor markers, and higher clinical stage maintained an association with the presence LVI.

Table 3 shows the results of univariate and multivariate analyses to identify predictors of LVI in the 98 men with clinical stage I at diagnosis. Men with testicular pain had a 1.8X-higher likelihood of LVI than those without pain (95% CI 1.13–14.9, $p = 0.02$), and patients with elevated serum tumor markers had an 8.5-fold increased probability of LVI than those presenting with normal tumor markers (CI 1.1–4.2, $p = 0.05$). Using multivariate backward logistic regression the findings of elevated markers and nonseminoma histology were significant predictors of LVI, but pain at diagnosis was not (Table 3). In the group of men diagnosed with nonseminoma histology, the presence of elevated tumor markers at presentation was a strong predictor of LVI on both univariate and multivariate analyses (OR 5.05, 95% CI 1.16–21.8, $p = 0.03$), controlling for age, pain at presentation, and clinical stage (Table 4).

DISCUSSION

In men diagnosed with clinical stage I testicular germ cell tumor, LVI in the orchiectomy specimen has long been established as an independent risk factor for occult metastases, leading to an almost fourfold increase in the risk of retroperitoneal disease [11, 12]. While the optimal management for these men remains contentious, many urologists and oncologists employ a risk-adapted strategy based on the presence or absence of LVI. [13]However, obtaining accurate information on the status of LVI is still considered a major hurdle in genitourinary pathology [6, 7, 8, 14]. We therefore endeavored to identify clinical parameters that might enhance the diagnostic accuracy of pathologists searching for LVI and potentially improve patient outcome.

In the present study, LVI was identified in 38 of 145 testicular germ cell tumor specimens (26%). Predictors of the presence of LVI included younger age, testicular pain, and abnormal serum tumor markers at presentation, the latter being the strongest predictor of LVI in multivariate analyses (OR 5.05), both in the overall study population and in those diagnosed with nonseminoma. Notably, in the subset of men with nonseminoma histology, LVI was associated with a more advanced clinical stage, confirming the prior association between LVI and increased risk of retroperitoneal metastases. Taken together, our data suggest that information on levels of preorchiectomy tumor markers and, possibly, on testicular pain at presentation should be provided to pathologists reviewing the specimen [6, 14], and used as an indi-

Table 4. Predictors of LVI in 63 patients with nonseminomatous testis cancer

Univariate analysis		Multivariate Analysis	
p Value	Odds Ratio (95% CI)	p Value	Odds Rati (95% CI)
Age	0.75	0.99 (0.93, 1.05)	0.71
Pain at presentation (present vs. absent)	0.06	1.12 (1.02, 6.38)	0.19
Serum tumor markers (elevated vs. normal)	0.04	3.8 (1.03, 14.7)	0.03
Clinical stage (II / III vs. I)	0.01	3.86 (1.34, 11.09)	0.27

cator for meticulous assessment of LVI. To the best of our knowledge, the relationship between tumor marker levels and LVI has never been described. The critical role of serum tumor markers in the diagnosis, treatment, and monitoring of testis cancer patients cannot be overstated. For example, an elevated alpha fetoprotein in a seemingly pure seminoma is used to reclassify the tumor as nonseminoma and changing management accordingly; in those under surveillance, rising tumor markers are considered an early indicator of relapse used to modify the treatment strategy; and in the setting of metastatic disease the marker levels are used to risk stratify patients and guide chemotherapy dosage and regimen [4, 5]. Remarkably, however, the implications of abnormal tumor markers in patients with an otherwise organ-confined tumor (i.e., markers have normalized following orchiectomy) have been less evident. Our data suggest that with this clinical finding there is an increased likelihood of occult LVI and, as such, pathologists should employ extra vigilance in scrutinizing the tumor tissue. Moreover, based on outcomes from the SWENOTECA study [3] along with our findings, a risk adapted strategy that considers elevated preorchiectomy serum tumor markers as an additional risk factor in clinical stage I NSGCT would seem

sensible. Whether treating these men with adjuvant chemotherapy may translate into improved oncological outcomes needs further investigation.

This study remains limited by its retrospective design and relatively small and heterogeneous cohort. Admittedly, accurate determination of the LVI status based solely on H&E stained specimens remains challenging even in hands of dedicated urologic pathologists [15]. Future studies should explore novel molecular markers or genomic alterations that might improve the prediction of retroperitoneal relapse in men with clinical stage I testicular cancer beyond morphologic criteria [16], thus allowing a more accurate risk-adapted approach.

CONCLUSIONS

Accurate determination of the lymphovascular invasion status in testicular germ cell tumors remains a challenge. Providing pathologists with information on preorchiectomy tumor marker levels and, possibly, testicular pain at presentation may increase their vigilance in searching for lymphovascular invasion, potentially improving their diagnostic accuracy. Whether it may also translate into improved oncological outcomes needs further evaluation.

References

- Albers P, Siener R, Kliesch S, Weissbach L, Krege S, Sparwasser C, et al. Risk factors for relapse in clinical stage I nonseminomatous testicular germ cell tumors: results of the German Testicular Cancer Study Group Trial. *J Clin Oncol.* 2003; 21: 1505.
- Valdevenito JP, Gallegos I, Fernández C, Acevedo C, Palma R. Correlation between primary tumor pathologic features and presence of clinical metastasis at diagnosis of testicular seminoma. *Urology.* 2007; 70: 777.
- Tandstad T, Dahl O, Cohn-Cedermark G, Solberg A, Stienen U, Cavallin-Stahl E, et al. Risk-adapted treatment in clinical stage I nonseminomatous germ cell testicular cancer: the SWENOTECA management program. *J Clin Oncol.* 2009; 27: 2122.
- Motzer R J, Agarwal N, Beard C, Carducci MA, Boston B, Bolger GB, et al. NCCN clinical practice guidelines in oncology: testicular cancer. *J Natl Compr Canc Netw.* 2009; 7: 672.
- Albers P, Albrecht W, Algaba F, Bolemeier C, Cohn-Cedermark, Fizazi K, et al. EAU guidelines on testicular cancer: 2011 update. *Eur Urol.* 2011; 60: 304.
- Delaney RJ, Sayers CD, Walker MA, Mead GM, Theaker JM: The continued value of central histopathological review of testicular tumours. *Histopathology.* 2005; 47: 166.
- Wayment RO, Bourne A, Kay P, Tarter TH. Second opinion pathology in tertiary care of patients with urologic malignancies. *Urol Oncol.* 2011; 29: 194.
- Sesterhenn IA, Weiss RB, Mostofi FK, Falkson G, Rowland RG, Stablein DM, et al. Prognosis and other clinical correlates of pathologic review in stage I and II testicular carcinoma: a report from the Testicular Cancer Intergroup Study. *J Clin Oncol.* 1992; 10: 69.
- Segelov E, Cox K M, Raghavan D, McNeil E, Lancaster L, Rogres J. The impact of histological review on clinical management of testicular cancer. *Br J Urol.* 1993; 71: 736.
- Ehrlich Y, Konichezky M, Yossepowitch O, Baniel J. Multifocality in testicular germ cell tumors. *J Urol.* 2009; 181: 1114.
- Williams SB, Kacker R, Winston D, Bahnson E, Steele GS, Richie JP. Predictors of positive retroperitoneal lymph nodes in patients with high risk testicular cancer. *J Urol.* 2011; 186: 2245.
- Stephenson AJ, Bosl GJ, Bajorin DF, Stasi J, Motzer RJ, Sheinfeld J. Retroperitoneal lymph node dissection in patients with low stage testicular cancer with embryonal carcinoma predominance and/or lymphovascular invasion. *J Urol.* 2005; 174: 557.
- Foster RS: Role of urologist in testis cancer management. *J Urol.* 2011; 186: 2151.
- Nicolai N, Colecchia M, BIASONI D, Catanzaro M, Stagni S, Torelli T, et al. Concordance and prediction ability of original and reviewed vascular invasion and other prognostic parameters of clinical stage I nonseminomatous germ cell testicular tumors after retroperitoneal lymph node dissection. *J Urol.* 2011; 186: 1298.
- Reuter VE: Lymphovascular invasion as an independent predictor of recurrence and survival in node-negative bladder cancer remains to be proven. *J Clin Oncol.* 2005; 23: 6450.
- Gilbert DC, Chandler I, Summersgill B, McIntyre A, Missiaglia E, Goddard NC, et al. Genomic gain and over expression of CCL2 correlate with vascular invasion in stage I non-seminomatous testicular germ-cell tumours. *Int J Androl.* 2011; 34: e114. ■