

Technetium-99m dimercaptosuccinic acid scan in evaluation of renal cortical scarring: Is it mandatory to do single photon emission computerized tomography?

Hussein Rabie Saleh Farghaly^{1,2}, Mohamed Hosny Mohamed Sayed¹

¹Department of Clinical Oncology and Nuclear Medicine, Faculty of Medicine, Assiut University, Assiut, Egypt, ²Department of Radiology, Division of Nuclear Medicine, Prince Sultan Military Medical City, Riyadh, Saudi Arabia

ABSTRACT

Objectives: Renal cortical scintigraphy with technetium-99m (Tc-99m) dimercaptosuccinic acid (DMSA) is the method of choice to detect acute pyelonephritis and cortical scarring. Different acquisition methods have been used: Planar parallel-hole or pinhole collimation and single photon emission tomography (SPECT). This study compared planar parallel-hole cortical scintigraphy and dual-head SPECT for detection of cortical defects. **Patients and Methods:** We retrospectively reviewed 190 consecutive patients with 380 kidneys and 200 DMSA scans referred to rule out renal cortical scarring. The diagnoses were 52 vesicoureteric reflux, 61 recurrent urinary tract infection, 39 hydronephrosis, 20 renal impairment, and 18 hypertension. All patients were imaged 3 h after injection of Tc-99m DMSA with SPECT and planar imaging (posterior, anterior, left, and right posterior oblique views). For each patient, planar and SPECT images were evaluated at different sittings, in random order. Each kidney was divided into three cortical segments (upper, middle and lower) and was scored as normal or reduced uptake. The linear correlation coefficient for the number of abnormal segments detected between planar and SPECT techniques was calculated. **Results:** From 200 DMSA scans, 100 scans were positive for scar in SPECT images, from which only 95 scans were positive for scar in planar imaging. Out of the five mismatched scans, three scans were for patients with renal impairment and high background activity and two scans were for very small scars. No significant difference was seen in the average number of abnormal segments detected by planar versus SPECT imaging ($P = 0.31$). The average correlation coefficient between was high ($r = 0.91 - 0.92$). **Conclusions:** Tc-99m DMSA renal cortical scanning using SPECT offers no statistically significant diagnostic advantage over multiple views planar imaging for detection of cortical defect.

Keywords: Cortical scarring, dimercaptosuccinic acid, dual-head single photon emission tomography

INTRODUCTION

Urinary tract infection (UTI) is a relatively frequent disease in children, and diabetic individuals with increased risk of renal scarring.^[1,2] Renal cortical scintigraphy with technetium-99m (Tc-99m) dimercaptosuccinic acid (DMSA)

has become “the gold slandered” for renal cortical scarring imaging.^[3] Different acquisition methodologies have been used, including planar parallel-hole collimator imaging, pinhole collimator imaging, single photon emission computerized tomography (SPECT) and pinhole SPECT (PSPECT).^[4,5] Controversy exists regarding the superiority of Tc-99m DMSA SPECT over planar imaging. The purpose of the current study was to compare planar parallel-hole cortical scintigraphy and dual-head SPECT for detection of cortical defects.

PATIENTS AND METHODS

We retrospectively reviewed 190 consecutive patients, including 106 female and 84 male with 380 kidneys and

Access this article online

Quick Response Code:



Website:
www.ijnm.in

DOI:
10.4103/0972-3919.147530

Address for correspondence:

Dr. Hussein Rabie Saleh Farghaly, Department of Radiology, Division of Nuclear Medicine, Prince Sultan Military Medical City, Riyadh, Saudi Arabia. E-mail: hussen2h@yahoo.com

200 DMSA scans referred to our division to rule out renal cortical scarring. Age range was 7 months to 81 years (mean age, 31.6 ± 23 year). The diagnoses were 52 vesicoureteric reflux (VUR), 61 recurrent UTI, 39 hydronephrosis, 20 renal impairment and 18 hypertension. None of them had any clinical evidence of acute pyelonephritis at the time of DMSA scan.

Technetium-99m DMSA was prepared from a commercial kit (Amerscan DMSA agent, Nycomed Amersham plc, Little Chalfont, Buckinghamshire, UK). All adult patients were injected with 5 mCi (185 MBq) of Tc-99m DMSA. Children were injected with a weight-adjusted dose of Tc-99m DMSA based on the maximal dose of Tc-99m DMSA of 5 mCi (185 MBq). The minimum administered dose was 1 mCi (37 MBq).

All studies were acquired 3 h after Tc-99m DMSA injection, in a supine position using a rotating, large field-of-view, dual-head gamma camera (Infinia; GE Healthcare) fitted with a low-energy, high-resolution collimator, and set at 140 keV with a 20% energy window. Planar images were acquired, in four projections including anterior, posterior, right posterior oblique, and left posterior oblique views of kidneys, for 600 s or 500,000 counts/image in a 256×256 matrix, include kidneys and bladder in view. All children aged 7 months to 4 years were sedated before the study with either oral chloral hydrate or intravenous pentobarbital.

Single photon emission tomography images were acquired immediately after planar images. Gamma camera heads are mounted at 180° , and acquisition parameters used a 128×128 matrix, a contour orbit, 360° rotation, 3° /rotation, 64 views/head, 20 s/view, no zoom was applied for patients older than 10 years and a zoom of 1.60 was applied for patients younger than 10 years. The imaging field was centered on the kidneys to include from the xiphoid process to the symphysis pubis. Reconstruction was performed using a Butterworth postfilter (cutoff frequency, 0.6 cm^{-1} ; power, 10), generate sagittal, coronal, and transaxial slice.

Each Tc-99m DMSA scan was examined by the agreement of two experienced nuclear medicine physicians blind to clinical and laboratory data. Planar and SPECT images were evaluated at different sittings, in random order. Each kidney was divided into three cortical segments (upper, middle and lower) and was scored as normal or reduced uptake. The images were interpreted according to the following parameters. Normal Tc-99m DMSA renal cortex scan findings were: (1) Normal contour, defined as smooth and continuous without indentations; (2) homogeneous parenchymal uptake in all regions of both kidneys; and (3) normal size and uniform shape of both kidneys. Abnormal Tc-99m DMSA renal cortex scan findings were: (1) Single or multiple, focal or diffuse areas of decreased or completely absent activity in the renal cortex; (2) diffuse or sharp indentation in contour with thinning of renal cortex; and (3) loss of renal cortex volume.

Statistical analysis

All data were analyzed using MedCalc version 11 (MedCalc Software bvba, Mariakerke, Belgium). Data are presented as mean and standard deviation (SD) ($\text{mean} \pm \text{SD}$), and as range. The linear correlation coefficient for the number of abnormal segments detected between planar and SPECT techniques was calculated. $P < 0.05$ was considered as significant.

RESULTS

From 200 DMSA scans, 100 scans were negative for scar in both SPECT and planar imaging, the other 100 scans were positive for scar in SPECT images, from which only 95 scans were positive for scar in planar imaging [Figure 1], and five mismatched scans between SPECT and planar imaging [Figure 2]. Out of these five mismatched scans, three scans were for patients with renal impairment and high background activity and two scans were for very small scars.

A total of 225 renal scars were identified in SPECT images, and 220 were identified in planar images. More than 79% of defects were located in both upper and lower poles of both

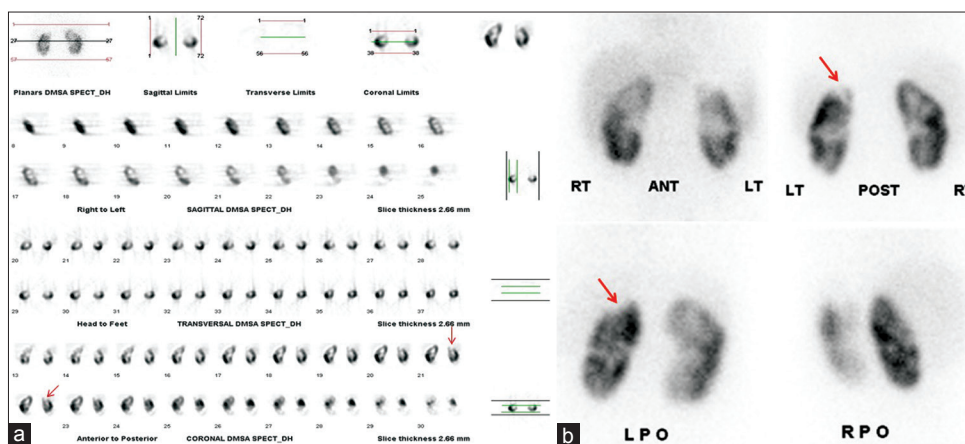


Figure 1: Technetium-99m dimercaptosuccinic acid renal scan showed evidence of cortical scar (arrowed) in both single photon emission tomography (a) and planar imaging (b)

kidneys [Table 1, and Figure 3]. No significant difference was seen in the average number of abnormal segments detected by planar versus SPECT imaging ($P = 0.31$, two-tailed). The average correlation coefficient between techniques (dual-head SPECT and planar imaging) was high ($r = 0.91 - 0.92$).

DISCUSSION

Urinary tract infection is a relatively frequent disease in children, and diabetic individuals with increased risk of renal scarring.^[1,2] The prevalence of UTI as well as renal scarring was significantly higher in females, when compared to male diabetics.^[2] The core imaging modalities advocated after a UTI have been ultrasonography, voiding cystourethrography, and Tc-99m

DMSA scan renal scintigraphy. The reason for imaging is to detect obstructive malformations, VUR, and renal parenchymal damage.^[6] Renal cortical scintigraphy with Tc-99m DMSA has become the mainstay of evaluation for renal cortical scarring.^[7] Different acquisition methodologies have been used, including planar parallel-hole collimator imaging, planar high-resolution parallel-hole collimator imaging, pinhole collimator imaging, SPECT and PSPECT.^[4,5]

All over the world, SPECT imaging is widely implemented in nuclear medicine as its clinical role in the diagnosis and management of several diseases is very helpful.^[8] Tc-99m DMSA SPECT is recommended to be used instead of or complementarily to planar scintigraphy especially in pediatrics to help with early diagnosis, follow-up, and monitoring of the effects of treatment in acute pyelonephritis and possible scars formation.^[9-11] However, controversy exists regarding the superiority of Tc-99m DMSA SPECT over planar imaging.

Due to the diversity of techniques, differing results,^[12] small cohort of patients in previous studies, and the limited number of comparative studies had been published; we think that the controversy regarding the superiority of Tc-99m DMSA SPECT over planar imaging needs to be further investigated. Thus, we conducted our study using random order for image interpretation at different sittings to avoid any bias caused by initial readings in one technique over a reading in the other technique.

Although, we found more defects in dual-head SPECT compared with high-resolution planar imaging (225 vs. 220), no significant difference was seen in the average number of abnormal segments detected by planar versus SPECT imaging ($P = 0.31$, two-tailed). The average correlation coefficient for SPECT alone, planar imaging alone, and between techniques (SPECT vs. planar imaging) was high ($r = 0.91 - 0.92$). Our results are consistent with those reported by Brenner *et al.*,^[5] who compared Tc-99m DMSA renal cortical imaging using dual-head SPECT with planar imaging and found that dual-head SPECT offers no statistically significant diagnostic advantage over planar imaging for detection of cortical defects. Similarly, Everaert *et al.*^[13] found more defects

Table 1: Segmental distribution of renal cortical defects in planar and single photon emission tomography images

Segments	Number of scars in planner imaging	Number of scars in SPECT
Left upper	55	56
Right upper	48	50
Left middle	31	31
Right middle	15	16
Left lower	35	36
Right lower	36	36

SPECT: Single photon emission computerized tomography

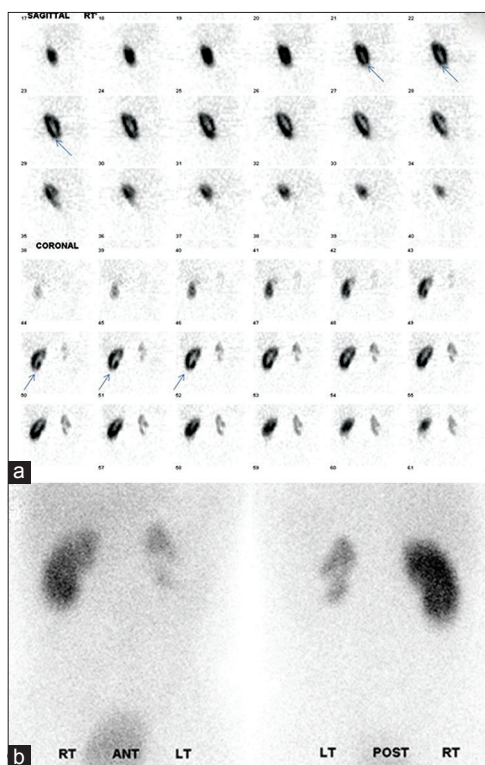


Figure 2: Technetium-99m dimercaptosuccinic acid renal scan of patient with renal impairment and diabetes mellitus showed evidence of cortical scar at the lower pole of right kidney (arrowed) in single photon emission tomography (SPECT) images (a), high background activity and homogenous radiotracer uptake by right kidney in planner imaging (b), as well as small, scarred left kidney in both SPECT and planner images. The absolute percentage dose uptake for left kidney was (1.45%), and for right kidney was (6.89%)

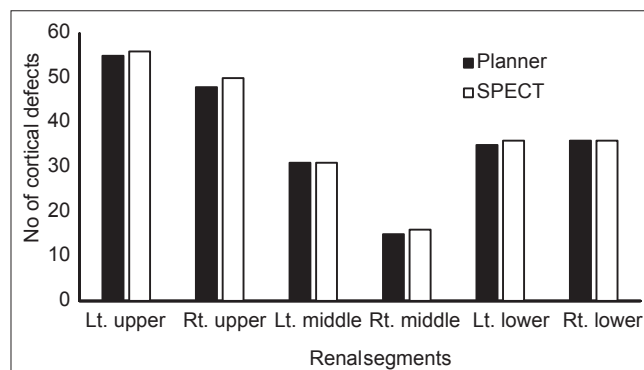


Figure 3: Segmental distribution of renal cortical defects in planner and single photon emission tomography images

detected by SPECT compared with planar imaging; however, their results were not statistically significant.

In contrast with our findings, two clinical studies have compared Tc-99m DMSA renal triple-detector SPECT with planar imaging in humans and showed promising results for SPECT. Tarkington *et al.*^[14] compared triple-detector SPECT with pinhole imaging in 33 patients (65 renal units) and found that SPECT “enhanced” diagnostic information in 71% of studied renal units, and allows detection of cortical defects in 63% of kidneys that appeared normal on pinhole imaging. Those authors reported that high-resolution SPECT imaging improves the ability to identify cortical defects and visualize asymmetry of cortical thickness compared with standard pinhole imaging. Applegate *et al.*^[15] compared Tc-99m DMSA renal triple-detector SPECT with planar high-resolution parallel-hole, and pinhole imaging, in 40 patients (80 kidneys), and found that SPECT was significantly better than pinhole ($P = 0.03$) or planar imaging ($P = 0.001$) at showing definite defects. The difference between these two studies and our study results may be due to better image resolution provided by triple-detector systems with ultra-high-resolution collimators; however, triple-detector systems are not generally available today. Dual-head cameras are commonly used; however, there have not been direct comparisons with the triple-head systems.

Single-head SPECT cameras are still in use at some centers; the advantage of these cameras in renal SPECT is even less clear. Yen *et al.*^[11] compared the sensitivity of Tc-99m DMSA single-detector renal SPECT with planar scintigraphy, for the early diagnosis of acute pyelonephritis and found significantly ($P = 0.05$) more defects using single-detector SPECT than planar imaging. On the other hand, Mouratidis *et al.*^[16] compared single-detector SPECT with high-resolution planar scintigraphy and found more defects detected by SPECT than planar imaging, but these differences were not statistically significant ($P = 0.54$).

Our segment-by-segment analysis also found that the precision in lesion localization is similar between planar imaging and SPECT. Out of the five mismatched scans that we detect, three scans were for patients with renal impairment and high background activity, and two scans were for very small scars. A SPECT study may be helpful in the detection of very small renal parenchymal damage, which cannot be revealed by a planar study. Multiheaded SPECT is more sensitive than planar techniques for detection of small defects because of its better contrast resolution. However, specificity may be somewhat lower because some apparent cortical defects actually may be caused by normal variations such as fetal lobulation and splenic impression.^[17] The false positive results have been reported as 10% in the literature on renal space occupying lesions.^[18] Tc-99m DMSA uptake in a thin cortex due to hydronephrosis was so prone to being affected by the partial volume effects in SPECT that it appeared as decreased uptake areas mimicking renal scars. In this context, regional uptake defects which are demonstrated by DMSA scintigraphy may include not only renal scars but also some false positives and

other abnormalities as cited above, particularly in heterogeneity of the studied population.^[19]

More than 79% of renal cortical defects were located in both upper and lower poles of both kidneys. Our results are consistent with those reported by Itoh *et al.*,^[19] where more than 90% of renal cortical defects were located in both upper and lower poles of both kidneys. Similarly, Kullendorff and Evander^[20] found most of the regional parenchymal damage detected by scintigraphy was localized in both the upper and lower poles of the kidney. This predominantly polar distribution of renal cortical scarring may be related to the reflux of infected or sterile urine into compound or refluxing papillae situated at the poles of the kidney.^[21,22]

A distinguishing feature of this study was the large cohort of patients included, as well as random order for image interpretation at different sittings, giving more reliable results.

CONCLUSIONS

Technetium-99m DMSA renal cortical scanning using dual-head SPECT offers no statistically significant diagnostic advantage over multiple views planar imaging for detection of cortical defect. Very small scars and renal impairment are the common causes of missed scars in planner images.

Clinical relevance/Application

Multiple views planner imaging Tc-99m DMSA is almost equal to SPECT in detecting pyelonephritis and renal cortical scarring and can replaced the time consuming and sophisticated SPECT study.

REFERENCES

1. Snodgrass WT, Shah A, Yang M, Kwon J, Villanueva C, Traylor J, *et al.* Prevalence and risk factors for renal scars in children with febrile UTI and/or VUR: A cross-sectional observational study of 565 consecutive patients. *J Pediatr Urol* 2013;9:856-63.
2. Goswami R, Bal CS, Tejaswi S, Punjabi GV, Kapil A, Kochupillai N. Prevalence of urinary tract infection and renal scars in patients with diabetes mellitus. *Diabetes Res Clin Pract* 2001;53:181-6.
3. MacKenzie JR. DMSA – The new ‘gold standard’. *Nucl Med Commun* 1990;11:725-6.
4. Chroustová D, Palyzová D, Urbanová I, Kolská M. Results of a five-year study of 99mTc DMSA renal scintigraphy in children and adolescents following acute pyelonephritis. *Nucl Med Rev Cent East Eur* 2006;9:46-50.
5. Brenner M, Bonta D, Eslamy H, Ziessman HA. Comparison of 99mTc-DMSA dual-head SPECT versus high-resolution parallel-hole planar imaging for the detection of renal cortical defects. *AJR Am J Roentgenol* 2009;193:333-7.
6. Montini G, Tullus K, Hewitt I. Febrile urinary tract infections in children. *N Engl J Med* 2011;365:239-50.
7. Egli DF, Tulchinsky M. Scintigraphic evaluation of pediatric urinary tract infection. *Semin Nucl Med* 1993;23:199-218.
8. Lyra M, Ploussi A. Filtering in SPECT Image Reconstruction. *Int J Biomed Imaging* 2011;2011:693795.
9. De Sadeleer C, Bossuyt A, Goes E, Piepsz A. Renal technetium-99m-DMSA SPECT in normal volunteers. *J Nucl Med* 1996;37:1346-9.
10. Groshar D, Moskovitz B, Issaq E, Nativ O. Quantitative SPECT of DMSA uptake by the kidneys: Assessment of reproducibility. *Kidney Int* 1997;52:817-20.

11. Yen TC, Chen WP, Chang SL, Liu RS, Yeh SH, Lin CY. Technetium-99m-DMSA renal SPECT in diagnosing and monitoring pediatric acute pyelonephritis. *J Nucl Med* 1996;37:1349-53.
12. Craig JC, Wheeler DM, Irwig L, Howman-Giles RB. How accurate is dimercaptosuccinic acid scintigraphy for the diagnosis of acute pyelonephritis? A meta-analysis of experimental studies. *J Nucl Med* 2000;41:986-93.
13. Everaert H, Flamen P, Franken PR, Peeters P, Bossuyt A, Piepsz A. Tc-99 m DMSA renal scintigraphy for acute pyelonephritis in adults: Planar and/or SPET imaging? *Nucl Med Commun* 1996;17:884-9.
14. Tarkington MA, Fildes RD, Levin K, Ziessman H, Harkness B, Gibbons MD. High resolution single photon emission computerized tomography (SPECT) 99mtechnetium-dimercapto-succinic acid renal imaging: A state of the art technique. *J Urol* 1990;144:598-600.
15. Applegate KE, Connolly LP, Davis RT, Zurakowski D, Treves ST. A prospective comparison of high-resolution planar, pinhole, and triple-detector SPECT for the detection of renal cortical defects. *Clin Nucl Med* 1997;22:673-8.
16. Mouratidis B, Ash JM, Gilday DL. Comparison of planar and SPECT 99Tcm-DMSA scintigraphy for the detection of renal cortical defects in children. *Nucl Med Commun* 1993;14:82-6.
17. Ziessman HA, O'Malley JP, Thrall JH. Genitourinary system. In: Ziessman HA, editor. *Nuclear Medicine: The Requisites*. 4th ed. Philadelphia: Elsevier Mosby; 2014. p. 168-203.
18. Williams ED, Parker C, Rankin D, Roy RR. Multiple-section radionuclide tomography of the kidney: A clinical evaluation. *Br J Radiol* 1986;59:975-83.
19. Itoh K, Yamashita T, Tsukamoto E, Nonomura K, Furudate M, Koyanagi T. Qualitative and quantitative evaluation of renal parenchymal damage by 99mTc-DMSA planar and SPECT scintigraphy. *Ann Nucl Med* 1995;9:23-8.
20. Kullendorff CM, Evander E. Distribution of renal parenchymal damage on 99m-Tc DMSA scintigraphy in vesico-ureteric reflux. *Ann Chir Gynaecol* 1990;79:153-6.
21. Ransley PG, Risdon RA. Renal papillary morphology and intrarenal reflux in the young pig. *Urol Res* 1975;3:105-9.
22. Ransley PG, Risdon RA. Renal papillary morphology in infants and young children. *Urol Res* 1975;3:111-3.

How to cite this article: Saleh Farghaly HR, Mohamed Sayed MH. Technetium-99m dimercaptosuccinic acid scan in evaluation of renal cortical scarring: Is it mandatory to do single photon emission computerized tomography?. *Indian J Nucl Med* 2015;30:26-30.

Source of Support: Nil. **Conflict of Interest:** None declared.