



Case report

An unusual case of acute transverse myelitis caused by HSV-1 infection



Danisha Figueroa*, Carmen Isache, Michael Sands, Nilmarie Guzman

Department of Internal Medicine, Division of Infectious Disease, University of Florida, College of Medicine-Jacksonville, United States

ARTICLE INFO

Article history:

Received 9 March 2016

Received in revised form 29 May 2016

Accepted 31 May 2016

Keywords:

Quadriplegia

Herpes simplex virus

Transverse myelitis

ABSTRACT

Transverse myelitis is a neurological disorder of the spinal cord that can have a variety of etiologies. Herpes simplex virus (HSV) infection has been described as one of the causes, most commonly HSV type 2.

We report here a case of an 18 year old male who presented with weakness that started in his upper extremities and rapidly evolved to quadriplegia. Magnetic resonance imaging of spine was consistent with transverse myelitis. HSV type 1 PCR testing on cerebrospinal fluid (CSF) was positive. He was started on acyclovir and steroids, but despite therapy, patient did not recover motor function.

© 2016 The Author(s). Published by Elsevier Ltd. This is an open access article under the CC BY-NC-ND license (<http://creativecommons.org/licenses/by-nc-nd/4.0/>).

Introduction

Transverse myelitis is a neurological disorder of the spinal cord caused by inflammation that typically has an acute presentation [1]. The etiology may be infectious, parainfectious, other systemic inflammatory disorders, a spinal form of multiple sclerosis or idiopathic.

Infectious myelitis presents with fever and paraparesis, most commonly affecting the thoracic spinal cord. It can manifest as motor, sensory, and/or autonomic dysfunction of varying degrees. Symptoms develop over hours to days and worsen over days to weeks. Sensory symptoms usually present as ascending paresthesias, with or without back pain at or near the level of the myelitis. Motor symptoms often include weakness that preferentially affects the flexors of the legs and the extensors of the arms and can include sphincter dysfunction. Autonomic involvement manifests with bowel and bladder dysfunction, temperature dysregulation or bouts of hypertension.

We present a case of infectious transverse myelitis secondary to HSV-1 with an unusual presentation of descending paralysis, who despite appropriate therapy did not recover motor function.

Case

On arrival to the hospital, the patient was talking and moving his upper extremities. He was afebrile, tachycardic (106 bpm) and tachypneic (25 bpm). During initial evaluation, patient suddenly became unable to talk or move any of his extremities. He was

intubated and placed on mechanical ventilation for airway protection. He remained fully conscious.

On physical exam, strength was 0/5 in all four extremities. Sensation was intact over the head and neck, decreased 3/5 in the right arm and absent over the rest of his body. Complete blood count and comprehensive metabolic panels were normal. Computer tomography of his head without intravenous contrast showed no hemorrhage or midline shift.

Lumbar puncture (LP) was done on admission and CSF analysis showed 49 red blood cells, one white blood cell, normal protein and normal glucose. CSF HSV PCR was negative. Magnetic resonance imaging (MRI) of the spine showed segmental increase in T2 and STIR signal with associated mild expansion of the spinal cord (Fig. 1), consistent with possible transverse myelitis. Patient was started on high dose methylprednisone. Toxicology screen including lead, arsenic, cadmium and mercury was negative. Tests for lupus, neuronal potassium channel antibodies, anti-calcium-channel antibodies, anti-Purkinje-cell antibodies, anti-chromatin antibodies, anti-gliar antibodies, anti-neuronal antibodies, Rheumatoid arthritis latex turbid test, Lyme serology, Mycoplasma antibodies and quantitative HIV RT-PCR were all negative.

LP was repeated after one week and CSF analysis showed this time 92,000 red cells/cubic cm, 40 white cells/cubic cm with 88% neutrophils, glucose 72 mg/dL and protein 209 mg/dL. CSF aerobic and fungal cultures, Enterovirus RT-PCR, West Nile virus IgM and IgG, VDRL, oligoclonal bands and NMO/AQP4 were negative. Repeat HSV-1 PCR was positive.

After repeat LP, intravenous dexamethasone 6 g every 4 h was initiated, followed by a taper. In addition patient received intravenous acyclovir 1 g every 8 h and was given also IVIG, but his symptoms failed to improve.

* Corresponding author.

E-mail address: giselle-d80@hotmail.com (D. Figueroa).

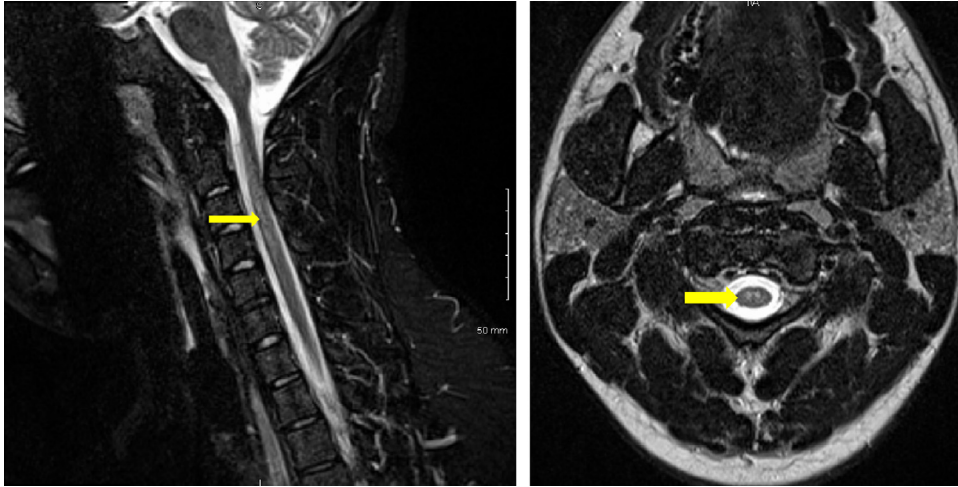


Fig 1. MRI of cervical spine with intravenous contrast done on admission with cord enhancement and possible hemorrhage indicated by the arrow.

Of note, during his hospital stay, patient also underwent plasma exchange every other day for 5 days without signs of improvement. This was done due to suspicion of possible Guillain Barre syndrome, prior to repeating the LP.

Repeat spine MRI done 12 days from admission showed interval increase in abnormal signal intensity of cervical cord, acute cervical cord edema with associated diffuse intramedullary enhancement with complete effacement of the CSF space surrounding the cervical spinal cord. There were also areas suggestive of possible spinal cord hemorrhages (Fig. 2). A follow up MRI done at 51 days showed marked improvement in the focal expansile appearance of upper cervical cord and abnormal T2 signal within the spinal cord and slightly decreased in craniocaudal extent, improved in cystic myelomalacia with T2 signal changes and minimal persistent enhancement.

Despite completing three weeks of intravenous acyclovir, high dose steroids, IVIG and plasma exchange patient did not recover motor function.

Discussion

Several viruses have been associated with infectious transverse myelitis, most commonly enteroviruses, HSV type 2 and varicella-zoster virus. Klastersky et al. reported the first case of HSV myelitis in 1972 [2,3]. HSV, most frequently HSV type 2, has been reported

since as the causative agent in several other cases of transverse myelitis. It can affect all ages, but seems to be more common in the 10–19 years old and 30–39 years old age groups. HSV myelitis has been described mostly in immunocompromised patients, but it has also been reported in immunocompetent patients [3]. Patients may or may not present with HSV skin manifestations at the time of neurological symptoms.

It has been hypothesized that the pathogenesis of HSV myelitis starts with HSV latent infection of the dorsal root ganglion at the level of the lumbosacral spinal cord which reactivates. This leads to invasion of the spinal cord, forming of necrotizing lesions and sometimes spread to the cervico-thoracic spinal cord. Related to the localization of the latent HSV infection, it has been described that HSV type 1 more often produces myelitis involving the cervical to the thoracic segment, while HSV type 2 involves the whole spinal cord or just the lumbosacral segment [4].

The initial symptoms of HSV myelitis are sensory-motor disturbances of the lower limbs and urinary disturbance [1]. The ascending necrotizing form often presents with encephalitis, quadriplegia or respiratory muscle paralysis which makes the prognosis poor. Necrotic cord changes are common, and hemorrhagic lesions are occasionally seen [2].

Ascending paralysis has been described as the most common presentation of transverse myelitis secondary to HSV type 2 infection. In contrast, Nakajima and Shoji et. al described cases

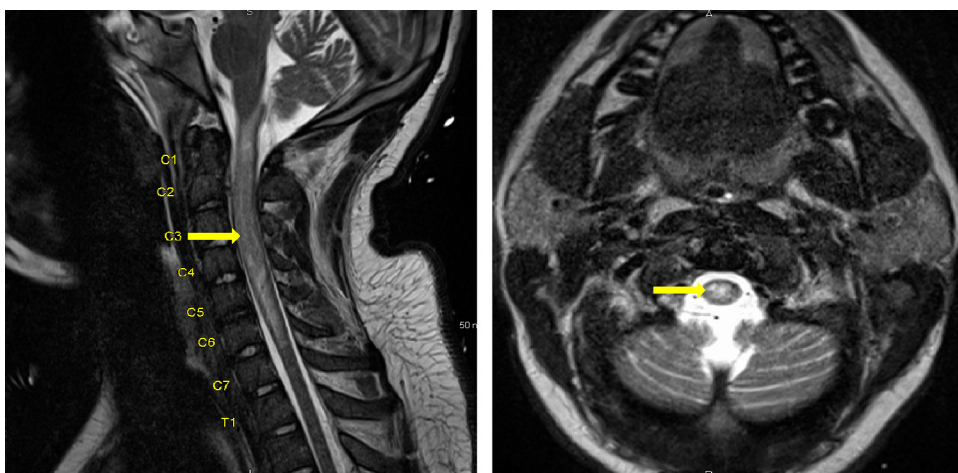


Fig. 2. MRI of cervical spine with intravenous contrast done after 12 days with cystic myelomalacia indicated by the arrow.

of transverse myelitis secondary to HSV type 1 infection where a non-ascending paralysis pattern was observed [2]. Initial diagnosis is made by imaging. Magnetic resonance imaging is the most specific test and may reveal signs of demyelination with or without necrosis. Histopathologic findings include marked necrosis of both gray and white matters, hemorrhage, perivascular lymphocyte infiltration and vascular necrosis. Progression may be prevented by administration of antiviral agents and steroids which lower mortality and improve neurological symptoms [3].

In this case, presentation was unusual with initial complaints of weakness in his upper extremity, followed by rapid progression to quadriplegia. The first CSF HSV PCR was negative, but subsequent repeat CSF HSV PCR was positive for HSV type 1. After administration of acyclovir, steroids, IVIG and plasma exchange,

MRI of spine showed improvement of the lesions, but at four month follow-up, the patient had not recovered any of his motor function.

References

- [1] Jacob A, Weinschenker B. An approach to the diagnosis of acute transverse myelitis. *Semin Liver Dis* 2008;28(February (1)):105–20.
- [2] Nakajima H, Shoji H. Herpes simplex myelitis: differences in clinical manifestations between herpes simplex virus type 1 and type 2. *Pathog Enceph* 2011;153–68.
- [3] Nakajima H, Furutama D. Herpes simplex virus myelitis: diagnosis by the polymerase chain reaction method. *Eur Neurol* 1998;39:163–7.
- [4] Yoshimoto A, Nshimura M. Herpes simplex virus type 1 myelitis with a favorable outcome. *Intern Med* 2001;40(10):1068–9.