



Intraspinal Anomalies in Individuals with Scheuermann's Kyphosis: Is the Routine Use of Magnetic Resonance Imaging Necessary for Preoperative Evaluation?

Serdar Demiroz¹, Ismail Emre Ketenci², Hakan Serhat Yanik², Samet Bayram², Koray Ur³, Sevki Erdem⁴

¹Department of Orthopaedics and Traumatology, Bingöl State Hospital, Bingöl, Turkey

²Department of Orthopaedics and Traumatology, Haydarpasa Numune Education and Research Hospital, Istanbul, Turkey

³Department of Neurosurgery, Bingöl State Hospital, Bingöl, Turkey

⁴Department of Orthopaedics and Traumatology, Emsey Hospital, Istanbul, Turkey

Study Design: Retrospective study.

Purpose: This study aimed to determine the incidence of intraspinal pathologies (ISPs) in individuals with Scheuermann's kyphosis (SK) and to validate whether the routine use of magnetic resonance imaging (MRI) is necessary for preoperative evaluation.

Overview of Literature: There are several studies on the necessity of routine MRI screening and prevalence of ISPs related to different types of scoliosis have been conducted. However, despite the well-established association between ISPs and a higher risk for neurological complications there is no any study on the scientific literature concerning the prevalence of ISPs in patients with SK has been conducted.

Methods: The database of the institution was retrospectively reviewed to identify all patients diagnosed with SK who underwent surgery between 2012 and 2015. Patients were excluded from the study if their hospital database records did not include spinal images, which are routinely collected before surgery. The presence or absence of ISPs, as indicated on magnetic resonance images, was evaluated by a radiologist.

Results: Of the 138 potential participants, 120 were included in the study. Of these, seven patients (5.8%) had ISPs, and all the cases involved syringomyelia. None of the seven patients with ISPs required additional neurosurgical procedures before corrective surgery. No complications were reported during the perioperative period, and none of the patients developed postoperative neurological deficits.

Conclusions: According to this study, the incidence rate of ISPs in patients with SK was 5.8%, and we recommend that all patients with SK should be evaluated using MRI of the spine before corrective surgery.

Keywords: Scheuermann disease; Syringomyelia; Kyphosis; Magnetic Resonance Imaging

Received Oct 11, 2017; Revised Nov 5, 2017; Accepted Nov 6, 2017

Corresponding author: Serdar Demiroz

Department of Orthopaedics and Traumatology, Bingöl State Hospital, Saray Street, Bingöl 12000, Turkey

Tel: +90-505-338-6490, Fax: +90-426-213-1043, E-mail: serdardemiroz@hotmail.com

Introduction

Scheuermann's kyphosis (SK) is a structural hyperkyphosis of the thoracic or thoracolumbar spine that develops during adolescence [1]. It is the most common cause of rigid hyperkyphosis in the pediatric population, with equal prevalence in both the sexes and incidence rate ranging from 0.4% to 8% [2,3]. The diagnosis is based on the Sorensen criteria, which include the presence of thoracic kyphosis of $>40^\circ$ or thoracolumbar kyphosis of $>60^\circ$ and at least three consecutive vertebrae wedged at a minimum of 5° , as indicated on lateral spine imaging [4]. Although the etiology of the disease is unknown, it is considered as multifactorial, with a strong genetic predisposition [5]. The first-line treatment of SK is usually conservative. However, surgical management is indicated in patients with progressive deformity exceeding 70° , progressive neurological deficit, severe back pain, or significant cosmetic deformity [3]. Posterior-only, anterior-only, and combined anterior and posterior approaches have been used for the surgical management of SK. Although some reports have recommended the use of combined anterior and posterior approaches to maximize initial deformity correction [6], Ponte [7] argued that posterior fusion alone is sufficient to achieve satisfactory outcomes with lower complication rates than those of combined approaches.

Coe et al. [8] have reported an overall complication rate of 15% and incidence rate of neurological deficit, which is one of the most serious complications following posterior surgery for SK, of 1.9%. In contrast, Hamilton et al. [9] have indicated a neurological complication rate of 0.73% following idiopathic scoliosis (IS) surgery; however, they did not categorize patients into adolescent, juvenile, and infantile groups. Coe et al. [10] have also reported that the neurological complication rate specifically for adolescent IS (AIS) ranged from 0.26% to 1.75% depending on the surgical approach. These data indicated that the surgical management of SK does not have lower neurological complication rates than those of the surgical management of AIS.

Intraspinal pathologies (ISPs), including Arnold–Chiari malformation, spinal cord tethering, diastematomyelia, syringomyelia, lipoma, teratoma, neurenteric cyst, dermoid cyst, and epidermoid cyst, may result in increased risk for neurological complications during scoliosis correction [11]. Consequently, several studies on the neces-

sity of routine magnetic resonance imaging (MRI) screening and prevalence of ISPs related to different types of scoliosis have been conducted [12,13]. However, despite the well-established association between ISPs and a higher risk for neurological complications and the fact that neurological complication rates for the surgical management of SK compared with AIS are not lower, no review on the scientific literature concerning the prevalence of ISPs in patients with SK has been conducted. Therefore, this study aimed to determine the prevalence of ISPs and importance of preoperative MRI assessment in patients with SK.

Materials and Methods

The database of the institution was retrospectively reviewed to identify patients who were diagnosed with SK and who underwent surgery between 2012 and 2015. Neurological examination and MRI assessment were routinely conducted for all the patients requiring surgery for spinal deformity, as required by the clinical protocol. The records of these patients were reviewed, and patients were included in the study if they had no neurological abnormalities on physical examination and no congenital spinal abnormalities on MRI. Patients with tumors, infections, traumatic spine pathology, or connective tissue disorders, those undergoing repeated surgeries, or those whose hospital database records did not include preoperative MR images or scoliosis orthoroentgenogram were excluded from the study. Finally, 120 patients with SK were included in the study.

The diagnosis of SK was based on the radiological criteria reported by Sorensen [4], including additional observations, such as irregularities of the vertebral endplates, Schmorl's nodes, narrowing of the disc spaces, and lengthening of the vertebral bodies. The indications for surgery were as follows: thoracic or thoracolumbar kyphosis with a curve greater than 70° , intractable back pain or an unacceptable cosmetic appearance, and no response to conservative treatment. Motor strength and sensation in the extremities and deep tendon and abdominal reflexes were all normal. All the patients had intact neurologic function according to their records.

A routine MRI of the spine, including the examination of T1- and T2-weighted sagittal, axial, and coronal images, was performed in all patients using a 1.5-Tesla MRI scanner. The presence or absence of intraspinal anomalies was evaluated by a radiologist based on the MR images.

Table 1. Morphologies of syringomyelia

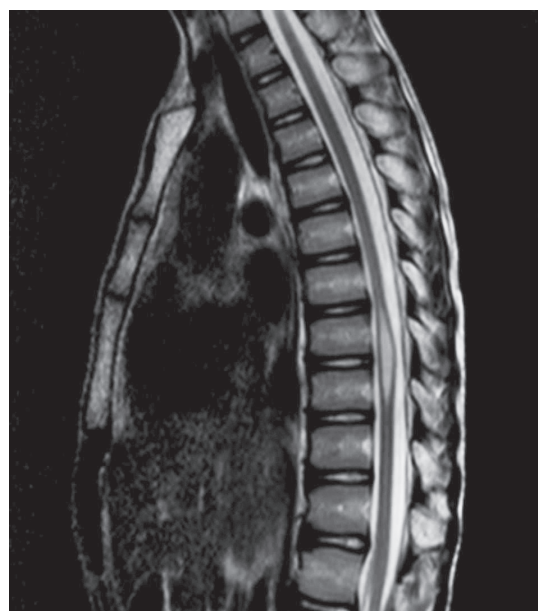	Maximal syrinx/cord ratio (mm)	Length	Width (mm)	Region	Type
Patient 1	0.37	T9–T11	3	Thoracic	Central
Patient 2	0.33	L1–L2	3	Lumbar	Central
Patient 3	0.55	L1–L3	5	Lumbar	Central
Patient 4	0.44	L2–L3	4	Lumbar	Central
Patient 5	0.55	L1–L3	5	Lumbar	Central
Patient 6	0.30	L3–L4	3	Lumbar	Central
Patient 7	0.57	T10–T12	4	Thoracic	Central

Posterior instrumentation and fusion were performed in all patients. Pedicle screws were bilaterally placed using a free-hand technique. Posterior release was performed with partial facetectomies, whereas major osteotomies, such as Smith Petersen or pedicle subtraction, were not performed. Titanium rods with 6.0-mm diameter were contoured to correct the deformity and restore the physiological kyphosis using cantilever reduction and apical compression. Intraoperative somatosensory evoked potential (SSEP) and motor evoked potential (MEP) spinal cord monitoring were routinely used for all patients to identify intraoperative neurological complications.

Results

Of the 138 patients, 120 were included in the study, of which 75 were male and 45 were female. The mean age was 22.9 ± 10 years (range, 59–12 years). Seven patients (5.8%) had ISPs, all of which were classified as syringomyelia (Table 1, Fig. 1). Arnold–Chiari malformation, tethered cord, or diastematomyelia were not observed. Although younger patients with hyperkyphosis have a higher risk for ISPs in AIS, age and thoracic kyphosis were not correlated with a higher incidence of ISPs in patients with SK. Moreover, gender was not a risk factor for ISPs in patients with SK, which was again contradictory with the study results on AIS. The mean age at presentation was 24.7 ± 14.4 years (range, 56–15 years) in patients with ISPs and 22.8 ± 9.8 years (range, 59–12 years) in those without ISPs. All patients were neurologically intact according to their preoperative examination, regardless of whether they had ISP. Radiologically, the preoperative mean kyphosis angle was 75° (range, 70° – 94°), and the postoperative mean kyphosis angle was 32° (range, 26° – 41°).

None of the seven patients with ISPs required addi-

**Fig. 1.** Syringomyelia in the thoracic region.

tional neurosurgical procedures prior to the corrective surgery (Fig. 2). SSEP and MEP results were normal; no differences were observed between the patients with and without ISPs. There were no complications during the perioperative period, and none of the patients developed postoperative neurological deficits.

Discussion

The increasing availability of MRI technology has led to its routine use by surgeons to evaluate patients before a spinal corrective surgery. Owing to the increased use of MRI examinations in assessing patients prior to surgery, several studies on the incidence of ISPs and the importance of MRI evaluation have been conducted; however, all the published studies in the scientific literature are on

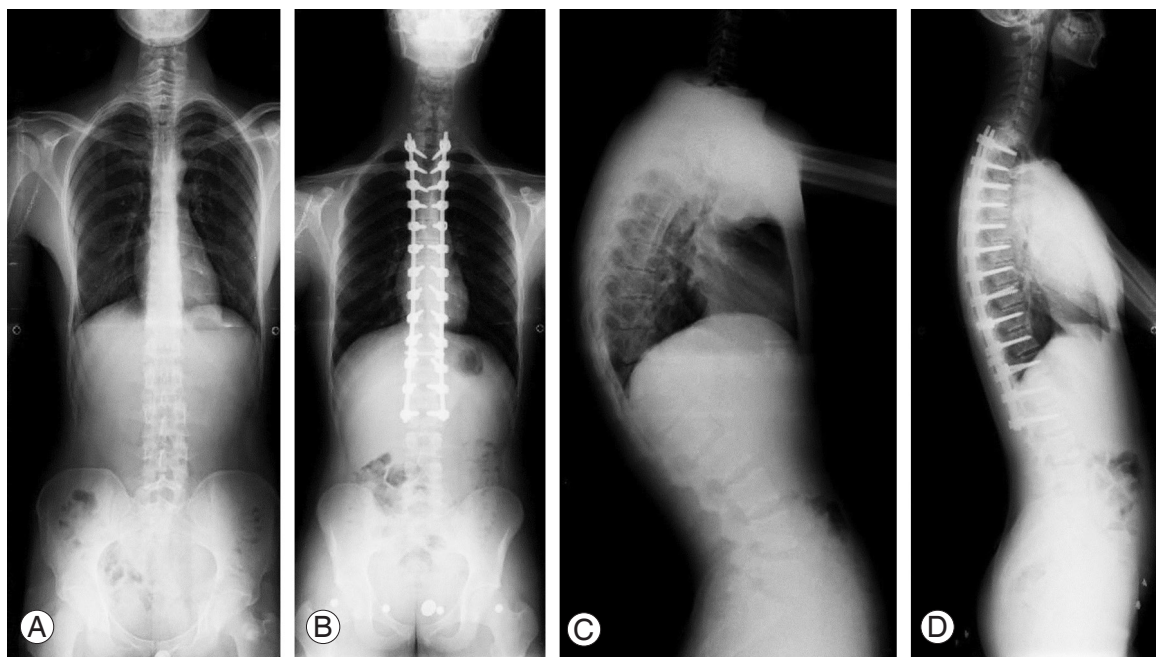


Fig. 2. AP and lateral views of the patient before and after corrective surgery. **(A)** AP view before surgery, **(B)** AP view after surgery, **(C)** lateral view before the surgery, and **(D)** lateral view after the surgery. AP, anteroposterior.

scoliosis. This study first examined the prevalence of ISPs and the importance of preoperative MRI in patients with SK.

ISPs are associated with the increased risk for postoperative neurological complications following corrective spinal surgery for scoliosis [11,14]. Therefore, it is important to evaluate patients for the presence of potential ISPs. Neurosurgical intervention may also be required before the corrective procedures to prevent neurological complications. Therefore, MRI evaluations are routinely performed for high-risk populations, such as patients with congenital or neuromuscular scoliosis. However, whether preoperative MRI evaluation is necessary for patients with IS remains controversial. The presence of back pain, neurological findings, atypical curve pattern, early onset of the disease, sex (male), and organ anomalies indicate that MRI evaluation is essential for patients with IS [15]. However, some studies have suggested the routine use of MRIs in all patients because of the high prevalence of ISPs.

The incidence of ISPs among individuals with congenital scoliosis varies. Singhal et al. [16] have reported an incidence rate of 9.7%, of which 55% of patients required neurosurgical intervention. However, Shen et al. [17] have reported that the incidence rate of congenital scoliosis was 43%, which was significantly different from those of other

studies. Rajasekaran et al. [18] have reported that among individuals with ISPs, 38% had congenital scoliosis and 22% had miscellaneous scoliosis secondary to connective tissue disorders or neuromuscular anomalies, with atypical curve patterns and rapid progression. Thus, the incidence of ISPs is higher in individuals with congenital and neuromuscular scoliosis. Therefore, routine MRI assessment is important in evaluating and managing patients with ISPs, if necessary, before corrective surgery.

However, it is important to note that the incidence of ISPs varied among individuals with different types of IS. Pahys et al. [19] reported an incidence rate of 13% in patients with infantile IS (IIS), of which 71% required neurosurgical intervention before corrective surgery. Rajasekaran et al. [20] reported an ISP incidence rate of 16% in individuals with IS; further analysis has revealed the following incidence rates: 4.2% for patients with AIS, 27% for those with juvenile IS (JIS), and 25% for those with IIS. Moreover, JIS and IIS are associated with a higher incidence of ISPs. Correspondingly, younger age (early onset) is another indication for MRI evaluation, as mentioned previously.

The necessity of MRI evaluation for patients with AIS before surgery remains controversial. Several studies have suggested that routine preoperative MRI evaluations are

not necessary in individuals with IS [20,21]. Do et al. [21] presented a study on 327 consecutive patients with AIS and reported low incidence rates for syrinx (0.6%) and Chiari malformations (1.2%). None of the patients required neurosurgical intervention before surgery, and no postoperative neurological complications were reported. Consequently, they concluded that MRI may not be performed if a patient with AIS has intact neurologic function, because normal results on physical examination indicates that there is no risk for complications despite the presence of ISP. In contrast, Shen et al. [17] suggested that there is no difference between patients with and without ISPs on physical examination; therefore, physical examination alone is not sufficient to indicate the presence of ISP or necessity of MRI evaluation. Furthermore, Rajasekaran et al. [18] reported that 54.5% of patients with ISPs who were diagnosed via MRI evaluation had no neurological deficits on preoperative clinical examination. Singhal et al. [16] reported that 55% of patients with IS who presented with ISPs required neurosurgical intervention. Furthermore, Ozturk et al. [22] reported an ISP incidence rate of 8% in patients with AIS, all of whom had intact neurological function on preoperative clinical examination; approximately 15% of these patients required neurosurgical intervention.

Although several studies have been published and controversies remain on the incidence of ISPs and necessity of MRI evaluation in individuals with AIS, there are no published reports addressing these issues, specifically in relation to SK. We showed an ISP incidence rate of 5.8% in patients with SK who were neurologically intact on preoperative examination and presented with syringomyelia. However, these results were inconsistent with those of previous studies on scoliosis. None of the patients required neurosurgical intervention before corrective surgery or had neurologic deficits after surgery.

Strahle et al. [23] reported that a total of 270 of 14,118 consecutive patients (1.9%) who underwent spinal MRI due to different indications, such as scoliosis, pain, or weakness, had syringomyelia. They were diagnosed as having idiopathic syringomyelia if no association with other brain and spinal cord conditions, such as tethered cord or Chiari malformation, was found; additionally, 80 of the 270 patients were idiopathic. Chiari malformation was the most frequently associated condition (117 of 270 patients). Strahle et al. [23] also emphasized the association between syringomyelia morphology, including width

and location, and its etiology and reported that a width of >5 mm and cranial extent in the cervical spine are associated with Chiari malformation. Conversely, a width of <5 mm and cranial extent in the thoracic or lumbar spine were associated with idiopathic syringomyelia. In the present study, all syringomyelia cases were <3.5 cm in length and 5 mm in width, and all the patients did not present with neurologic deficits during the preoperative and postoperative periods. Therefore, whether ISP size affects the neurological status remains unknown.

As mentioned previously, syringomyelia is associated with postoperative complications after corrective surgery, and a normal result on neurological examination before surgery does not rule out the presence of ISP. Although neurosurgical intervention was not required for these individuals with ISPs prior to the corrective surgery, intervention may be required in the future. Corrective maneuvers differ between scoliosis and kyphosis surgeries. Thus, the association between ISPs and postoperative neurological complications in individuals with scoliosis may differ from that in patients with kyphosis. However, kyphosis alone can also increase the risk for syringomyelia, and MRI is indicated in individuals with IS if thoracic kyphosis is >30° [15].

Conclusions

In conclusion, the incidence rate of ISPs was 5.8% in individuals with SK. All the ISP cases involved syringomyelia and had no association with other spinal pathologies. Thus, we recommend the routine use of MRI in patients with SK to identify ISPs. Further studies with a larger sample size must be conducted to further evaluate the incidence of ISPs and their effect on neurological complications during SK surgery.

Conflict of Interest

No potential conflict of interest relevant to this article was reported.

References

1. Scheuermann HW. The classic: kyphosis dorsalis juvenilis. *Clin Orthop Relat Res* 1977;(128):5-7.
2. Damborg F, Engell V, Andersen M, Kyvik KO, Thomsen K. Prevalence, concordance, and heritability of

- Scheuermann kyphosis based on a study of twins. *J Bone Joint Surg Am* 2006;88:2133-6.
3. Lowe TG. Scheuermann disease. *J Bone Joint Surg Am* 1990;72:940-5.
 4. Sorensen KH. Scheuermann's juvenile kyphosis: clinical appearances, radiography, aetiology, and prognosis. Copenhagen: Munksgaard; 1964.
 5. Lowe TG, Line BG. Evidence based medicine: analysis of Scheuermann kyphosis. *Spine (Phila Pa 1976)* 2007;32(19 Suppl):S115-9.
 6. Bradford DS, Ahmed KB, Moe JH, Winter RB, Lonstein JE. The surgical management of patients with Scheuermann's disease: a review of twenty-four cases managed by combined anterior and posterior spine fusion. *J Bone Joint Surg Am* 1980;62:705-12.
 7. Ponte A. Posterior shortening procedure by segmental closing wedge osteomies. *J Pediatr Orthop* 1995;15:404.
 8. Coe JD, Smith JS, Berven S, et al. Complications of spinal fusion for Scheuermann kyphosis: a report of the scoliosis research society morbidity and mortality committee. *Spine (Phila Pa 1976)* 2010;35:99-103.
 9. Hamilton DK, Smith JS, Sansur CA, et al. Rates of new neurological deficit associated with spine surgery based on 108,419 procedures: a report of the scoliosis research society morbidity and mortality committee. *Spine (Phila Pa 1976)* 2011;36:1218-28.
 10. Coe JD, Arlet V, Donaldson W, et al. Complications in spinal fusion for adolescent idiopathic scoliosis in the new millennium: a report of the Scoliosis Research Society Morbidity and Mortality Committee. *Spine (Phila Pa 1976)* 2006;31:345-9.
 11. Noordeen MH, Taylor BA, Edgar MA. Syringomyelia: a potential risk factor in scoliosis surgery. *Spine (Phila Pa 1976)* 1994;19:1406-9.
 12. Gupta P, Lenke LG, Bridwell KH. Incidence of neural axis abnormalities in infantile and juvenile patients with spinal deformity: is a magnetic resonance image screening necessary? *Spine (Phila Pa 1976)* 1998;23:206-10.
 13. Benli IT, Uzumcugil O, Aydin E, Ates B, Gurses L, Hekimoglu B. Magnetic resonance imaging abnormalities of neural axis in Lenke type 1 idiopathic scoliosis. *Spine (Phila Pa 1976)* 2006;31:1828-33.
 14. Phillips WA, Hensinger RN, Kling TF Jr. Management of scoliosis due to syringomyelia in childhood and adolescence. *J Pediatr Orthop* 1990;10:351-4.
 15. Davids JR, Chamberlin E, Blackhurst DW. Indications for magnetic resonance imaging in presumed adolescent idiopathic scoliosis. *J Bone Joint Surg Am* 2004;86-A:2187-95.
 16. Singhal R, Perry DC, Prasad S, Davidson NT, Bruce CE. The use of routine preoperative magnetic resonance imaging in identifying intraspinal anomalies in patients with idiopathic scoliosis: a 10-year review. *Eur Spine J* 2013;22:355-9.
 17. Shen J, Wang Z, Liu J, Xue X, Qiu G. Abnormalities associated with congenital scoliosis: a retrospective study of 226 Chinese surgical cases. *Spine (Phila Pa 1976)* 2013;38:814-8.
 18. Rajasekaran S, Kamath V, Kiran R, Shetty AP. Intraspinal anomalies in scoliosis: an MRI analysis of 177 consecutive scoliosis patients. *Indian J Orthop* 2010;44:57-63.
 19. Pahys JM, Samdani AF, Betz RR. Intraspinal anomalies in infantile idiopathic scoliosis: prevalence and role of magnetic resonance imaging. *Spine (Phila Pa 1976)* 2009;34:E434-8.
 20. Maiocco B, Deeney VF, Coulon R, Parks PF Jr. Adolescent idiopathic scoliosis and the presence of spinal cord abnormalities: preoperative magnetic resonance imaging analysis. *Spine (Phila Pa 1976)* 1997;22:2537-41.
 21. Do T, Frasc C, Burke S, Widmann RF, Rawlins B, Boachie-Adjei O. Clinical value of routine preoperative magnetic resonance imaging in adolescent idiopathic scoliosis: a prospective study of three hundred and twenty-seven patients. *J Bone Joint Surg Am* 2001;83-A:577-9.
 22. Ozturk C, Karadereler S, Ornek I, Enercan M, Ganiyusufoglu K, Hamzaoglu A. The role of routine magnetic resonance imaging in the preoperative evaluation of adolescent idiopathic scoliosis. *Int Orthop* 2010;34:543-6.
 23. Strahle J, Muraszko KM, Garton HJ, et al. Syrinx location and size according to etiology: identification of Chiari-associated syrinx. *J Neurosurg Pediatr* 2015;16:21-9.