

Tanaffos (2011) 10(3), 67-70

©2011 NRITLD, National Research Institute of Tuberculosis and Lung Disease, Iran

A Twenty-Year-Old Woman with Hemoptysis

Ilad Alavi Darazam^{1,2}, Atefeh Fakharian², Mohammad Behgam Shadmehr³, Atosa Dorudinia⁴, Davood Mansouri^{1,5}

¹ Department of Internal Medicine, Division of Infectious Disease and Clinical Immunology, ² Chronic Respiratory Disease Research Center, ³ Tracheal Disease Research Center, ⁴ Department of Pathology, ⁵ Clinical Tuberculosis and Epidemiology Research Center, NRITLD, Shahid Beheshti University of Medical Sciences, Tehran, Iran.

WHAT IS YOUR DIAGNOSIS?

A twenty-year-old woman was admitted due to non-massive hemoptysis and low grade fever from a few days earlier. She reported productive cough, no chills, no chest pain and no shortness of breath. On admission, she was stable with mild fever and no respiratory distress or tachypnea; the remainder of physical examinations was normal.

She mentioned a history of diabetes mellitus type one (DM1) since a few years ago. Surprisingly, she was on oral agents for DM1. She was well until approximately a month ago when she developed episodes of unconsciousness and she was admitted to a hospital with diabetic ketoacidosis. After intensive care, the patient was discharged in an improved condition.

She was a single employee, with no travel history in recent months. She was neither a drinker nor a smoker and was not using any illicit drugs. Allergic history was unremarkable.

Laboratory analysis showed normal complete blood cell and differential counts, electrolyte levels and renal and liver function tests with 250 mg/dl random glucose level. Analysis of arterial blood gases revealed no acidosis and urinalysis showed no ketonuria.

Initial chest x-ray and chest computed tomography (CT) scan are shown in Figure 1. Chest CT-scan revealed bilateral alveolar infiltration which was greater in the left lung with a central parahilar cavity in the right side in addition to right hilar and subcarinal adenopathy. Mild pleural effusion in left side was seen. On high resolution chest CT-scan, bilateral patchy ground glass opacity involving upper lobes, right middle lobe and superior segment of lower lobes was detected (Figure 1).

Based on imaging findings, after repeated negative acid fast staining of sputum smears, bronchoscopy was performed. An intrabronchial tumor with full obstruction of right main bronchus associated with diffuse necrosis of the bronchi and severe secretion was reported. The necrotic mass was partially removed with rigid bronchoscopy. (Tanaffos 2011; 10(3): 67-70)

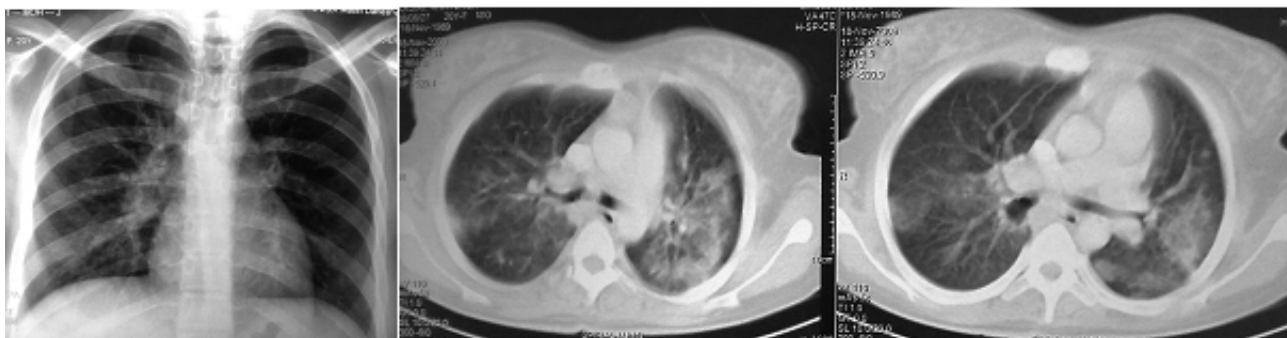

Figure 1. Chest x-ray and computed tomography on admission.

Correspondence to: Mansouri SD

Address: NRITLD, Shaheed Bahonar Ave, Darabad, TEHRAN 19569, P.O.:19575/154, IRAN

Email address: dmansouree@yahoo.com

Diagnosis: Pulmonary Mucormycosis

Histopathologic evaluation revealed inflammation associated with fungal hyphae highly suggestive of mucormycosis (Figure 2).

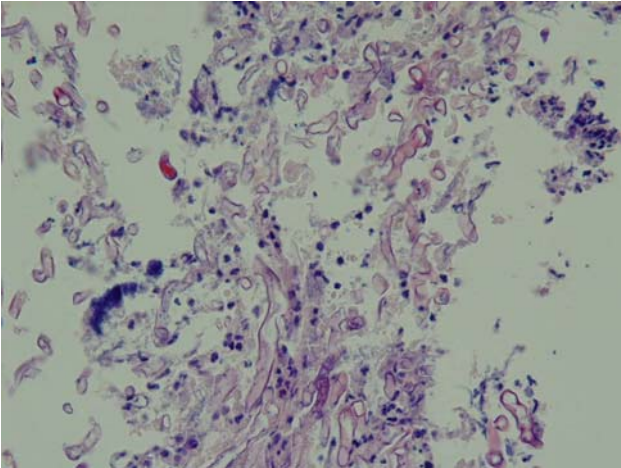


Figure 2. Hematoxylin and eosin staining of necrotic endobronchial mass revealed fungal hyphae without septation and right angle branches

Platauf, in 1885, described an invasive and disseminated infection in a cancer patient by ribbon-like angioinvasive hyphae that he named as *Mycosis mucorina* (1). Despite the controversy over the phylogenetic classification, the term “mucormycosis” is currently used (2); but in fact, the main causes of this type of human infection are members of the genus *Rhizopus*, not *Mucor* (3).

Poorly controlled diabetes mellitus particularly with ketoacidosis, high-dose glucocorticoid therapy, hematologic malignancies, hematopoietic stem cell and solid organ transplantation, therapy with deferoxamine in dialysis or transfusion-dependent patients, trauma, burn, renal failure, diarrhea, malnutrition in low-birth-weight infants and human immunodeficiency virus infection are the most

important underlying and predisposing factors for this infection (2-6).

The clinical presentation of mucormycosis is broad, depending on the underlying immune status and comorbidities of the host, but the most common and classic clinical presentation is rhino-orbital-cerebral infection, probably due to inhalation of spores into the paranasal sinuses of a susceptible host usually in hyperglycemic state with an associated metabolic acidosis (3).

Other manifestations followed by rhino-orbital infection are pulmonary, cutaneous, gastrointestinal or disseminated organ involvement.

Pulmonary mucormycosis is relatively uncommon but is an important opportunistic fungal infection in immunocompromised persons.

Patients with prolonged neutropenia, recipients of solid organ or stem cell transplantation, and treatment with glucocorticoids or deferoxamine are the most important underlying factors for this disease but pulmonary infection is less common than rhino-orbital-cerebral infection in diabetic patients (3,7,8). Concomitant sinus infection is commonly seen (8).

Pulmonary mucormycosis is a life threatening condition and prompt diagnosis and treatment is mandatory. Furthermore, patients are almost always immunocompromised and this is another important issue in management of patients. They are susceptible to other mimicking and indistinguishable mold infections such as invasive pulmonary aspergillosis and first line potent medications like voriconazole, lack activity against zygomycetes (9).

In logistic regression analysis of clinical characteristics of 16 patients with cancer and

pulmonary mucormycosis and 29 patients with cancer and invasive pulmonary aspergillosis at the time of infection onset, concomitant sinusitis and voriconazole prophylaxis were significantly associated with *Mucor* infection. Furthermore, the presence of multiple nodules (more than ten) and pleural effusion according to the initial CT-scan were both independent predictors of pulmonary mucormycosis (10).

As mentioned above, pulmonary disease is less frequent than sino-orbital infection in diabetics, and pulmonary mucormycosis has a slightly less fulminant course in these patients compared to neutropenic patients and transplant recipients. Also, endobronchial lesions and obstruction are seen commonly among diabetic patients.

Combination of surgical debridement, antifungal therapy and elimination of predisposing factors for infection are the principles of management. Lipid formulations of amphotericin-B have evolved as the cornerstone of primary therapy for mucormycosis (12). Management of pulmonary mucormycosis is the same. Patients usually undergo lobectomy, but sometimes pneumonectomy and repeated surgeries may be necessary for proximal or extensive involvements (8).

Isolated pulmonary infection is not common in diabetics but in this patient, paranasal sinuses, brain and orbital structures were intact. The patient was treated with liposomal amphotericin-B for one month followed by 3 months of oral itraconazole which was associated with clinical and radiologic response (Figure 3). Interestingly, the patient never needed radical surgery or repeated debridement by rigid bronchoscopy after cessation of antifungal agents. It has been more than twenty months after primary infection and she is healthy with no respiratory symptoms.

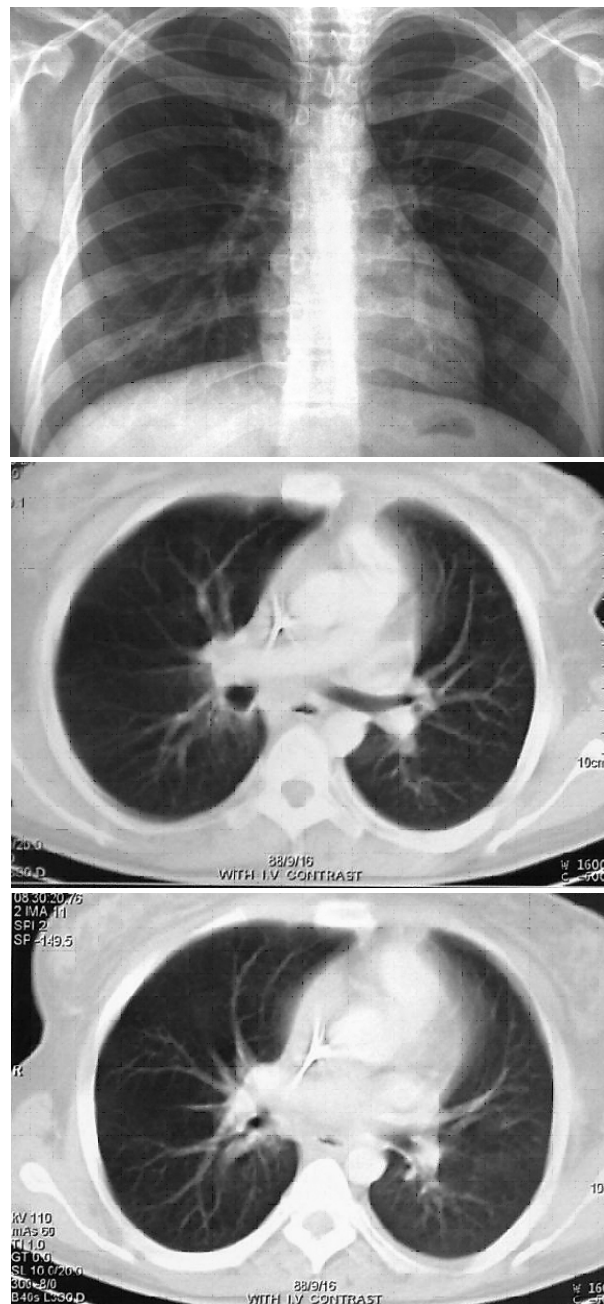


Figure 3. Chest x-ray and computed tomography one month after combination therapy

REFERENCES

1. Platauf AP. Mycosis mucorina. *Virchows Arch* 1885; 102:543-64.
2. Hibbett DS, Binder M, Bischoff JF, Blackwell M, Cannon PF, Eriksson OE, et al. A higher-level phylogenetic

- classification of the Fungi. *Mycol Res* 2007; 111(Pt 5): 509-47.
3. Roden MM, Zaoutis TE, Buchanan WL, Knudsen TA, Sarkisova TA, Schaufele RL, et al. Epidemiology and outcome of zygomycosis: a review of 929 reported cases. *Clin Infect Dis* 2005; 41 (5): 634- 53.
 4. Spellberg B, Edwards J Jr, Ibrahim A. Novel perspectives on mucormycosis: pathophysiology, presentation, and management. *Clin Microbiol Rev* 2005; 18 (3): 556- 69.
 5. Trifilio SM, Bennett CL, Yarnold PR, McKoy JM, Parada J, Mehta J, et al. Breakthrough zygomycosis after voriconazole administration among patients with hematologic malignancies who receive hematopoietic stem-cell transplants or intensive chemotherapy. *Bone Marrow Transplant* 2007; 39 (7): 425- 9.
 6. Singh N, Aguado JM, Bonatti H, Forrest G, Gupta KL, Safdar N, et al. Zygomycosis in solid organ transplant recipients: a prospective, matched case-control study to assess risks for disease and outcome. *J Infect Dis* 2009; 200 (6): 1002- 11.
 7. Kontoyiannis DP, Wessel VC, Bodey GP, Rolston KV. Zygomycosis in the 1990s in a tertiary-care cancer center. *Clin Infect Dis* 2000; 30 (6): 851- 6.
 8. Lee FY, Mossad SB, Adal KA. Pulmonary mucormycosis: the last 30 years. *Arch Intern Med* 1999; 159 (12): 1301- 9.
 9. Kontoyiannis DP, Lionakis MS, Lewis RE, Chamilos G, Healy M, Perego C, et al. Zygomycosis in a tertiary-care cancer center in the era of Aspergillus-active antifungal therapy: a case-control observational study of 27 recent cases. *J Infect Dis* 2005; 191 (8): 1350- 60.
 10. Chamilos G, Marom EM, Lewis RE, Lionakis MS, Kontoyiannis DP. Predictors of pulmonary zygomycosis versus invasive pulmonary aspergillosis in patients with cancer. *Clin Infect Dis* 2005; 41 (1): 60- 6.
 11. McAdams HP, Rosado de Christenson M, Strollo DC, Patz EF Jr. Pulmonary mucormycosis: radiologic findings in 32 cases. *AJR Am J Roentgenol* 1997; 168 (6): 1541- 8.
 12. Spellberg B, Walsh TJ, Kontoyiannis DP, Edwards J Jr, Ibrahim AS. Recent advances in the management of mucormycosis: from bench to bedside. *Clin Infect Dis* 2009; 48 (12): 1743- 51.