

Unconventional Management of Chyloascites After Laparoscopic Nissen Fundoplication

Paul F. Hwang, MD, Karen A. Ospina, MD, Earl H. Lee, DO, Scott R. Rehring, MD

ABSTRACT

Background & Objectives: Chyloascites is a rare complication that can result from abdominal trauma, neoplasm, inflammatory conditions, or various abdominal surgeries. Few cases have been described secondary to iatrogenic injury from laparoscopic Nissen fundoplication. We describe a case in which this surgery resulted in chyloascites that was successfully treated by lymphatic glue embolization.

Methods: A 37-year-old male presented with signs and symptoms consistent with chronic reflux disease. He underwent an uneventful laparoscopic Nissen fundoplication. Two weeks postoperatively, he was admitted for dehydration. During his admission, he began to develop a persistent cough, shortness of breath, and abdominal distention. Imaging and fluid analysis from thoracentesis and paracentesis were consistent with chyle leakage. Despite nonoperative measures, the patient's presentation persisted.

Results: Thoracic duct ligation was performed without success. Bipedal lymphangiography identified an extensive leak revealing a severely lacerated thoracic duct spilling contrast freely into the abdomen and no contrast entering the thoracic duct in the chest. The site of injury

was successfully sealed off with percutaneous glue embolization through lymph channels.

Conclusion: Chyloascites is a rare complication of laparoscopic Nissen fundoplication. When not successful with conservative measures, lymphatic glue embolization can provide effective treatment.

Key Words: Chyloascites, Laparoscopic Nissen fundoplication, Lymphatic glue embolization.

INTRODUCTION

Chyloascites is a rare and challenging complication that can result from abdominal trauma, neoplasm, inflammatory conditions, and various abdominal surgeries.¹⁻³ Iatrogenic injury usually occurs when dissecting near the base of the mesentery, retroperitoneum, or the cisterna chyli, leading to damage of abdominal lymphatics.¹ Laparoscopic Nissen fundoplication is one surgery where you have the potential for this damage to occur. Only a few cases have been described in the literature secondary to iatrogenic injury after this surgery. All have been treated through conventional nonoperative methods, such as enteral or parenteral nutrition with NPO to operative measures, such as abdominal lymphatic duct ligation.

Use of lymphatic duct glue embolization to treat chylothoraces has been increasingly reported in the literature.⁴⁻⁶ Although different in location, chyloascites can be treated the same way in which there is a transabdominal approach and lymphatic glue embolization proximal to the site of injury once the lymph channel is cannulated. Herein, we describe a case in which a laparoscopic Nissen fundoplication resulted in chyloascites that was successfully treated with lymphatic glue embolization when other conventional methods had failed. To our knowledge, the use of this technique in this specific case has never been reported before.

CASE REPORT

A 37-year-old male presented with a long-standing history of chronic reflux disease. Despite adequate medical ther-

Department of Surgery, General Surgery Service, Walter Reed Army Medical Center, Washington, DC, USA (all authors).

Department of Surgery, Uniformed Services University of the Health Sciences, Bethesda, Maryland, USA (Dr. Hwang).

The multidisciplinary care of this patient would not have been possible without the dedicated efforts of WRAMC medical and ancillary staff. Both civilian and military personnel have rendered skilled and compassionate care for this patient. We would like to give special thanks to Dr. Stephen Lowe, WRAMC (Interventional Radiology) & Dr. Anthony Venbrux, George Washington University (Interventional Radiology).

Presented as a General Surgery Open Forum Presentation at the 19th Society of Laparoendoscopic Surgeons Annual Meeting and Endo Expo 2010, New York, New York, USA, September 1-4, 2010.

Address correspondence to: Paul F. Hwang, MD, Walter Reed Army Medical Center, Department of Surgery, General Surgery Service, 6900 Georgia Avenue, NW, Bldg 2, RM 5C28, Washington, DC 20307. E-mail: Paul.F.Hwang@us.army.mil

DOI: 10.4293/108680812X13427982376545

© 2012 by JSLS, *Journal of the Society of Laparoendoscopic Surgeons*. Published by the Society of Laparoendoscopic Surgeons, Inc.

apy with proton pump inhibitors, the patient was without symptomatic relief. After an appropriate preoperative workup, he underwent a laparoscopic Nissen fundoplication. The procedure was uneventful, and the immediate postoperative period was just as unremarkable.

Two weeks later, the patient came to the emergency department dehydrated in prerenal acute renal failure after not being able to keep himself hydrated. He was immediately started on fluid resuscitative therapy. The patient had also developed a persistent cough with mild shortness of breath. Physical examination was remarkable for abdominal distention. The patient was further evaluated with CT of the chest and abdomen, which was remarkable for bilateral pleural effusions (**Figure 1a**) and

ascitic fluid in the abdomen (**Figure 1b**). Fluid was sampled from each cavity, and laboratory analysis showed triglyceride levels were well above 110mg/dL. Thus, the patient had subsequently developed a chylothorax and chyloascites after the index procedure.

Chest tubes were placed and paracentesis was performed, leading to evacuation of >1 liter of chylous fluid from both cavities. The patient was made NPO, started on parenteral nutrition, and IV Octreotide therapy, but leakage of chyle continued to persist. The patient was transferred to our facility for further management. Unable to localize the site of lymph duct injury, a thoracic duct ligation was performed between the aorta and azygous vein at the level of the eighth-ninth rib in the region of the right mediastinum. The pathology persisted despite adequate surgical technique.

After this failed surgical attempt, the decision was made to discontinue current management and transfer to a center specializing in lymphography. Bipedal lymphography was performed. A frank extensive leak was detected at the level of T10, showing a severely lacerated thoracic duct freely spilling contrast into the LUQ abdomen (**Figure 2**). No contrast entered the thoracic duct in the chest. Percutaneous lymph duct glue embolization was performed successfully using Cordis Tissue Glue (N-butylcyanoacrylate) (**Figure 3**). For the remainder of the hospital stay, all drain outputs decreased to insignificant levels and were discontinued. Abdominal girth also continued to decrease, and the patient was subsequently discharged. The patient was last seen at 8-month follow-up with normalization of weight and abdominal girth without recurrence of chyloascites in the setting of a normal diet.

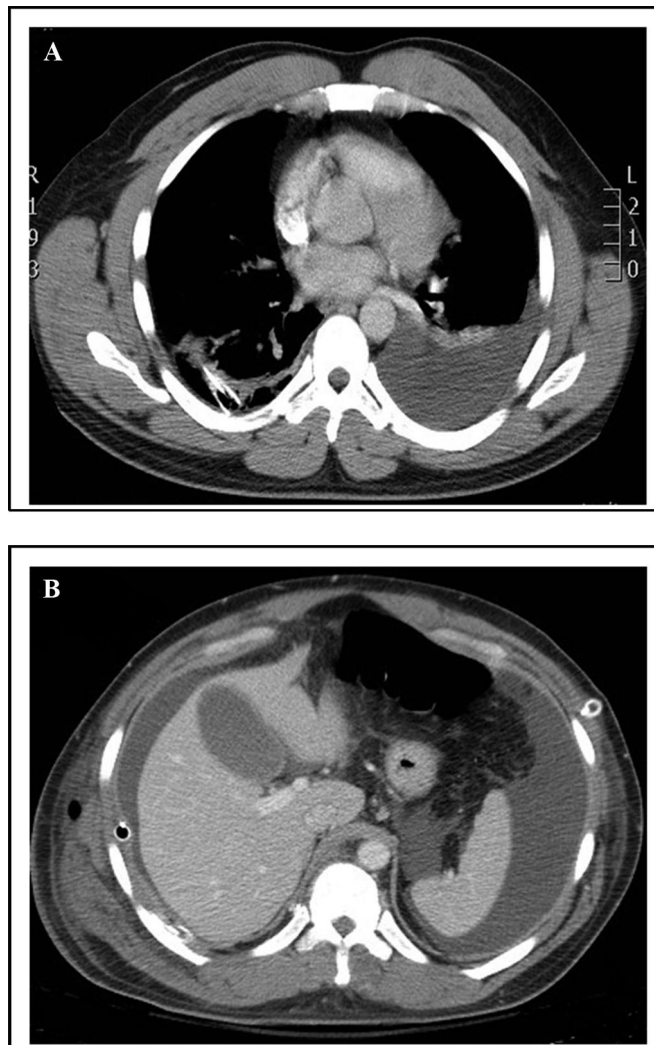


Figure 1. CT imaging at the time of presentation, demonstrating (a) pleural effusions and (b) ascites.

DISCUSSION

Laparoscopic Nissen fundoplication has become the mainstay of surgical treatment for gastroesophageal reflux disease whose most common complications consist of pneumothorax, pneumomediastinum, esophageal or gastric perforation, bleeding and mesenteric thrombosis.³ Chyloascites has been reported in the literature as a complication, but the incidence is very rare and usually occurs in retroperitoneal surgical procedures, such as lymphadenectomy, pancreaticoduodenectomy, distal spleen-renal shunt, and aortic surgery.⁷ This is probably due to the anatomy of the thoracic duct, and its relation to the esophagus and stomach dictate that this should be a rare event after such a procedure if carefully executed.

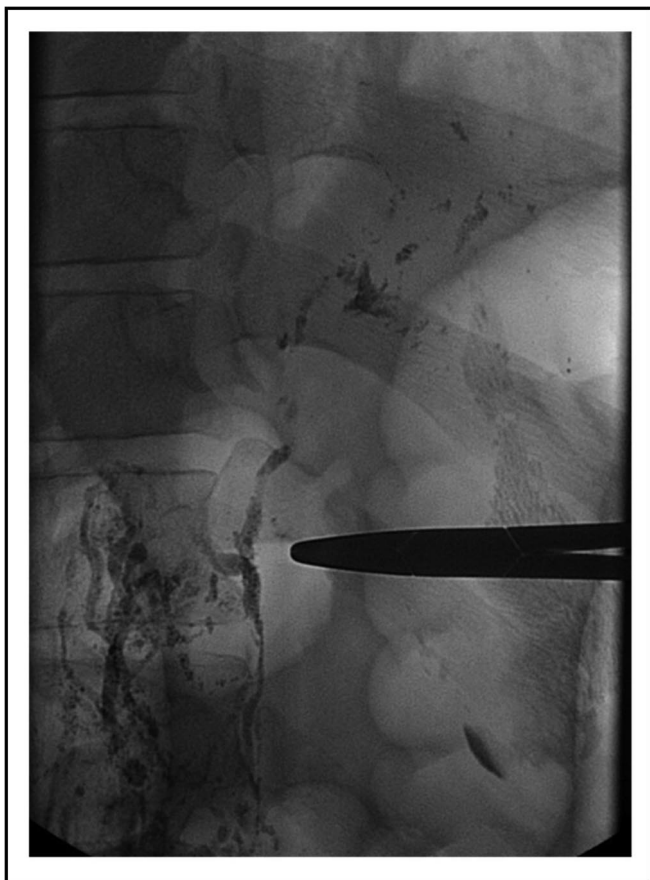

Figure 2. A frank extensive leak detected at the level of T10, showing a severely lacerated thoracic duct freely spilling contrast into the LUQ abdomen.

The thoracic duct is the largest lymphatic channel within the body. Except for the right head, neck, upper extremity, and chest, this channel is responsible for the remainder of lymphatic drainage. Flow starts at the cisterna chyli within the abdomen, acting as a confluence point for other smaller lymphatics coming from the lumbar, intestinal, liver, and inferior intercostal sources, located between the abdominal aorta and azygous vein. It courses posterior to the right crus of the diaphragm and along the right posterior mediastinum with a final destination proximal to the junction between the left subclavian and internal jugular veins.^{2,3} The true presence of a cisterna chyli was found in only 50% of individuals and in those missing this anatomic confluence are replaced by smaller lymphatic channels of the abdomen and lower extremities that form directly into the thoracic duct.⁸

The anatomic course of the thoracic duct in relation to the esophagus dictates that this complication should rarely

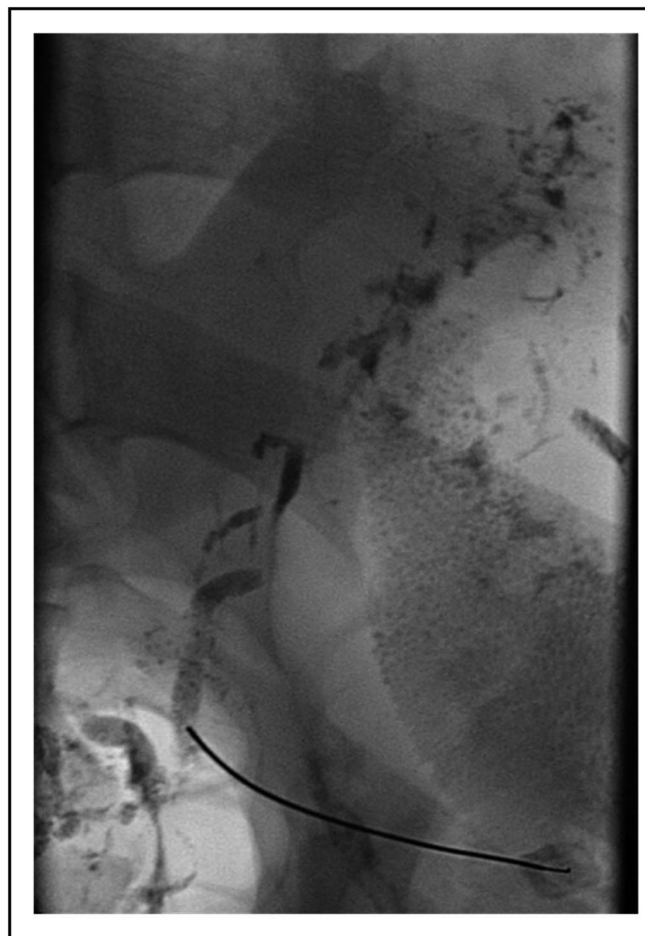

Figure 3. Fluoroscopic imaging displaying transabdominal puncture of the thoracic duct followed by contrast and lymphatic glue injection.

occur after a laparoscopic Nissen fundoplication if carefully executed. However, there are 2 steps during the procedure that deserve extra attention. First, one needs to be careful when entering the retroperitoneum medial to the right half of the diaphragmatic crus when developing the retrosophageal window prior to passing the gastric fundus posteriorly. This step is crucial, because it opens up exposure to lymphatic channels, allowing for these conduits to be susceptible to laceration or thermal injury if the retrosophageal window is entered too posteriorly.^{3,7} The second step that leaves the thoracic duct susceptible to injury is when re-approximating the left and right halves of the diaphragmatic crus. Obstruction of the duct can occur during this maneuver.² In this case, the former is most likely the culprit as the lymphogram clearly showed a lacerated lymphatic duct freely spilling into the abdomen. This could have been prevented by minimizing

posterior dissection behind the esophagus in the correct plane.

When this complication occurs secondary to this procedure, management of these patients should start with nonoperative measures followed by operative for refractory conditions. Each patient deserves a first-line treatment modality of dietary changes consisting of low-fat, long-chain triglycerides versus keeping the patient NPO with parenteral nutrition. Most reported cases of chyloascites secondary to the Nissen procedure found in the literature did not require anything more than dietary changes.^{2,3,7} Cases of this complication secondary to other etiologies have been reported to have been managed along with medical therapy to include somatostatin and octreotide.^{9–11} Surgery should only be attempted if there is a correctable lesion, persistence of symptoms despite dietary manipulations, and deterioration of clinical status in patients with unknown etiologies.^{2,3} Despite attempts at nonoperative and operative management and the inability to localize the site of injury, our patient was ultimately treated by a unconventional method of lymphatic glue embolization with lymphography.

Lymphography has long been the gold standard for imaging the lymphatic system. However, due to the introduction and expanding use of cross-sectional imaging, very few interventional radiologists and centers continue to perform these studies let alone continue to maintain the skills to interpret them.¹² This technology effectively located the leaking lymphatic channel in this patient and stopped the leakage with glue embolization. The specific glue used in this case was Cordis Tissue Glue (N-butyl-cyanoacrylate) mixed with Ethiodol contrast due to the glue's natural nonradiopaque characteristic. Internally, this substance becomes an adhesive very quickly and efficiently, polymerizing on contact with anionic substances, such as plasma, blood cells, endothelium or saline, provoking a local inflammatory response with fibrosis.¹³ To our knowledge, this was the first time lymphatic glue embolization was used to treat chyloascites secondary to a laparoscopic Nissen fundoplication; however, this technology has been used before.

This technique was first described by Cope et al in 1998.¹⁴ He has shown this technique in a series of 42 patients to be safe and effective allowing for a cure or partial response rate of 74% of patients with unremitting chylothoraces.¹⁵ Although mainly used to treat chylothoraces, the technique is the same as for chyle leakage in the abdomen. The thoracic duct is punctured trans-

abdominally at the cisterna chyli under fluoroscopic guidance, and the duct is embolized proximal to the location of injury/leakage, may it be in the abdomen or in the chest. Using this same technique or modifications of it, others¹⁶ have been able to repeat his results. Most recently, a retrospective review of 109 patients was conducted to evaluate the efficacy of thoracic duct embolization combined with needle interruption with an overall success rate of 71%, leading them to speculate that this could possibly be used as first-line therapy. One group¹⁷ went further and attempted retrograde embolization of the cisterna chyli from the subclavian vein for the treatment of chylous ascites, although initial success was short lived.

CONCLUSION

Chyloascites is a rare complication of laparoscopic Nissen fundoplication. This case demonstrates the importance of maintaining the surgical principles involved in a procedure to minimize the chances of iatrogenic injury that can lead to substantial morbidity. However, if this complication occurs, lymphatic glue embolization may provide effective treatment in chyloascites after iatrogenic injury from a laparoscopic Nissen fundoplication and should be considered in the armamentarium of treatment options, especially if conventional nonoperative measures have failed.

References:

1. Yeo M, Tan L, Chang S. Postoperative chylous ascites: An institutional experience over two years. *Surgical Practice*. 2008; 12:133–136.
2. Parys SC, Hart MH. Chylous ascites following a Nissen fundoplication. *J Pediatr Gastroenterol Nutr*. 1992;15(2):181–183.
3. Bacelar TS, de Albuquerque AC, de Arruda PC, Ferraz AA, Ferraz EM. Postoperative chylous ascites: a rare complication of laparoscopic Nissen fundoplication. *JLS*. 2003;7(3):269–271.
4. Binkert CA, Yucel EK, Davison BD, Sugarbaker DJ, Baum RA. Percutaneous treatment of high-output chylothorax with embolization or needle disruption technique. *J Vasc Interv Radiol*. 2005;16(9):1257–1262.
5. Hoffer EK, Bloch RD, Mulligan MS, Borsa JJ, Fontaine AB. Treatment of chylothorax: percutaneous catheterization and embolization of the thoracic duct. *AJR Am J Roentgenol*. 2001; 176(4):1040–1042.
6. Cope C, Salem R, Kaiser LR. Management of chylothorax by percutaneous catheterization and embolization of the thoracic

- duct: prospective trial. *J Vasc Interv Radiol.* 1999;10(9):1248–1254.
7. Slim K, Pezet D, Chipponi J. Development of chylous ascites after laparoscopic Nissen fundoplication. *Eur J Surg.* 1997;163(10):793–794.
 8. Gaba RC, Owens CA, Bui JT, Carrillo TC, Knuttinen MG. Chylous ascites: a rare complication of thoracic duct embolization for chylothorax. *Cardiovasc Intervent Radiol.* May 28 2010.
 9. Ijichi H, Soejima Y, Taketomi A, et al. Successful management of chylous ascites after living donor liver transplantation with somatostatin. *Liver Int.* 2008;28(1):143–145.
 10. Huang Q, Jiang ZW, Jiang J, Li N, Li JS. Chylous ascites: treated with total parenteral nutrition and somatostatin. *World J Gastroenterol.* 2004;10(17):2588–2591.
 11. Bhatia C, Pratap U, Slavik Z. Octreotide therapy: a new horizon in treatment of iatrogenic chyloperitoneum. *Arch Dis Child.* 2001;85(3):234–235.
 12. Guermazi A, Brice P, Hennequin C, Sarfati E. Lymphography: an old technique retains its usefulness. *Radiographics.* 2003;23(6):1541–1558, discussion 1559–1560.
 13. Golzarian J, Sharafuddin MJ, Sun S, SpringerLink (Online service). Vascular Embolotherapy. A Comprehensive Approach. Volume 1. General Principles, Chest, Abdomen, and Great Vessels. *Medical Radiology, Diagnostic Imaging.* Berlin, Heidelberg: Springer-Verlag Berlin Heidelberg; 2006.
 14. Cope C. Diagnosis and treatment of postoperative chyle leakage via percutaneous transabdominal catheterization of the cisterna chyli: a preliminary study. *J Vasc Interv Radiol.* 1998; 9(5):727–734.
 15. Cope C, Kaiser LR. Management of unremitting chylothorax by percutaneous embolization and blockage of retroperitoneal lymphatic vessels in 42 patients. *J Vasc Interv Radiol.* 2002; 13(11):1139–1148.
 16. Itkin M, Kucharczuk JC, Kwak A, Trerotola SO, Kaiser LR. Nonoperative thoracic duct embolization for traumatic thoracic duct leak: experience in 109 patients. *J Thorac Cardiovasc Surg.* 2010;139(3):584–589, discussion 589–590.
 17. Mittleider D, Dykes TA, Cicuto KP, Amberson SM, Leusner CR. Retrograde cannulation of the thoracic duct and embolization of the cisterna chyli in the treatment of chylous ascites. *J Vasc Interv Radiol.* 2008;19(2 Pt 1):285–290.