

A rare case report of fungal esophagitis combined with giant gastric ulcer in an immunocompetent patient

Ma Liang, MD^a, Zhang Liwen, MD^b, Dai Juan, MD^a, Zhuang Yun, MD^a, Ding Yanbo, MD^a, Chen Jianping, MD, PhD^{a,*}

Abstract

Rationale: Fungal infection of gastrointestinal (GI) tract is usually seen in immunocompromised patients, but can rarely occur in immunocompetent people in whom no permissive factor is present.

Patient concerns: We describe a 68-year-old male immunocompetent patient presenting with simultaneous fungal esophagitis and giant gastric ulcer.

Diagnoses: Repeated endoscopic biopsies were taken from the giant gastric ulcer edge and base and histology demonstrated granulation tissue and pseudohyphal fungal forms.

Interventions: The patient was treated with fluconazole and omeprazole for 8 weeks.

Outcomes: After antifungal treatment with fluconazole, the patient's clinical symptoms gradually disappeared with the healing of gastric ulcer, which never recurred in this patient until 3 months after follow-up.

Lessons: Nonhealing gastroesophageal ulcers highlights the importance of repeated endoscopies and biopsies.

Abbreviation: GI = gastrointestinal tract.

Keywords: antifungal treatment, fungal esophagitis, fungal gastric ulcer

1. Introduction

Fungal infection of gastrointestinal (GI) tract is an extremely rare disease, which is usually seen in immunocompromised patients who are malnourished, broad-spectrum antibiotics recipients, on steroids, immune-suppressed or have uncontrolled diabetes

Editor: N/A.

ML and ZL made equal contributions to this study.

This study was supported by grants from the National Natural Science Foundation of China (No. 81700500), the Applied Basic Research Programs of Science, Technology Department of Changzhou city (CJ20160031), the Research Project of Jiangsu Province Commission of Health and Family Planning (No. H201547), the Major Scientific and Technological Project of Changzhou City Commission of Health and Family Planning (No. ZD201612) and the Scientific and Technological Project of NanJing medical University (No. 2017NJMU042).

The authors report no conflicts of interest.

^a Department of Digestive Disease, The First People's Hospital of Changzhou, The Third Affiliated Hospital of Soochow University, ^b Department of Pediatrics, the Second People's Hospital of Changzhou, Affiliate Hospital of NanJing medical University, Changzhou, Jiangsu, China.

* Correspondence: Chen Jianping, Department of Digestive Disease, The First People's Hospital of Changzhou, The Third Affiliated Hospital of Soochow University, Changzhou, Jiangsu 213003, China (e-mail: chenjianping123abc@163.com).

Copyright © 2019 the Author(s). Published by Wolters Kluwer Health, Inc. This is an open access article distributed under the terms of the Creative Commons Attribution-Non Commercial-No Derivatives License 4.0 (CCBY-NC-ND), where it is permissible to download and share the work provided it is properly cited. The work cannot be changed in any way or used commercially without permission from the journal.

Medicine (2019) 98:3(e14158)

Received: 26 September 2018 / Received in final form: 8 December 2018 /

Accepted: 13 December 2018

<http://dx.doi.org/10.1097/MD.0000000000014158>

mellitus,^[1–4] but can rarely occur in immunocompetent people. In the GI tract, fungal infection frequently involves the esophagitis and rarely involves the gastric ulcer.^[2–4] In the case report below, we encountered an immunocompetent patient with epigastric pain, dysphagia and heartburn, which was eventually diagnosed as fungal esophagitis combined with giant gastric ulcer. After antifungal agents treatment, the patient's clinical symptoms were relieved and endoscopic observation of the gastric ulcer was healed.

2. Case presentation

A 68-year-old man presented with upper abdominal pain of 2 months, dysphagia and heart burn of 2 weeks duration after meals. He lost 5 kg weight in the last 2 months. The patient denied any recent use of non-steroidal anti-inflammatory drugs (NSAIDs), alcohol or anticoagulants. Gastrointestinal (GI) tract radiography in the external hospital demonstrated reflux esophagitis and giant gastric ulcer. Endoscopy revealed severe esophagitis and gastric ulcer of approximately 5 × 5 cm in size (A textual description of the gastroscopy). Initially, ulcer was considered to be malignant. However, biopsy demonstrated a gastric ulcer with no evidence of malignancy and antral biopsy revealed *Helicobacter pylori*-associated gastritis. Despite high-dose treatment with a combination of omeprazole, amoxicillin, and clarithromycin for *H pylori*, upper abdominal pain did not respond even after treatment for 14 days. On June 28, 2018, the patient was admitted to the inpatient service of Department of Gastroenterology, the First People's Hospital of Changzhou. Examination was unremarkable. Laboratory evaluation revealed mild anemia with a hemoglobin level of 118 g/L. In addition, as listed in Table 1, other laboratory data, including liver function

Table 1**Laboratory observation upon admission.**

| Characteristics | Index | Normal range |
|----------------------------|-------|--------------|
| Blood | | |
| WBC ($\times 10^9$ /L) | 4.9 | 4.0–10.0 |
| RBC ($\times 10^{12}$ /L) | 3.3 | 3.5–5.5 |
| HB (g/L) | 118 | 120–155 |
| PLT ($\times 10^9$ /L) | 266 | 100–300 |
| Liver function | | |
| ALT (u/L) | 35 | 9–50 |
| AST (u/L) | 30 | 10–45 |
| γ -GT (u/L) | 55 | 10–60 |
| ALP (u/L) | 120 | 40–125 |
| TP (g/L) | 55 | 60–82 |
| ALB (g/L) | 26.5 | 35–55 |
| CHE (u/L) | 2205 | 3000–8000 |
| Serum tumor markers | | |
| AFP (ng/mL) | 6.2 | 0–8 |
| CEA (ng/mL) | 1.5 | 0–5 |
| CA199 (U/mL) | 23 | 0–37 |

γ -GT = glutamyltranspeptidase, ALB = albumin, ALP = alkaline phosphatase, ALT = alanine transaminase, AST = aspartate aminotransferase, CHE = cholinesterase, TP = total protein.

and serum tumor markers, were normal. Thoracic and abdominal contrast-enhanced computed tomography (CT) revealed a diffuse thick walled proximal esophagus and mild thickening of

stomach wall along the lesser curvature but no typical appearances of carcinoma. Repeated upper gastrointestinal (GI) endoscopic showed severe esophagitis with extensive white patches in the middle and lower esophagus and a large oval to circular 6×6 cm ulcer with slough at base, smooth and irregular margin in lesser curvature of stomach (Fig. 1). Repeated endoscopic biopsies were taken from antrum and from the ulcer edge and base and histology demonstrated granulation tissue and pseudo-hyphal fungal forms on Periodic acid-Schiff stain consistent with *Candida albicans* (Fig. 2), whereas antral biopsy was negative for *H pylori*. Hence, there was no evidence of malignancy. He was treated with fluconazole for 8 weeks, thus his symptoms disappeared in 4 weeks after the institution of therapy. The patient was followed-up in our gastroenterology outpatient department. Repeated endoscopy at 3 months showed complete healing of ulcer.

3. Ethic statement

Our institutional review board was waived due to the retrospective nature of the study. Informed consent was obtained from the patient's parents for the publication of this case report.

4. Discussion

In the GI tract, fungal esophagitis are frequent and have documented in immunocompromised and immunocompetent

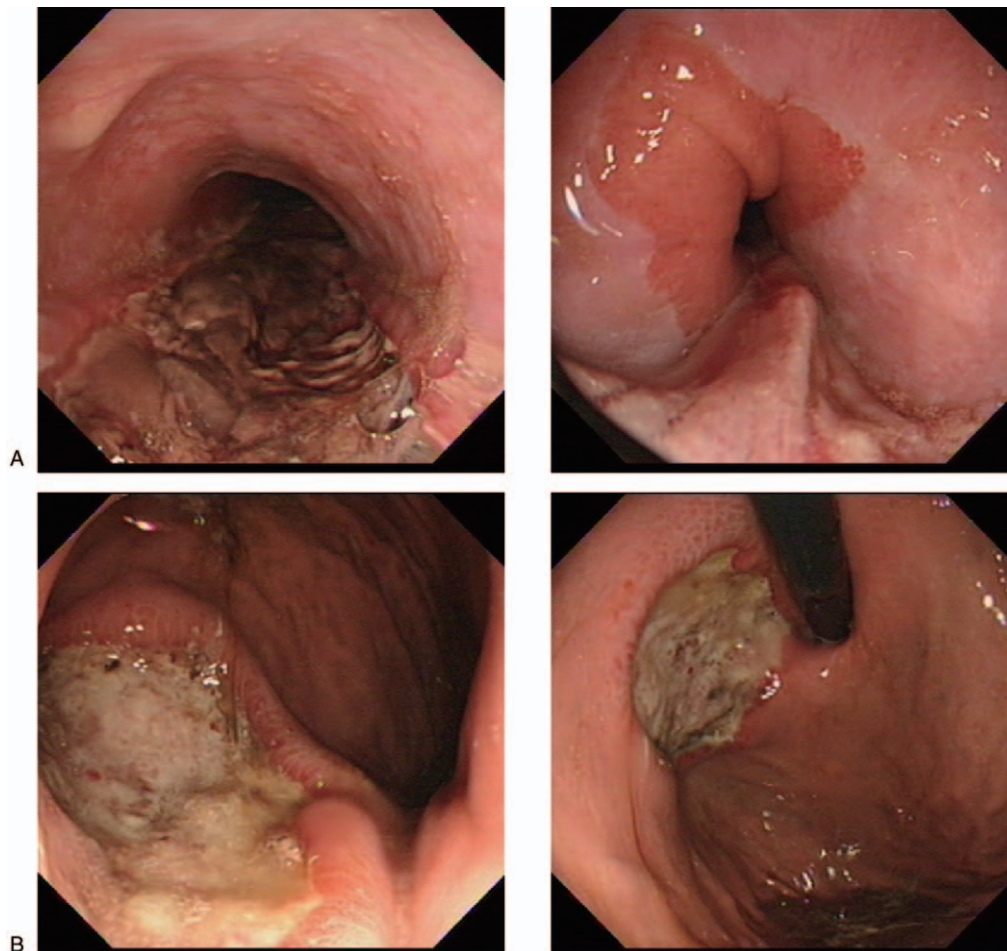


Figure 1. Endoscopic appearance. (A) Endoscopy showing severe esophagitis with extensive white patches in the middle and lower esophagus; (B) Endoscopy showing large ulcer with slough at base in lesser curvature of stomach.

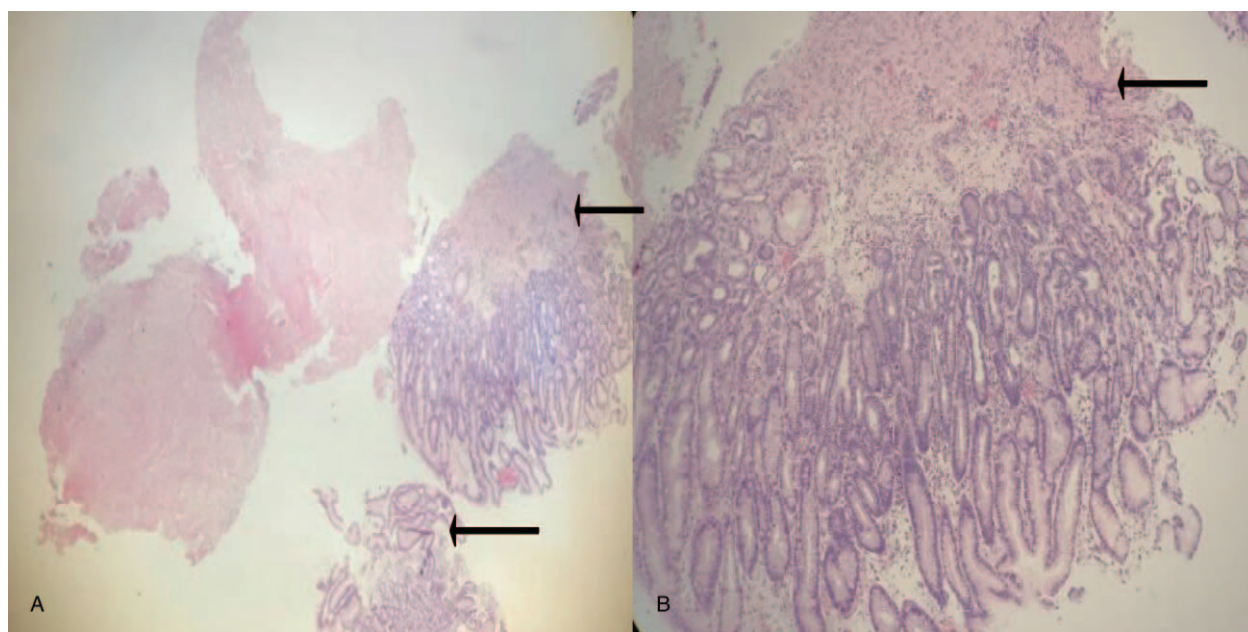


Figure 2. Histological examination. Photomicrograph showing granulation tissue and pseudohyphal fungal forms (black arrow). (A) magnification, 10x; (B) magnification, 40x.

patients.^[3–5] However, fungal infections of gastric ulcers are rare and have only been reported in patients who had undergone surgery for peptic ulcer disease or in an immunosuppressed state,^[1–2] but infrequent in immunocompetent individuals. The patient in the case above presented with 2 simultaneous severe GI diseases: fungal esophagitis and giant gastric ulcer associated with fungal infections.

Presentation of fungal esophagitis in immunocompetent patients includes heartburn, odynophagia, dysphagia, and retrosternal discomfort, and more serious cases can cause systemic candidiasis, esophageal dysmotility, stricture, fistulae and perforation.^[3–5] Typical features of endoscopic finding are the presence of mucosa in the form of white plaques, which are difficult to wash and even brushing makes the mucosa bleeds but does not wash it away.^[6] Hyphae presence in the biopsy specimen is diagnostic for fungal esophagitis. Two to 6 weeks institution of anti-fungal, such as Nystatin or Fluconazole, are sufficient for clearing the fungal infection.^[4]

Compared to fungal esophagitis, fungal colonization of the stomach is uncommon in immunocompetent patients.^[7–8] Knoke and Benhardt^[9] found that *Candida* was isolated in 6 of 2537 patients. Moreover, another a study on the presence of fungal infection as a stomach opportunistic germ in 149 patients, only 23 outpatients had gastric *Candida*.^[10] However, classical appearance of fungal gastric ulcer is even rarer; only single case reports were available. Praveer et al^[11] reported a patient with *Candida* gastric ulcer who was successfully treated with intravenous amphotericin for initial 3 weeks followed by oral fluconazole. However, successful treatment methods are only limited to case sharing at present, and the standard treatment method has not been established.

In this report, we have described an immunocompetent patient presenting with simultaneous fungal esophagitis and giant gastric ulcer. Despite high-dose treatment with proton pump inhibitors (PPI) and anti-*H pylori* drug, his clinical symptoms persisted. The repeated endoscopic examination showed a giant gastric ulcer

appeared to be malignant. Immunostaining of a biopsy from the ulcer edge indicated fungal infections. It is possible that antacids cause a decrease in the acidic environment in the stomach cavity, which is beneficial to the growth of fungus. This may be the reason why the size of the stomach ulcer increases from 5 × 5 cm to 6 × 6 cm. Hence, we speculated that presence of fungus in gastric ulcer impaired the course of ulcer healing as well as persistence of symptoms.^[8,11] Molecular mechanisms may be attributed to low expression of vascular endothelial growth factor-A (VEGF-A) and proliferating cell nuclear antigen (PCNA).^[12] After 8 weeks of antifungal treatment with fluconazole, the patient's clinical symptoms gradually disappeared with the healing of gastric ulcer, which never recurred in this patient until 3 months after follow-up.

5. Conclusion

To our knowledge, this is an unusual presentation of fungal esophagitis and giant gastric ulcer, which highlights the importance of repeated endoscopies and biopsies as features are not always identified initially. In addition, it should be remembered fungal infections as a cause of a nonhealing ulcer or the chance for curative therapy may be missed. In addition, because our observation is limited to 1 patient, more patients and longer follow-up are necessary to establish the standard treatment for patients with simultaneous fungal esophagitis and giant gastric ulcer.

Author contributions

Conceptualization: Chen Jianping.
Data curation: Ding Yanbo.
Formal analysis: Dai Juan.
Project administration: Zhuang Yun.
Writing – original draft: Ma Liang.

Writing – review & editing: Zhang Liwen.
Chen Jianping orcid: 0000-0002-5505-4140.

References

- [1] Praveer R, Sunil BC. Giant fungal gastric ulcer in an immunocompetent individual. *Saudi J Gastroenterol* 2012;18:282–4.
- [2] Rajablou M, Ganz RA, Batts KP. Candida infection presenting as multiple ulcerated masses. *Gastrointest Endosc* 2007;65:164–6.
- [3] Badarinarayanan G, Gowrisankar R, Muthulakshmi K. Esophageal candidiasis in non-immune suppressed patients in a semi-urban town, southern India. *Mycopathologia* 2000;149:1–4.
- [4] Anjum S, Asaad A, Zafar Z, et al. Fungal esophagitis in a child with insulin dependent diabetes mellitus. *J Coll Physicians Surg Pak* 2016;26:712–3.
- [5] Nassar Y, Eljabbour T, Lee H, et al. Possible risk factors for candida esophagitis in immunocompetent individuals. *Gastroenterol Res* 2018;11:195–9.
- [6] Bonacini M, Young T, Laine L. The causes of esophageal symptoms in human immunodeficiency virus infection. A prospective study of 110 patients. *Arch Intern Med* 1991;151:1567–72.
- [7] Zwolinska WM, Budak A, Bogdał J, et al. Fungal colonization of gastric mucosa and its clinical relevance. *Med Sci Monit* 2001;7:982–8.
- [8] Zwolińska WM, Budak A, Bogdał J, et al. Effect of fungal colonization of gastric mucosa on the course of gastric ulcers healing. *Med Sci Monit* 2001;7:266–75.
- [9] Knoke M, Bernhardt H. Endoscopic aspects of mycosis in the upper digestive tract. *Endoscopy* 1980;12:295–8.
- [10] Minoli G, Terruzzi V, Butti GC, et al. A prospective study on Candida as a gastric opportunistic germ. *Digestion* 1982;25:230–5.
- [11] Wu CS, Wu SS, Chen PC. A prospective study of fungal infection of gastric ulcers: clinical significance and correlation with medical treatment. *Gastrointest Endosc* 1995;42:56–8.
- [12] Jin L, Yoshida M, Nakamura T, et al. Candida albicans infection delays duodenal ulcer healing in cysteamine-induced duodenal ulcers in rats. *Dig Dis Sci* 2008;53:2878–85.