

Absence of Granzyme B positive tumour-infiltrating lymphocytes in primary melanoma excisional biopsies is strongly associated with the presence of sentinel lymph node metastasis

I.S. van Houdt^{a,*}, B.J.R. Sluijter^{b,*}, P.A.M. van Leeuwen^b, L.M. Moesbergen^a, E. Hooijberg^{a,**}, C.J.L.M. Meijer^a, T.D. de Gruijl^c, J.J. Oudejans^{a,2} and E. Boven^c

^a *Department of Pathology, VU University Medical Center, Amsterdam, The Netherlands*

^b *Department of Surgical Oncology, VU University Medical Center, Amsterdam, The Netherlands*

^c *Department of Medical Oncology, VU University Medical Center, Amsterdam, The Netherlands*

Abstract. *Background:* Sentinel Lymph Node (SLN) status is strongly related to clinical outcome in melanoma patients. In this study we investigated the possible association between the presence of activated and/or suppressive Tumour Infiltrating Lymphocytes (TILs) and SLN status in clinically stage I/II melanoma patients.

Methods: Diagnostic primary melanoma samples from 20 patients with a sentinel lymph node metastasis were compared to melanoma samples from 20 patients with a negative sentinel lymph node, who were matched for gender, age and Breslow thickness. Presence of activated Granzyme B positive (GrB⁺) TILs, presence of suppressive (FoxP3⁺) TILs and MHC class I antigen expression on tumour cells were analysed by immunohistochemistry.

Results: FoxP3 and MHC-I expression had no direct bearing on the presence of melanoma metastases in the SLN. Whereas the presence of activated GrB⁺ TILs in the primary melanoma had no predictive value for SLN status either, their absence was strongly associated with the presence of metastasis in the SLN ($p = 0.001$). While both GrB⁺ and FoxP3⁺ TILs could be detected in SLN metastases, a majority did not display MHC-I expression.

Conclusion: These data support a role for cytotoxic T cells in the prevention of early metastasis of melanoma to the draining lymph nodes.

Keywords: Melanoma, CTL, Tregs, FoxP3, Granzyme B, sentinel lymph node

1. Introduction

Fatal outcome in melanoma patients mostly results from occurrence of distant metastases, which are usually preceded by lymph node metastases [23,29]. Lymph node metastases develop in the first-line tu-

mour-draining lymph node, the sentinel lymph node (SLN). The prognostic value of the SLN status has been shown in several large studies [3] and the SLN status is used as a tool for selecting patients for trials on adjuvant (immune) therapy [20]. The SLN status and clinical outcome in melanoma patients is known to be associated with a number of variables, including Bres-

* Both authors contributed equally to this work.

** Corresponding author: Erik Hooijberg, PhD, Cancer Center Amsterdam, Department of Pathology (CCA 2-26), VU University Medical Center, de Boelelaan 1117, NL 1081 HV, P.O. Box 7057, NL-1007 MB, Amsterdam, The Netherlands. Tel.: +31 20 4444041; Fax: +31 20 4442964; E-mail: erik.hooijberg@vumc.nl.

¹ Current address: Department of Tumour Immunology, Nijmegen Centre for Molecular Life Sciences, Radboud University Nijmegen Medical Centre, P.O. Box 9101, 6500 HB Nijmegen, The Netherlands.

² Current address: Department of Pathology, Diaconessenhuis, Postbus 80250 3508 TG, Utrecht, The Netherlands.

low thickness, ulceration, location of primary tumour, lymphatic invasion, gender and age [6,2,24,21].

It has previously been shown that melanomas can elicit an immune response [15,17] and that tumour cells can effectively be eradicated *in vivo* by cytotoxic activity of MHC class I restricted CD8⁺ Granzyme B⁺ (GrB⁺) T-cells [1]. Proper activation of a CD8⁺ T-cell mediated immune response requires antigen to be presented in the context of the appropriate MHC class I molecules. When a cell loses expression of MHC class I molecules, it can no longer be recognized by CD8⁺ lymphocytes, but it might become susceptible to natural killer (NK) cell recognition [14]. Loss of MHC class I antigen expression has been shown to be involved in immune escape and tumour progression [1,18,19] and has been associated with poor clinical outcome [8,11]. In addition, target cell killing by cytotoxic T-cells (CTLs) requires the help of CD4⁺ T-helper (Th) cells [4,12] and is negatively regulated by suppressive regulatory T-lymphocytes. These suppressive T-lymphocytes express the FoxP3 transcription factor, which we used in this study as a marker for detection of suppressive T-lymphocytes [9,30]. FoxP3 is an X-chromosome-linked factor that controls development and function of regulatory T-lymphocytes (T_{reg}). While high expression levels are indeed found in this specialized CD4⁺CD25⁺ T cell subset, FoxP3 expression may also specify immune-suppressive activities in activated conventional T cells [9,10].

In a previous study of patients with stage I/II melanoma we showed that the presence of activated (i.e. GrB⁺ and CD8⁺) Tumour Infiltrating Lymphocytes (TILs) predicted favourable outcome. Presence of these TILs was significantly correlated with expression of MHC class I antigen on tumour cells [26,27]. These data suggest that the cellular immune response, although apparently not sufficient to prevent primary tumour growth, is nevertheless able to prevent the occurrence of lymph node and/or distant metastases.

On the basis of these previous observations, we set out to determine if MHC class I status and the presence of GrB⁺ or FoxP3⁺ T cells in the immune infiltrate of early-stage primary melanomas might be associated with the absence or presence of SLN metastases.

2. Materials and methods

2.1. Patient characteristics

Two groups of patients were selected from the melanoma database of the department of Surgical On-

cology at the VU University medical center based on the outcome of the SLN procedure to obtain 20 cases with a positive SLN and 20 cases with a negative SLN. All patients were diagnosed as stage I/II based on the Breslow thickness, and underwent a re-excision of the primary tumour and SLN procedure between October 1994 and September 2001. The 40 patients were selected to have comparable age, gender distribution and Breslow thickness to avoid a confounding effect of these known prognostic parameters. Both groups included 9 male and 11 female patients. From 12 of 20 patients with a positive SLN, paraffin-embedded tissue of the SLN metastasis was available to detect TIL populations in the tumour area in the affected sentinel node. In the remaining 9 patients no material was left for further analysis.

2.2. Antibodies and immunohistochemistry

Paraffin-embedded 3- μ m tissue sections of primary melanoma excisional biopsies were stained as previously described [5]. Lymphocytes were characterised for expression of GrB using monoclonal antibody (mAb) GrB7 (mouse IgG2a; VU University Medical Centre, Amsterdam, The Netherlands) specific for human GrB [13] and for expression of FoxP3 (rat IgG2a, PCH101; e-Biosciences, San Diego, CA, USA). Expression of MHC class I antigen on melanoma cells was investigated using polyclonal antibody β 2-microglobulin (β 2m) (rabbit Ig, A0072 Dako; Heverlee, Belgium), the mAb HCA2 reactive with HLA-A locus products, and mAb HC10 recognizing HLA-B/C locus products [22]. For staining with antibodies against FoxP3 and HLA-B/C, antigen retrieval was performed with 10 mM Na-citrate (pH 6) and for staining with antibodies against GrB and HLA-A, retrieval was performed with 10 mM TRIS, 1 mM EDTA (pH 9). No antigen retrieval was required for staining with anti- β 2m. Following antigen retrieval, primary antibodies were applied and visualization was performed with either the EnvisionTM horseradish peroxidase system (DakoCytomation, Glostrup, Denmark) for HCA2, HC10 and β 2m, or the Power Vision plusTM system (Immunologic, Duiven, The Netherlands) for GrB and FoxP3 staining according to the manufacturer's instructions.

2.3. Interpretation of the immunohistochemical staining

Two independent observers, including an experienced pathologist and blinded to the SLN status,

performed scoring of immunohistochemically stained slides based on at least ten high power fields. A high power field references the area visible using a 400× magnification level. Lymphocytes surrounding the tumour served as an internal control for interpretation of GrB, FoxP3, and MHC class I antigen expression. The difference between melanoma cells and lymphocytes was based on morphological examination. GrB was used as a marker for activated TILs with cytolytic ability and FoxP3 was used as a marker for suppressive TILs [16]. GrB⁺ and FoxP3⁺ TILs were scored as either positive (>1 positive TIL per high power field) or negative (<1 TIL per high power field). Expression of HLA-A, HLA-B/C and β 2m on melanoma cells was scored semi-quantitatively in steps of 10% from 0% to 100%. The median percentage of tumour cells expressing HLA-A, HLA-B/C and β 2m was determined. MHC class I expression was considered preserved if expression of both HLA-A, HLA-B/C and β 2m was detected on a higher number of the tumour cells than the median percentage. Cases in which one of the MHC class I antigen markers was expressed below the median percentage, were categorized as “lost MHC class I antigen expression”.

2.4. Statistical analysis

All analyses were performed using the SPSS statistical software (version 12 SPSS, Inc., Chicago, IL).

Differences between the groups were analysed using Pearson's χ^2 test or Fisher exact test when appropriate. The Mann–Whitney *U*-test was used to compare group means. All *p* values were based on two-tailed statistical analysis. *p* values ≤ 0.05 were considered significant.

3. Results

3.1. Patients and clinical characteristics

Clinical characteristics are listed in Table 1. The 20 patients with a SLN metastasis had a median follow-up period of 83 (range: 24–147) months and the 20 patients without a SLN metastasis had a median follow-up period of 102 (range: 65–137) months. Thirty-five patients were free of disease at the time of last follow-up, while one patient in the SLN-positive group died of a disease-unrelated cause and four patients had developed distant metastases resulting in death in two of these patients.

3.2. Presence of sentinel lymph node metastasis correlates with absence of GrB⁺ TILs in primary melanoma excisional biopsies

In 19 out of the 20 patients selected for negative SLN status, GrB⁺ TILs (Fig. 1A) were present in the

Table 1
Clinical and primary melanoma characteristics of SLN⁻ and SLN⁺ patients*

	Sentinel lymph node		<i>p</i> value
	Negative (<i>n</i> = 20)	Positive (<i>n</i> = 20)	
Patients			
Gender (male/female)	9/11	9/11	ns
Median age (years)	49	41	ns
Median follow-up (months)	102 (65–137)	83 (24–147)	ns
Median Breslow (\pm st. dev.)	1.36 (\pm 0.5) mm	1.32 (\pm 0.2) mm	ns
Primary melanoma excisional biopsies			
GrB ⁺ TILs			
Absent	1	11	0.001
Present	19	9	
FoxP3 ⁺ TILs			
Absent	8	11	ns
Present	12	9	
MHC class I antigen expression			
Loss**	13	13	ns
Preserved***	7	7	

*SLN = Sentinel lymph node.

**Defined as <70% (i.e. median) HLA-A/B/C expression (p9).

***Defined as $\geq 70\%$ HLA-A/B/C expression (p9).

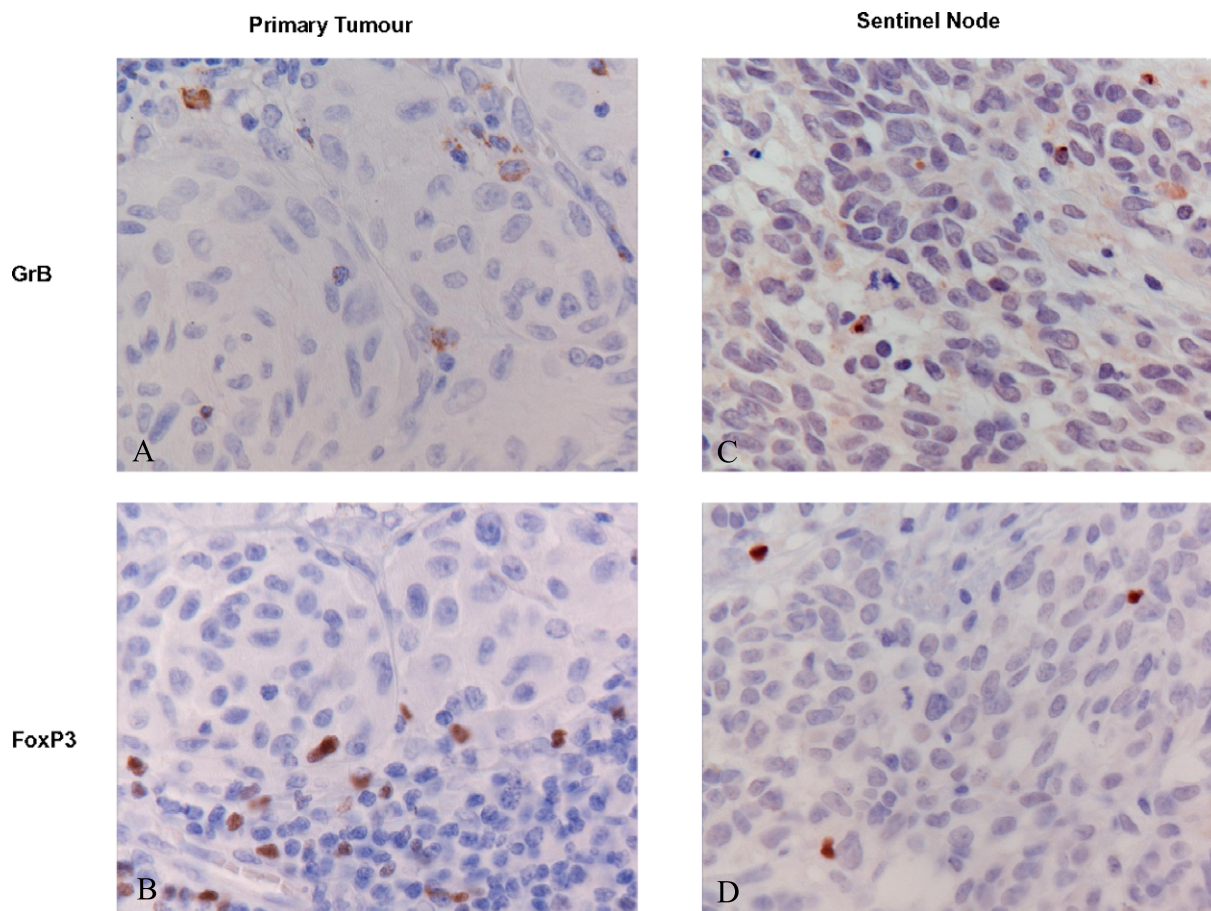


Fig. 1. Photographs of images of immunohistochemical staining of TILs. A representative primary melanoma biopsy of a patient with a negative SLN with: (A) GrB⁺ TILs and (B) FoxP3⁺ TILs, and a representative biopsy of a SLN metastasis with: (C) GrB⁺ TILs and (D) FoxP3⁺ TILs.

primary tumour. Primary melanomas of 9 patients from the SLN positive group, however, also contained GrB⁺ TILs. Thus, a direct association with presence of GrB⁺ TILs and a negative SLN status was not observed. In contrast, absence of GrB⁺ TILs in the primary tumour was strongly associated with SLN metastasis: primary melanoma excisional biopsies of 12 patients did not contain any GrB⁺ TILs and for 11 of these 12 patients a metastasis was detected in the SLN ($p = 0.001$, see Table 1). While an inverse correlation between suppressive FoxP3⁺ T cells and GrB⁺ effector T cells might *a priori* have been expected, the opposite was actually found: primary melanomas with GrB⁺ TILs most often also harboured FoxP3⁺ TILs (Fig. 1B and Table 2). The expected correlation between the presence of FoxP3⁺ TILs in primary tumours and the presence of metastases in SLN was also not observed (Table 1).

3.3. Presence of MHC class I antigen expression on primary tumour cells does not correlate with SLN status

Complete loss of MHC class I antigen expression in the primary melanoma was observed in one case. All other patients showed expression of the three different MHC-I markers ranging from 10% to 100%. Based on the median percentages of positive cells, MHC class I antigen expression was considered preserved if expression of HLA-A/B/C and $\beta 2m$ was detected on $\geq 70\%$ of the melanoma cells. No correlation was observed between preserved MHC class I antigen expression and either GrB⁺ T cell infiltration or SLN status (Table 1).

3.4. Both FoxP3⁺ and GrB⁺ TILs are frequently detected in SLN metastases

Paraffin-embedded tissue of the melanoma positive SLN was available from 12 out of 20 patients with

Table 2
Expression of MHC class I and presence of GrB⁺ and FoxP3⁺ TILs in primary melanoma excisional biopsies and SLN metastasis

	GrB ⁺ TILs absent	GrB ⁺ TILs present	<i>p</i> value
Primary melanoma biopsy	<i>n</i> = 12	<i>n</i> = 28	
FoxP3 ⁺ TILs			ns
Absent	8	11	
Present	4	17	
MHC class I antigen expression			ns
Loss*	10	16	
Preserved**	2	12	
SLN metastasis			
FoxP3 ⁺ TILs			ns
Absent	1	1	
Present	2	7	
MHC class I antigen expression			ns
Loss*	3	3	
Preserved**	0	1	

*Defined as <70% (i.e. median) HLA-A/B/C expression (p9).

**Defined as ≥70% HLA-A/B/C expression (p9).

a SLN metastasis. In most cases both GrB⁺ TILs (Fig. 1C) and FoxP3⁺ TILs (Fig. 1D) were detected in the metastatic melanoma area (Table 2). In 7 of these 12 patients MHC class I expression on tumour cells infiltrated in the SLN could be determined, while in the remaining five not enough tumour tissue was left in the tissue blocks after diagnostic examination to make a reliable assessment. Of note, in 6 of the 7 evaluable patients a loss of MHC class I expression was observed. However, no correlation was found between preserved MHC class I expression and presence of GrB⁺ TILs.

4. Discussion

In this study we demonstrate that absence of GrB⁺ TILs in primary melanoma excisional biopsies is strongly associated with SLN metastasis, as GrB⁺ TILs were nearly always (19/20 cases) present in primary melanoma excisional biopsies of patients with a negative SLN.

The two groups of patients, either with or without a SLN metastasis, were stratified for relevant co-variables, i.e. selected for comparable prognostic factors (Breslow thickness, gender and age). Therefore, the differences in the cellular immune response as we describe in this report, are more likely to be associated with differences in SLN status than with other confounding clinical factors. These results are in line with our previous studies, demonstrating that the presence

of activated GrB⁺ TILs is strongly associated with a favourable outcome in clinically stage I/II patients [27] and may also have a favourable impact on survival in patients with more advanced melanoma [26]. Furthermore, our data are in accordance with a recent study demonstrating that absence of CD3⁺ TILs predicts SLN metastasis in cutaneous melanoma patients [25].

We hypothesize that when GrB⁺ TILs are present in the primary tumour, they are capable of inhibiting or delaying the occurrence of melanoma lymph node metastasis. The cellular immune response, however, is apparently not able to clear the primary tumour itself. In a substantial number of cases (9 out of 20) GrB⁺ TILs were also observed in the primary tumour of patients with a SLN metastasis. Although absence of GrB⁺ TILs in the primary tumour is associated with the presence of SLN metastasis, the reverse is therefore not true. Apparently, an active cellular immune response is not sufficient for prohibiting the spread of melanoma cells to lymph nodes. In 6 of these 9 patients the occurrence of a positive SLN status despite presence of GrB⁺ TILs in the primary tumour, might be explained by presence of FoxP3⁺ suppressive TILs in the primary tumour. Although it is now accepted that in humans FoxP3 is not an exclusive marker for naturally occurring regulatory T cells (nTregs) as it can be expressed by other effector T cells upon activation, FoxP3⁺ T-lymphocytes are considered to be generally suppressive and may be involved in the induction of immunotolerance in lymph node metastases [28,31].

While a novel model for the role of GrB in FoxP3⁺ Treg-mediated suppression of anti-tumour CD8⁺ T cells has recently been proposed [7], the actual effector function of GrB in Tregs remains poorly understood. We were unable to detect GrB and FoxP3 co-localization in TILs in the primary tumour (unpublished data) and found no correlation between FoxP3⁺ TILs and GrB⁺ TILs, which supports the assumption that the detected GrB⁺ TILs are likely not Tregs. We hypothesize that presence of FoxP3⁺ suppressive TILs in the primary tumour, next to GrB⁺ effector TILs (both markers of possible activation), might result in active suppression of the latter and thus facilitate tumour escape, despite the presence of immune effector cells with a GrB-mediated cytolytic potential. Such local immune suppression might also explain the presence of apparently ineffective GrB⁺ TILs in SLN metastases, since most of these harboured FoxP3⁺ TILs as well.

Loss (either partial or total) of MHC class I antigen expression was observed in a significant number of melanomas as described before [8], and is in accordance with our previous results. Loss of MHC class I antigen expression on melanoma cells was nearly always associated with a lack of GrB⁺ TILs (Table 2). Although no correlation was present between MHC class I antigen expression and SLN status, a trend for association with clinical outcome was observed, because all patients with recurrence of disease ($n = 4$) showed loss of MHC class I antigen expression. Moreover, the finding of MHC class I loss in 6 out of 7 SLN metastases is highly suggestive of a role for MHC class I down-regulation in early immune escape of melanoma and regional spread to the draining lymph nodes.

In conclusion, absence of GrB⁺ TILs in primary melanoma excisional biopsies is strongly associated with the presence of SLN metastasis. These data underscore the notion that an activated cellular immune response is important in preventing melanoma cells to disseminate to lymph nodes. In addition, absence of GrB⁺ TILs in primary melanoma excisional biopsies in immunohistochemistry might be used to predict presence of SLN metastasis. Although confirmation in a larger number of patients is clearly needed, the absence of GrB⁺ TILs might prove a useful diagnostic tool to distinguish patients with invasive melanoma that might benefit from immediate full regional lymph node dissection.

Acknowledgements

The diagnostic melanoma excisional biopsies we obtained from either our own pathology department or were kindly provided by the pathology departments of the hospitals in which the primary biopsy was taken: MCA (Alkmaar), Gelderse vallei Hospital (Ede), PA laboratory East Netherlands (Enschede), SPALK (Haarlem), Leids cytology laboratory (Leiden), IJsselmeer Hospital (Lelystad), Waterland Hospital (Purmerend), Ikazia Hospital (Rotterdam), Academisch Medisch Centrum (Amsterdam), Antoni van Leeuwenhoek Hospital (Amsterdam), St. Lucas-Andreas Hospital (Amsterdam), BovenIJ Hospital (Amsterdam) and Slotervaart Hospital (Amsterdam), all in the Netherlands. Antibodies HCA2 and HC10 to detect MHC class I molecules were kindly provided by Prof. Dr. J. Neeffjes, Netherlands Cancer Institute, Amsterdam, The Netherlands.

Financial support: Grant of the VU University medical center. Supported by the Vivax foundation.

References

- [1] S.E. Al-Batran, M.R. Rafiyan, A. Atmaca, A. Neumann, J. Karbach, A. Bender, E. Weidmann, H.M. Altmannsberger, A. Knuth and E. Jäger, Intratumoral T-cell infiltrates and MHC class I expression in patients with stage IV melanoma, *Cancer Res.* **65** (2005), 3937–3941.
- [2] P.F. Austin, C.W. Cruse, G. Lyman, K. Schroer, F. Glass and D.S. Reintgen, Age as a prognostic factor in the malignant melanoma population, *Ann. Surg. Oncol.* **1** (1994), 487–494.
- [3] C.M. Balch, S.J. Soong, J.E. Gershenwald, J.F. Thompson, D.S. Reintgen, N. Cascinelli, M. Urist, K.M. McMasters, M.I. Ross, J.M. Kirkwood, M.B. Atkins, J.A. Thompson, D.G. Coit, D. Byrd, R. Desmond, Y. Zhang, P.Y. Liu, G.H. Lyman and A. Morabito, Prognostic factors analysis of 17,600 melanoma patients: validation of the American Joint Committee on Cancer melanoma staging system, *J. Clin. Oncol.* **19** (2001), 3622–3634.
- [4] M.J. Bevan, Helping the CD8(+) T-cell response, *Nat. Rev. Immunol.* **4** (2004), 595–602.
- [5] B.A. Bladergroen, M.C. Strik, N. Bovenschen, O. van Berkum, G.L. Scheffer, C.J. Meijer, C.E. Hack and J.A. Kummer, The granzyme B inhibitor, protease inhibitor 9, is mainly expressed by dendritic cells and at immune-privileged sites, *J. Immunol.* **166** (2001), 3218–3225.
- [6] A. Breslow, Thickness, cross-sectional areas and depth of invasion in the prognosis of cutaneous melanoma, *Ann. Surg.* **172** (1970), 902.
- [7] X. Cao, S.F. Cai, T.A. Fehniger, J. Song, L.I. Collins, D.R. Piwnica-Worms and T.J. Ley, Granzyme B and perforin are important for regulatory T cell-mediated suppression of tumor clearance, *Immunity* **27** (2007), 635–646.

- [8] S. Ferrone and F.M. Marincola, Loss of HLA class I antigens by melanoma cells: molecular mechanisms, functional significance and clinical relevance, *Immunol. Today* **16** (1995), 487–494.
- [9] J.D. Fontenot, M.A. Gavin and A.Y. Rudensky, Foxp3 programs the development and function of CD4⁺CD25⁺ regulatory T cells, *Nat. Immunol.* **4** (2003), 330–336.
- [10] S. Hori, T. Nomura and S. Sakaguchi, Control of regulatory T cell development by the transcription factor Foxp3, *Science* **299** (2003), 1057–1061.
- [11] T. Kageshita, S. Hirai, T. Ono, D.J. Hicklin and S. Ferrone, Down-regulation of HLA class I antigen-processing molecules in malignant melanoma: association with disease progression, *Am. J. Pathol.* **154** (1999), 745–754.
- [12] S.A. Kalams and B.D. Walker, The critical need for CD4 help in maintaining effective cytotoxic T lymphocyte responses, *J. Exp. Med.* **188** (1998), 2199–2204.
- [13] J.A. Kummer, A.M. Kamp, T.M. Tadema, W. Vos, C.J. Meijer and C.E. Hack, Localization and identification of granzymes A and B-expressing cells in normal human lymphoid tissue and peripheral blood, *Clin. Exp. Immunol.* **100** (1995), 164–172.
- [14] D. Meyer, J. Schubert, C. Scholz, S. Braun and R.E. Schmidt, MHC-I antigen expression determines sensitivity of hematopoietic progenitor cells as targets for NK cells, *Immunobiology* **197** (1997), 494–504.
- [15] D.L. Morton, L. Wanek, J.A. Nizze, R.M. Elashoff and J.H. Wong, Improved long-term survival after lymphadenectomy of melanoma metastatic to regional nodes. Analysis of prognostic factors in 1134 patients from the John Wayne Cancer Clinic, *Ann. Surg.* **214** (1991), 491–501.
- [16] V. Mourmouras, M. Fimiani, P. Rubegni, M.C. Epistolato, V. Malagnino, C. Cardone, E. Cosci, M.C. Nisi and C. Miracco, Evaluation of tumour-infiltrating CD4⁺CD25⁺FOXP3⁺ regulatory T cells in human cutaneous benign and atypical naevi, melanomas and melanoma metastases, *Br. J. Dermatol.* **157** (2007), 531–539.
- [17] N. Nathanson, Spontaneous regression of malignant melanoma: a review of the literature on incidence, clinical features, and possible mechanisms, *Natl. Cancer Inst. Monogr.* **44** (1976), 67–76.
- [18] N.P. Restifo, F.M. Marincola, Y. Kawakami, J. Taubenberger, J.R. Yannelli and S.A. Rosenberg, Loss of functional beta 2-microglobulin in metastatic melanomas from five patients receiving immunotherapy, *J. Natl. Cancer Inst.* **88** (1996), 100–108.
- [19] D.J. Ruiter, V. Mattijssen, E.B. Broecker and S. Ferrone, MHC antigens in human melanomas, *Semin. Cancer Biol.* **2** (1992), 35–45.
- [20] J.V. Schaffer, D.S. Rigel, A.W. Kopf and J.L. Bolognia, Cutaneous melanoma—past, present, and future, *J. Am. Acad. Dermatol.* **51** (2004), S65–S69.
- [21] C.R. Scoggins, M.I. Ross, D.S. Reintgen, R.D. Noyes, J.S. Goydos, P.D. Beitsch, M.M. Urist, S. Ariyan, B.S. Davidson, J.J. Sussman, M.J. Edwards, R.C. Martin, A.M. Lewis, A.J. Stromberg, A.J. Conrad, L. Hagendoorn, J. Albrecht and K.M. McMasters, Sunbelt Melanoma Trial. Gender-related differences in outcome for melanoma patients, *Ann. Surg.* **243** (2006), 693–698.
- [22] N.J. Stam, T.M. Vroom, P.J. Peters, E.B. Pastoors and H.L. Ploegh, HLA-A- and HLA-B-specific monoclonal antibodies reactive with free heavy chains in western blots, in formalin-fixed, paraffin-embedded tissue sections and in cryo-immuno-electron microscopy, *Int. Immunol.* **2** (1990), 113–125.
- [23] M.G. Stenius Muller, P.A. van Leeuwen, E.S. de Lange-De Klerk, P.J. van Diest, R. Pijpers, C.C. Ferwerda, R.J. Vuylsteke and S. Meijer, The sentinel lymph node status is an important factor for predicting clinical outcome in patients with Stage I or II cutaneous melanoma, *Cancer* **91** (2001), 2401–2408.
- [24] A. Streetly and H. Markowe, Changing trends in the epidemiology of malignant melanoma: Gender differences and their implications for public health, *Int. J. Epidemiol.* **24** (1995), 897–907.
- [25] R.C. Taylor, A. Patel, K.S. Panageas, K.J. Busam and M.S. Brady, Tumor-infiltrating lymphocytes predict sentinel lymph node positivity in patients with cutaneous melanoma, *J. Clin. Oncol.* **25** (2007), 869–875.
- [26] I.S. van Houdt, J.J. Oudejans, A.J. van den Eertwegh, A. Baars, W. Vos, B.A. Bladergroen, D. Rimoldi, J.J. Muris, E. Hooijberg, C.M. Gundy, C.J. Meijer and J.A. Kummer, Expression of the apoptosis inhibitor protease inhibitor 9 predicts clinical outcome in vaccinated patients with stage III and IV melanoma, *Clin. Cancer Res.* **11** (2005), 6400–6407.
- [27] I.S. van Houdt, B.J. Sluiter and L. Moesbergen, Favorable outcome in clinically stage II melanoma patients is associated with the presence of activated tumor infiltrating T-lymphocytes and preserved MHC class I antigen expression, *Int. J. Cancer* **123** (2008), 609–615.
- [28] M. Viguier, F. Lemaître, O. Verola, M.S. Cho, G. Gorochov, L. Dubertret, H. Bachelez, P. Kourilsky and L. Ferradini, Foxp3 expressing CD4⁺CD25 (high) regulatory T cells are overrepresented in human metastatic melanoma lymph nodes and inhibit the function of infiltrating T cells, *J. Immunol.* **173** (2004), 1444–1453.
- [29] R.J. Vuylsteke, P.J. Borgstein, P.A. van Leeuwen, H.A. Gietema, B.G. Molenkamp, M.G. Stenius Muller, P.J. van Diest, J.R. van der Sijp and S. Meijer, Sentinel lymph node tumor load: an independent predictor of additional lymph node involvement and survival in melanoma, *Ann. Surg. Oncol.* **12** (2005), 440–448.
- [30] H. Yagi, T. Nomura, K. Nakamura, S. Yamazaki, T. Kitawaki, S. Hori, M. Maeda, M. Onodera, T. Uchiyama, S. Fujii and S. Sakaguchi, Crucial role of FOXP3 in the development and function of human CD25⁺CD4⁺ regulatory T cells, *Int. Immunol.* **16** (2004), 1643–1656.
- [31] S.F. Ziegler, FOXP3: not just for regulatory T cells anymore, *Eur. J. Immunol.* **37** (2007), 21–23.