


Soft tissue contour and radiographic evaluation of ridge preservation in early implant placement: A randomized controlled clinical trial

Brend Pjotr Jonker¹  | Alfonso Gil² | Nadja Naenni² | Ronald Ernst Jung²  |
Eppo Bonne Wolvius¹ | Justin Pijpe^{1,3}

¹Department of Oral & Maxillofacial Surgery, Special Dental Care and Orthodontics, Erasmus University Medical Center, Rotterdam, The Netherlands

²Clinic of Reconstructive Dentistry, Center of Dental Medicine, University of Zurich, Zurich, Switzerland

³Department of Oral & Maxillofacial Surgery, Catharina Hospital Eindhoven, Eindhoven, The Netherlands

Correspondence

Brend Pjotr Jonker, Department of Oral and Maxillofacial Surgery, Erasmus Medical Center, Dr. Molewaterplein 40, 3015 GD Rotterdam, The Netherlands.
Email: b.jonker@erasmusmc.nl

Funding information

Implants were provided by Straumann AG and biomaterials by Geistlich Pharma AG.

Abstract

Objectives: To compare two ridge preservation techniques and spontaneous healing in terms of hard and soft tissue changes 2 months after tooth extraction.

Material and methods: The study was designed as a randomized controlled trial and included 75 patients. After single tooth extraction in the maxillary incisor/premolar area, patients were randomly allocated to one of the following groups: (a) ridge preservation with a xenogeneic bone substitute covered with a collagen matrix (CM-group), (b) ridge preservation with a xenogeneic bone substitute covered with a free palatal graft (PG-group) or (c) spontaneous healing (control). Eight weeks after tooth extraction, implants were placed and clinical, profilometric and radiographic evaluations were performed. In addition, the need for further guided bone regeneration (GBR) at implant placement was assessed. The differences between the treatment groups were compared with the One-way ANOVA or Kruskal–Wallis test with the corresponding post hoc analysis. The proportions of the categorical parameters were compared with the Fisher's exact test.

Results: Seventy-five patients underwent early implant placement 8 weeks after tooth extraction and were evaluated. CM-group (-0.9 SD 0.6 mm) and PG-group (-1.0 SD 0.8 mm) showed less horizontal bone resorption compared to the control group (-3.2 SD 2.1 mm) ($p < .001$). Moreover, the necessity of GBR at implant placement was significantly less in CM-group (32%) and PG-group (24%) when compared to control group (72%) ($p = .001$). Patients in CM-group experienced less pain than PG-group, one week after tooth extraction ($p = .042$). No significant differences were found regarding graft evaluation, post-operative complications, and soft tissue contour.

Conclusions: Ridge preservation using a xenogeneic bone substitute covered with a collagen matrix or a palatal graft, results in less bone resorption and fewer GBR procedures at early implant placement compared to spontaneous healing.

KEYWORDS

bone regeneration, bone substitutes, clinical research, clinical trials, CT imaging, guided tissue regeneration, patient-centered outcomes

This is an open access article under the terms of the Creative Commons Attribution-NonCommercial-NoDerivs License, which permits use and distribution in any medium, provided the original work is properly cited, the use is non-commercial and no modifications or adaptations are made.

© 2020 The Authors. *Clinical Oral Implants Research* published by John Wiley & Sons Ltd

1 | INTRODUCTION

Replacement of a single tooth in the esthetic zone by means of implant therapy is a demanding procedure. Following tooth extraction, the alveolar ridge undergoes horizontal and vertical bone loss (Chappuis et al., 2013, 2015; Lang et al., 2012). This can negatively influence the ridge contour and thus the esthetic outcome (Chappuis et al., 2017). In order to achieve optimal esthetic results, both the bone and soft tissue contour should be preserved as good as possible. Ridge preservation is used to reduce the resorption of the ridge (Jung et al., 2018). The main goal of alveolar ridge preservation (ARP) procedures is to preserve both hard and soft tissue volume for future implant placement (Avila-Ortiz et al., 2019; Jung et al., 2018). Landsberg described a modified ridge preservation technique called “socket seal surgery,” where flap elevation is avoided and bone and soft tissue grafting is combined prior to implant placement. In addition to the application of a bone substitute material, an epithelialized palatal graft is used to seal the extraction site from the oral cavity immediately after tooth extraction (Landsberg & Bichacho, 1994). The application of a biomaterial at the extraction site, which is then covered with a collagen matrix or a free soft tissue graft, results in less vertical and horizontal changes of the alveolar ridge 4–6 months after extraction and can lead to good esthetic results at future implant sites (Jung et al., 2004, 2013; Lim et al., 2019). Combining ARP with early implant placement might offer the advantage of optimizing the soft tissues but without the drawback of a prolonged healing period (Thoma et al., 2020). Although applying a free soft tissue punch graft is a relatively straightforward procedure, patient morbidity is increased due to the second surgical site (Griffin et al., 2006). The use of a substitute material for soft tissue grafting would prevent donor morbidity associated with soft tissue grafts when performing ARP (Jung et al., 2013; Schneider et al., 2014). This is one of the first studies to evaluate two ARP techniques with spontaneous healing for early implant placement. The aim of current study was to evaluate the clinical results, profilometric and radiographic changes, as well as patient satisfaction following alveolar ridge preservation (ARP) in single sites in the anterior maxilla comparing the use of a bone substitute material of xenogeneic origin covered with either a xenogeneic collagen matrix or a free gingival graft (punch technique) versus spontaneous healing.

2 | MATERIAL AND METHODS

2.1 | Study design

The study protocol was approved by the medical ethical committee, the central committee on human subjects (MEC-2015-016; NL49965.078.14) and registered in the Dutch trial register (NL6497). This research was conducted according to the principles of the Declaration of Helsinki. The CONSORT statement was used for reporting (Moher et al., 2010). The study was designed as a randomized controlled clinical trial with patients being randomly allocated to one of two ARP techniques or a negative control group:

CM-group: Demineralized bovine bone mineral with added 10% collagen (Geistlich Bio-Oss® Collagen, Geistlich Pharma: DBBM-C), and covered with a collagen matrix (Geistlich Mucograft® Seal, Geistlich Pharma: CM).

PG-group: Demineralized bovine bone mineral with added 10% collagen (DBBM-C) covered with an autogenous soft tissue “punch” graft harvested from the palate (PG).

Control: Spontaneous healing.

2.2 | Randomization and treatment allocation

The patients were randomized in either the CM-group, PG-group, or control by digital software allocation according to the block method (Urbaniak & Plous, 2013). The allocation sequence was concealed from the surgeon (JP) in opaque, sealed envelopes, until the very last step in the surgical procedure (just after surgical removal of the tooth). Patients were not blinded as this was not possible. Reporting of clinical measurements was blinded, as the reporting clinician (JP) was unaware of the treatment group. The investigators were not aware of the allocation during the analysis of the data.

2.3 | Study population

All operations were performed at the Erasmus University Medical Center, Rotterdam and the Catherina Hospital, Eindhoven, the Netherlands. All patients were referred for implant placement by their general practitioner. In close cooperation with the referring dentist, a treatment plan was set up that included a surgical phase (extraction, ARP and implant placement) and a prosthetic phase in the dental office of the referring dentist (dental crown placement). All surgeries were performed by one surgeon (JP). Patients were considered for inclusion in this study when they fulfilled the following criteria:

Inclusion criteria

- Over 18 years of age
- Single tooth replacement
- Maxillary tooth at the location of an incisor, cuspid, or first/second premolar
- Patients able and willing to understand and follow the study procedures

Exclusion criteria

- Ongoing periodontal disease and bone loss
- Smoking
- Uncontrolled diabetes
- History of radiotherapy in the head-and-neck region
- Current chemotherapy
- Disability to maintain basic oral hygiene procedures

2.4 | Surgical procedure

Tooth extraction was performed carefully in order to preserve the buccal bone plate and the surrounding soft tissues. A flapless procedure was performed using periosteal elevators, and forceps. If needed, a drill was used to remove the tooth in multiple pieces. After extraction, any existing granulation tissue was removed and the socket was rinsed with sterile saline.

2.4.1 | CM-group

The soft tissue borders of the alveolus were de-epithelialized using a rotating diamond burr. The DBBM-C was placed within the socket up to the level of the lingual/palatal bone plate. The CM was placed on top of the DBBM-C and sutured to the gingival margins of the socket with 4 to 6 interrupted sutures (No. 4-0 Ethilon, Ethicon).

2.4.2 | PG-group

The soft tissue borders of the alveolus were de-epithelialized using a rotating diamond burr. The DBBM-C was placed within the socket up to the level of the lingual/palatal bone plate. A suitable site for graft harvesting at the patient's palate was chosen, keeping a distance of 4 to 5 mm to the gingival margin. A free gingival graft with a target thickness of 4- to 5-mm thickness was harvested with a biopsy punch and gently removed with a sharp tissue elevator. Bleeding was stopped by compression with a sterile gauze. The soft tissue defect (mucosa or periosteum) was then covered with a tissue glue (Histoacryl, B. Braun Medical B.V.). The harvested graft was placed on top of the DBBM-C and sutured to the marginal gingiva of the socket with 4 to 6 interrupted sutures (No. 4-0 Ethilon, Ethicon). If the harvested graft was higher than the buccal or palatal soft tissues of the recipient sites, the graft was adapted according to these dimensions.

2.4.3 | Control

After cleaning and rinsing the socket with sterile saline solution, a cross-mattress suture (No. 4-0 Ethilon, Ethicon) was used to keep the blood clot in place allowing spontaneous healing of the site.

All patients in the three treatment groups were instructed to rinse twice a day with a 0.12% Chlorhexidine solution and received pain medication (Ibuprofen) and antibiotics (Amoxicillin) for 5 days. Sutures were removed after 1 week.

2.4.4 | Implant placement

Eight weeks after tooth extraction implants were placed. The implants placed had a diameter of 4.1 or 3.3 mm, and a length of 8 to

12 mm (Bone Level Tapered implants, Institute Straumann AG). After raising a mucoperiosteal flap from the top of the alveolar process, implants were placed according to the manufacturers guidelines. In case of thin a thin buccal plate (<1 mm) or a dehiscence at the buccal aspect, a guided bone regeneration (GBR) was performed. This implied coverage of the titanium surface of the dental implant with locally harvested autogenous bone, covered with DBBM (Geistlich Bio-Oss[®], Geistlich Pharma AG) and subsequent coverage with a resorbable membrane (Geistlich Bio-Gide[®], Geistlich Pharma AG). The autogenous bone chips were harvested via the existing flap or a relatively small extension of the flap.

2.5 | Outcome measurements

Figure 1 shows an overview of the treatment and follow-up sequence of the three treatment groups. Figure 2 illustrates the surgical procedure in the three different groups and follow-up after 1 and 8 weeks. The null hypothesis is that there is no difference between the three treatment groups for the following outcome measurements.

2.5.1 | Clinical evaluation of the soft tissue healing after ridge preservation

The status of the grafted area was visually assessed at 1 and 8 weeks following grafting (Jung et al., 2004). The soft tissue was classified as:

- Integrated: supplied with blood, indicated by a reddish tissue color
- Fibrinoid: covered with fibrin and responding by bleeding after removal of the fibrinoid surface

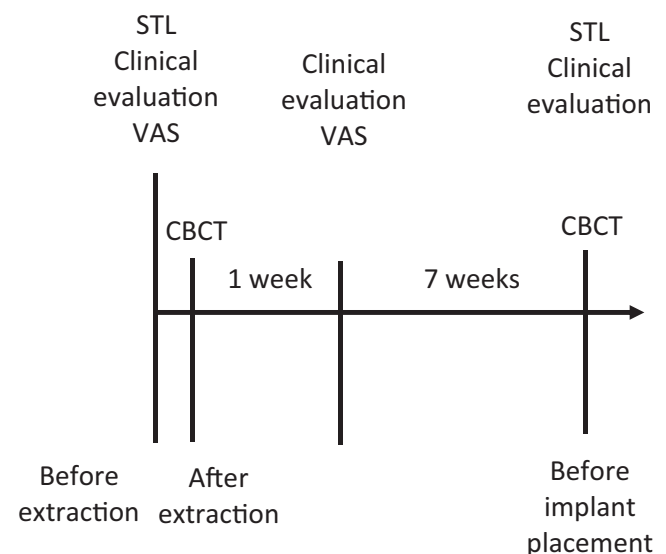
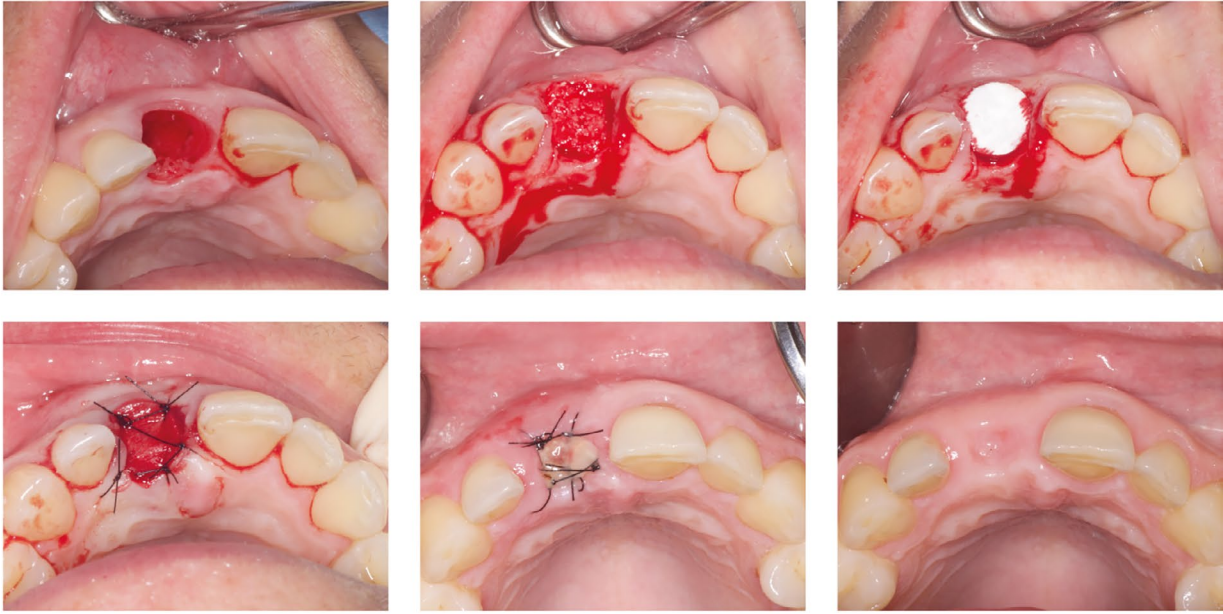
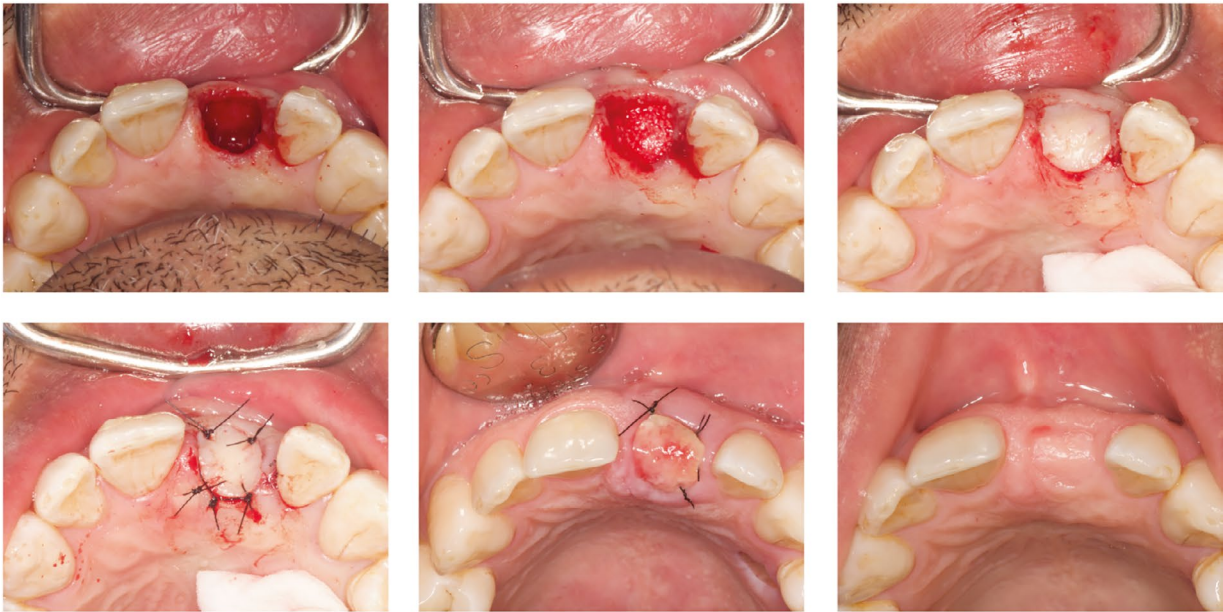


FIGURE 1 Overview of the treatment and follow-up sequence

CM-group



PG-group



Control

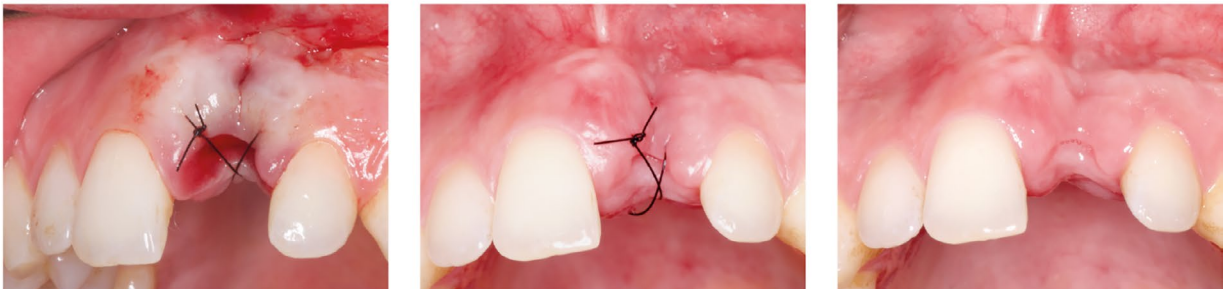


FIGURE 2 The surgical procedure in the three different groups and follow-up after 1 and 8 weeks

- Incomplete (partially integrated): incomplete wound closure, area of epithelial invagination, and access to the graft material with a periodontal probe
- Necrotic (not integrated): no signs of blood supply

Clinical evaluation of the soft tissue healing was carried out by one person (JP).

All adverse events such as signs of infection, post-operative bleeding, and allergic reactions were evaluated during all follow-up visits.

2.5.2 | Horizontal soft tissue contour changes

Alginate (Cavex CA37, Cavex Holland) impressions of the patients were taken at baseline (before extraction) and 8 weeks thereafter at the time of implant placement. Alginate was mixed using an automatic alginate mixer (Cavex Alginate Mixer, Cavex Holland). Pouring and casting was performed the next day by the dental laboratory. For the evaluation of the soft tissue contour changes, the poured plaster models were scanned with a surface scanner (7Series Model & Impression Scanner, Dental Wings). The obtained standard tessellation language (stl)-files were imported into a software for profilometric analysis (Swissmeda/SMOP). Digital cast models representing the time point before extraction and before implant placement (8 weeks after extraction) were superimposed by selecting three common points in both models for an automatic superimposition, followed by manual superimposition of both models in all three dimensions. The relevant area for the measurements of contour changes was defined according to previous studies on ridge contour alterations (Fickl et al., 2009; Schneider et al., 2011; Thoma et al., 2010). The area was defined horizontally by the mesial and distal papillary midline and vertically by the mucogingival line, and was measured 1 mm apical to the pre-extraction gingival margin. The area of interest was a rectangle measuring 4 mm in width and 2 mm in height. The mean change in the soft tissue contour per area was obtained by calculating in millimeters the mean value of all distances in labial direction contained in that area of interest.

2.5.3 | Horizontal and vertical radiographic changes

To perform the radiographic measurements, cone-beam computer tomograph (CBCT) scans at baseline (before extraction) and at 8 weeks post-extraction (before implant placement) were processed using the same software for profilometric analysis. The smallest field possible for the CBCT device and maximal axial slice thickness of 1 mm was used. The horizontal and vertical measurements were calculated using the center of the long axis of the alveolus as a reference (Figure 3). The most apical point of the extraction socket was defined in the baseline image and two reference lines were subsequently drawn. The vertical reference line was drawn in the center following the long axis of the healed extraction socket crossing the apical

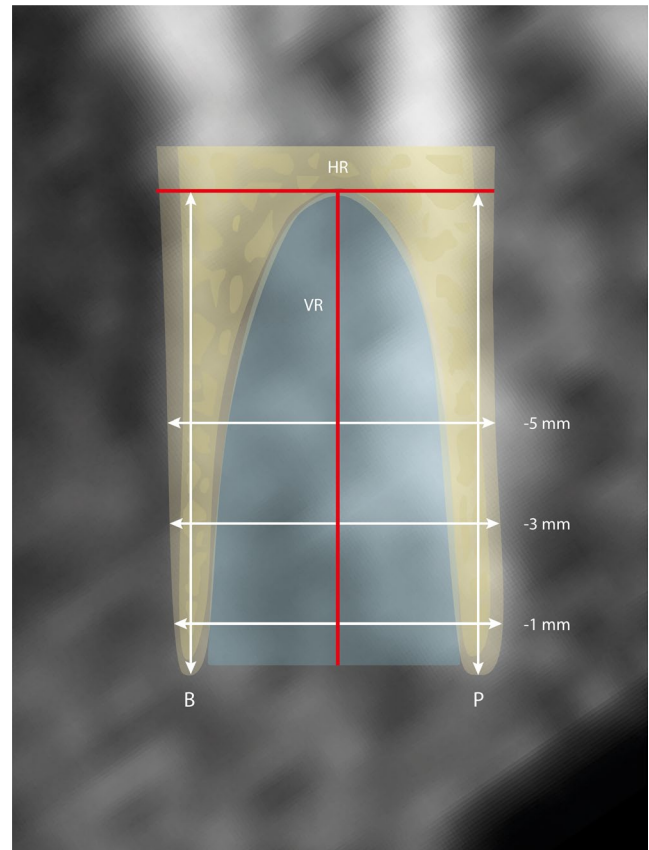


FIGURE 3 Horizontal and vertical radiographic changes. HR, horizontal reference line; VR, vertical reference line; B, buccal side; P, palatal side

reference point. The horizontal reference line was drawn perpendicular to the vertical line crossing the apical reference point. The following measurements with respect to these reference points and lines were performed in the center of the extraction socket at baseline and at 8 weeks post-extraction:

- The horizontal ridge width measured at -1, -3, and -5 mm depth from the level of the palatal crest parallel to the horizontal reference line.
- The vertical ridge height measured from the apex of the alveolus to the buccal and palatal crest, parallel to the vertical reference line.

2.5.4 | Soft tissue dimensions at implant placement

Both the CBCT and the STL data obtained at 8 weeks post-extraction were imported into the above-described analysis software. Both were superimposed by selecting three common points to both surfaces for the automatic superimposition, followed by the manual superimposition in the three dimensions. The vertical reference line was drawn in the center following the long axis of the healed extraction socket crossing the apex (Figure 4). The horizontal reference line was drawn perpendicular to the vertical line at -1 mm depth from the palatal

bone crest. The following measurements were then performed in the center of the extraction socket at 8 weeks post-extraction:

- The horizontal thickness of the tissue was calculated in millimeters on the buccal and palatal side.
- The vertical thickness of the tissue was calculated in millimeters at the center vertical reference line of the alveolus.

2.5.5 | Necessity of additional augmentation

A thin buccal wall (<1 mm) or dehiscence of the buccal wall after implant placement was reconstructed with the above-mentioned GBR technique. Necessity of this additional augmentation was recorded and evaluated.

2.5.6 | Patient-reported outcomes

At follow-up, the influence of the treatment on patient satisfaction was investigated by a patient's questionnaire (before treatment and 1 week after tooth extraction by a visual analog scale (VAS) ranging from 1–10. Pain, swelling, and impact of the surgery were evaluated.

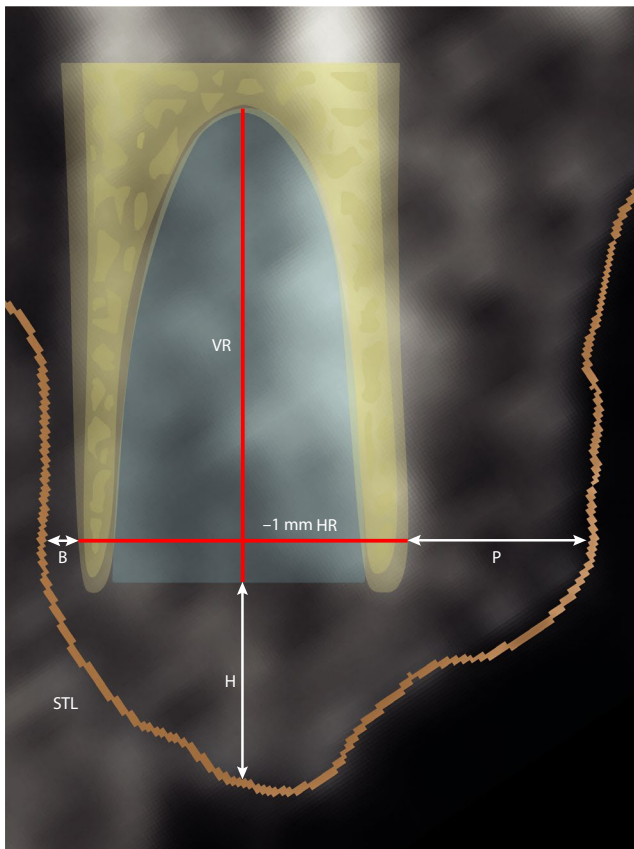


FIGURE 4 Soft tissue dimensions. HR, horizontal reference line; VR, vertical reference line; B, buccal mucosal thickness; P, palatal mucosal thickness; H, mucosal height; STL, superimposed soft tissues

2.6 | Statistical analysis

For nominal and dichotomous outcome data, significant differences between groups were calculated using the Fisher-Freeman-Halton exact test with post hoc pairwise Fisher's exact tests. A p -value <.05 was considered a significant difference. A Bonferroni correction for multiple comparisons was used. For the continuous outcomes, means were presented together with standard deviations (SD's) and medians with the first and third interquartile ranges. Means and SD's were additionally calculated for the non-normal distributed data to compare the data to other studies. To observe possible differences between the 3 treatment arms, the one-way ANOVA was used and presented. If a significant difference was observed between the groups from the one-way ANOVA, a Tukey's honestly significant difference post hoc analysis was performed to check which specific groups differed. If there were outliers the test was re-run without the outliers to check if results were different. If other assumptions for the ANOVA were not met (assessed by the Shapiro-Wilk test of normality and Levene's test of homogeneity of variances), the non-parametric Kruskal-Wallis test was used and were significantly different, post hoc analysis was performed using Dunn's procedure. A Bonferroni correction for multiple comparisons was used for both procedures and adjusted p -values were presented. As thin wall phenotypes (incisor and cuspid area) often show a progressive bone resorption in contrary to thicker bone wall biotypes (premolar area), a subgroup analysis was performed with the patients receiving an implant in the incisors/cuspid area and premolar area separately. (Chappuis et al., 2017) All analyses were performed using IBM SPSS Statistics for Mac, version 26.0: IBM Corp. Sample size calculation of this randomized controlled trial is based on the change in marginal soft tissue between the three groups one year after 1 year of loading. For similar patients, the SD of these changes was 0.58 mm (Buser et al., 2009). A difference of 0.5 mm is considered a relevant difference leading to 21 patients/group for a power of 80% and alpha = 0.05. To allow for some drop-out cases, 25 patients per group were randomized.

3 | RESULTS

3.1 | Baseline characteristics

Patients were recruited between June 2015 and June 2017. The CONSORT flow diagram of patients assessed, allocated, and analyzed is displayed in Figure 5. During inclusion 75 patients were assessed for eligibility and randomized to one of the 3 groups (25 patients in each group). One patient in the control group was wrongly treated according to the palatal graft-group (PG-group) protocol. As suggested by the CONSORT guidelines this patient was analyzed according to randomization. No patients were lost over the 8-week follow-up. In total, 36 patients were included for treatment in the incisor/cuspid area and 39 patients for the premolar area. Baseline characteristics are shown in Table 1.

3.2 | Graft evaluation and complications

One week after ridge preservation all sites were clinically evaluated. In the group receiving a collagen matrix (CM-group), 10 grafts (40%) were judged as integrated, 12 as fibrinoid (48%), 2 as partially integrated (8%), and 1 as not integrated (4%). In the group receiving an autologous graft (PG-group), 13 grafts (52%) were judged as integrated, 8 as fibrinoid (32%), 1 as partially integrated (4%), and 3 as not integrated (12%). The distribution was not statistically different between both groups ($p = .496$). After eight weeks all sites in the CM-group had fully healed, whereas in group PG 2 grafts (8%) still showed incomplete healing. One patient in group PG had an allergic skin reaction to chlorhexidine, which cleared spontaneously. Another patient in PG-group needed bipolar electrocoagulation of the donor area because of prolonged bleeding. Apart from this, no complications occurred.

3.3 | Horizontal soft tissue contour changes

The mean change of soft tissue contour measured -1.5 SD 0.6 mm in CM-group, -1.3 SD 0.8 mm in PG-group, and -1.7 SD 0.9 mm in the control group. There were no statistically significant differences between the different groups, $F(2, 72) = 1.875$, $p = .161$.

3.4 | Horizontal radiographic changes

The median horizontal radiographic changes at 1, 3, and 5 mm below the crest are presented in Table 2. One mm below the crest the mean change in the CM-group measured -0.9 SD 0.6 mm, in the PG-group -1.0 SD 0.8 mm, and -3.2 SD 2.1 mm in the control group. This difference

was statistically different between the groups, $H(2) = 25.899$, $p < .001$. Post hoc analysis revealed that both the difference between the CM and the control group (MD 2.3 mm, 95% CI 1.3 – 3.2 , $p < .001$) as well as the difference between the PG- and control group (MD 2.2 mm, 95% CI 1.2 – 3.1 , $p < .001$) were statistically significant.

3.5 | Vertical radiographic changes

The median vertical changes at the buccal and palatal crest are presented in Table 3. At the buccal aspect, the mean change in the CM-group measured -0.8 SD 0.8 mm, in the PG-group -0.5 SD 0.8 mm and -2.3 SD 1.8 mm in the control group. The difference in change was statistically different between the different groups, $H(2) = 25.322$, $p < .001$. Post hoc analysis revealed that the difference between the CM and control (MD 1.5 mm, 95% CI 0.7 – 2.4 , $p < .001$) as well as the difference between the PG and control (MD 1.8 mm, 95% CI 0.9 – 2.7 , $p < .001$) were statistically significant.

At the palatal aspect, the mean change in the CM-group was -0.5 SD 0.6 mm, in the PG-group -0.3 SD 0.6 mm and -1.6 SD 1.0 mm in the control group. The difference was statistically different between the different groups, $H(2) = 28.646$, $p < .001$. Post hoc analysis revealed that the difference between the CM- and control group (MD 1.0 mm, 95% CI 0.5 – 1.6 , $p = .001$) as well as the difference between the PG- and control group (MD 1.3 mm, 95% CI 0.8 – 1.8 , $p < .001$) were statistically significant.

3.6 | Soft tissue dimensions at implant placement

The median buccal/palatal/vertical soft tissue dimensions at implant placement are shown in Table 4. No significant differences were

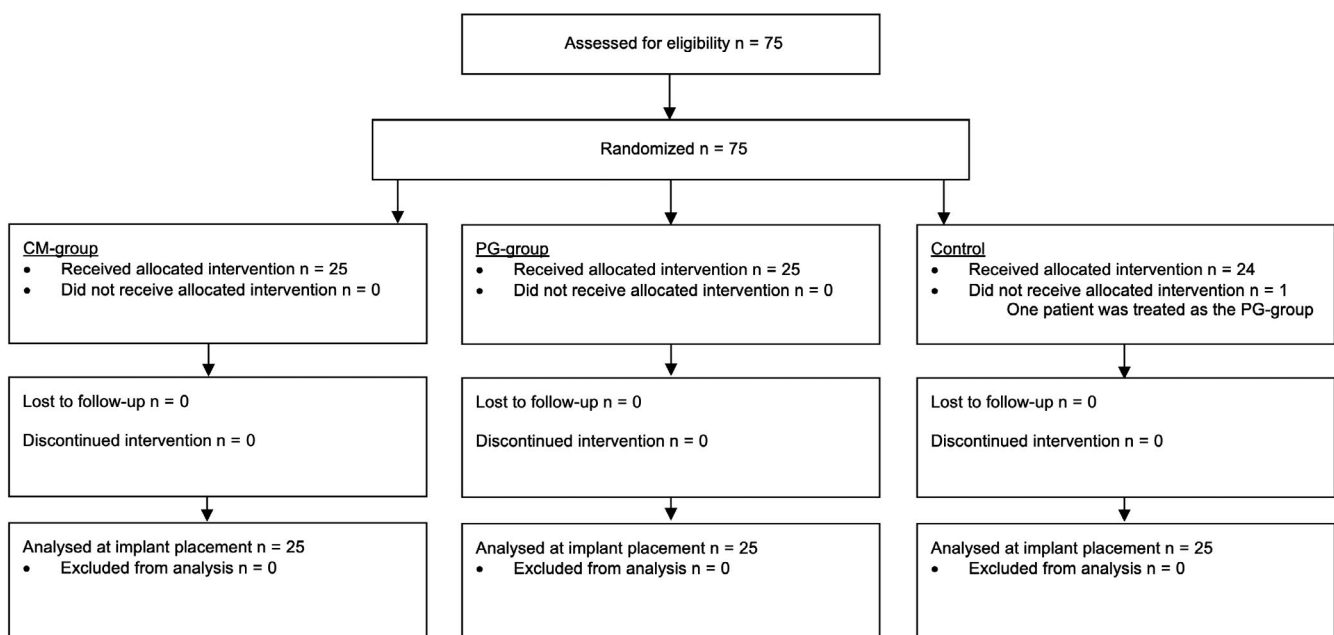


FIGURE 5 Flow diagram

found between the three groups for the buccal, palatal, and vertical mucosal dimensions at implant placement.

3.7 | Necessity of additional augmentation

Additional GBR was needed in 32% of the sites in CM-group, in 24% in PG-group and in 72% in the control group ($\chi^2(2) = 13.277, p = .001$). The difference was significant comparing CM to control ($\chi^2(1) = 8.013, p = .010$) and for PG to control ($\chi^2(1) = 11.538, p = .002$). The risk difference was 40% between CM-group and control and 48% between PG-group and control.

3.8 | Patient-reported outcomes

Median scores for pain were significantly different between groups after extraction $H(2) = 6.283, p = .043$. The median score for the

TABLE 1 Baseline characteristics

Group	CM	PG	Control
Number of patients	25	25	25
Age (mean and SD)	49 (16)	50 (13)	44 (12)
Gender (female/male)	13/12	11/14	18/7
Center (EMC/CZE)	17/8	16/9	17/8
Cause of tooth loss (fracture/infection/resorption)	17/6/2	17/8/0	17/6/2
Location of implant (I1, I2, C, P1, P2)	8/2/4/4/7	7/6/0/6/8	7/4/0/6/8
Plaque index (0/1/2/3)	23/0/1/0 ^a	23/0/2/0	22/2/1/0
Bleeding index (0/1/2/3)	16/7/1/0 ^a	15/7/2/1	17/4/4/0
Gingiva index (0/1/2/3)	22/1/1/0 ^a	18/3/4/0	21/1/3/0
Pocket probing depth (mean and SD)	2.5 (0.7)	2.6 (1.1)	2.4 (0.7)

Abbreviations: CM, Collagen Matrix; PG, palatal graft; SD, standard deviation; EMC, Erasmus Medical Center; CZE, Catherina Hospital Eindhoven.

^aOne radix was completely covered by gingiva.

CM-group was 0 (0–1.8), for PG-group 2.0 (0.3–3.8), and for the control group 1.0 (0–5.5) at one week after extraction. The post hoc analysis only revealed a significant difference in median pain scores after ridge preservation for the CM-group compared with the PG-group ($p = .042$). No significant differences were found for neither the impact of the implant surgery nor the experienced swelling (Table 5).

3.9 | Subgroup analysis

Only for soft tissue contour changes, the subgroup analysis revealed a different outcome compared to the analysis of the whole group. Subgroup analysis showed that for the incisor/cuspid area the mean change measured -1.5 SD 0.6 mm in the CM-group, -1.7 SD 0.6 mm in the PG-group, and -2.3 SD 0.9 mm in the control group. This difference was statistically different between the groups, $F(2, 33) = 3.661, p = .037$. Post hoc analysis revealed that the mean difference between the CM and control group (MD 0.8 mm, 95% CI 0.1–1.5 $p = .031$) was statistically significant. Subgroup analysis for the premolar area was not significantly different between the three groups.

4 | DISCUSSION

This randomized controlled clinical study compared two different ridge preservation techniques with spontaneous healing when early implant placement was performed. Ridge preservation using a particulated xenogenic bone substitute covered with either a collagen matrix (CM) or an autologous palatal connective tissue graft (PG) resulted in less horizontal and vertical bone resorption compared to spontaneous healing (control group) 8 weeks after tooth extraction. This was in accordance with earlier studies, where ridge preservation resulted in less vertical and horizontal resorption 4–6 months after tooth removal (Araujo et al., 2015; Jung et al., 2013; Lim et al., 2019).

Although ridge preservation reduced bone resorption in current study, there was no significant difference in horizontal soft tissue contour changes between both techniques and the control group. In the subgroup analysis, there was a statistically significant difference

	CM <i>n</i> = 24	PG <i>n</i> = 25	Control <i>n</i> = 24	<i>p</i> -value
1 mm below crest	-1.0 (-0.3; -1.4)	-0.8 (-0.6; -1.3)	-2.5 (-1.6; -4.7)	<.001*
3 mm below crest	-0.6 (-0.3; -1.2)	-0.6 (-0.1; -0.9)	-1.8 (-0.8; -3.1)	.001**
5 mm below crest	-0.6 (-0.1; -1.0)	-0.2 (-0.1; -0.4)	-0.9 (-0.3; -1.3)	.002***

Note: Median, first, and third quartile of the bone and soft tissue dimensions in mm at implant placement; CM, Collagen matrix; PG, Palatal graft.

A Kruskal-Wallis test was used to calculate significance levels (*p*-values). Pairwise comparisons were performed using Dunn's procedure with a Bonferroni correction for multiple comparisons.

*CM-Control $p < .001$, PG-Control $p < .001$ **CM-Control $p = .001$, PG-Control $p < .001$

***PG-Control = 0.001.

TABLE 2 Horizontal radiographic changes

TABLE 3 Vertical radiographic changes

	CM	PG	Control	
	n = 24	n = 25	n = 24	p-value
Buccal	-0.8 (-0.1; -1.1)	-0.5 (-0.1; -0.9)	-1.9 (-1.4; -3.0)	<.001*
Palatal	-0.4 (-0.2; -0.8)	-0.2 (-0.1; -0.7)	-1.3 (-0.8; -2.2)	<.001**

Note: Median, first and third quartile of the bone and soft tissue dimensions in mm at implant placement; CM, Collagen matrix; PG, Palatal graft.

A Kruskal–Wallis test was used to calculate significance levels (*p*-values). Pairwise comparisons were performed using Dunn's procedure with a Bonferroni correction for multiple comparisons.

*CM-Control *p* < .001, PG-Control *p* < .001 **CM-Control *p* = .001, PG-Control *p* < .001.

TABLE 4 Soft tissue dimensions at implant placement

	CM	PG	Control	
	n = 24	n = 25	n = 25	p-value
Buccal mucosa	1.6 (1.3;1.9)	1.3 (0.9;1.8)	1.7 (1.2;3.1)	.067
Palatal mucosa	2.5 (1.9;3.2)	3.0 (1.9;3.5)	3.3 (2.8;4.0)	.067
Mucosal height	2.5 (2.1;3.0)	2.4 (1.9;2.9)	2.4 (1.8;3.1)	.846

Note: Median, first and third quartile of the bone and soft tissue dimensions in mm at implant placement; CM, Collagen matrix; PG, Palatal graft. A Kruskal–Wallis test was used to calculate significance levels (*p*-values).

in the mean change in horizontal soft tissue contour changes between the CM-group and the control group for the incisor/cuspid area. However, this difference was minimal and might not be clinically relevant. This was also reported in earlier studies, where only a limited protective effect was seen at the labial ridge contour when compared to spontaneous healing. The lack in significant difference could also be related to the area of interest selected for the analysis (Schneider et al., 2014; Thalmair et al., 2013). Alginate was the impression material used, while an intra-oral scan would be more precise. Unfortunately, during the start of the inclusion no intra-oral scan was available for this study.

The present study showed no significant difference between the three groups for the buccal, palatal, and vertical mucosal dimensions at 8 weeks post-extraction. The change in mucosal thickness could

not be calculated between the two time-points since the baseline STL was obtained prior to extraction and the CBCT-scan was performed right after the extraction.

Covering the augmented extraction socket with a collagen matrix or an autologous graft might be important to facilitate maximal healing of the bone graft when performing ridge preservation (Lim et al., 2019; Thalmair et al., 2013). When compared to other studies, the present results showed less integration of the palatal graft (Araujo et al., 2015; Jung et al., 2004). This difference might be explained by the current study scoring the graft as a total in contrary to applying a digital planimetry and expressing the scores as a percentage of the entire grafted area (Jung et al., 2004). Although a higher amount of necrosis was found in the PG-group when compared to the CM-group, the differences

TABLE 5 Patient-reported outcome measurements

	Visual Analogue Scale	CM	PG	Control	
		n = 24	n = 24	n = 25	p-value
Before surgery	Expected impact of surgery	7.0 (3.0; 8.0)	6.0 (3.0; 8.0)	6.0 (2.5; 7.5)	.569
	Pain	0.5 (0; 4.0)	1.0 (0; 4.0)	0 (0; 5.0)	.879
	Swelling	0 (0; 2.8)	1.5 (0; 5.0)	0 (0; 5.0)	.424
One week after removal	Impact of removal	4.0 (1.3; 7.0)	3.5 (2.3; 6.0)	3.0 (1.0; 5.0)	.555
	Pain	0 (0; 1.8)	2.0 (0.3; 3.8)	1.0 (0; 5.5)	.043*
	Swelling	0 (0; 1.0)	1.5 (0; 2.8)	0 (0; 1.0)	.054

Note: Median, first and third quartile of the patient-reported outcomes measured on a visual analogue scale from 0 to 10; CM, Collagen matrix; PG, Palatal graft. A Kruskal–Wallis test was used to calculate significance levels (*p*-values).

Pairwise comparisons were performed using Dunn's procedure with a Bonferroni correction for multiple comparisons: *CM-PG *p* = .042.

were not statistically significant. Harvesting a free connective palatal graft can be a painful procedure, where most of the pain is experienced in the first days postoperatively (Burkhardt et al., 2015; Thoma et al., 2012). In the present study, patients in the CM-group experienced significantly less pain when compared to the patients in group PG. To our knowledge, so far, no other clinical studies comparing a palatal graft with a substitute for ARP and evaluating patient-reported outcomes exist. According to the results from this study, a collagen matrix is associated with less morbidity, less necrosis, and less change in soft tissue volume in the incisal/cuspid area and might therefore be preferred over a palatal graft when performing ridge preservation procedures.

Although ridge preservation resulted in less bone loss compared with spontaneous healing and the amount of additional GBR needed at the time of implant placement was less in the ARP groups, additional GBR was still needed in a large percentage the ARP patients. This is in line with earlier studies describing results ranging from 0%–45% additional augmentations in ridge preservation groups and 0%–100% in groups that were left for spontaneous healing (Avila-Ortiz et al., 2019; Lim et al., 2020; Mardas et al., 2015; Thoma et al., 2020). The augmented DBBM-C is still quite soft at early implant placement and some particles are easily displaced during drilling of the osteotomy resulting in the need of additional augmentation (Thoma et al., 2017).

As mentioned in earlier studies (Jung et al., 2013; Schneider et al., 2014), a power analysis would lead to approximately 240 patients to achieve a power of 81% to detect a difference measuring 0.5 mm with a SD of 1 mm. This is practically not feasible and the power of the current study was based on the marginal change in soft tissue after 1 year of loading. Compared to earlier publications the present study was able to include more than double the number of patients for each group. Thus, a subgroup analysis was performed to evaluate the incisor/cuspid and bicuspid area separately. To prevent the associated bias, subgroups analysis was performed for all outcomes. Additionally, it must be noted that the buccal bone thickness and integrity was not calculated and could be of influence. The relevance regarding the clinical and esthetic outcomes of the implants 12 months after loading will be reported in the 1-year follow-up.

The study was performed using CONSORT and the Cochrane Risk of Bias assessment tool to keep bias as low as possible (Higgins et al., 2011). Selection bias was prevented by using a computer-generated random sequence generation. Allocation was concealed in opaque, sealed envelopes. The allocation sequence was concealed from the surgeon (JP) until the very last possible step in the surgical procedure. Blinding of the outcome assessment (detection bias) was ensured as investigators (BJ, AG, NN & JP) were not aware of the allocation during the assessments. It must be noted that surgeon (JP) might remember the allocated procedure during clinical follow-up. There were no losses to follow-up, resulting in a low risk of attrition bias. Risk of reporting bias was low because all outcomes originally described in the registered protocol are reported.

5 | CONCLUSION

Ridge preservation in the esthetic zone applying a particulated xenogenic bone substitute covered with a collagen matrix or an autogenous palatal punch results in less bone resorption and less need of additional bone augmentation at early implant placement compared to spontaneous healing.

CONFLICT OF INTEREST

All authors declare to have no conflict of interest.

AUTHOR CONTRIBUTION

Brend Pjotr Jonker: Data curation (equal); Formal analysis (equal); Investigation (equal); Visualization (equal); Writing-original draft (equal). **Alfonso Gil:** Investigation (equal); Software (equal); Visualization (equal); Writing-review & editing (equal). **Nadja Naenni:** Conceptualization (equal); Investigation (equal); Supervision (equal); Writing-review & editing (equal). **Ronald Ernst Jung:** Conceptualization (equal); Supervision (equal); Writing-review & editing (equal). **Eppo Bonne Wolvius:** Funding acquisition (equal); Supervision (equal); Writing-review & editing (equal). **Justin Pijpe:** Conceptualization (equal); Funding acquisition (equal); Investigation (equal); Supervision (equal); Writing-original draft (equal).

ORCID

Brend Pjotr Jonker  <https://orcid.org/0000-0003-0100-3871>

Ronald Ernst Jung  <https://orcid.org/0000-0003-2055-1320>

REFERENCES

- Araujo, M. G., da Silva, J. C., de Mendonca, A. F., & Lindhe, J. (2015). Ridge alterations following grafting of fresh extraction sockets in man. A randomized clinical trial. *Clinical Oral Implants Research*, 26(4), 407–412. <https://doi.org/10.1111/clr.12366>
- Avila-Ortiz, G., Chambrone, L., & Vignoletti, F. (2019). Effect of alveolar ridge preservation interventions following tooth extraction: A systematic review and meta-analysis. *Journal of Clinical Periodontology*, 46(Suppl 21), 195–223. <https://doi.org/10.1111/jcpe.13057>
- Burkhardt, R., Hammerle, C. H., Lang, N. P., & Research Group on Oral Soft Tissue Biology & Wound Healing. (2015). Self-reported pain perception of patients after mucosal graft harvesting in the palatal area. *Journal of Clinical Periodontology*, 42(3), 281–287. <https://doi.org/10.1111/jcpe.12357>
- Buser, D., Halbritter, S., Hart, C., Bornstein, M. M., Grutter, L., Chappuis, V., & Belsler, U. C. (2009). Early implant placement with simultaneous guided bone regeneration following single-tooth extraction in the esthetic zone: 12-month results of a prospective study with 20 consecutive patients. *Journal of Periodontology*, 80(1), 152–162. <https://doi.org/10.1902/jop.2009.080360>
- Chappuis, V., Araujo, M. G., & Buser, D. (2017). Clinical relevance of dimensional bone and soft tissue alterations post-extraction in esthetic sites. *Periodontology 2000*, 73, 73–83. <https://doi.org/10.1111/prd.12167>
- Chappuis, V., Engel, O., Reyes, M., Shahim, K., Nolte, L. P., & Buser, D. (2013). Ridge alterations post-extraction in the esthetic zone: A 3D analysis with CBCT. *Journal of Dental Research*, 92(12 Suppl), 195S–201S. <https://doi.org/10.1177/0022034513506713>

- Chappuis, V., Engel, O., Shahim, K., Reyes, M., Katsaros, C., & Buser, D. (2015). Soft tissue alterations in esthetic postextraction sites: A 3-Dimensional analysis. *Journal of Dental Research*, 94(9 Suppl), 187S–193S. <https://doi.org/10.1177/0022034515592869>
- Fickl, S., Schneider, D., Zuh, O., Hinze, M., Ender, A., Jung, R. E., & Hürzeler, M. B. (2009). Dimensional changes of the ridge contour after socket preservation and buccal overbuilding: An animal study. *Journal of Clinical Periodontology*, 36(5), 442–448. <https://doi.org/10.1111/j.1600-051X.2009.01381.x>
- Griffin, T. J., Cheung, W. S., Zavras, A. I., & Damoulis, P. D. (2006). Postoperative complications following gingival augmentation procedures. *Journal of Periodontology*, 77(12), 2070–2079. <https://doi.org/10.1902/jop.2006.050296>
- Higgins, J. P. T., Savović, J., Page, M. J., Elbers, R. G., & Sterne, J. A. C. (2011). Chapter 8: Assessing risk of bias in a randomized trial. In J. P. T. Higgins, J. Thomas, J. Chandler, M. Cumpston, T. Li, M. J. Page, & V. A. Welch (Eds.), *Cochrane handbook for systematic reviews of interventions version 6.1* (updated September 2020). Cochrane, 2020. Available from www.training.cochrane.org/handbook
- Jung, R. E., Ioannidis, A., Hämmerle, H. F., & Thoma, D. S. (2018). Alveolar ridge preservation in the esthetic zone. *Periodontology 2000*, 77, 165–175.
- Jung, R. E., Philipp, A., Annen, B. M., Signorelli, L., Thoma, D. S., Hämmerle, C. H. F., Attin, T., & Schmidlin, P. (2013). Radiographic evaluation of different techniques for ridge preservation after tooth extraction: A randomized controlled clinical trial. *Journal of Clinical Periodontology*, 40(1), 90–98. <https://doi.org/10.1111/jcpe.12027>
- Jung, R. E., Siegenthaler, D. W., & Hämmerle, C. H. (2004). Postextraction tissue management: A soft tissue punch technique. *International Journal of Periodontics and Restorative Dentistry*, 24(6), 545–553.
- Landsberg, C. J., & Bichacho, N. (1994). A modified surgical/prosthetic approach for optimal single implant supported crown. *Practical Periodontics and Aesthetic Dentistry*, 6(2), 11–17.
- Lang, N. P., Pun, L., Lau, K. Y., Li, K. Y., & Wong, M. C. M. (2012). A systematic review on survival and success rates of implants placed immediately into fresh extraction sockets after at least 1 year. *Clinical Oral Implants Research*, 23, 39–66. <https://doi.org/10.1111/j.1600-0501.2011.02372.x>
- Lim, H. C., Seo, S., Thoma, D. S., Park, J. C., Hong, J. Y., & Shin, S. Y. (2020). Late implant placement following ridge preservation versus early implant placement: A pilot randomized clinical trial for periodontally compromised non-molar extraction sites. *Journal of Clinical Periodontology*, 47(2), 247–256. <https://doi.org/10.1111/jcpe.13223>
- Lim, H. C., Shin, H. S., Cho, I. W., Koo, K. T., & Park, J. C. (2019). Ridge preservation in molar extraction sites with an open-healing approach: A randomized controlled clinical trial. *Journal of Clinical Periodontology*, 46(11), 1144–1154. <https://doi.org/10.1111/jcpe.13184>
- Mardas, N., Trullenque-Eriksson, A., MacBeth, N., Petrie, A., & Donos, N. (2015). Does ridge preservation following tooth extraction improve implant treatment outcomes: A systematic review. *Clinical Oral Implants Research*, 26, 1–22. <https://doi.org/10.1111/clr.12639>
- Moher, D., Hopewell, S., Schulz, K. F., Montori, V., Gotzsche, P. C., Devereaux, P. J., Elbourne, D., Egger, M., & Altman, D. G. (2010). CONSORT 2010 explanation and elaboration: Updated guidelines for reporting parallel group randomised trials. *BMJ*, 340, c869. <https://doi.org/10.1136/bmj.c869>
- Schneider, D., Grunder, U., Ender, A., Hammerle, C. H., & Jung, R. E. (2011). Volume gain and stability of peri-implant tissue following bone and soft tissue augmentation: 1-year results from a prospective cohort study. *Clinical Oral Implants Research*, 22(1), 28–37. <https://doi.org/10.1111/j.1600-0501.2010.01987.x>
- Schneider, D., Schmidlin, P. R., Philipp, A., Annen, B. M., Ronay, V., Hämmerle, C. H. F., Attin, T., & Jung, R. E. (2014). Labial soft tissue volume evaluation of different techniques for ridge preservation after tooth extraction: A randomized controlled clinical trial. *Journal of Clinical Periodontology*, 41(6), 612–617. <https://doi.org/10.1111/jcpe.12246>
- Thalmair, T., Fickl, S., Schneider, D., Hinze, M., & Wachtel, H. (2013). Dimensional alterations of extraction sites after different alveolar ridge preservation techniques – A volumetric study. *Journal of Clinical Periodontology*, 40(7), 721–727. <https://doi.org/10.1111/jcpe.12111>
- Thoma, D. S., Bienz, S. P., Lim, H. C., Lee, W. Z., Hammerle, C. H. F., & Jung, R. E. (2020). Explorative randomized controlled study comparing soft tissue thickness, contour changes, and soft tissue handling of two ridge preservation techniques and spontaneous healing two months after tooth extraction. *Clinical Oral Implants Research*, 31(6), 565–574. <https://doi.org/10.1111/clr.13594>
- Thoma, D. S., Jung, R. E., Schneider, D., Cochran, D. L., Ender, A., Jones, A. A., Görlach, C., Uebersax, L., Graf-Hausner, U., & Hämmerle, C. H. F. (2010). Soft tissue volume augmentation by the use of collagen-based matrices: A volumetric analysis. *Journal of Clinical Periodontology*, 37(7), 659–666. <https://doi.org/10.1111/j.1600-051X.2010.01581.x>
- Thoma, D. S., Naenni, N., Benic, G. I., Munoz, F., Hammerle, C. H. F., & Jung, R. E. (2017). Effect of ridge preservation for early implant placement – Is there a need to remove the biomaterial? *Journal of Clinical Periodontology*, 44(5), 556–565. <https://doi.org/10.1111/jcpe.12709>
- Thoma, D. S., Sancho-Puchades, M., Ettlin, D. A., Hammerle, C. H., & Jung, R. E. (2012). Impact of a collagen matrix on early healing, aesthetics and patient morbidity in oral mucosal wounds – A randomized study in humans. *Journal of Clinical Periodontology*, 39(2), 157–165. <https://doi.org/10.1111/j.1600-051X.2011.01823.x>
- Urbaniak, G. C., & Plous, S. (2013). Research Randomizer (Version 4.0). Retrieved from <http://www.randomizer.org>

SUPPORTING INFORMATION

Additional supporting information may be found online in the Supporting Information section.

How to cite this article: Jonker BP, Gil A, Naenni N, Jung RE, Wolvius EB, Pijpe J. Soft tissue contour and radiographic evaluation of ridge preservation in early implant placement: A randomized controlled clinical trial. *Clin Oral Impl Res*. 2021;32:123–133. <https://doi.org/10.1111/clr.13686>