

Diagnosis and management of the intra-abdominal desmoid tumour

Authors: J Stürmlin, V Banz & J Metzger

Location: Cantonal Hospital Lucerne, Lucerne, Switzerland

Citation: Stürmlin J, Banz V, Metzger J. Diagnosis and management of the intra-abdominal desmoid tumour. JSCR 2012. 2:2

ABSTRACT

Desmoid tumours are a rare entity and are usually detected with a certain delay, as they initially often grow without causing any specific clinical symptoms. Although these tumours grow slowly and do not metastasise, their growth pattern remains aggressive and local tissue displacement or even destruction is common. Surgery remains the only potentially curative treatment option. Here we report on the findings of a 43-year old female patient with a large intra-abdominal desmoid tumour, resulting in the displacement of most intra-abdominal organs to the right of the patient's abdominal cavity. She successfully underwent surgical removal of the mass and recovered without complications.

INTRODUCTION

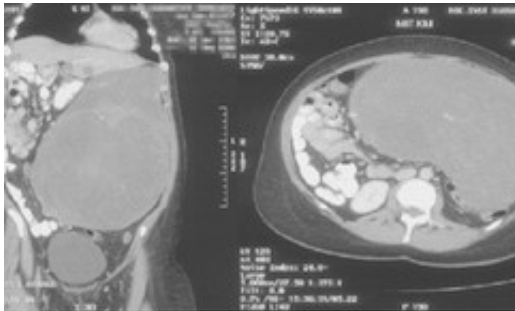
Desmoid tumours comprise 0.03% of all neoplasms, less than 3% of all soft tissue tumours ([1](#)), with an incidence of 2-4 cases / 1'000'000 per year ([2](#)). They are usually detected relatively early on in life (10-40 years of age), with a slight female predominance. While normally occurring sporadically, they are more common in patients with familial adenomatous polyposis (FAP), where the incidence is 850 times higher than in the general population ([3](#)).

Most desmoid tumours typically tend to grow slowly and do not metastasise, although their growth pattern remains quite aggressive, with organ infiltration, local tissue destruction and organ compression/displacement. The tumours often grow without causing any clinical symptoms and are therefore usually only detected relatively late or during a check-up for another ailment, when they may have already reached substantial sizes of 15cm in diameter or more. Problems associated with intestinal, vascular or neural compression are quite common.

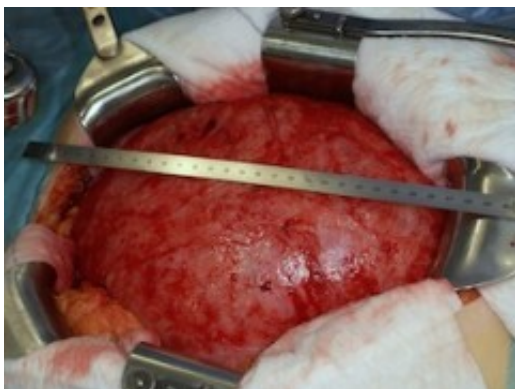CASE REPORT

During a routine check-up for hypertension, the 43-year old female patient's general practitioner noted a painless mass in the abdomen. The patient reported increased fatigue and a reduced overall performance for the previous two years. Further questioning revealed occasional dyspepsia and an increased urge to urinate, although micturition was otherwise without any associated discomfort. She was otherwise in good general health and without

previous abdominal surgery. Routine haematology and biochemistry were normal. An abdominal computed tomography revealed a very large, well-defined intra-abdominal mass, resulting in the displacement of most intra-abdominal organs to the right of the patient's abdominal cavity (Fig. 1).



Radiological evaluation did not make it possible to tell from which organ the tumour originated. Intra-operative findings revealed a tumour spanning from the symphysis to the xyphoid (Fig. 2) and showed multiple adhesences between the omentum and the caudal pole of the spleen. In order to achieve an R0-resection, a partial splenectomy and partial removal of the omentum was necessary. The tumour weighed 5.6kg and measured 28cm.



DISCUSSION

Diagnostic imaging includes abdominal sonography, computed tomography or magnetic resonance imaging (MRI). MRI usually is the examination of choice as it provides the surgeon with a better evaluation of exact tumour size, location and infiltration in to the surrounding tissues with tumour recurrences being more easily detected. Upon diagnosis of a desmoid tumour all patients should have a colonoscopy and a gastroscopy to exclude FAP.

Histologically, desmoid tumours are benign and characterised by a monoclonal fibroblastic proliferation typically arising from muscular or aponeurotic structures. Although upon initial inspection an intact capsule seems to surround the periphery, the tumour characteristically extends beyond this pseudo-capsule. Tumours are classified as intra- or extra-abdominal, with extra-abdominal tumours most often located around the neck and shoulders, the pelvis, or within the thoracic wall. Sporadic desmoid tumours are mainly located extra-abdominal and are relatively easy to resect. High recurrence rates and difficult locations make treatment of the intra-abdominal sub-group particularly difficult.

Treatment of desmoid tumours is challenging and the optimal therapeutic strategy remains a matter of debate. While spontaneous tumour regression has been observed, usually in menopausal women or post- oophorectomy, suggesting a certain estrogen-dependency (4,5), rapid growing tumours require an aggressive therapy if cure is to be sought. Their high recurrence rate and their ability and tendency to infiltrate vital organs and structures can result in difficult and highly complex operations. Treatment for small, non-infiltrating tumours can be delayed in completely asymptomatic patients and / or in patients unfit for surgery, as the tumours can remain stable over years without any significant morbidity. However, these patients require routine radiological imaging to exclude rapid growth or new organ infiltration.

Surgery remains the main therapeutic option, with complete tumour resection providing the only potentially curative treatment. Although, as with classical cancer surgery, the aim is to achieve an R0 resection margin, surgery should nevertheless be kept to the required minimum, avoiding any mutilating intervention. If resected early on, the removal of abdominal-wall desmoid tumours is associated with a low morbidity and mortality. Overall recurrence rates lie by 20% to 75% (6,7) and are more frequent for the rarer extra-abdominal tumours. Surgical interventions for intra-abdominal tumours are often associated with a high mortality and morbidity. Many are found at the root of the small bowel mesenterium and up to 65% of the tumours are unresectable upon intraoperative inspection (8).

There is little evidence for the benefit of pharmacological therapies, which include the use of non-steroidal anti-inflammatory drugs, such as sulindac or anti-estrogens such as tamoxifen (9). The aim is tumour regression / growth stop and it can be used as a first-line treatment for multiple, intra-abdominal tumours. The high recurrence rate can be reduced by adjuvant and / or neoadjuvant radiotherapy (10) both for abdominal wall and extra-abdominal tumours. The usefulness of alternative therapies, such as radio frequency ablation is currently under scrutiny. Other options include placement of a percutaneous catheter for use in chemical ablation using acids. The possibility of gene transfer is also subject to intense research.

Desmoid tumours are rare and are either found sporadically or more commonly associated with FAP. A classification into abdominal wall tumours as well as extra- and intra-abdominal tumours is important with regard to further treatment and outcome. Clear guidelines outlining possible therapy options - including helpful algorithms - are missing. However, symptomatic tumours, especially if located intra-abdominal, should be treated aggressively. Surgery still remains the treatment of choice, although recurrence rates are high, even after R0 resection.

REFERENCES

1. [Nuyttens JJ, Rust PF, Thomas CR, Jr., Turrisi AT, 3rd. Surgery versus radiation therapy](#)

- [for patients with aggressive fibromatosis or desmoid tumors: A comparative review of 22 articles. Cancer. 2000 Apr 1;88\(7\):1517-23](#)
2. [Papagelopoulos PJ, Mavrogenis AF, Mitsiokapa EA, Papaparaskeva KT, Galanis EC, Soucacos PN. Current trends in the management of extra-abdominal desmoid tumours. World J Surg Oncol. 2006;4:21](#)
 3. [Gurbuz AK, Giardiello FM, Petersen GM, Krush AJ, Offerhaus GJ, Booker SV, et al. Desmoid tumours in familial adenomatous polyposis. Gut. 1994 Mar; 35\(3\):377-81](#)
 4. [Easter DW, Halasz NA. Recent trends in the management of desmoid tumors. Summary of 19 cases and review of the literature. Ann Surg. 1989 Dec;210\(6\):765-9](#)
 5. [Reitamo JJ, Scheinin TM, Hayry P. The desmoid syndrome. New aspects in the cause, pathogenesis and treatment of the desmoid tumor. Am J Surg. 1986 Feb;151\(2\):230-7](#)
 6. [Heiskanen I, Jarvinen HJ. Occurrence of desmoid tumours in familial adenomatous polyposis and results of treatment. Int J Colorectal Dis. 1996;11\(4\):157-62](#)
 7. [Clark SK, Neale KF, Landgrebe JC, Phillips RK. Desmoid tumours complicating familial adenomatous polyposis. Br J Surg. 1999 Sep;86\(9\):1185-9](#)
 8. [Dozois EJ. Desmoid disease. In: Kelly KA, editor. Mayo Clinic gastrointestinal Surgery Philadelphia: Saunders; 2004. p.563-5](#)
 9. [Hansmann A, Adolph C, Vogel T, Unger A, Moeslein G. High-dose tamoxifen and sulindac as first-line treatment for desmoid tumors. Cancer. 2004 Feb 1;100\(3\):612-20](#)
 10. [Tsukada K, Church JM, Jagelman DG, Fazio VW, Lavery IC. Systemic cytotoxic chemotherapy and radiation therapy for desmoid in familial adenomatous polyposis. Dis Colon Rectum. 1991 Dec;34\(12\):1090-2](#)