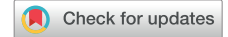

# High-resolution mapping and successful ablation of Purkinje ectopy-triggered ventricular fibrillation storm



Alexandre Raymond-Paquin, MD, FRCPC,<sup>\*†</sup> Scott Lovejoy, BS, BME,<sup>‡</sup>  
Kenneth A. Ellenbogen, MD, FACC, FHRS,<sup>\*</sup> Santosh K. Padala, MD, FACC<sup>\*</sup>

From the <sup>\*</sup>Division of Cardiology, Pauley Heart Center, Virginia Commonwealth University, Richmond, Virginia, <sup>†</sup>Montreal Heart Institute, Department of Medicine, Université de Montréal, Québec, Canada, and <sup>‡</sup>Abbott Laboratories, Abbott Park, Chicago, Illinois.

## Introduction

Catheter ablation is recognized as a central therapeutic option in treating patients with drug-refractory, scar-related monomorphic ventricular tachycardia (VT).<sup>1</sup> Catheter ablation also has a role in selected cases of polymorphic VT (PMVT) and/or ventricular fibrillation (VF). Rarely, premature ventricular contractions (PVCs) originating from the Purkinje network can induce PMVT/VF. Although not completely elucidated, the electrophysiologic mechanisms behind this lethal arrhythmia have generally been thought to be related to abnormal automaticity and triggered activity.<sup>2</sup> Ablation of the triggering PVCs can prevent VF recurrence and is potentially lifesaving.<sup>3–6</sup>

## Case report

A 42-year-old man with a history of nonischemic cardiomyopathy was referred to our center during a VF storm requiring 5 defibrillations from his implantable cardioverter-defibrillator (ICD) in 24 hours for a combined epicardial-endocardial catheter ablation procedure. The patient had recurrent episodes of VF with ICD shocks for 2 years despite treatment with beta blocker and amiodarone. During the present admission he was on sotalolol 160 mg twice daily and mexiletine 150 mg 3 times daily.

The patient had a history of hypertension, type 2 diabetes, morbid obesity (body mass index 41 kg/m<sup>2</sup>), and nonischemic

## KEY TEACHING POINTS

- Purkinje ectopy triggering polymorphic ventricular tachycardia (PMVT) and ventricular fibrillation (VF) in patients with structural heart disease is a rare entity distinct from short-coupled VF and idiopathic VF.
- Purkinje premature ventricular contractions typically have a narrow QRS duration (<120 ms) with rapid downstroke, are short-coupled, and tend to be pleomorphic.
- Purkinje ectopy triggering PMVT and VF is generally thought to be caused by abnormal automaticity or triggered activity. Intramyocardial and Purkinje reentry are possible mechanisms that need to be studied in the future.
- High-resolution mapping and catheter ablation can be a lifesaving treatment strategy for selected patients with PMVT and VF.

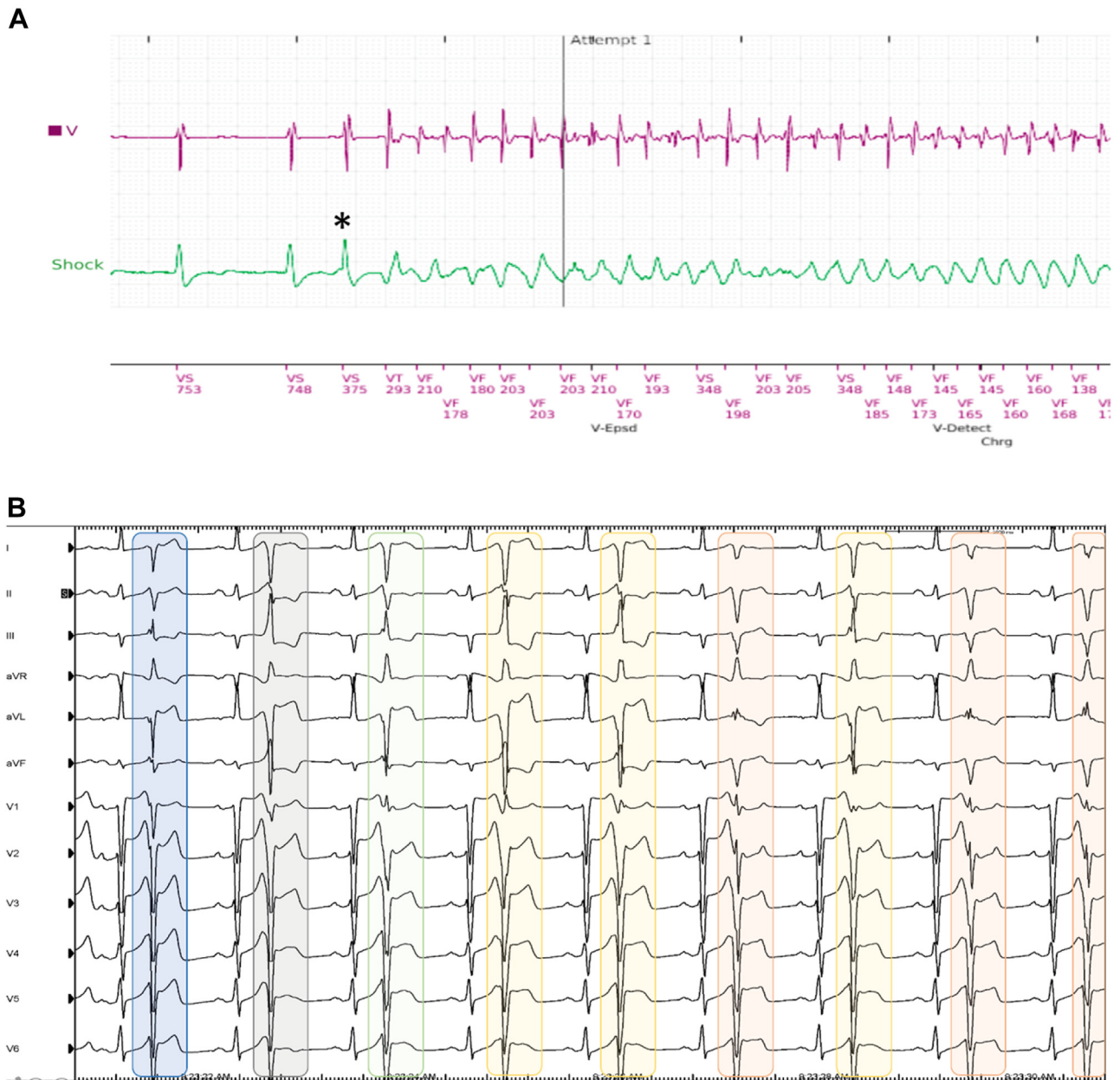
dilated cardiomyopathy with left ventricular (LV) ejection fraction of 30%–35%. A coronary angiogram was normal. A single-chamber ICD was placed in 2016 for primary prevention. Cardiac magnetic resonance imaging was negative for infiltrative or inflammatory cardiomyopathy.

Careful analysis of the ICD electrograms revealed multiple VF episodes induced by PVCs (Figure 1A). Telemetry revealed PVCs that occasionally triggered short bursts of PMVT. An electrocardiogram rhythm strip showed a high burden of pleomorphic PVCs with characteristics compatible with Purkinje network origin. The PVCs had a relatively narrow QRS duration (120–125 ms), a rapid initial deflection, and a short coupling interval (360 ms) with R-on-T phenomenon (Figure 1B).

**KEYWORDS** Ventricular fibrillation; Polymorphic ventricular tachycardia; Short-coupled ventricular fibrillation; Purkinje network; Sudden cardiac death; Catheter ablation

(Heart Rhythm Case Reports 2022;8:217–221)

**Funding Sources:** This research did not receive any specific grant from funding agencies in the public, commercial, or not-for-profit sectors. **Conflict of Interest:** Dr Alexandre Raymond-Paquin has no conflict of interest. Dr Kenneth Ellenbogen is a DSMB chair and received honoraria and research support from Medtronic. Dr Santosh Padala is a consultant for Medtronic. **Address reprint requests and correspondence:** Dr Alexandre Raymond-Paquin, Division of Cardiology, Pauley Heart Center, Virginia Commonwealth University, Gateway Building, 3rd floor, 3-216, 1200 East Marshall St, Richmond, VA. E-mail address: alexandre.raymond.p@gmail.com.

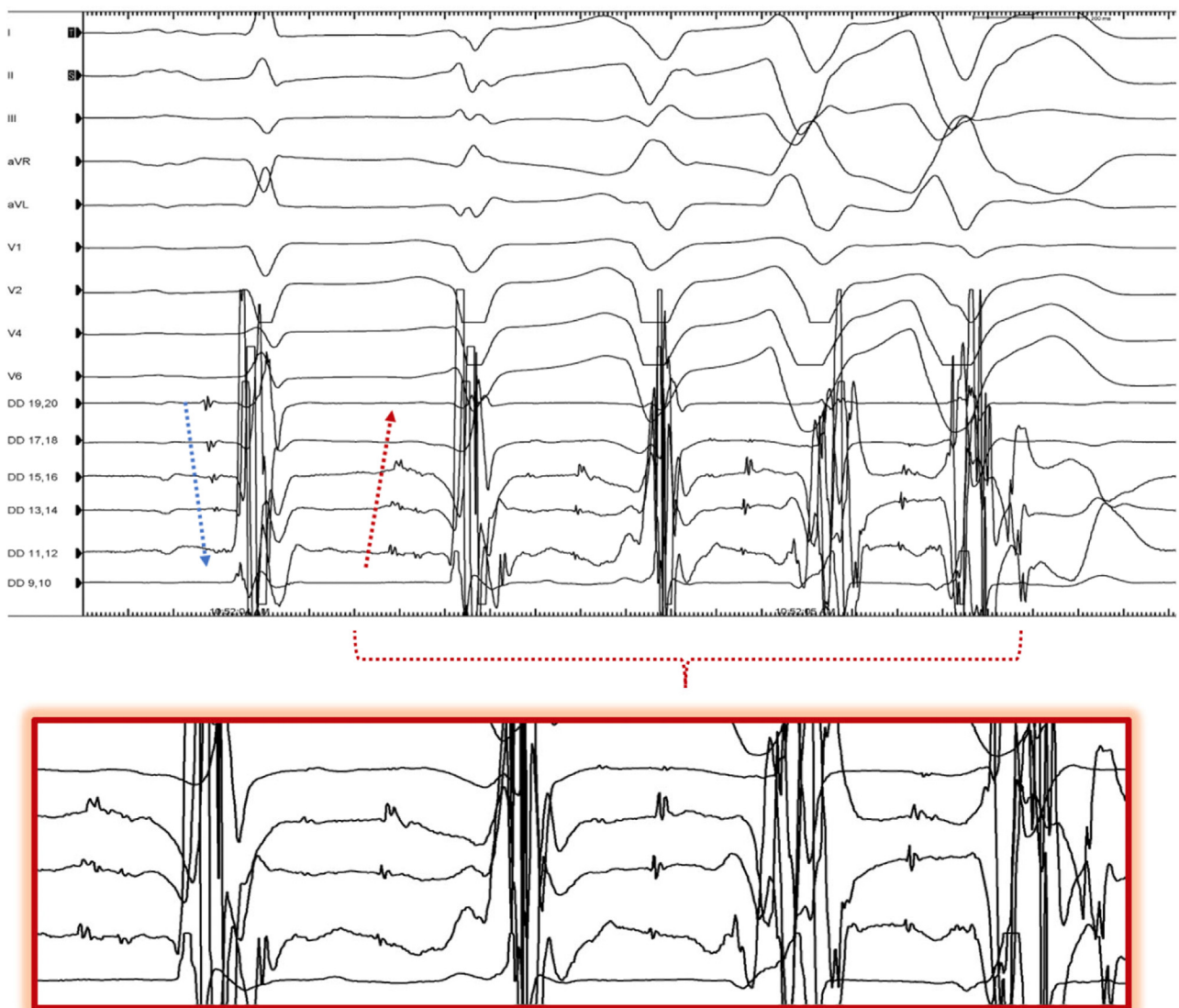


**Figure 1** A: Implantable cardioverter-defibrillator electrogram of an episode of premature ventricular contraction (PVC)-induced ventricular fibrillation. The coupling interval of the culprit PVC is 375 ms (black asterisk). B: Rhythm strip showing sinus rhythm and bigeminal PVCs with QRS pleomorphism. PVCs are highlighted with colors representing slightly different morphologies. The PVCs have a relatively narrow QRS duration (120–125 ms), a rapid initial deflection, and a short-coupling interval (360 ms) with R-on-T phenomenon.

At this point, a decision was made to pursue an endocardial-only catheter ablation to eliminate the conduction system PVCs initiating VF. The patient provided informed consent and was brought to the electrophysiology lab.

The procedure was performed under general anesthesia. Intracardiac echocardiography showed concentric LV hypertrophy and depressed LV ejection fraction. High-resolution electrophysiologic mapping was performed using the EnSite Precision™ (Abbott, Chicago, IL) navigation system. A decapolar mapping catheter (Biosense Webster, Irvine, CA) was placed along the right ventricular septum and a Livewire

steerable duodecapolar mapping catheter with 2 mm inter-electrode spacing (Abbott) along the LV septum. Sequential antegrade His and Purkinje potentials were recorded during sinus rhythm. The earliest electrograms during PVCs were noted along the proximal LV septum and were consistently preceded by high-frequency Purkinje potentials with a retrograde activation sequence. During salvos of PMVT, Purkinje split potentials were noted with increasing intra-split delay over consecutive beats, suggestive of possible intra-Purkinje reentry or diseased Purkinje tissue (Figure 2). This confirmed the Purkinje-mediated mechanism of this VF storm. The activation map localized the earliest presystolic



**Figure 2** Signals recorded from surface electrocardiogram and a Livewire duodecapolar mapping catheter (Abbott) positioned along the left ventricular septum. Sequential antegrade His and Purkinje potentials are recorded during the first sinus rhythm beat (*blue arrow*) and a retrograde sequence is observed during the first Purkinje ectopy beat (*red arrow*). During salvos of polymorphic ventricular tachycardia, note the Purkinje split potentials with increasing delay in between the splits, with consecutive beats suggestive of possible intra-Purkinje reentry (*magnified portion*).

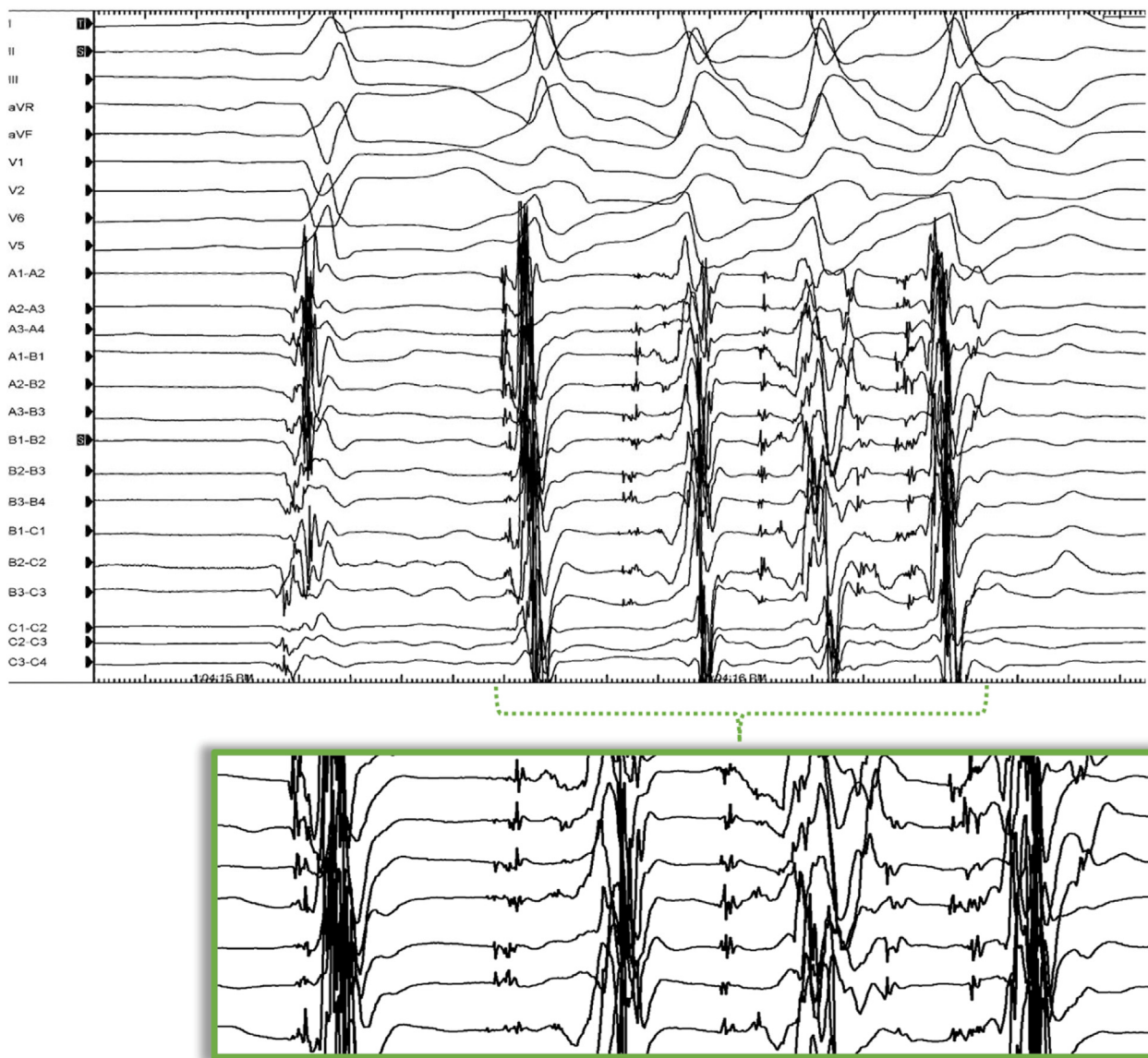
Purkinje-triggered PVC activation at the level of the proximal left fascicle (55 ms early) ([Supplemental Figure 1A](#)).

Prior to ablation, the patient went into VF storm owing to incessant spontaneous Purkinje ectopy triggering VF. Eleven successive defibrillations were necessary in quick succession. Lidocaine and amiodarone (both intravenous) were required to regain electrical and hemodynamic stability.

Ablation was then performed over the proximal left fascicular region using an irrigated tip ablation catheter (TactiCath™, Abbott). Automaticity with salvos of PVCs and VF was noted during ablation, followed by complete suppression. After the first set of lesions, a second type of PVC was noted frequently on Isoproterenol. These PVCs had right bundle branch block morphology with a wider QRS duration (152 ms) and a longer coupling interval (460 ms) compared to the first PVCs, but still

induced salvos of nonsustained PMVT/VF. Mapping of the distal LV septum was performed with an Advisor HD Grid™ catheter (Abbott). Early Purkinje potentials (60 ms early) were identified over the distal left fascicle with intra-Purkinje splits during PMVT ([Figure 3](#) and [Supplementary Figure 1B](#)). After ablation and subsequent suppression of these PVCs, PVCs with a wide left bundle branch block morphology were mapped and ablated on the mid right ventricular septum. These PVCs did not induce VF. They were not preceded by Purkinje prepotentials and likely had a myocardial origin. A total of 35 minutes of radiofrequency energy was applied using half normal saline irrigant.

At the end of the procedure, no PVCs triggering PMVT/VF were seen despite high-dose isoproterenol infusion. Of note, a new nonspecific intraventricular conduction delay



**Figure 3** Signals recorded from surface electrocardiogram and a multielectrode Advisor HD Grid catheter (Abbott) positioned along the distal left ventricular septum. A premature ventricular contraction preceded by early Purkinje potentials is observed on the second beat, followed by Purkinje-driven nonsustained ventricular tachycardia with Purkinje split potentials (*magnified portion*).

(QRS duration of 122 ms) was observed after ablation over the left fascicles. An LV endocardial bipolar voltage map was performed (0.5–1 mV) and showed a limited basal lateral low-voltage area. There were no immediate complications. Antiarrhythmic agents were stopped at 1-month follow-up. The patient had no VF recurrences or ICD shock therapy during 12-months follow-up. A repeat echocardiogram showed improved LV ejection fraction to 45%–50%.

## Discussion

Purkinje ectopy triggering VF storm is a true electrophysiological emergency and prompts careful evaluation. In patients with structural heart disease, it is a rare entity distinct from short-coupled VF and idiopathic VF.<sup>3,7</sup> Although rarely reported, this case serves as a reminder that Purkinje triggers

for VF can also be seen in patients with structural heart disease.<sup>2,6,8,9</sup>

Treatment of PVC-triggered VF in patients with structural heart disease should first be aimed at removing the inciting reversible proarrhythmic cause promptly: electrolyte imbalance, myocardial ischemia, QT-prolonging drugs, heart failure decompensation, inflammation, etc. Antiarrhythmic agents can be helpful. However, there is a paucity of data regarding their effectiveness in treating this population. The effectiveness of quinidine may be extrapolated from short-coupled VF and idiopathic VF studies that showed a ventricular arrhythmia burden reduction.<sup>7,10</sup> ICD is recommended in patients who experience sudden cardiac death caused by VT/VF, hemodynamically unstable VT, or sustained VT in the absence of reversible causes.<sup>1</sup> Successful catheter ablation of Purkinje PVCs triggering PMVT/VF has been sporadically reported.<sup>3–6</sup>

High-resolution mapping with multipolar catheters may aid in better identification of Purkinje potentials and their characteristics compared with mapping with the ablation catheter. In this case, the presence of intra-Purkinje splits during PVCs/PMVT suggests Purkinje slow conduction and possible local reentry as a mechanism for VF maintenance. The role of intramyocardial reentry (or rotor) in VF has been proposed in a small human cohort.<sup>11</sup> Reentry involving the Purkinje network system during VF has been evoked through computer models.<sup>12,13</sup> In this case, identification of the abnormal split Purkinje potentials using high-density multipolar catheters and ablation was critical in successful elimination of VF. In the absence of triggering PVC, abnormal substrate ablation has proved to be a useful alternative.<sup>3–5,14</sup> We believe that abnormal split Purkinje potentials should be carefully sought during substrate VF mapping, as they may be involved in PMVT/VF maintenance. Further studies are needed to define their role in VF genesis.

## Conclusion

We describe a case of Purkinje ectopy-triggering VF storm refractory to medical treatment and successfully treated with high-resolution mapping and catheter ablation. Ablation of ventricular arrhythmia has classically been reserved for monomorphic VT but may also play a critical role in selected patients with PMVT/VF.

## Appendix Supplementary data

Supplementary data associated with this article can be found in the online version at <https://doi.org/10.1016/j.hrcre.2021.12.015>.

## References

1. Al-Khatib SM, Stevenson WG, Ackerman MJ, et al. 2017 AHA/ACC/HRS Guideline for Management of Patients With Ventricular Arrhythmias and the Prevention of Sudden Cardiac Death: A Report of the American College of Cardiology/American Heart Association Task Force on Clinical Practice Guidelines and the Heart Rhythm Society. *J Am Coll Cardiol* 2018;72:e91–e220.
2. Haissaguerre M, Vigmond E, Stuyvers B, Hocini M, Bernus O. Ventricular arrhythmias and the His-Purkinje system. *Nat Rev Cardiol* 2016;13:155–166.
3. Haissaguerre M, Duchateau J, Dubois R, et al. Idiopathic ventricular fibrillation: role of Purkinje system and microstructural myocardial abnormalities. *JACC Clin Electrophysiol* 2020;6:591–608.
4. Marrouche NF, Verma A, Wazni O, et al. Mode of initiation and ablation of ventricular fibrillation storms in patients with ischemic cardiomyopathy. *J Am Coll Cardiol* 2004;43:1715–1720.
5. Nogami A. Mapping and ablating ventricular premature contractions that trigger ventricular fibrillation: trigger elimination and substrate modification. *J Cardiovasc Electrophysiol* 2015;26:110–115.
6. Bode K, Hindricks G, Piorowski C, et al. Ablation of polymorphic ventricular tachycardias in patients with structural heart disease. *Pacing Clin Electrophysiol* 2008;31:1585–1591.
7. Steinberg C, Davies B, Mellor G, et al. Short-coupled ventricular fibrillation represents a distinct phenotype among latent causes of unexplained cardiac arrest: a report from the CASPER registry. *Eur Heart J* 2021;42:2827–2838.
8. Sinha AM, Schmidt M, Marschang H, et al. Role of left ventricular scar and Purkinje-like potentials during mapping and ablation of ventricular fibrillation in dilated cardiomyopathy. *Pacing Clin Electrophysiol* 2009;32:286–290.
9. Van Herendael H, Zado ES, Haqqani H, et al. Catheter ablation of ventricular fibrillation: importance of left ventricular outflow tract and papillary muscle triggers. *Heart Rhythm* 2014;11:566–573.
10. Belhassen B, Glick A, Viskin S. Excellent long-term reproducibility of the electrophysiologic efficacy of quinidine in patients with idiopathic ventricular fibrillation and Brugada syndrome. *Pacing Clin Electrophysiol* 2009;32:294–301.
11. Krummen DE, Hayase J, Morris DJ, et al. Rotor stability separates sustained ventricular fibrillation from self-terminating episodes in humans. *J Am Coll Cardiol* 2014;63:2712–2721.
12. Berenfeld O, Jalife J. Purkinje-muscle reentry as a mechanism of polymorphic ventricular arrhythmias in a 3-dimensional model of the ventricles. *Circ Res* 1998;82:1063–1077.
13. Vigmond EJ, Bouyssier J, Bayer J, Haissaguerre M, Ashikaga H. On the nature of delays allowing anatomical re-entry involving the Purkinje network: a simulation study. *Europace* 2021;23:i71–i79.
14. Nakamura T, Schaeffer B, Tanigawa S, et al. Catheter ablation of polymorphic ventricular tachycardia/fibrillation in patients with and without structural heart disease. *Heart Rhythm* 2019;16:1021–1027.