Duodeno-enteral omega switches – more physiological techniques in metabolic surgery

W. Konrad Karcz[1], Simon Kuesters[2], Goran Marjanovic[2], Jodok M. Grueneberger[2]

[1]University of Schleswig-Holstein, Campus Lübeck, Lübeck, Germany
[2]Department of General and Visceral Surgery, University of Freiburg, Freiburg, Germany

Videosurgery Miniinv 2013; 8 (4): 273–279
DOI: 10.5114/wiitm.2013.39647

Abstract

Introduction: *In bariatric surgery, still new surgical techniques are developed. On the one hand, the Roux-en-Y gastric bypass (RYGB) is one of the most common procedures used. However, many patients experience dumping syndrome or pain due to bile reflux. On the other hand, revisions after gastric banding are frequent and may be technically challenging.*
Aim: *To create a new bariatric procedure counterbalancing the drawbacks of conventional RYGB, also suitable as a redo option after gastric banding.*
Material and methods: *To diminish the complication rate and pathophysiological disadvantages in reoperations after gastric banding, we primarily combined a gastric plication (GP) with a single anastomosis duodeno-ileal omega switch (DIOS), bypassing 2/3 of the total bowel length. Further on, in patients with lower body mass index we combined a GP or LSG and laparoscopic sleeve gastrectomy with a duodeno-jejunal omega switch (DJOS), performing an end-to side anastomosis after 1/3 of the total bowel length.*
Results: *The DIOS and DJOS techniques restrict food intake and bypass the duodenum and part (DJOS) or the whole (DIOS) jejunum. Restriction is achieved either through gastric plicature or conventional sleeve gastrectomy.*
Conclusions: *Similar bariatric and metabolic effects to proximal RYGB are expected in the case of DJOS, or to a conventional duodenal switch when performing a DIOS procedure. Performing a gastric plicature will reduce the risk of gastric leak when revising patients after failed gastric banding.*

Key words: *gastric plication, SADI-S, bariatric surgery, laparoscopic sleeve gastrectomy, Roux-en-Y gastric bypass, biliopancreatic diversion.*

Introduction

Restrictive operations such as vertical banded gastroplasty (VBG) or laparoscopic adjustable gastric banding (LAGB) have been very popular weight loss operations in the past [1, 2]. Further development led to the Magenstrasse and Mill operation (M&M), and thence to laparoscopic sleeve gastrectomy (LSG) [3–5]. Banded sleeve gastrectomy (BSG) was established as a combination of VBG and LSG [6]. In order to reduce the risk of gastric leak, Talebpour *et al.* developed laparoscopic gastric plication (LGP), also creating a sleeve-like stomach [7]. On the other hand, malabsorptive operations evolved from jejuno-ileal bypass (JIB) through biliopancreatic diversion (BPD) to combined, restrictive and malabsorptive procedures such as biliopancreatic diversion with duodenal switch (BPD-DS) or single anastomosis

Address for correspondence
Dr. Jodok Matthias Grueneberger, Department of General and Visceral Surgery, University of Freiburg, Hugstetter Str. 55, 79106 Freiburg, Germany, phone: +49 761 270 26970, e-mail: jodok.grueneberger@uniklinik-freiburg.de

duodeno-ileostomy associated with a sleeve gastrectomy (SADI-S) [8].

A large number of patients undergo revision after LAGB. There is a well-known risk in conversion to LSG or Roux-en-Y gastric bypass (RYGB) in that the stapler may cut the scar on the stomach after band explantation, thus causing possible staple line instability [9]. To avoid these problems, some surgeons still perform the conventional Scopinaro operation as a revisionary procedure after LAGB [10]. After band explantation, a gastric plication could be used to restore restriction and to avoid gastric resection. Although the LGP is mostly used these days as a sole bariatric operation [11], it could be combined with a duodeno-enterostomy omega switch to preserve the pylorus, antrum and stomach as a functionally intact reservoir. Performing a pancreatic head resection, the antrum and pylorus historically were preserved for the first time by Watson after radical Papilla-Vateri tumor resection [12]. Strong protagonists of the method were Traverso and Longmire. They believed that antrum and pylorus preservation decreased postoperative jejunal ulceration, perforation and bile reflux [13]. The trend was also observed in bariatric surgery with the development of the duodenal switch [14–16]. Hinder proposed a similar reconstruction especially for patients suffering from duodeno-gastric reflux disease [17]. The Mini Gastric Bypass (MGB), which combines a vertical stomach pouch formation with a Billroth II gastro-jejunostomy, influenced the next modification by Sanchez-Pernautein in which a single anastomosis duodeno-ileal reconstruction (SADI-S) was used, again preserving the pylorus [18, 19].

Aim

The advantages of LGP and SADI-S could be used to create new procedures in terms of hybrid operations comprised of gastric plication and duodeno-enteral omega switch reconstructions. These variations maintain the flexibility of the MGB (proximal, distal), yet minimize biliary reflux, which is the weak point of the procedure.

For patients after gastric banding we propose the following two operations: with malabsorption analogous to BPD-DS or SADI-S a Duodeno-Ileal Omega Switch with Gastric Plication (DIOS-GP), and similar to proximal or Mini Gastric Bypass a Duodeno-Jejunal Omega Switch with Gastric Plication (Omega DJOS-GP). For primary operations, instead of a gastric plication an LSG could be used as a restrictive component with identical loop reconstructions leading to Duodeno-Ileal Omega Switch with LSG (DIOS-SG) and Duodeno-Jejunal Omega Switch with LSG (DJOS-SG) operations.

Material and methods

We perform the operation as a two-surgeon procedure with the patient in the lithotomic position and the operating table at a 30-degree reverse Trendelenburg tilt. The surgeon stands between the patient's legs with one assistant on the patient's left side. After penetrating into the abdominal cavity with a 12-mm single-use separator trocar (Pajunk, Geisingen, Germany) through the musculus rectus abdominis in the left lateral quadrant, insufflation of carbon dioxide is commenced with a set point at 14 mm Hg (Termoflator Set, Storz, Tuttlingen, Germany). Two other 5-mm and 12-mm separator trocars are placed. The epigastric region is exposed by lifting the left lobe of the liver with a liver retractor.

The dissection begins on the greater curvature approximately 4 cm to 6 cm from the pylorus. The greater curvature of the stomach is separated from the omentum majus using a LigaSure® vessel sealing device (Covidien, Dublin, Ireland). Once the bursa omentalis is entered, the dissection is continued under preservation of the gastro-omental artery in a cephalic direction until the posterior pole of the spleen and the left crus of the diaphragm are visualized under preservation of at least two short gastric vessels located close to the crus in order to safely maintain blood supply at the critical gastro-oesophageal junction. A 35 Ch gastric tube is then introduced per os. The first stomach plication is made with the 3-0 V-Loc™ Suture (Covidien, Dublin, Ireland). The continuous suturing begins at the fundus along the separation line of the gastro-splenic and gastrocolic ligaments. After completion, we make three additional Biosyn 3-0 single sutures (Covidien, Dublin, Ireland), which are located on the upper medial and lower part of the stomach. Each single suture is located on the medial vertical part of the anterior and posterior wall to create the actual stomach plication (Photo 1). The plication is then secured by a second continuous suture with 2-0 V-Loc (Covidien, Dublin, Ireland) beginning on the gastric fundus, exactly on the faulted stomach edge. If the restriction is not tight enough, a third layer of inter-

rupted sutures is performed. An intraoperative gastroscopy ends the first part of the operation. In the case of a sleeve gastrectomy the technique used was as described earlier by our group [6].

The second step of the operation starts with the separation of the duodenum with an endostapling device (Auto Suture, Covidien, Dublin, Ireland, purple cartridge). Before performing the duodenoenterostomy, the length of the small bowel is determined to account for inter-individual differences. After measurement, the omega loop should be placed near the postpyloric duodenum without rotation. The position of the duodenoenterostomy is determined to be aboral of the Treitz ligament, 33% of the total small bowel length for DJOS-GP (SG) (Figures 1 A, 2 A), and 66% of the total small bowel length for DIOS-GP (SG) (Figures 1 B, 2 B).

The duodenojejunostomy is performed as a simple antecolic, continuous end-to-side hand-sewn anastomosis using 3-0 sutures. Creating a double-layer anastomosis on the back side, the duodenal staple line is included in the outer back layer of the anastomosis (Photos 2, 3). Diluted half-strength methylene blue dye is used for leak testing after completing the anastomosis. Finally, a drain is placed towards the duodenal stump.

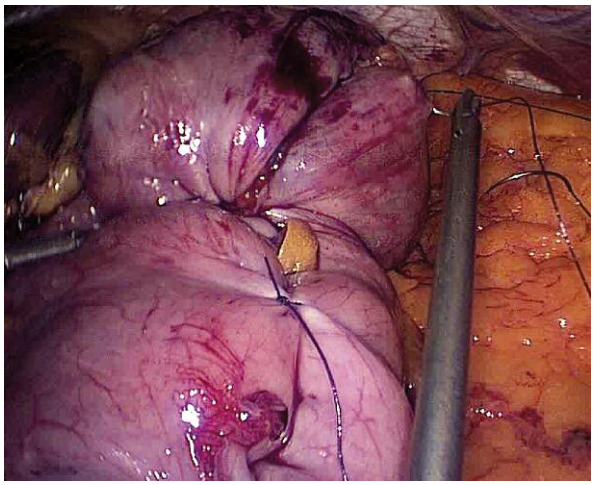

Photo 1. Gastric plication before the second layer of 3-0 V-Loc™ sutures is applied. The Biosyn 3-0 single sutures can also be used technically as holding sutures

Discussion

The procedures contain alterations compared to established bariatric procedures. Restriction has to be considered in all bariatric procedures. In comparison with the small pouch created in conventional bypass

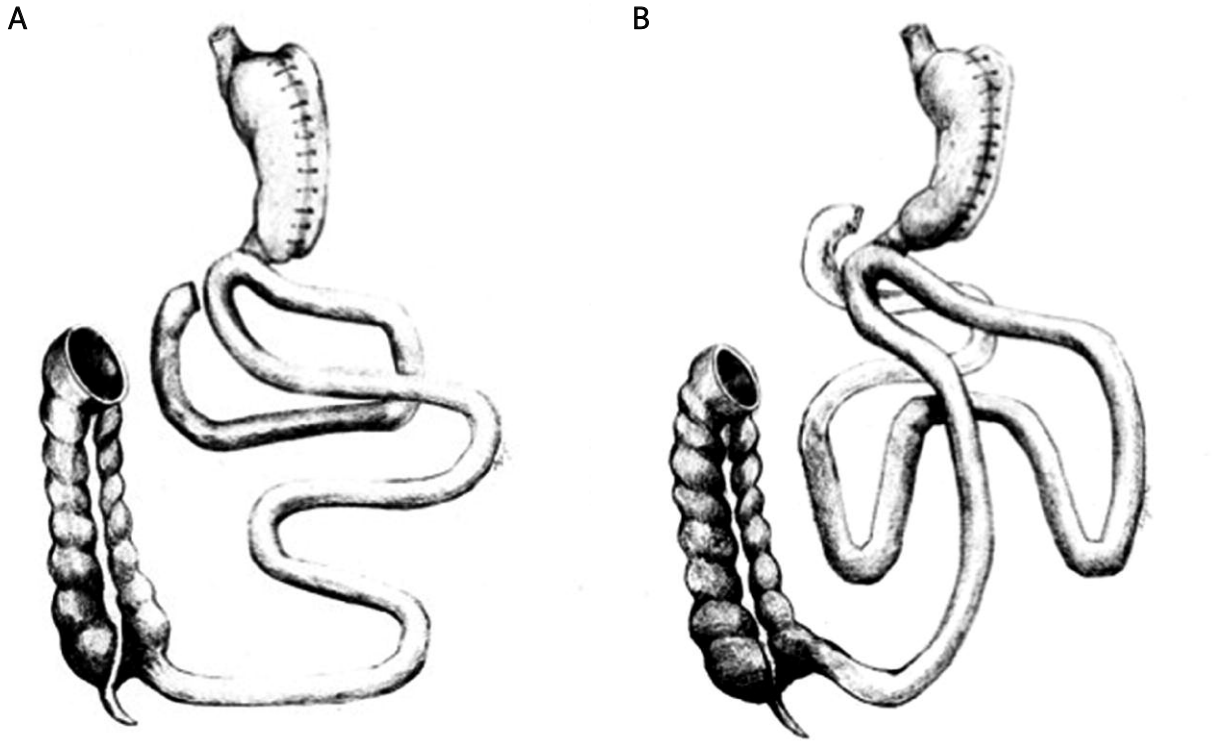

Figure 1. Diagram of a duodeno-*jejunal* omega switch with gastric plication (DJOS-GP, **A**) and a duodeno-*ileal* omega switch with gastric plication (DIOS-GP, **B**)

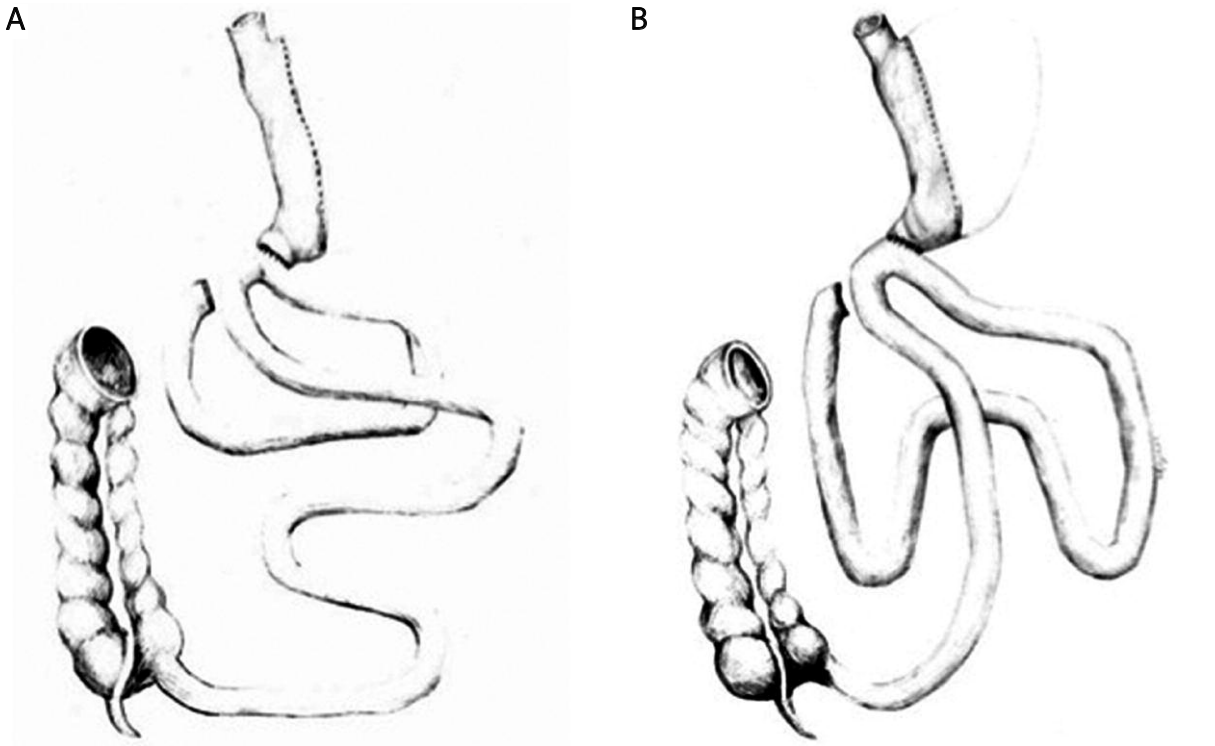

Figure 2. Diagram of a duodeno-*jejunal* omega switch with sleeve gastrectomy (DJOS-SG, **A**) and a duodeno-*ileal* omega switch with sleeve gastrectomy (DIOS-SG, **B**)

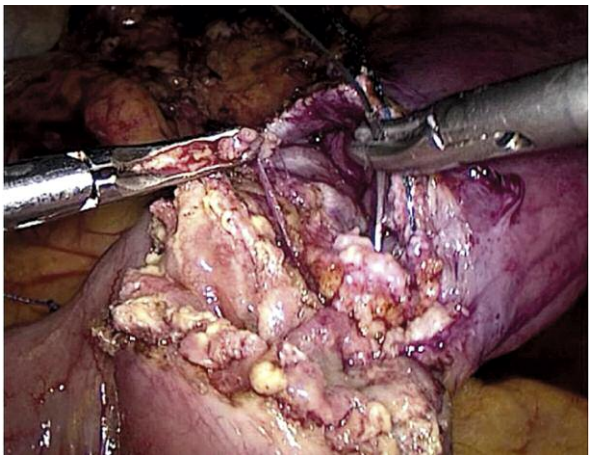

Photo 2. Duodenoenterostomy with 3-0 V-loc™ continuous sutures creating a double-layer anastomosis on the back side

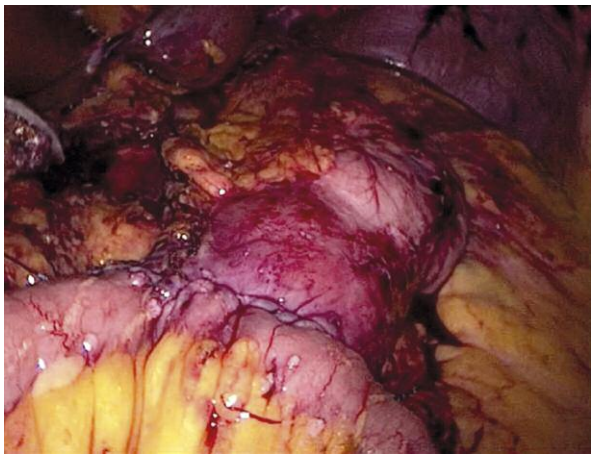

Photo 3. Final aspect of a gastric plication combined with a duodenoenterostomy

operations, a sleeve stomach offers a greater stomach capacity, allowing better participation in everyday life. At the same time, it offers similar weight loss [20]. Laparoscopic sleeve gastrectomy was originally introduced as the first step of a two-step BPD-DS by Regan *et al.*, yet only about one-third of the LSG patients needed BPD-DS as a second step 3 years after the primary operation [21, 22]. Functional magnetic resonance imaging (MRI) analysis demonstrated a delayed gastric passage in the sleeve section of the stomach, leading to early satiation while simultaneously decreasing the emptying half time to provoke early stimulation of the terminal ileum [23]. We decided to use a sleeve-like stomach as a restrictive

component. Since gastric plication eliminates the risk of a staple line leak or bleeding, this procedure seems a favourable alternative to conventional sleeve gastrectomy in case stapling the stomach is considered high risk [11]. Restrictively, the percent excess weight loss after LGP is inferior in short-term follow-up when compared to conventional LSG, yet overall weight loss still lies at 57% after 3 years [24, 25].

All malabsorptive procedures bypass the duodenum, therefore requiring passage reconstruction via Roux-en-Y or Billroth II (BII). In bariatric surgery, the Roux-en-Y reconstruction is most often used today for laparoscopic gastric bypass or duodenal switch operations [26]. The Billroth II omega gastro-enterostomy reconstruction after distal stomach resection was first introduced to obesity surgery by Mason with the first gastric bypass in 1967 [27]. The procedure was modified by Alden 10 years later [28]. In 1980, Scopinaro described a BII reconstruction in the bilio-pancreato-jejuno-ileal bypass [29]. Rutledge again used an omega (BII) reconstruction when developing the MGB [18]. The BII reconstruction leads to biliary reflux into the stomach. The brilliant idea of preserving the pylorus and performing an omega duodeno-enterostomy originates from a modification of the Watson operation and was popularized by Traverso and Longmire [12, 13]. The omega switch was introduced into bariatric surgery by Sanchez-Pernaute and Torres as a single anastomosis duodenoileal bypass with sleeve resection (SADI-S) as an evolution of BPD-DS [19].

In all malabsorptive operations, the critical issue is the position of the duodeno-enterostomy. Numerous limb-length combinations have been tested. Hav-

Table I. Advantages and disadvantages of metabolic procedures

Procedure	Pre-gut exclusion	Hindgut stimulation	Pouch outlet calibration	Pouch inlet (LES integrity)	ARO	CC length	Anastomosis count	Average costs [%]	Difficulty of revisionary surgery	Remnant stomach
BPD	+	+++	+	+	+	50–75	2	150	Medium	+ or –
BPD-DS	+	+++	+	–/+	–	75–100	2	150	Medium	–
RYGB	+	+	–	–/+	–	ND	2	120	Difficult	+
BRYGB	+	+	+	–/+	–	ND	2	130	Difficult	+
LAGB	–	–	+	–/+	+	NA	0	50	Medium	–
LSG	–	–/+	+	–/+	–	NA	0	100	Easy	–
LBSG	–	–/+	+	–/+	–	NA	0	150	Medium	–
LGP	–	–/+	+	+	+	NA	0	20	Medium	–
DJOS-GP	+	+	+	+	+	66% of small bowel	1	60	Medium	–
DIOS-GP	+	+++	+	+	+	33% of small bowel	1	60	Medium	–
DJOS-SG	+	+	+	–/+	–	66% of small bowel	1	130	Medium	–
DIOS-SG	+	+++	+	–/+	–	33% of small bowel	1	130	Medium	–
SADI-S	+	+++	+	–/+	–	200	1	130	Medium	–

Column 1: Pregut exclusion (+) or no exclusion (–) with regards to glycaemic control; column 2: hindgut stimulation intensity (– to +++) as an indicator for potential antidiabetic effect; column 3: pouch outlet calibration (natural: pylorus, artificial: ring or no calibration of the gastro-enteral anastomosis) with regard so satiety and dumping; column 4: pouch inlet: lower oesophageal sphincter impaired (–) or not affected (–) by bariatric operation; column 5: ARO: anti-reflux operation possible (+) or technically impossible (–) after primary bariatric surgery; column 6: length of common channel in cm, NA: not applicable, ND: not determined; column 7: overall number of anastomoses; column 8: average cost of the operation in relation to sleeve gastrectomy (100%); column 9: difficulty of revisionary surgery; column 10: procedures leave (+) or do not leave (–) a remnant stomach

ing observed a great variability in small bowel length, the whole length of the small intestine should be measured before introducing malabsorption to account for these inter-individual differences. BII reconstruction makes the anatomical situation easier; there is no alimentary limb and changing the length of the common channel automatically induces the opposite change of the biliopancreatic limb. The position of the duodenoenterostomy determines the type of omega switch: DJ (jejunal) or DI (ileal). For the DJOS, the anastomosis should be placed at one-third of the total small bowel length (two-thirds common channel). For the DIOS it should be placed at two-thirds of the small bowel length (one-third common channel). However, the common channel should never be shorter than 2 m [8]. This method of common channel measurement is analogous to Hess's BPD-DS [14]. Scopinaro stated that the resorption of biliopancreatic fluids within the biliopancreatic limb causes the restricted ability of fat resorption after BPD. Therefore, elongation of the common channel does not alter fat resorption [30]. Hence, there is no difference between a common channel of 100 cm and an alimentary limb of 100 cm in classic BPD-DS operations and a 200 cm common channel in the SADI-S operation (Table I). For us, this was the second reason – besides technical simplification – to avoid the Y anastomosis.

The question where to place the duodeno-jejunostomy is more difficult. From empirical bariatric surgery, we know that the measurement is performed starting at the ligament of Treitz and a lot of surgeons use different lengths of alimentary (AL) and biliopancreatic (BPL) limbs. But again, the length of 2 m (this time in the proximal small intestine) is used by many surgeons in different combinations: 150 cm of AL with 50 cm BPL [31–33], 120 cm AL and 80 cm BPL [34], and 200 cm of jejunal bypass when performing an MGB [18].

With the DIOS and DJOS, two bariatric operations exist to create restrictive and malabsorptive surgery with only one anastomosis not leaving a long stomach resection line. The DJOS-GP (SG) seems to be a real alternative to conventional gastric bypass, avoiding the formation of a remnant stomach (Table I). The new modifications feature another advantage: both of them could be performed as two-step procedures. Regan *et al.* proposed LSG as the initial operation for bypass surgery in order to lower operative risk in the super-obese, with later conversion of the sleeve to a conventional R-en-Y bypass [21]. Although economic aspects should never be the primary focus, DIOS-GP and DJOS-GP certainly prove to be cost-effective concerning operation time and material costs (Table I).

Both proposed methods are controversial and have to be further evaluated in prospective randomized trials.

References

1. Buchwald H, Avidor Y, Braunwald E, et al. Bariatric surgery: a systematic review and meta-analysis. JAMA 2004; 292: 1724-37.
2. Buchwald H, Williams SE. Bariatric surgery worldwide 2003. Obes Surg 2004; 14: 1157-64.
3. Baltasar A, Serra C, Pérez N, et al. Laparoscopic sleeve gastrectomy: a multi-purpose bariatric operation. Obes Surg 2005; 15: 1124-8.
4. Johnston D, Dachtler J, Sue-Ling HM, et al. The Magenstrasse and Mill operation for morbid obesity. Obes Surg 2003; 13: 10-6.
5. Hady HR, Dadan J, Gołaszewski P, Safiejko K. Impact of laparoscopic sleeve gastrectomy on body mass index, ghrelin, insulin and lipid levels in 100 obese patients. Videosurgery Miniinv 2012; 7: 251-9.
6. Karcz WK, Marjanovic G, Grueneberger J, et al. Banded sleeve gastrectomy using the GaBP ring: surgical technique. Obes Facts 2011; 4: 77-80.
7. Talebpour M, Amoli BS. Laparoscopic total gastric vertical plication in morbid obesity. J Laparoendosc Adv Surg Tech A 2007; 17: 793-8.
8. Sánchez-Pernaute A, Herrera MA, Pérez-Aguirre ME, et al. Single anastomosis duodeno-ileal bypass with sleeve gastrectomy (SADI-S). One to three-year follow-up. Obes Surg 2010; 20: 1720-6.
9. Gagner M, Gumbs AA. Gastric banding: conversion to sleeve, bypass, or DS. Surg Endosc 2007; 21: 1931-5.
10. Peterli R, Donadini A, Peters T, et al. Re-operations following laparoscopic adjustable gastric banding. Obes Surg 2002; 12: 851-6.
11. Ramos A, Galvao Neto M, Galvao M, et al. Laparoscopic greater curvature plication: initial results of an alternative restrictive bariatric procedure. Obes Surg 2010; 20: 913-8.
12. Watson K. Carcinoma of ampulla of vater successful radical resection. Br J Surg 1944; 31: 368-73.
13. Traverso LW, Longmire WP Jr. Preservation of the pylorus in pancreaticoduodenectomy. Surg Gynecol Obstet 1978; 146: 959-62.
14. Hess DS, Hess DW. Biliopancreatic diversion with a duodenal switch. Obes Surg 1998; 8: 267-82.
15. Marceau P, Hould FS, Simard S, et al. Biliopancreatic diversion with duodenal switch. World J Surg 1998; 22: 947-54.
16. Baltasar M, Bou R, Cipagauta LA, et al. 'Hybrid' bariatric surgery: bilio-pancreatic diversion and duodenal switch-preliminary experience. Obes Surg 1995; 5: 419-23.
17. Hinder RA. Duodenal switch: a new form of pancreaticobiliary diversion. Surg Clin North Am 1992; 72: 487-99.
18. Rutledge R. The mini-gastric bypass: experience with the first 1,274 cases. Obes Surg 2001; 11: 276-80.

19. Sánchez-Pernaute A, Rubio Herrera MA, Pérez-Aguirre E, et al. Proximal duodenal-ileal end-to-side bypass with sleeve gastrectomy: proposed technique. Obes Surg 2007; 17: 1614-8.
20. Lee WJ, Chong K, Ser KH, et al. Gastric bypass vs sleeve gastrectomy for type 2 diabetes mellitus: a randomized controlled trial. Arch Surg 2011; 146: 143-8.
21. Regan JP, Inabnet WB, Gagner M, Pomp A. Early experience with two-stage laparoscopic Roux-en-Y gastric bypass as an alternative in the super-super obese patient. Obes Surg 2003; 13: 861-4.
22. Nocca D, Krawczykowsky D, Bomans B, et al. A prospective multicenter study of 163 sleeve gastrectomies: results at 1 and 2 years. Obes Surg 2008; 18: 560-5.
23. Baumann T, Kuesters S, Grueneberger J, et al. Time-resolved MRI after ingestion of liquids reveals motility changes after laparoscopic sleeve gastrectomy: preliminary results. Obes Surg 2011; 21: 95-101.
24. Shen D, Ye H, Wang Y, et al. Comparison of short-term outcomes between laparoscopic greater curvature plication and laparoscopic sleeve gastrectomy. Surg Endosc 2013; 27: 2768-74.
25. Abdelbaki TN, Huang CK, Ramos A, et al. Gastric plication for morbid obesity: a systematic review. Obes Surg 2012; 22: 1633-9.
26. Paluszkiewicz R, Kalinowski P, Wróblewski T, et al. Prospective randomized clinical trial of laparoscopic sleeve gastrectomy versus open Roux-en-Y gastric bypass for the management of patients with morbid obesity. Videosurgery Miniinv 2012; 7: 225-32.
27. Mason EE, Ito C. Gastric bypass in obesity. Surg Clin North Am 1967; 47: 1345-51.
28. Alden JF. Gastric and jejunoileal bypass. A comparison in the treatment of morbid obesity. Arch Surg 1977; 112: 799-806.
29. Scopinaro N, Gianetta E, Civalleri D, et al. Two years of clinical experience with biliopancreatic bypass for obesity. Am J Clin Nutr 1980; 33 (2 Suppl.): 506-14.
30. Scopinaro N. Principals of metabolic surgery. T.O. Karcz WK (ed.) Springer 2012.
31. Weiner RA, Blanco ER, Weiner S. [Indications, technique and results of laparoscopic gastric bypass operation]. Kongressbd Dtsch Ges Chir Kongr 2002; 119: 210-5.
32. Karcz WK, Suslin D, Baumann T, et al. To have or not to have the ring: early and late surgical complications after banded Roux-en-Y gastric bypass. Videosurgery Miniinv 2008; 3: 53-65.
33. Inabnet WB, Quinn T, Gagner M, et al. Laparoscopic Roux-en-Y gastric bypass in patients with BMI <50: a prospective randomized trial comparing short and long limb lengths. Obes Surg 2005; 15: 51-7.
34. Proczko M, Kaska L, Kobiela J, et al. Roux-en-Y gastric bypass in dialysed morbidly obese patients as a preparation for a kidney transplantation: case series. Videosurgery Miniinv 2013; 8: 174-7.

Received: 2.08.2013, **accepted:** 5.11.2013.