



## Case report

# A long-term survivor of non-small-cell lung cancer harboring concomitant EGFR mutation and ALK translocation



Fumio Imamura<sup>\*</sup>, Takako Inoue, Madoka Kimura, Kazumi Nishino, Toru Kumagai

Department of Thoracic Oncology, Osaka Medical Center for Cancer and Cardiovascular Diseases, Osaka, Japan

## ARTICLE INFO

## Article history:

Received 26 August 2016

Accepted 11 September 2016

## Keywords:

Lung cancer  
EGFR mutation  
T790M  
ALK translocation  
Concomitant

## ABSTRACT

In January 2003, a 55-year old, non-smoking woman visited our hospital to undergo treatment for T4N0M0 pulmonary adenocarcinoma of the left lung. Until death in October 2015, she received over 20 lines of treatment including a second line therapy with gefitinib, which showed long response. In March 2014, she noticed the left axillar lymph node swelling. Aspiration cytology of the lymph node revealed the presence of adenocarcinoma harboring EGFR exon 19 deletion (Ex19del) but not T790M. Concomitant ALK translocation of variant 1 was also detected. Crizotinib and alectinib showed marked decrease of serum CEA value from 731.9 to 122.2 and moderate radiologic response. In contrast, both Ex19del and T790M, but not ALK translocation, were detected in the metastasis to the left anterior chest wall.

© 2016 The Authors. Published by Elsevier Ltd. This is an open access article under the CC BY-NC-ND license (<http://creativecommons.org/licenses/by-nc-nd/4.0/>).

The activated mutation of epidermal growth factor receptor (EGFR) and translocation of anaplastic lymphoma kinase (ALK) are key molecular changes in non-small cell lung cancer (NSCLC). Tyrosine kinase inhibitors (TKIs) for them, EGFR-TKI and ALK-TKI, play essential roles in the treatment for NSCLC. Despite conventionally mutually exclusive, concomitant presence of these 2 genetic changes was sporadically reported in NSCLC. For example, Yang J-J et al. reported that the frequency of the concomitant presence was approximately 1.3% in 977 consecutive patients with NSCLC surgical specimens [1]. Lee T et al. reported only 3 cases of concomitant presence of common EGFR mutation and ALK translocation in 6637 NSCLC patients [2]. These mutations are supposed to be developed through de novo process in this setting, but their origin is not clear in the patients who underwent preceding TKI treatments. Actually, gain of activated EGFR mutation is reported as one of acquired resistance mechanisms for crizotinib, an ALK-TKI, whereas the opposite is rare. We experienced a NSCLC patient who had a long-term history of treatment with anti-cancer

drugs including EGFR-TKIs, and finally found that her lung cancer carried both an activated EGFR mutation and ALK translocation.

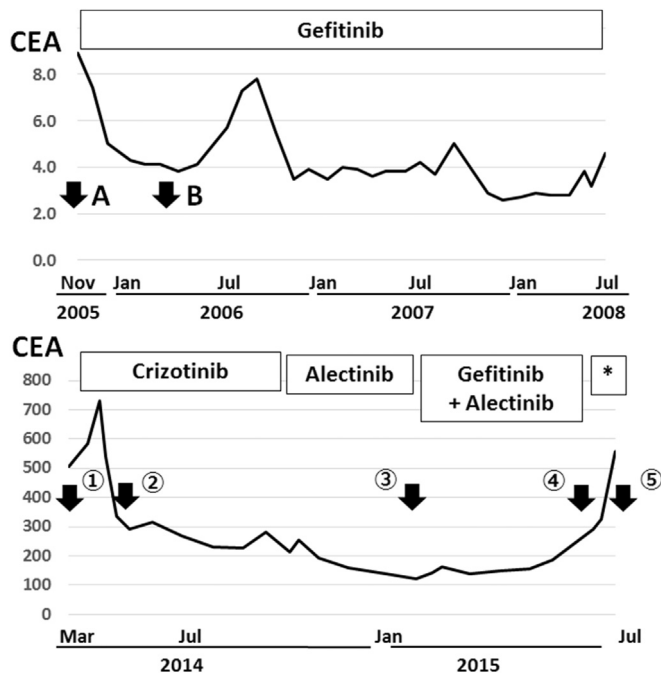
## 1. Case report

In January 2003, a 55-year old, non-smoking woman visited our hospital to undergo treatment for pulmonary adenocarcinoma of the left lung. Chest computed tomography (CT) suggested the presence of pleural dissemination, which was proved by video-assisted thoracic surgery (VATS), resulting the stage of her lung cancer to be T4N0M0 by the TNM staging system at the time. Until death in October 2015, she received over 20 lines of treatment. EGFR mutation test was not commercially available in Japan in 2005. However, gefitinib was started as the 2nd line therapy in October 2005, because she is a non-smoker Japanese woman. The response to gefitinib was shown in Figs. 1A and 2: Gefitinib exhibited prominent effect with a partial response lasting for 31 months. On the contrary, cytotoxic chemotherapy was generally less effective for her lung cancer: The durations of response of the representative chemotherapy regimens such as carboplatin + paclitaxel in combination with bevacizumab, docetaxel, and nab-paclitaxel to be 2M, 14M, and 2M, respectively.

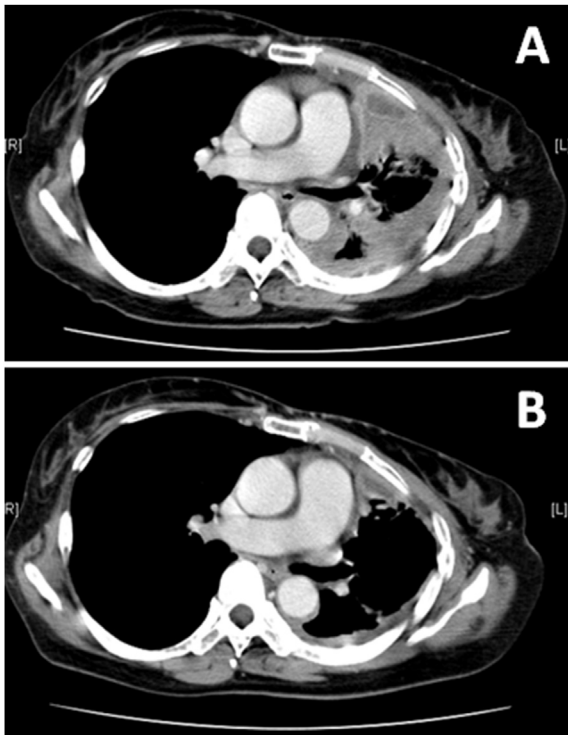
In March 2014, she noticed the left axillar lymph node (LN)

<sup>\*</sup> Corresponding author. Department of Thoracic Oncology, Osaka Medical Center for Cancer and Cardiovascular Diseases, 1-3-3 Nakamichi, Higashinari-ku, Osaka, 537-8511, Japan.

E-mail address: [imamura-fu@mc.pref.osaka.jp](mailto:imamura-fu@mc.pref.osaka.jp) (F. Imamura).



**Fig. 1.** Treatment history with an EGFR-TKI and ALK-TKIs. The vertical axis showed serum CEA values. Arrows indicated by A and B in the upper half show the time when CT images A and B in Fig. 2 were obtained, respectively. The numbers in the lower half indicate the time when CT images with the corresponding number in Fig. 3 and 5 were obtained, respectively. An asterisk indicates a 3rd generation of EGFR-TKI.



**Fig. 2.** Chest CT images during the treatment with an EGFR-TKI. A) extensive disease progression throughout in the left thorax before the start of gefitinib, and B) remarkable regression of the disease was attained with gefitinib.

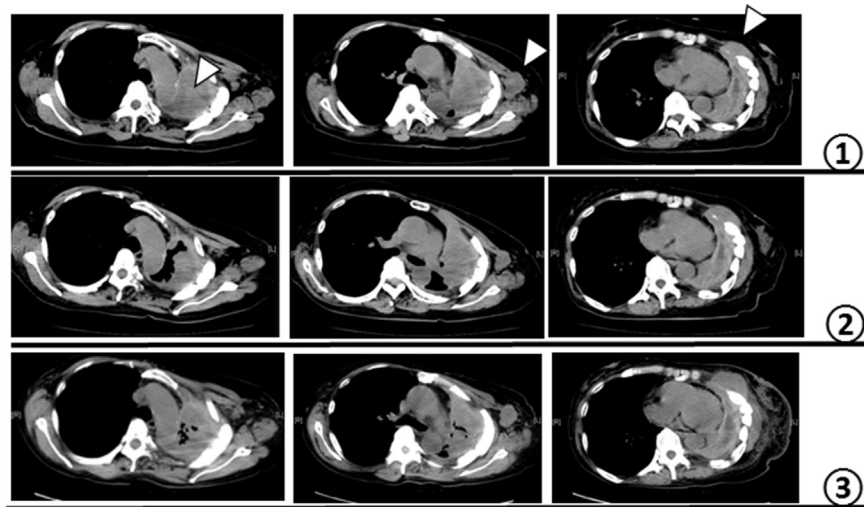
swelling (Fig. 3). Aspiration cytology of the LN revealed the presence of adenocarcinoma cells. Whereas EGFR exon 19 deletion (Ex19del) was detected as expected, a resistance mutation T790M was not detected. Surprisingly, ALK translocation of variant 1 was also detected. The presence of ALK translocation was confirmed by immunocytochemistry (Fig. 4). Neither immunohistochemistry nor fluorescent in-situ hybridization (FISH) was performed because of the lack of histologic material. Crizotinib of 500 mg/day was started as 19th line treatment in April 2014, which was continued until October 2014, then changed to alectinib, a second generation ALK-TKI. Serum CEA value decreased from 731.9 to 122.2 by the treatment with ALK-TKIs (Fig. 1). Although radiologic regression of the left lung mass and the left axillar LN was evident (Fig. 3①→②), the lesion in the left anterior chest wall was gradually increased in size (Fig. 3①→③). Genetic analysis of this lesion revealed EGFR Ex19del together with T790M, but ALK translocation could be detected neither by RT-PCR, immunohistochemistry, nor FISH. Because of gradual increase of serum CEA value after February 2015, the combination therapy with gefitinib and alectinib was started after the permission of in-house institutional review board. Her disease was relatively stable for the next 5 months. A third generation of EGFR-TKI was administered in July 2015, resulting in regression of lesions in the left lung and left chest wall. In contrast, the size of the left axillar LN stayed almost the same (Fig. 5).

## 2. Discussion

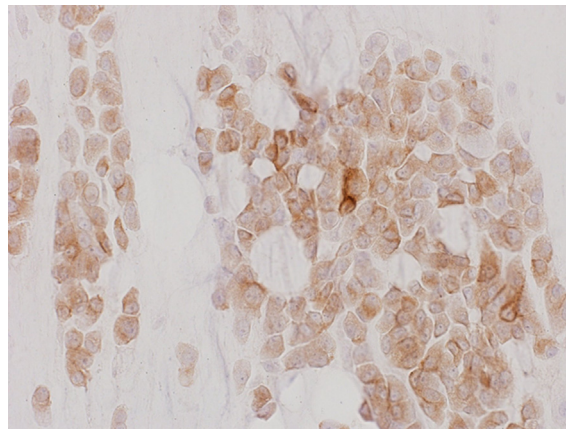
Although repetitive genetic testing of driver oncogenes is of critical importance nowadays, the results is not always simple. In our patient with a long history of lung cancer treatment including EGFR-TKIs, concomitant presence of an activated EGFR mutation, resistant T790M mutation, and ALK translocation was detected. Whereas T790M will have been dominated through selective pressure of EGFR-TKIs, the origin of ALK translocation is not clear. Long treatment history for her lung cancer suggests that cancer cells with the ALK translocation had not existed at the initial presentation. Instead, ALK translocation may have developed as an acquired resistance to EGFR-TKIs.

According to the preceding reports, the effect of ALK inhibitors on lung cancer which carries concomitant activated EGFR and ALK translocation is case-dependent: Some investigators observed a moderate response but the others did not [3–5]. In our patient, ALK-TKIs were undoubtedly effective, but the responses were different depending on the lesions. The left axillar LN, which carried translocated ALK, responded to ALK-TKIs, whereas the left chest wall lesion, which did not carry it, showed no distinct regression with ALK-TKIs. The fact that the mass in the left lung regressed in response to ALK-TKIs suggests that the lesion might also carry translocated ALK. These results indicate that the responses to ALK-TKIs reflected genetic status of each lesion. We tried the combination of gefitinib and alectinib. The combination was marginally effective.

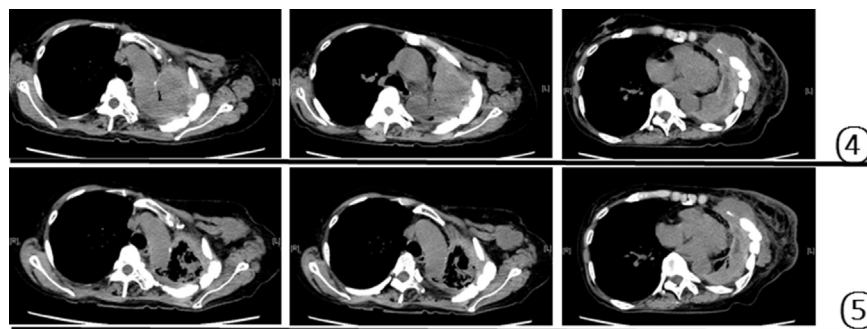
The better treatment for her disease might be a combination of a 3rd generation of EGFR-TKI and an ALK-TKI, because of the presence of T790M mutation. She underwent a 3rd generation EGFR-TKI as the 22-th treatment. The response was almost in accordance with the genetic status of the lesions. The response suggested that the lesion in the left lung might have contained T790M, although not tested. Our case suggests that genetic analysis guides the treatment strategy of lung cancer with multiple drivers. Further accumulation of treatment experiences is necessary.



**Fig. 3.** Chest CT images during the treatment with ALK-TKIs and the combination of an EGFR-TKI with an ALK-TKI. Arrow heads in the right, central, and left column indicate the lesion in the left lung, a left axillary lymph node, and a metastatic lesion to the thoracic wall, respectively.



**Fig. 4.** Immunocytochemical staining with an ALK antibody (Roche D5F3F). Almost all cancer cells were positive for ALK.



**Fig. 5.** Chest CT images before (4) and during (5) the treatment with a 3rd generation EGFR-TKI. Each column corresponds to that in Fig. 3. Appreciable response was observed.

## References

- [1] J.-J. Yang, X.-C. Zhang, J. Su, C.-R. Xu, Q. Zhou, Tian H-Xa, Z. Xie, H.-J. Chen, Y.-S. Huang, B.-Y. Jiang, Z. Wang, B.-C. Wang, X.-N. Yang, W.-Z. Zhong, Q. Nie, R.-Q. Liao, T.S. Mok, Y.-L. Wu, Lung cancers with concomitant EGFR mutations and ALK rearrangements: diverse responses to EGFR-TKI and crizotinib in relation to diverse receptors phosphorylation, *Clin. Cancer Res.* 20 (5) (2014) 1383–1392.
- [2] T. Lee, B. Lee, Y.L. Choi, J. Han, M.J. Ahn, S.W. Um, Non-small cell lung Cancer with concomitant EGFR, KRAS, and ALK mutation: clinicopathologic features of 12 cases, *J. Pathol. Transl. Med.* 50 (3) (2016 May) 197–203.
- [3] A. Miyanaga, K. Shimizu, R. Noro, M. Seike, K. Kitamura, S. Kosaihira, Y. Minegishi, T. Shukuya, A. Yoshimura, M. Kawamoto, S. Tsuchiya, K. Hagiwara, M. Soda, K. Takeuchi, N. Yamamoto, H. Mano, Y. Ishikawa, A. Gemma, Activity of EGFR-tyrosine kinase and ALK inhibitors for EML4-ALK-rearranged non-small-cell lung cancer harbored coexisting EGFR mutation, *BMC Cancer* 13 (2013 May 29) 262.
- [4] J. Zhou, J. Zheng, J. Zhao, Y. Sheng, W. Ding, J. Zhou, Poor response to gefitinib in lung adenocarcinoma with concomitant epidermal growth factor receptor mutation and anaplastic lymphoma kinase rearrangement, *Thorac. Cancer* 6 (2) (2015) 216–219.
- [5] M. Tiseo, F. Gelsomino, D. Boggiani, B. Bortesi, M. Bartolotti, C. Bozzetti, G. Sammarelli, E. Thai, A. Ardizzoni, EGFR and EML4-ALK gene mutations in NSCLC: a case report of erlotinib-resistant patient with both concomitant mutations, *Lung Cancer* 71 (2) (2011) 241–243.