

# Case Report

## Recurrent *Fusobacterium* pyogenic myositis of the rotator cuff A case report of recurrent *Fusobacterium* pyogenic myositis of the rotator cuff

Philip J. McElnay, Philip A. McCann, Martin O. Williams, Charles J. Wakeley, Rouin Amirfeyz

Access this article online

Website:

[www.internationalshoulderjournal.org](http://www.internationalshoulderjournal.org)

DOI:

10.4103/0973-6042.131854

Quick Response Code:



### ABSTRACT

Pyogenic myositis is uncommon. It normally affects the large muscle groups in the lower limb or trunk and the most common causative organism is *Staphylococcus aureus*. We present a case of an immunocompetent man who, unusually, had a recurring form of the disease in subscapularis and teres minor. The causative organism was also highly unusual (*Fusobacterium*).

**Key words:** Fusobacterium, pyomyositis, rotator cuff

**Key Messages:** Whilst uncommon, pyogenic myositis should be considered in patients presenting with signs and symptoms similar to those with septic joints.

Department of Trauma and Orthopaedics,  
University Hospitals Bristol, Bristol Royal  
Infirmary, United Kingdom

**Address for correspondence:**

Mr. Philip J McElnay,  
Bristol Royal Infirmary, Upper Maudlin  
Street, Bristol, BS2 8HW, United  
Kingdom.  
E-mail: pmcelnay@doctors.org.uk

### INTRODUCTION

Pyogenic myositis is a rare intramuscular infection. It most commonly occurs after a combination of muscle damage (e.g., due to intense exercise or local trauma) and a transient bacteraemia.<sup>[1]</sup> The causative organism is usually *Staphylococcus aureus*.<sup>[1]</sup> Sites of infection usually involve the large muscle groups in the lower limb or trunk.<sup>[1]</sup> The case we present is rare because of the anatomical site of infection, the causative organism and the recurring nature of the condition in an immunocompetent patient. There has been one reported case of *Fusobacterium* pyogenic myositis affecting the shoulder that resolved with intravenous antibiotics and ultrasound guided drainage.<sup>[2]</sup> To the best of our knowledge our case is the first reported of a recurring *Fusobacterium* pyogenic myositis of the shoulder requiring multiple surgical drainage procedures.

### CASE REPORT

We present a case of a 56-year-old right-hand dominant builder. He gave a weeks' history of worsening pain around his right

shoulder joint. There was no history of trauma or injection. He had been feeling feverish and also had complained of a sore throat a few weeks previously. His past medical history included diverticular disease and osteoarthritis of the right knee. He had no history of being immunocompromised. He was HIV negative and did not have diabetes.

On examination, the patient held the right shoulder in internal rotation. No active movement was possible and any attempted passive movement was significantly uncomfortable. The overlying skin displayed no cellulitis, erythema or puncture wounds. Palpation did not reveal any obvious subcutaneous collections, and there was no neurovascular deficit. The shoulder area was globally very tender to touch.

The patient demonstrated signs of systemic sepsis with a tachycardia and a temperature of 39.1°C. Hematological and biochemical investigation revealed an elevated white cell count at  $13.88 \times 10^9/L$  (normal range:  $4.00-10.00 \times 10^9/L$ ), as well as a raised C-reactive protein at 267 mg/L (normal range: Less than 5 mg/L).

Please cite this article as: McElnay PJ, McCann PA, Williams MO, Wakeley CJ, Amirfeyz R. Recurrent *Fusobacterium* pyogenic myositis of the rotator cuff A case report of recurrent *Fusobacterium* pyogenic myositis of the rotator cuff. Int J Shoulder Surg 2014;8:31-3.

Shoulder radiographs were unremarkable. Both anterior and posterior glenohumeral joint aspirations were performed in the emergency department which produced a small amount of turbid fluid which was initially thought to have come from the joint. It is possible that this had penetrated the abscess in the deltoid which was to be discovered later. Microscopy of the aspirate demonstrated numerous white cells but no organisms were seen on Gram stain. No bacterial growth was identified after 40 h of incubation. The patient was commenced on intravenous flucloxacillin for a presumed native joint septic arthritis.

An ultrasound of the right shoulder was performed which failed to identify any significant intra-articular effusion. An MRI scan of the shoulder girdle demonstrated a moderate joint effusion, extensive swelling and abnormal signal within the subscapularis and teres minor [Figures 1 and 2]. The initial suspicion was of septic arthritis.

A posterior portal arthroscopic washout the shoulder was subsequently performed. A moderate amount of turbid fluid was discovered and multiple samples were sent. The joint was irrigated until clear with 6 L of saline. The immediate Gram stain of the turbid fluid failed to identify any bacteria.

Further surgical exploration was undertaken 3 days later because of poor clinical response. The lack of specific clinical signs made this clinical decision difficult. A posterior abscess could not be excluded. A deltopectoral approach was performed. No clear edema was encountered down to subscapularis. A subscapularis split failed to show pus in the joint. A finger sweeping under deltoid (laterally and posteriorly) opened an abscess which drained 500 mls of foul smelling, dark green pus. A large cavity of pus was identified between infraspinatus, teres minor and deltoid. Multiple samples were again taken. One was referred for 16s rRNA PCR.

A further debridement was undertaken 3 days later. The shoulder was approached posteriorly and pus was identified between the deltoid and infraspinatus muscle bellies. The anterior incision was also re-opened and further pus drained. The posterior and lateral deltoid was necrotic and was resected. Again multiple biopsies, including both muscle and fat were sent for analysis. The antibiotic regimen was

modified to intravenous piperacillin/tazobactam, however, shortly afterwards the specimen from the third surgical washout grew mixed anaerobes. Antibiotics were changed accordingly to gentamicin and then further to metronidazole and ciprofloxacin when sensitivities were available. Shortly afterwards the 16s rRNA PCR identified a mixed trace with fusobacterium species and Prevotella species. This suggested a primary upper airway focus.

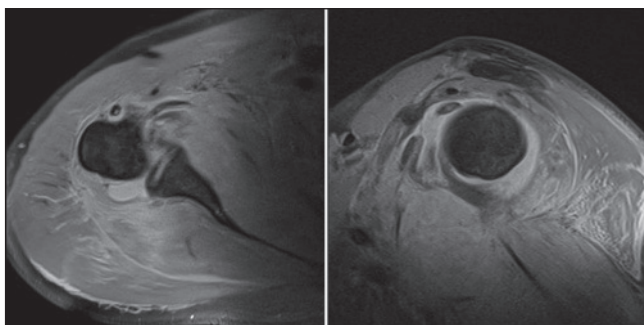
The patient's inflammatory makers transiently improved and then deteriorated once again. A repeat MRI scan was performed to ensure no other source of infection. It demonstrated no significant deterioration in the joint since open surgery. There was a small amount of joint fluid but no significant effusion. However, there was gross deterioration and swelling in the appearances of the surrounding musculature with gas and fluid in the soft tissues. This was highly suggestive of a rapidly progressive soft tissue infection. A fourth open debridement of the right deltoid area was undertaken on day 16 for failure of the inflammatory markers to improve. Pus was again identified and mixed anaerobes grown. Thorough debridement was carried out on the first episode so the re-accumulation was surprising.

The reason for recurrence was investigated. In order to exclude causes of an impaired immune response, a global immune screen, in addition to HIV and diabetes testing, was performed. It is of note that he was investigated with a CT on admission that showed no obvious collection making seeding from diverticulitis unlikely. It is postulated that, given his upper airway viral prodrome and the causative organism that this gentleman had a rare complication of Lemierre's syndrome.

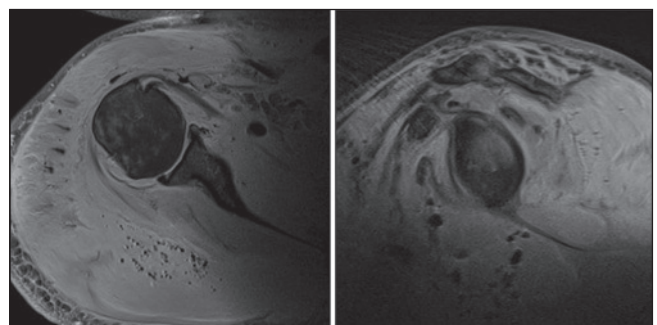
He was discharged on ciprofloxacin and reviewed at day 14 and day 21 after discharge. At both points he remained well and his inflammatory markers remained normal. At 6 months he remained systemically well and had full range of movement in his right shoulder.

## DISCUSSION

Whilst pyogenic myositis is rare it is a serious and potentially life threatening condition.<sup>[3]</sup> It was once thought to be primarily



**Figure 1:** Axial and sagittal fat suppressed T2 weighted MR images displaying joint effusion and high signal change within the muscle bellies of subscapularis and teres minor



**Figure 2:** Axial and sagittal fat suppressed T2 weighted MR images displaying further high signal change within the muscle bellies in addition to low signal loculations of gas within the soft tissues

a tropical disease but has increasingly been seen in developed countries.<sup>[4]</sup> In two-thirds of cases there is a well-documented pre-disposing condition such as diabetes, immunosuppressive therapy or HIV infection.<sup>[5]</sup> The condition has three stages: 1) Invasive, characterized by pain and swelling; 2) Suppurative, characterized by abscess formation, fever, tenderness and oedema; 3) Late, characterized by septic shock and end organ failure.<sup>[4]</sup> Most patients present in the suppurative stage.<sup>[4]</sup> Whilst a difficult diagnosis to make in the early stages, the clinician should be alerted to the diagnosis by the signs and symptoms if presenting in the suppurative stage.<sup>[5]</sup> The gold standard investigation is MRI of the affected area.<sup>[5]</sup> Treatment is with emergency surgical exploration and antimicrobial therapy.<sup>[5]</sup> The underlying cause of this gentleman's pyogenic myositis was thought to be Lemierre's syndrome. This syndrome is described as seeding of *Fusobacterium* into the blood stream after an oropharyngeal infection.<sup>[2]</sup> In rare cases it has been described to cause pyomyositis in the lower limbs and trunk. It has never been reported to cause recurring pyomyositis of the shoulder.

The case we present is uncommon for a number of reasons. Firstly, the initial clinical picture was confusing: A diagnosis of pyogenic myositis is not the most common cause of this patient's presentation, especially given no history of muscle damage. Secondly, the site of the infection is unusual as

pyogenic myositis normally affects the trunk and lower limbs. Thirdly, the recurring nature of the condition despite no detectable secondary source in an immunocompetent patient is exceptional. Finally, *Fusobacterium* is not a common organism in pyogenic myositis.

Whilst uncommon, pyogenic myositis should be considered in patients presenting with signs and symptoms similar to those with septic joints. Suspicion of Lemierre's syndrome should exist if there has been a viral-like prodrome.

## REFERENCES

1. Crum-Cianflone NF. Infectious myositis. *Best Pract Res Clin Rheumatol* 2006;20:1083-97.
2. Wolf RF, Konings JG, Prins TR, Weits J. *Fusobacterium* pyomyositis of the shoulder after tonsillitis. Report of a case of Lemierre's syndrome. *Acta Orthop Scand* 1991;62:595-6.
3. Brook I. Microbiology and management of Myositis. *Int Orthop* 2004;28:257-60.
4. Kelley C, Holmes J. A case of progressive pyomyositis: No longer just a condition of the tropics. *J Emerg Med* 2013;44:e339-40.
5. Annamalai AK, Gopalakrishnan C, Jesuraj M, Sureshkumar G, Chelian M, Srinivasan KG. Pyomyositis. *Postgrad Med J* 2013;89:179-80.

Source of Support: Nil, Conflict of Interest: None declared.